



مقرر (علم الحيوان Zoo 101– Zoology I "جزء الخلية والأنسجة")

لطلاب الفرقة الأولى بكلية العلوم شعبة البايوتكنولوجي للعام الدراسي

2023/2022 - التيرم الأول

الجزء العملي

د/ سهام علي مبارك- المدرس بقسم علم الحيوان

Microscopes

Types of microscopes

1- Light microscope

I- Illuminating system (source of light):

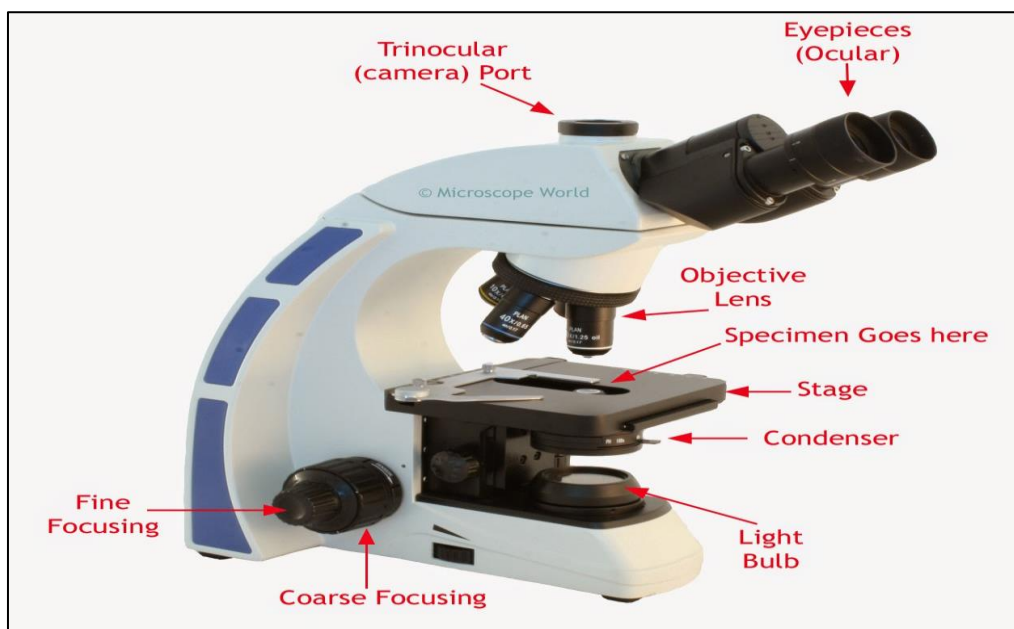
- Day light.
- Electric light.

II- Optical system:

- *Condenser lens*: collect and focus light on the specimen.
- *Objective lenses*: provide initial magnification (x4, x10, x40, x100).
- *An ocular lens (eyepiece)*: magnifies the primary

image a second time (x5, x10, x15).

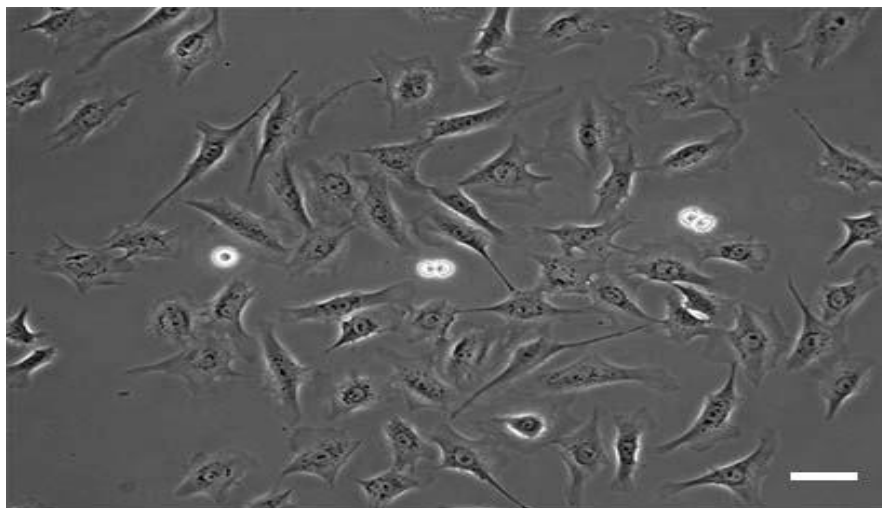
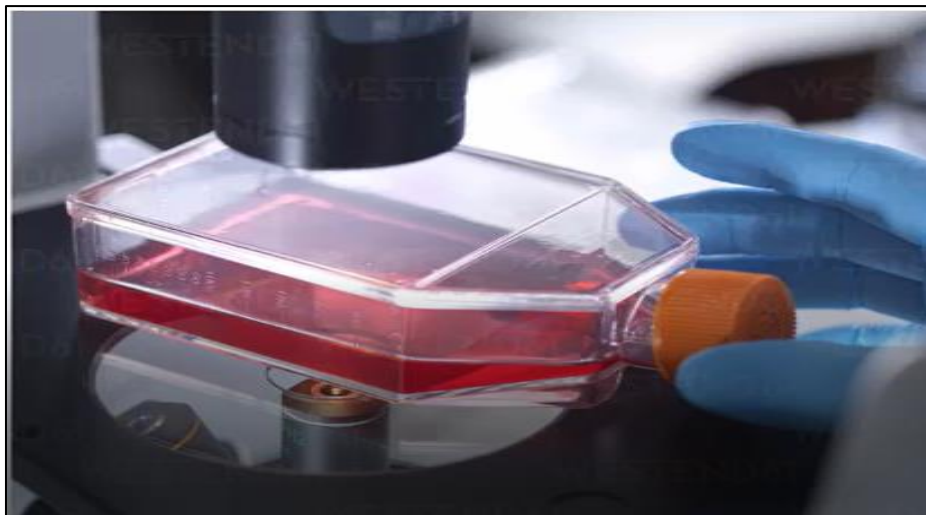III- Focus adjustment knobs: focus the image by moving the stage up and down.



Total magnification= Magnifying power of the objective lens x magnifying power of ocular lens


2- Phase contrast microscope

- **Use:** for unstained living histological specimen.



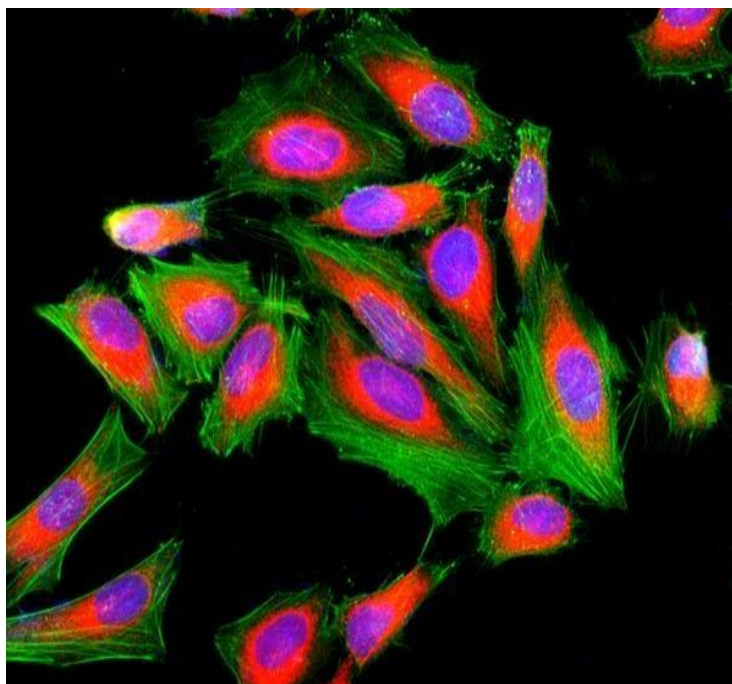
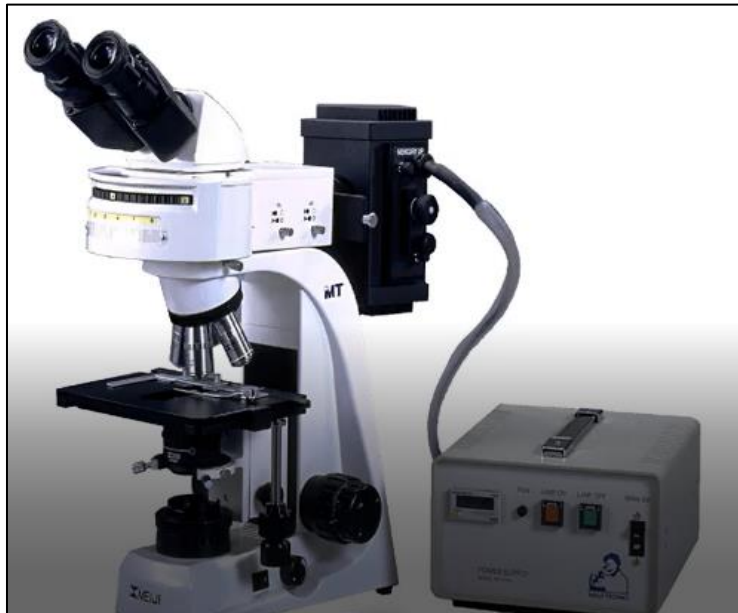3- Polarizing microscope

- Use:
 - Regularly oriented structures (bone).
 - Structures with linear symmetry (collagen, muscle, microtubules, cilia& flagella).



4- Fluorescence microscope

- **Light source:** ultraviolet light source.
- **Stain:** fluorescent stain.
- **Idea:** the specimen absorbs the UV light and emits light of a longer wavelength.
- **Use:** immunohistochemistry.



5- Electron microscope


- **Illuminating system:** electron beam.
- **Types:**

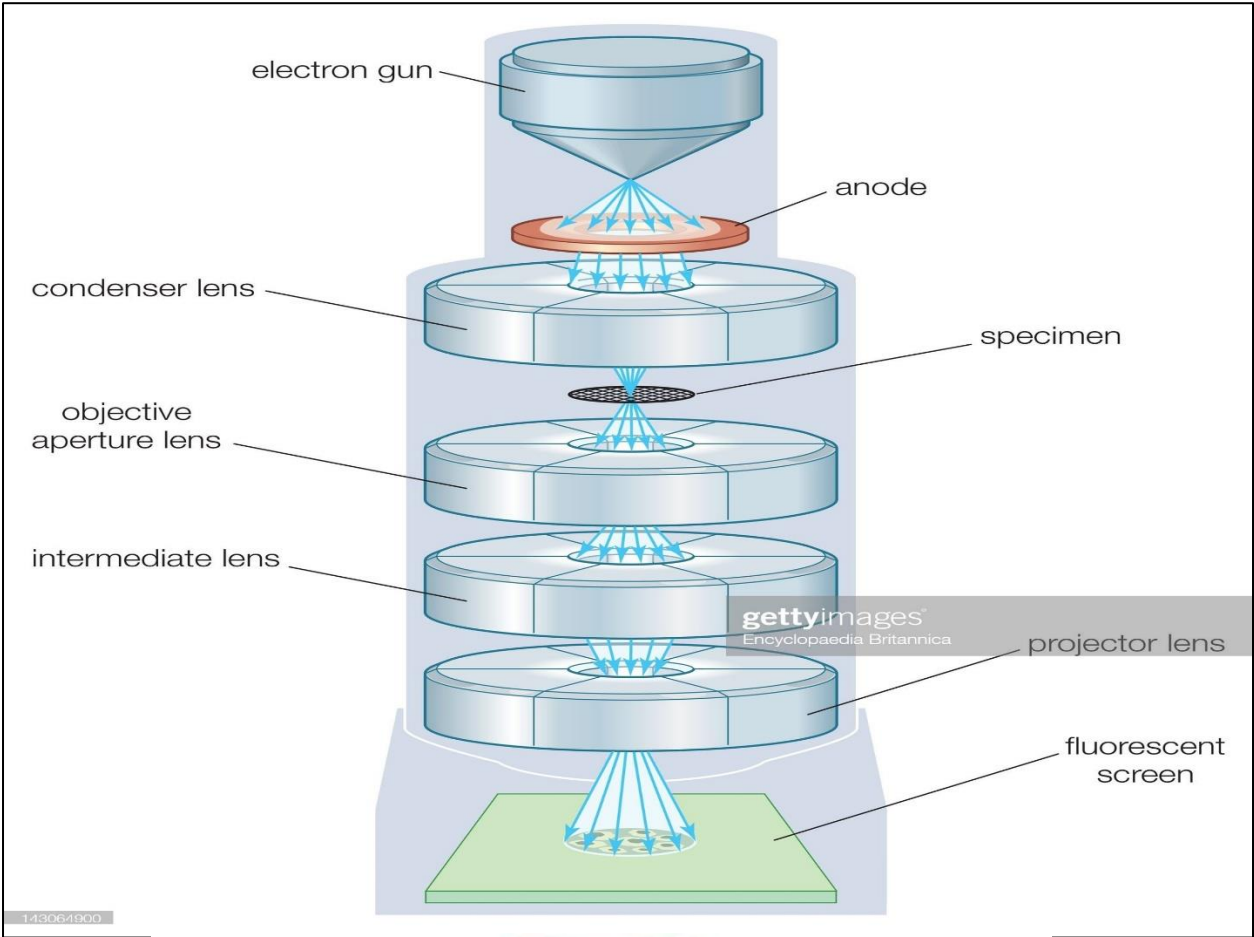
1- Transmission EM:

- It gives details about the cellular and intercellular structures.
- An electron gun at the top of a TEM emits electrons.
- An electromagnetic lens focuses the electrons into a very fine beam.
- This beam then passes through a very thin specimen.
- Another electromagnetic lenses form and magnify the image.
- The final image is viewed on a fluorescent screen.

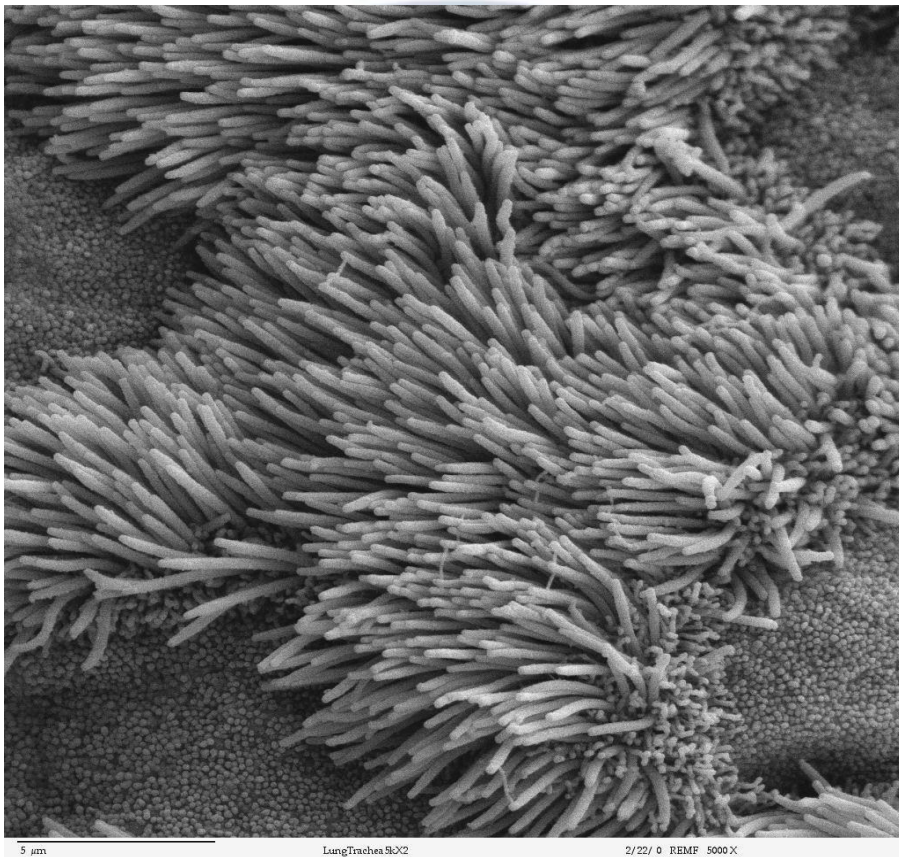
2- Scanning EM:

- Gets 3-D image of the surface of the specimen.





SEM



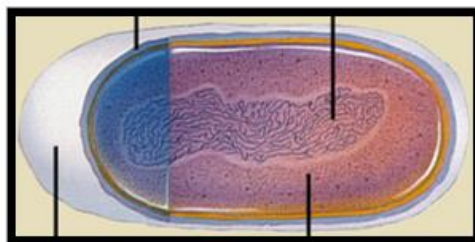
Type of microscope	LM	EM
1- Source of light	Day or electric light.	Beam of electrons.
2- Lenses	Glass lenses.	Magnetic fields.
3- Magnification	Up to 1500.	Up to 1000.000.
4- Embedding	Paraffin.	Plastic.
5- Sectioning knife	Rotatory microtome: steel knife.	Ultra microtome: glass or diamond knife.
6- Staining	Any stain.	Lead citrate & osmium tetroxide.
7- Thickness of section	5-9 microns.	50-90 nm.
8- Microphotographs	Colored according to stain.	Black & white.

Cytology

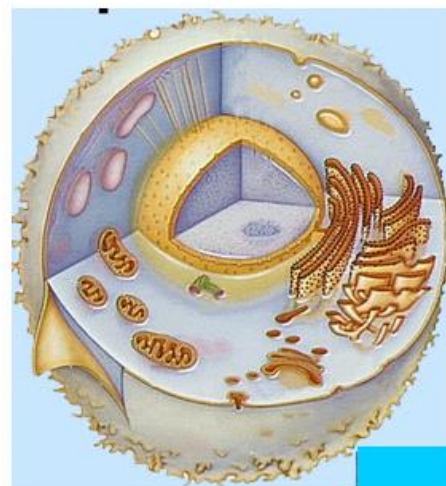Different Types of Cells

Definition of a cell	Smallest functional unit within a living organism that can function independently
Components	Plasma membrane, cytoplasm, nucleus, membranous organelles, non-membranous organelles
Membranous organelles	Nucleus, Endoplasmic reticulum, Golgi apparatus, mitochondria, peroxisomes, lysosomes, transport vesicles
Non-membranous organelles	Ribosomes, microtubules, cytoskeleton (actin filaments, intermediate filaments, centrioles)

Two Fundamentally Different Types of Cells

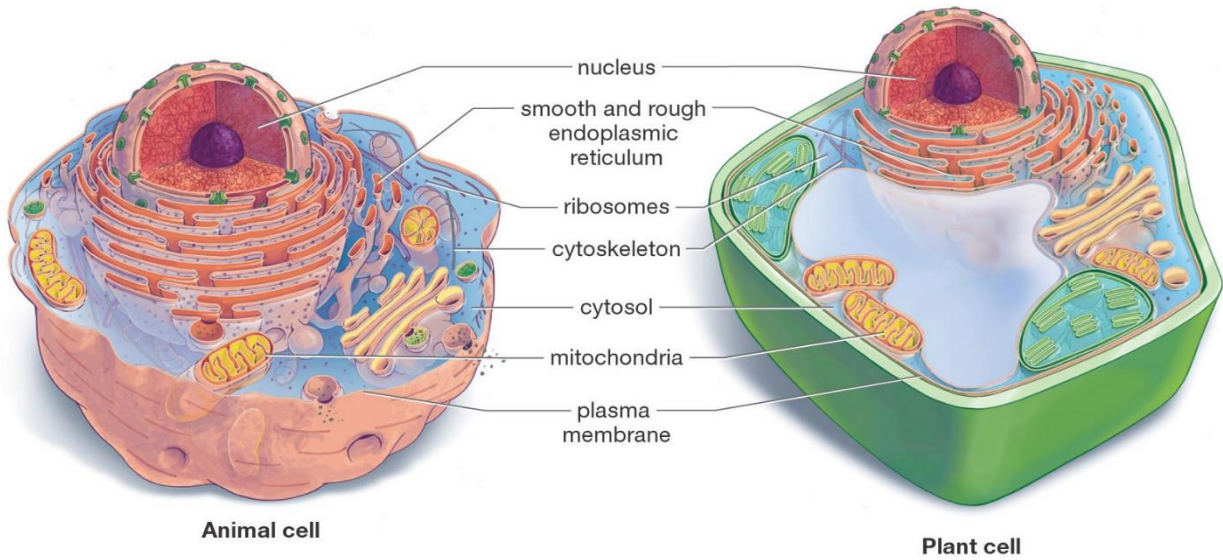


A prokaryotic cell

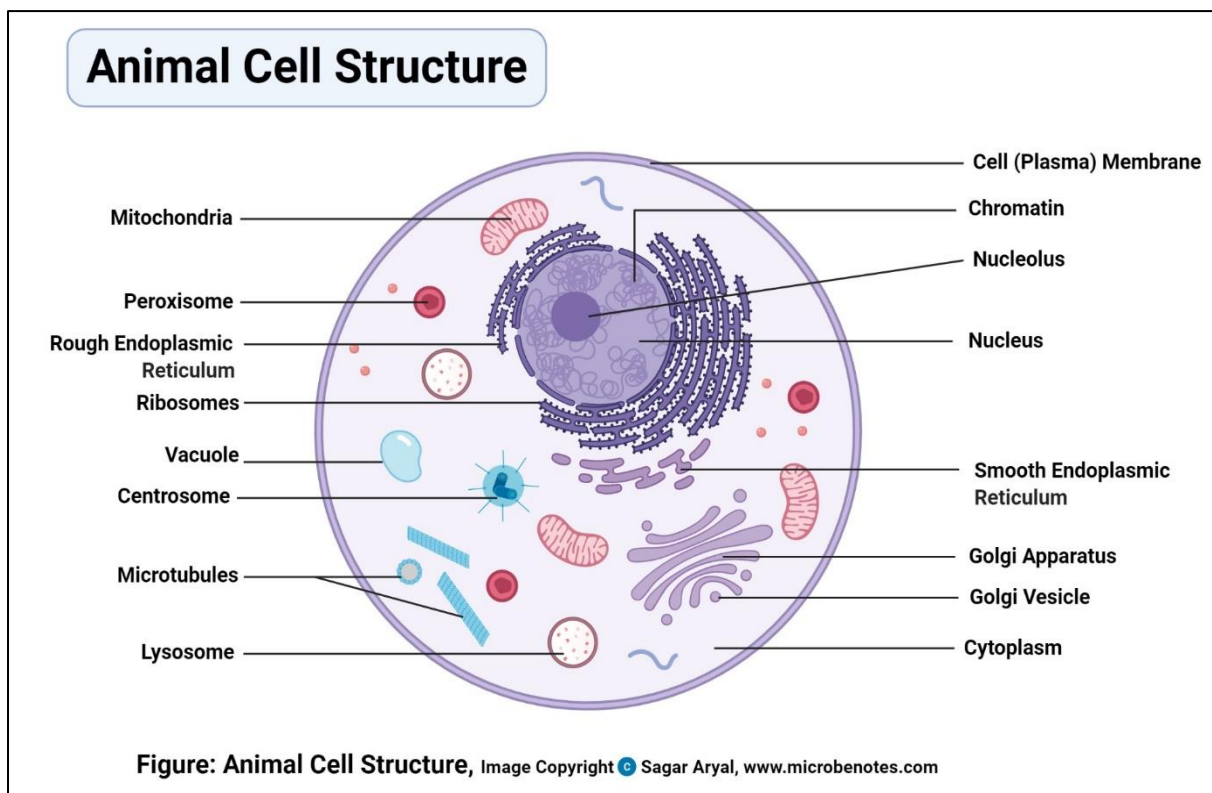


A eukaryotic cell

Animal and Plant Cells Have More Similarities Than Differences

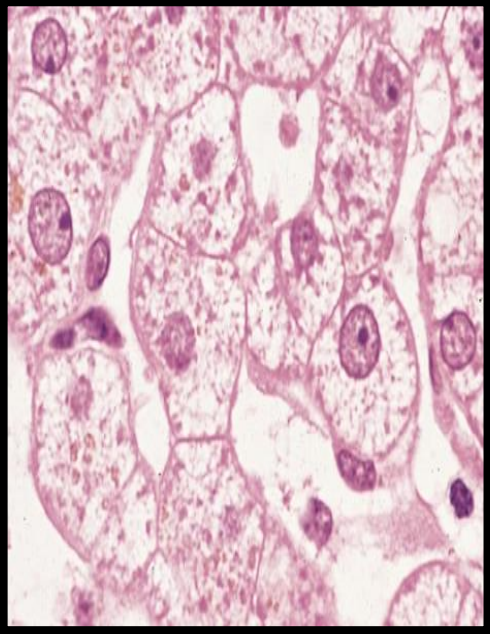
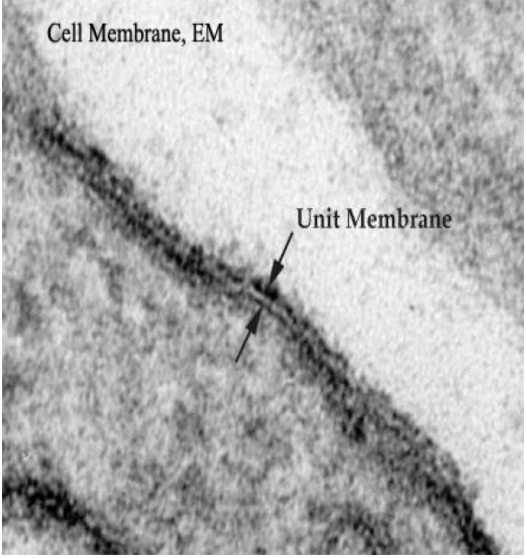


Draw animal cell

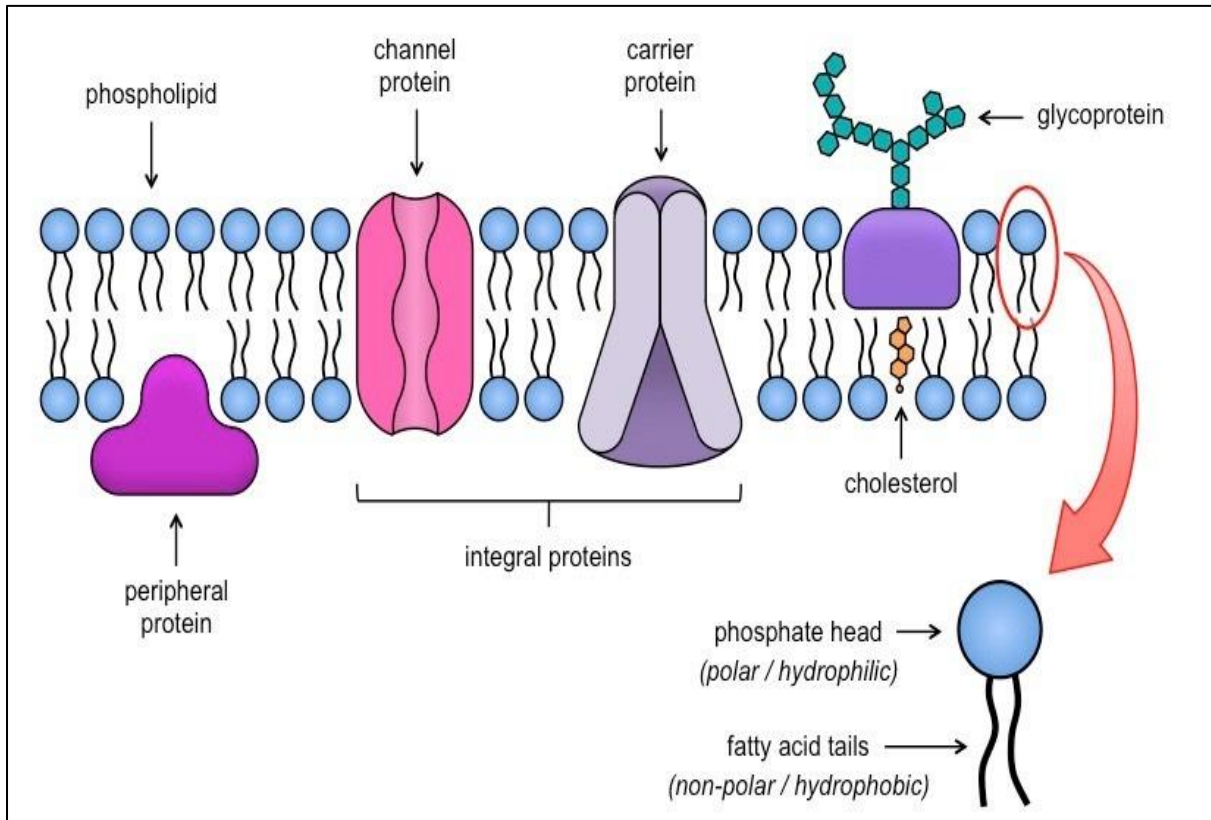


Cell organelles

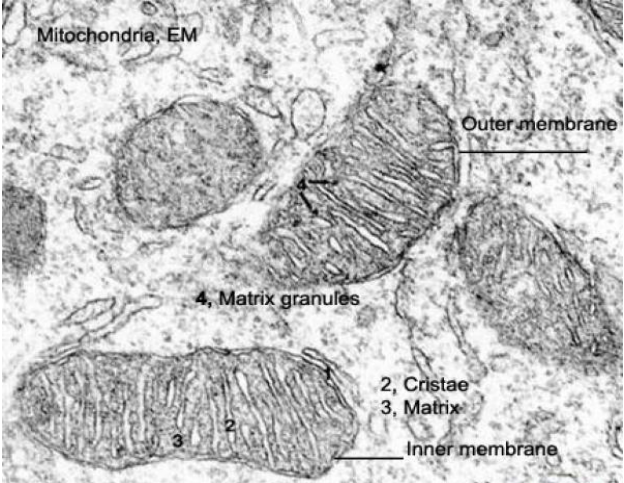
1- Cell membrane

		Structure	Function
		Molecular structure of the Cell membrane 3 components: 1-Lipid molecules: a- phospholipids b- cholesterol 2- Protein molecules: 50% of the membrane mass. 3- Carbohydrate molecules	Its function is to protect the integrity of the interior of the cell by allowing certain substances into the cell while keeping other substances out. It also serves as a base of attachment for the cytoskeleton in some organisms and the cell wall in others. Thus, the cell membrane also serves to help support the cell and help maintain its shape.
		LM	EM
Cell membrane	It can not be seen by light microscope <i>because</i> it is too thin to be seen <i>but</i> the condensation of the stain on the outer surface of the cell membrane marks its.		1- <i>At low magnification:</i> thin dense line 8 - 10 nm in thickness. 2- <i>With higher magnification:</i> a trilaminar structure, with an outer (= extracellular leaflet) and an inner (= cytoplasmic leaflet) electron dense lines and a middle electron lucent zone in between.
			

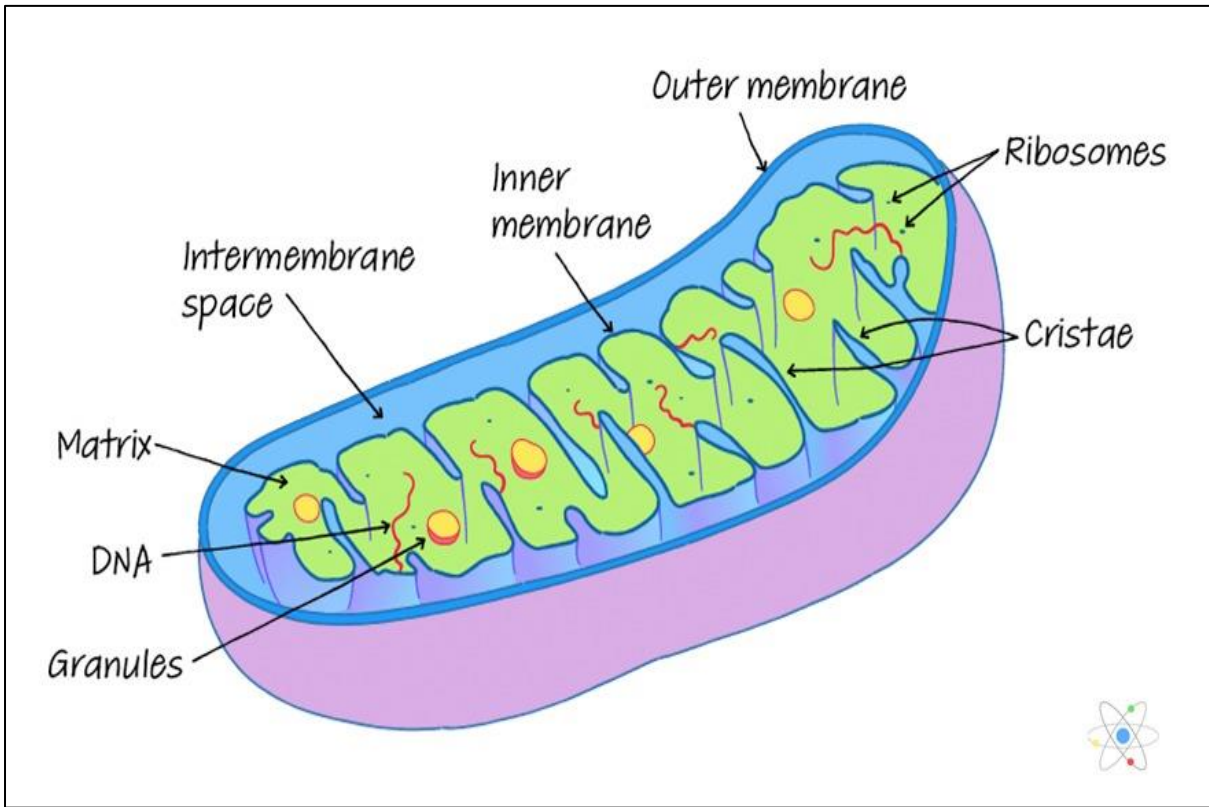
Draw



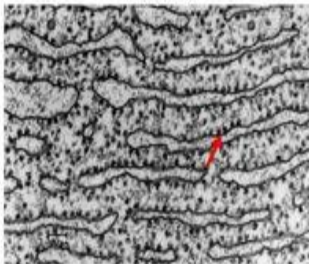
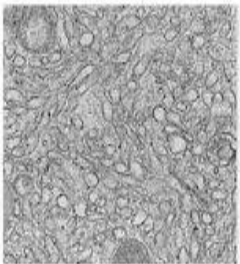
2- Mitochondria

Mitochondria	Structure	Function
	<p>The mitochondrion is composed of compartments that carry out specialized functions. These compartments or regions include the outer membrane :</p> <ol style="list-style-type: none"> 1. The outer mitochondrial membrane. 2. The intermembrane space (the space between the outer and inner membranes). 3. The inner mitochondrial membrane . 4. The cristae space (formed by infoldings of the inner membrane) . 5. The matrix (space within the inner membrane), which is a fluid. 	<ul style="list-style-type: none"> • They house the chains of enzymes that catalyze reactions that provide the cells with most of its ATP (adenosine triphosphate). • On demands, the ATP yields its high-energy phosphate bond to another molecule and become transformed into ADP. • Within the mitochondrial matrix, ADP is transformed again into ATP. These processes take place within the mitochondrial matrix and inner mitochondrial membranes. • The matrix contains enzymes of Krebs cycle and fatty acid oxidation. The inner membrane contains the cytochromes and the enzymes involved in ATP production. • Due to their role in energy production, the mitochondria are likened to powerhouses of the cells. • Participate in regulation of calcium level within the cytosol.
	LM	EM
	<p>they appear as granules, rod-like or thread-like. Their size rage from 5-10 mm length and 0.5-1 mm in diameter. The number is highly variable according to the energy requirements of the cells. Liver cells (active cells) contain as many as 1000 mitochondria. Small lymphocytes (inactive cells) contain very few.</p> <p>They are motile organelles and localize at intracellular sites of high-energy requirements such as basal regions of ion-transporting cells</p>	<p>they appear as ovoid or elongated structures bounded by two membranes. The outer membrane is smooth. The inner membrane is thrown into folds called cristae projecting into the inner cavity that is filled with an amorphous substance called matrix. The number of the cristae seen in mitochondria is directly related to the energy requirement of cell .</p>  <p>The electron micrograph shows several mitochondria with a smooth outer membrane and a highly folded inner membrane forming cristae. Labels include: 'Mitochondria, EM' at the top left, 'Outer membrane' on the right, '4, Matrix granules' in the center, '2, Cristae' and '3, Matrix' at the bottom right, and 'Inner membrane' at the bottom right.</p>

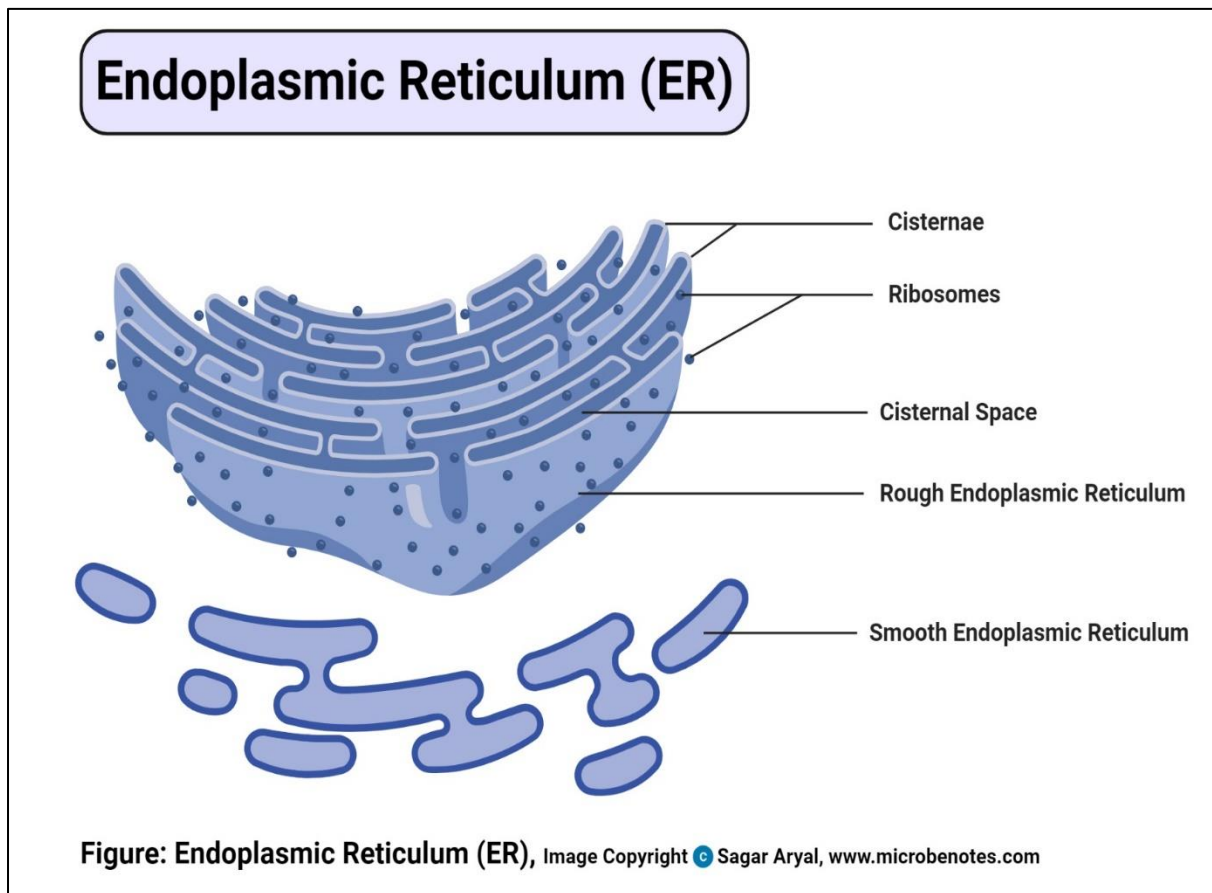
Draw



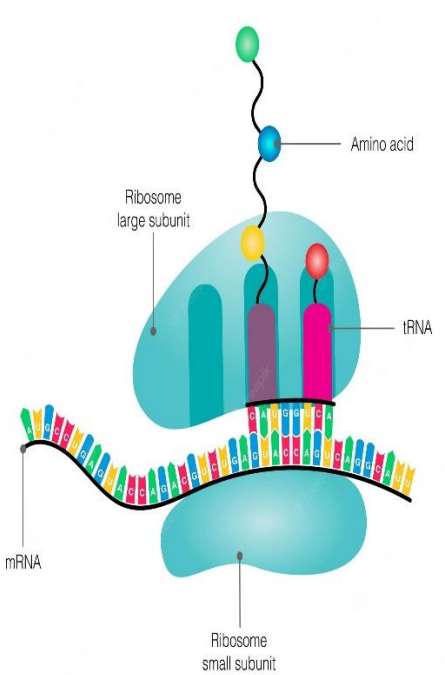
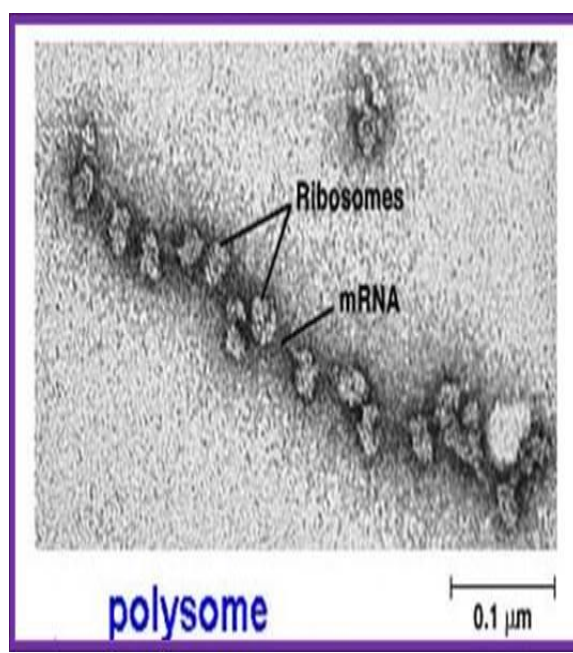
3- Endoplasmic reticulum

Endoplasmic reticulum	Structure	Function
	<p>The rough endoplasmic reticulum (rER) is a membranous organelle concerned principally with synthesis and secretion of proteins. It is called rough due to the presence of large number of ribosomes attached to its limiting membrane.</p> <p>The smooth endoplasmic reticulum (sER)</p> <p>is a membranous organelle consists primarily of a network of branching and anastomosing tubules and vesicles.</p> <p>It differs from the rER in that its limiting membrane is smooth and devoid of ribosomes.</p>	<p>rER</p> <ul style="list-style-type: none"> ✓ Synthesis of proteins for extracellular use (secretory proteins, lysosomal proteins and membrane proteins). ✓ Glycosylation of proteins to form glycoproteins. <p>sER</p> <ul style="list-style-type: none"> ✓ Steroid hormone synthesis in the testicular interstitial cells, the cells of the corpus luteum and adrenal cortex cells. ✓ Drug detoxification in liver cells. ✓ Lipid synthesis in the intestinal absorptive cells. ✓ Release and storage of Ca ++ ions in striated muscle cells. ✓ Production of HCL in gastric parietal cells.
	LM	EM
	<p>rER</p> <p>it appears as basophilic cytoplasmic areas that are referred to as the ergastoplasm or chromidial substances.</p> <p>sER</p> <p>it does not appear. The cytoplasm of the cells contained abundant sER usually appears acidophilic.</p>	<p>rER; Much of the surface of the rER is studded with ribosomes giving the reticulum a rough or granular appearance.</p> <p>sER; it appears as irregular network of membranous tubules and vesicles devoid of ribosomes in contrast to the flattened ribosome-studded cisternae of rER. The sER tubules may be continuous with those of rER and Golgi apparatus.</p> <div style="display: flex; justify-content: space-around; align-items: center;"> <div style="text-align: center;"> <p>Rough endoplasmic reticulum (RER)</p>  </div> <div style="text-align: center;"> <p>Smooth endoplasmic reticulum (SER)</p>  </div> </div>

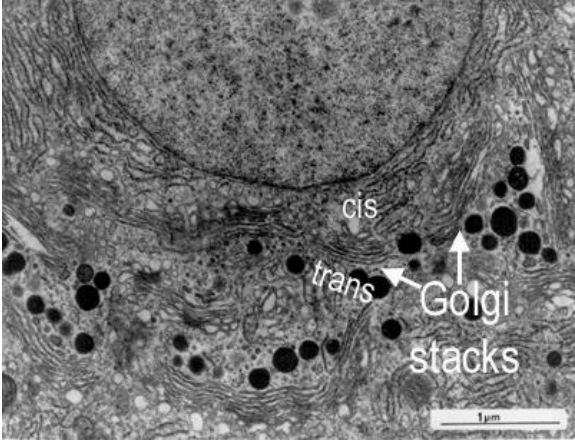
Draw



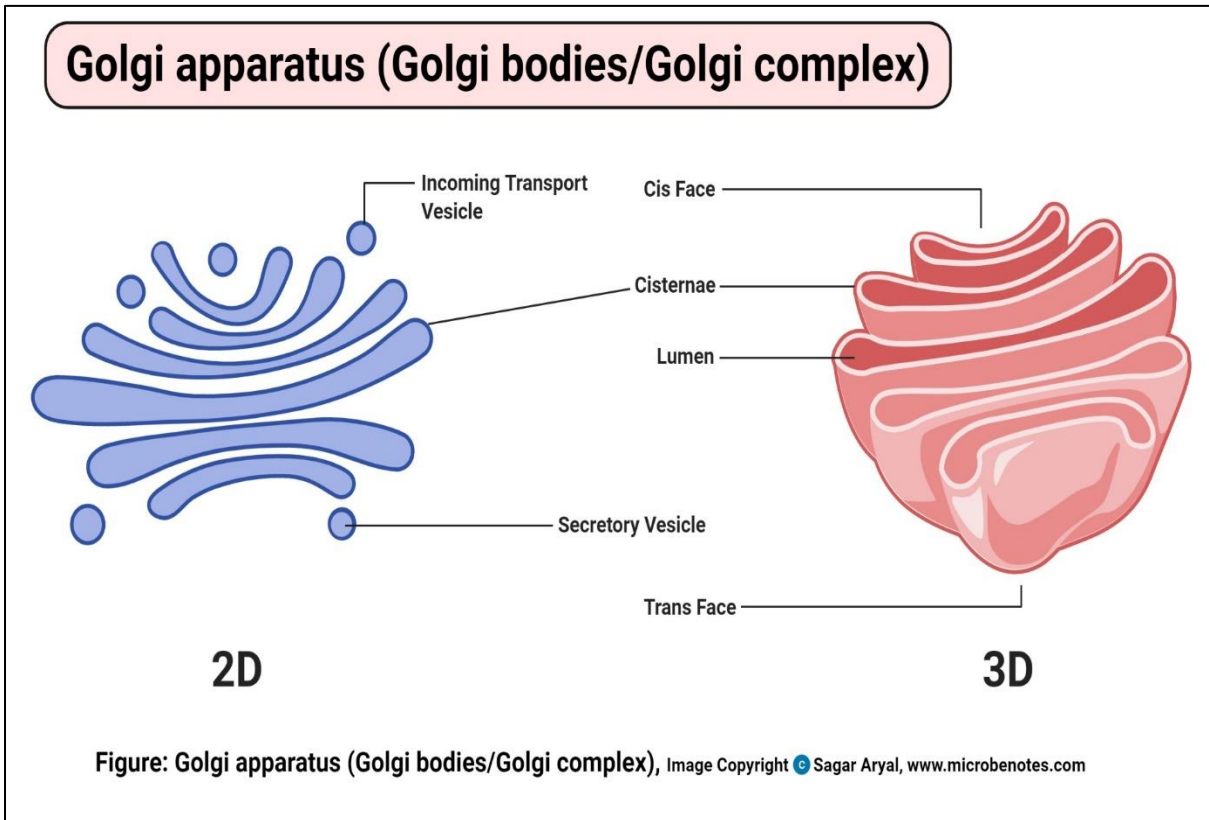
4- Ribosomes

		Structure	Function
Ribosomes		<ul style="list-style-type: none"> ✓ They are rounded ribonucleoprotein particles, 20-30 nm in diameter that provide the intracellular sites where amino acids are linked together to form polypeptide chains (proteins). ✓ Each ribosome composed of a large and a small subunit that are made of rRNA and different types of proteins. 	<ul style="list-style-type: none"> ✓ Free ribosomes are responsible for synthesis of proteins for internal use (cytoplasmic proteins and enzymes). ✓ Attached ribosomes are responsible for synthesis of proteins for external use (secretory or lysosomal enzymes).
		LM	EM
		they are too small to be seen. However, cell containing abundant ribosomes usually has basophilic cytoplasm. Such cytoplasmic basophilia is largely due to the strong affinity of rRNA for hematoxylin.	ribosomes are seen free in the cytoplasm either as separate entities or attached to messenger RNA molecules in small aggregation called polyribosomes or polysomes. Polyribosomes may also be attached to the surface of rER.
		Diagram	
		<p style="text-align: center;">Ribosome</p>  <p>The diagram illustrates a ribosome with a large subunit (top) and a small subunit (bottom). An mRNA molecule is shown passing through the ribosome. A tRNA molecule is attached to the mRNA, carrying an amino acid. The amino acid is being added to a growing polypeptide chain. Labels include: Ribosome large subunit, Ribosome small subunit, mRNA, tRNA, and Amino acid.</p>	 <p>The electron micrograph shows a polysome, which is a complex of multiple ribosomes attached to a single mRNA molecule. The ribosomes appear as small, dark, rounded structures. The mRNA is a long, thin, wavy line. Labels include: Ribosomes, mRNA, polysome, and a scale bar of 0.1 μm.</p>

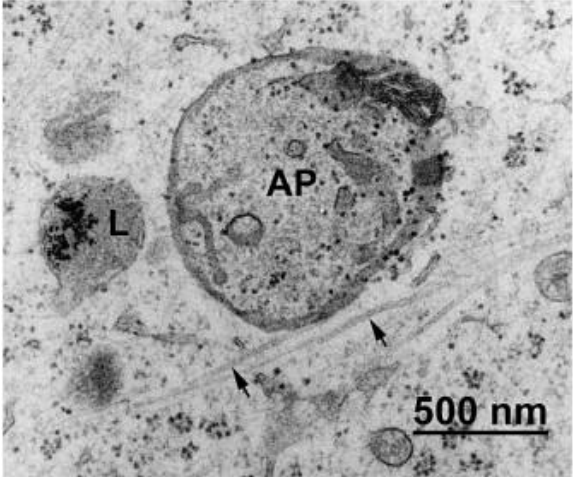
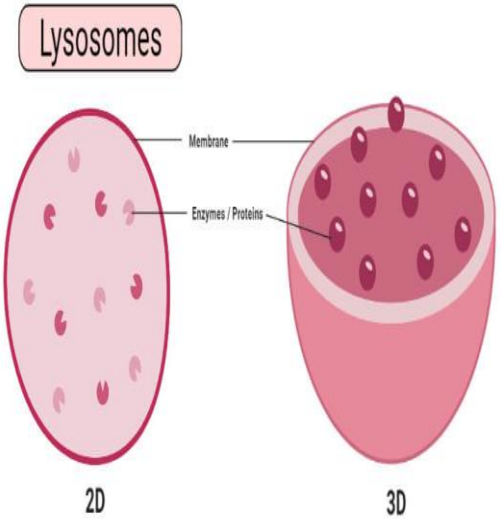
5- Golgi apparatus

Golgi apparatus	Structure	Function
	<ul style="list-style-type: none"> • a membranous organelle concerned principally with synthesis, concentration, packaging and release of the secretory products. • The Golgi saccules are arranged in Golgi stacks that contain from 3-10 saccules. Most cell types possess several stacks of Golgi saccules forming an elaborate ramifying network termed the Golgi complex. • Each stack of saccules has 1) a forming face or Cis face that is convex in shape. 2) a maturing face or trans face that is concave. The Cis face is usually associated with a number of small transfer vesicles. The trans face characterized by being associated with much larger secretory granules. 	<ul style="list-style-type: none"> • Packaging and concentration of secretions. • Modification of the secretory products such as glycosylation and sulfation of proteins to form glycoproteins and sulfated glycoproteins (mucus). • Production of primary lysosomes.
	LM	EM
	<p>it can be selectively stained with silver salts or osmium where it appears as a black network located near the nucleus. In H&E sections, it may be visible as a lighter-stained region called negative Golgi image. It is seen to great advantage in secretory cells such as osteoblasts.</p>	<p>the main structure unit of the Golgi apparatus is a flattened membranous vesicle called Golgi saccule.</p> 

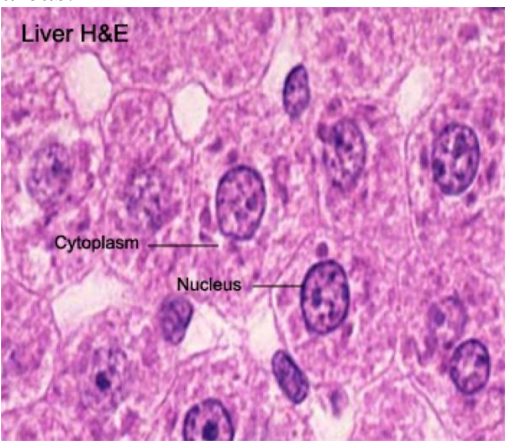
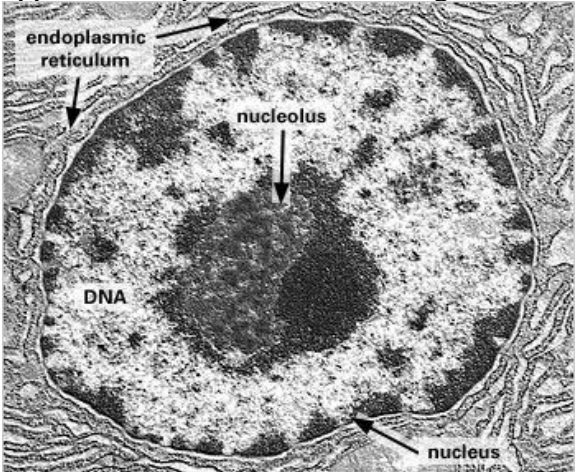
Draw



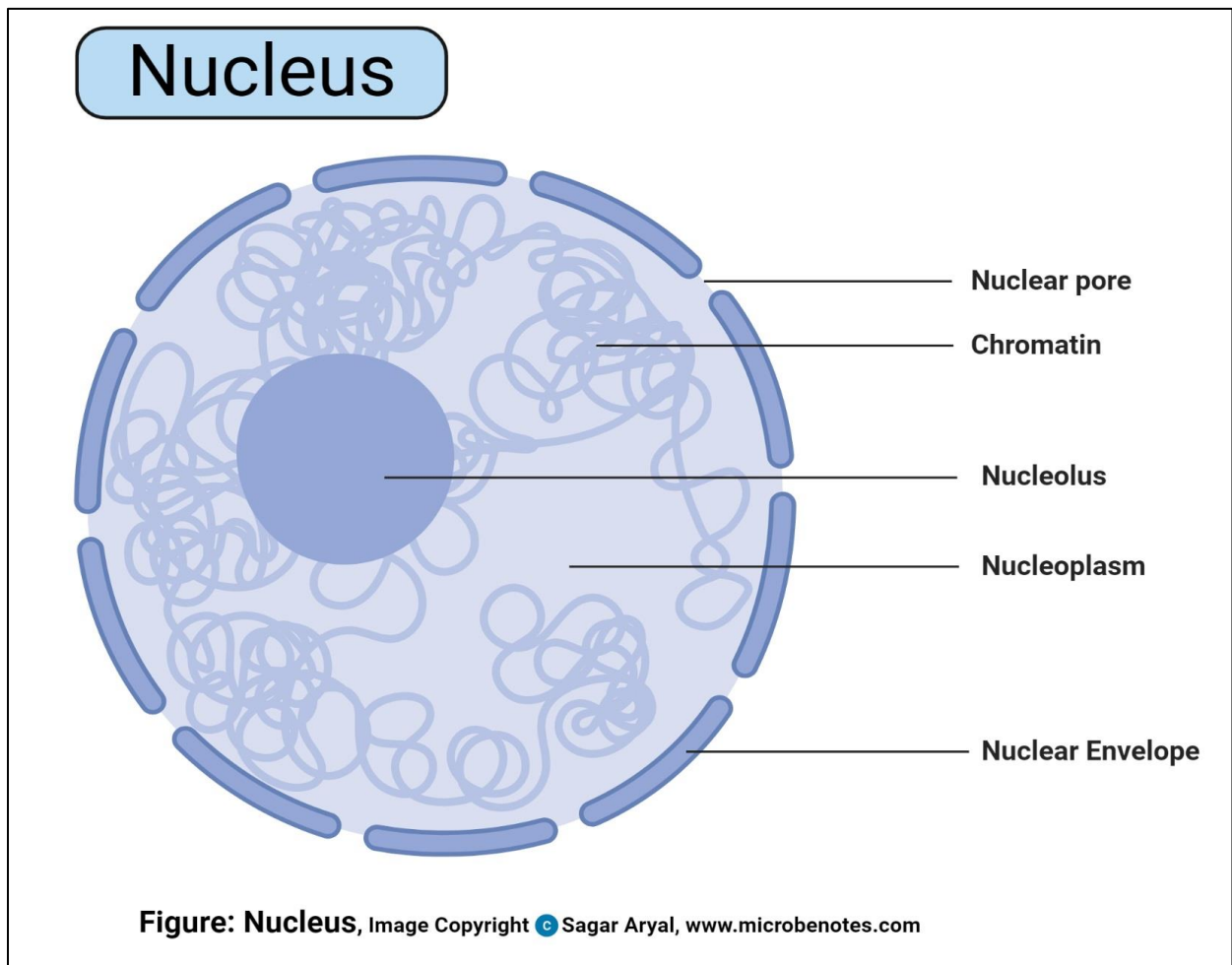
6- Lysosomes

Lysosomes	Structure	Function
	They are membrane-bounded vesicles (0.2-0.4µm) containing a number (more than 40) of hydrolytic enzymes that are active at acid pH (acid hydrolases) maintained within their interior. This group of enzymes is capable of destroying all the major macromolecules (e.g., proteins and lipids) of the cells.	<ul style="list-style-type: none"> ✓ Degradation of any exogenous macromolecules (phagocytosis and pinocytosis). ✓ Disposition of any organelles or cell constituents that are no longer useful to the cell (autophagy).
	LM	EM
	provides no direct evidence for the existence of lysosomes. The lysosomes are resolved at the LM level when their enzyme contents (e.g., acid phosphatase) are stained by histochemical methods.	The lysosomes appear as spherical membrane-bounded vacuoles with there contents showing varying degree of electron density.
	Diagram	
		

7- Nucleus

		Structure	Function
Nucleus		<p>It is the largest membranous organelle of the cell.</p> <p>The interphase (not engaged in cell division) nucleus consists of nuclear envelope, chromatin, nucleolus, and nuclear sap (karyolymph).</p> <ol style="list-style-type: none"> 1. Nuclear envelope 2. Chromatin <p>two types of chromatins are distinguished: heterochromatin and euchromatin.</p> <ol style="list-style-type: none"> 3. Nucleolus <p>a conspicuous, spherical, basophilic structure that is primary concerned with synthesis of ribosomal RNA.</p> <ol style="list-style-type: none"> 4. Nuclear sap (karyolymph) <p>The nuclear sap is a colloidal solution in which chromatins are suspended. It helps in the movement of RNA (rRNA, tRNA, and mRNA) toward the nuclear pores.</p>	<ul style="list-style-type: none"> ✓ The nucleus is the archive of the cell that carries the genetic information necessary to regulate the different cell functions. It consists primarily of DNA (20% of its mass), DNA-binding proteins, and some RNA. ✓ The DNA-binding proteins are of two major type histones and non-histones. The histones are involved in the folding of DNA strands and regulation of DNA activity. The non-histones are involved in the regulation of gene activity. ✓ The nuclear RNA represents newly synthesized transfer and ribosomal RNA that has not yet passed into the cytoplasm.
	LM	EM	
	appears as lightly-stained basophilic areas.	appears as dispersed filaments or granules.	
			

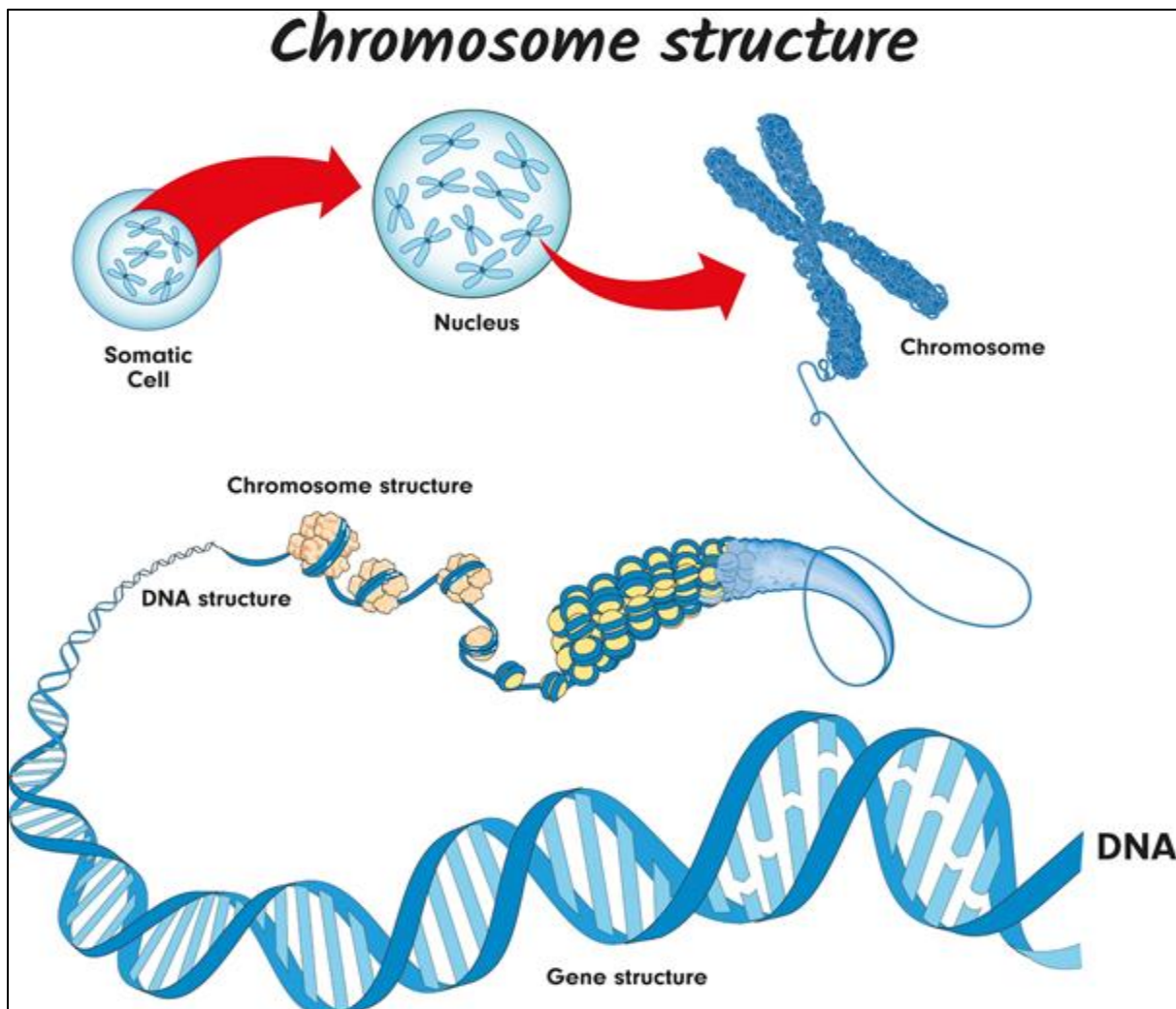
Draw



8- DNA and chromosomes

Inside the nucleus of a cell, there are thread-like structures called chromosomes. Each chromosome is made out of a long, coiled up strand of DNA (genetic material), which means that each chromosome contains many genes.

Normally, there are 46 chromosomes inside the nucleus of each human body cell. Chromosomes are usually found in pairs.



A **diploid** cell contains two complete sets of chromosomes in its nucleus, one from each parent. In humans, all body cells are diploid cells. Human diploid cells have 23 pairs of chromosomes (46 in total). The diploid number is often represented as $2n$, with n being the number of chromosomes. In humans, $2n = 46$.

The word **haploid** means half. It describes a cell that contains a single set of chromosomes. The symbol n is often used to show the haploid number. In humans, $n = 23$. Human sex cells (egg and sperm cells) contain a single set of chromosomes, so they are haploid cells.

- Sex cells are also called **gametes**

Histology

Tissue Preparation for Light Microscopy

- ✓ Stabilize cellular structures by chemical fixation.
- ✓ Dehydrate and infiltrate tissues with paraffin or plastic.
- ✓ Embed fixed tissues in paraffin or plastic blocks.
- ✓ Cut into thin slices of 3-10 micrometer thick; collect sections on slides.
- ✓ Re-hydrate and stain with Hematoxylin (a basic dye): Stains basophilic structures (e.g. nucleic acids) blue/purple.
- ✓ Counterstain with Eosin (an acidic dye): Stains acidophilic or “eosinophilic” structures (e.g. proteins, membranes) red/pink.
- ✓ “H & E” staining is routine, but other dyes and staining techniques may be used to visualize other structures.

Types of tissues

(A group of cells that all perform the same specific function)

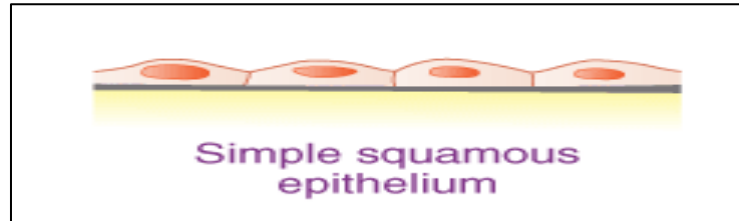
1. Epithelial Tissue – covers body surfaces and organs, lines body cavities
2. Connective Tissue – binds and supports body parts
3. Muscular Tissue – contracts producing movement
4. Nervous Tissue – responds to stimuli and transmits nerve impulses

1. Epithelial Tissue

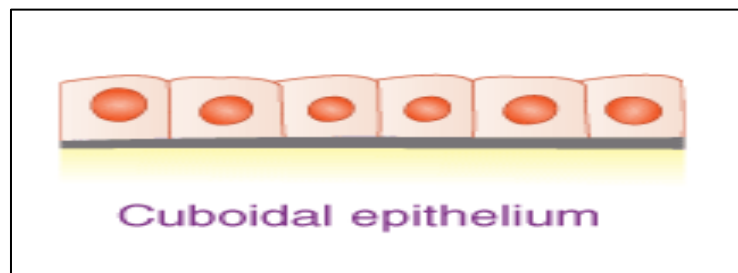
Simple epithelium

It consists of single layer of epithelial cells resting on basement membrane.

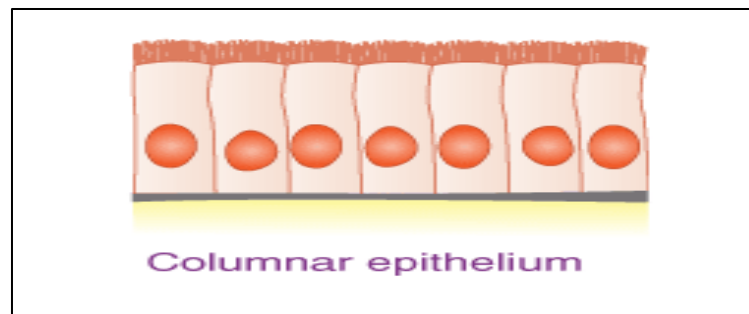
i. Simple squamous epithelium



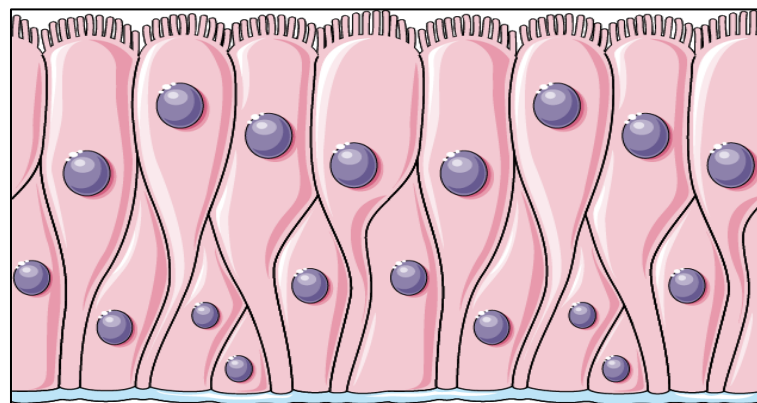
ii. Simple cuboidal epithelium



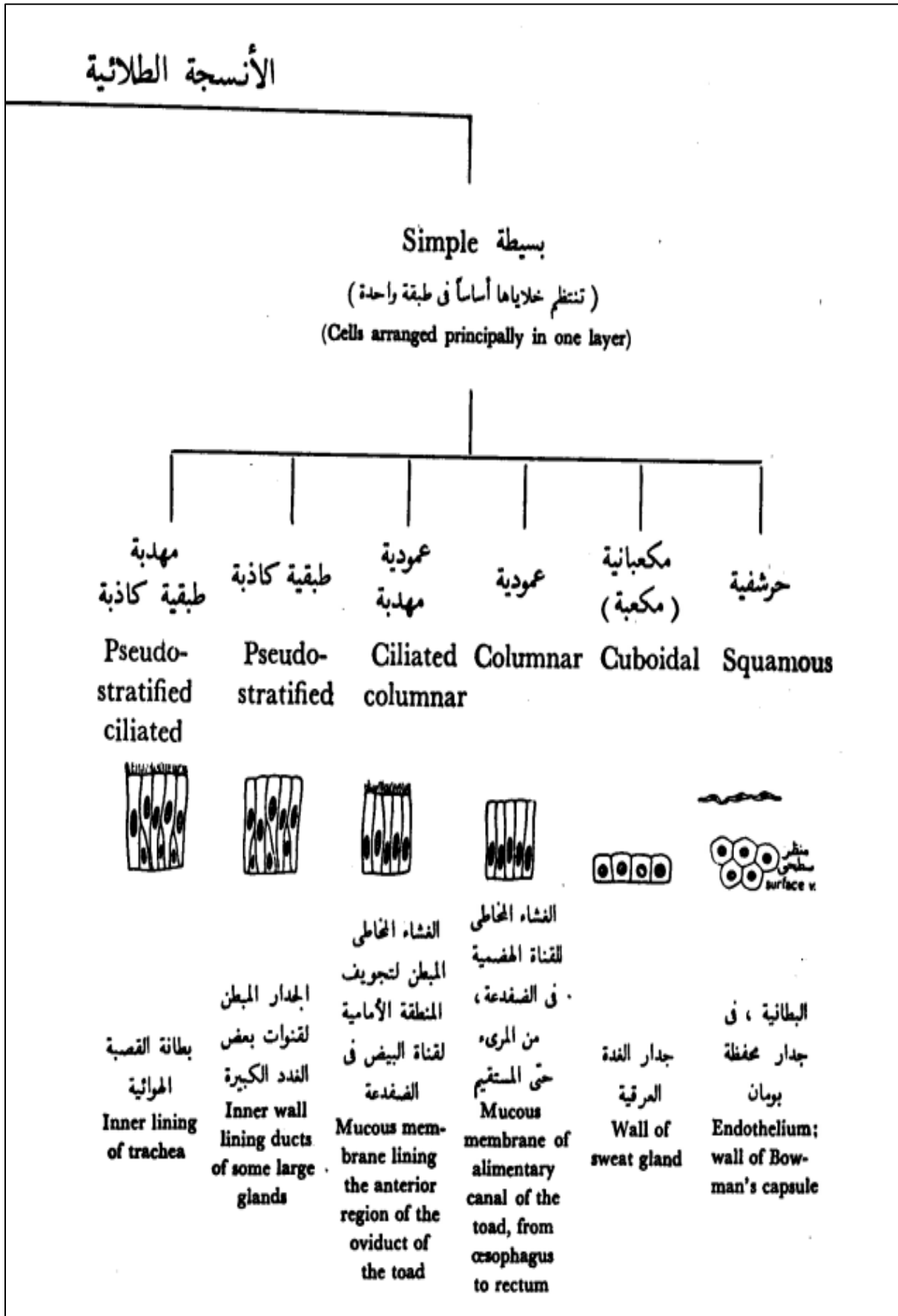
iii. Simple columnar epithelium



iv. Pseudostratified columnar epithelium

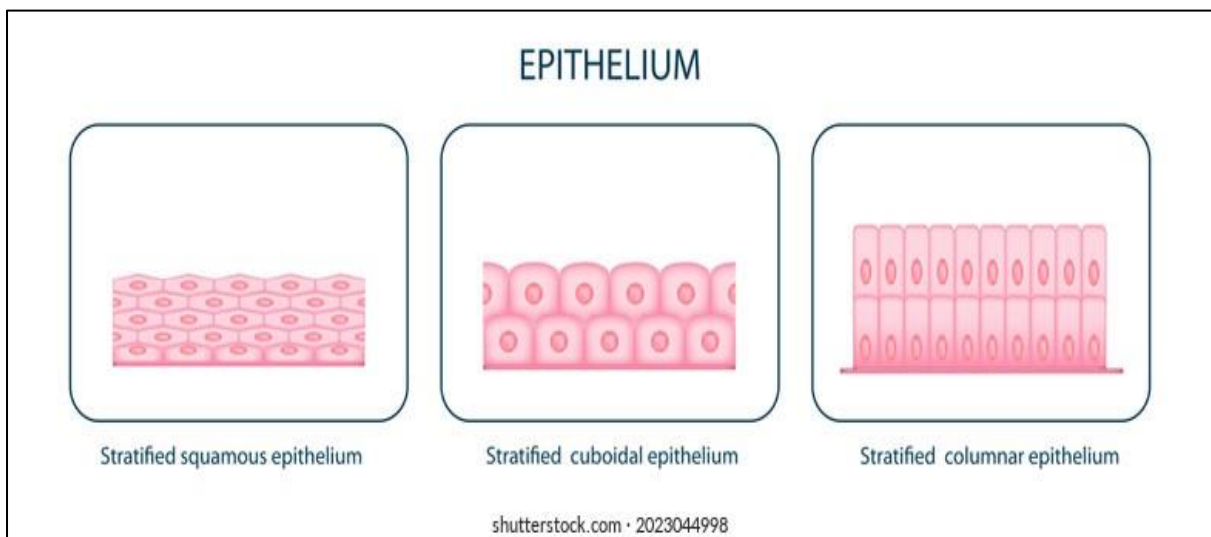


Draw

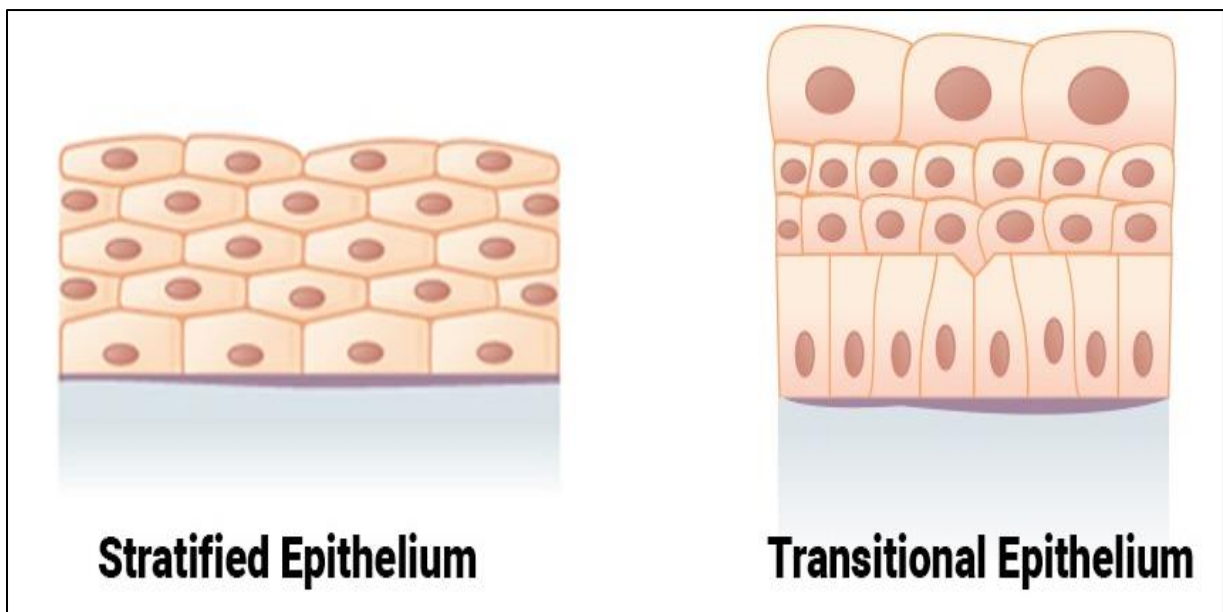


Stratified epithelium

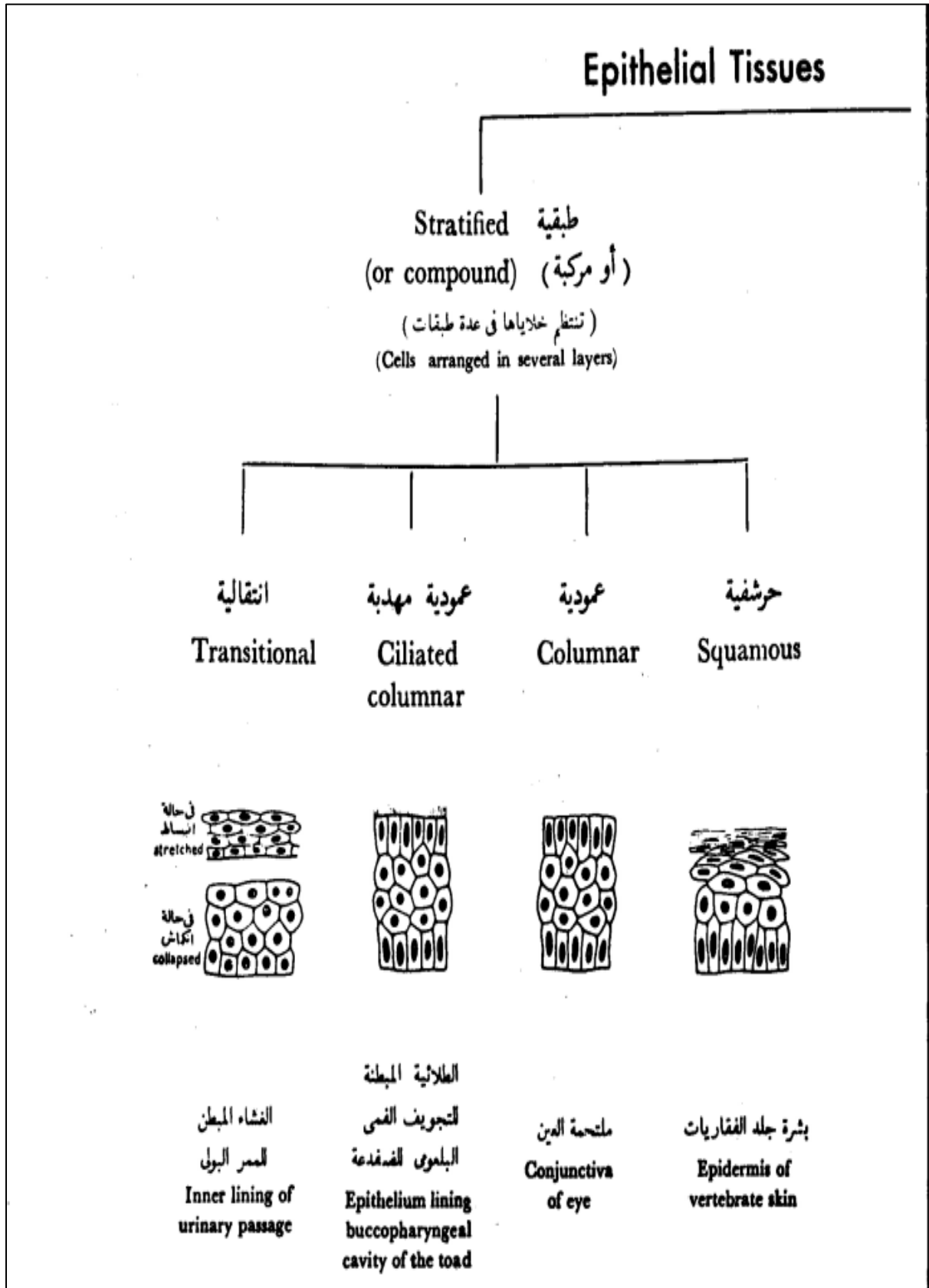
- It consists of two or more than two layers of cells.
 1. Stratified squamous epithelium
 2. Stratified cuboidal epithelium
 3. Stratified columnar epithelium



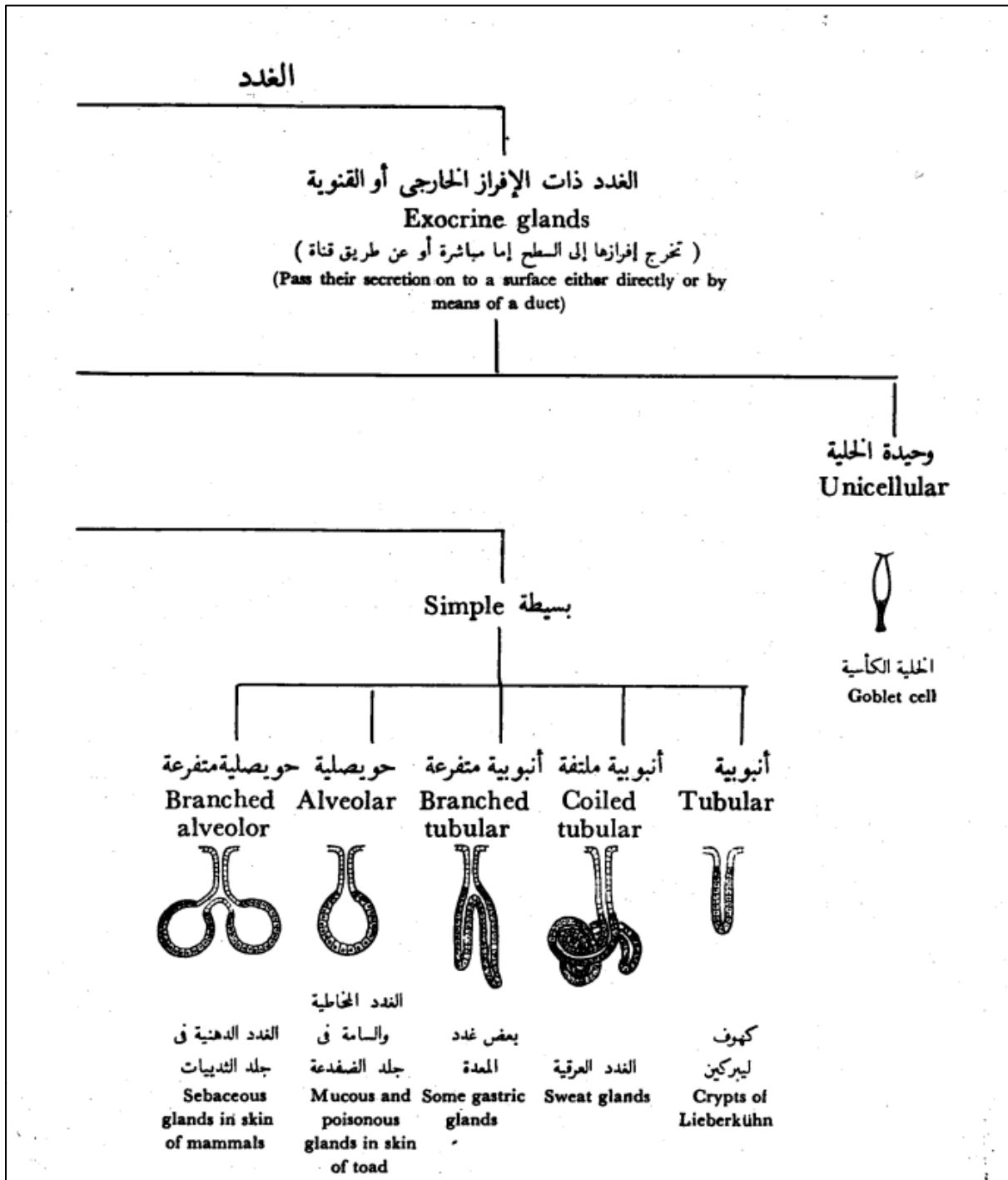
4. Transitional epithelium

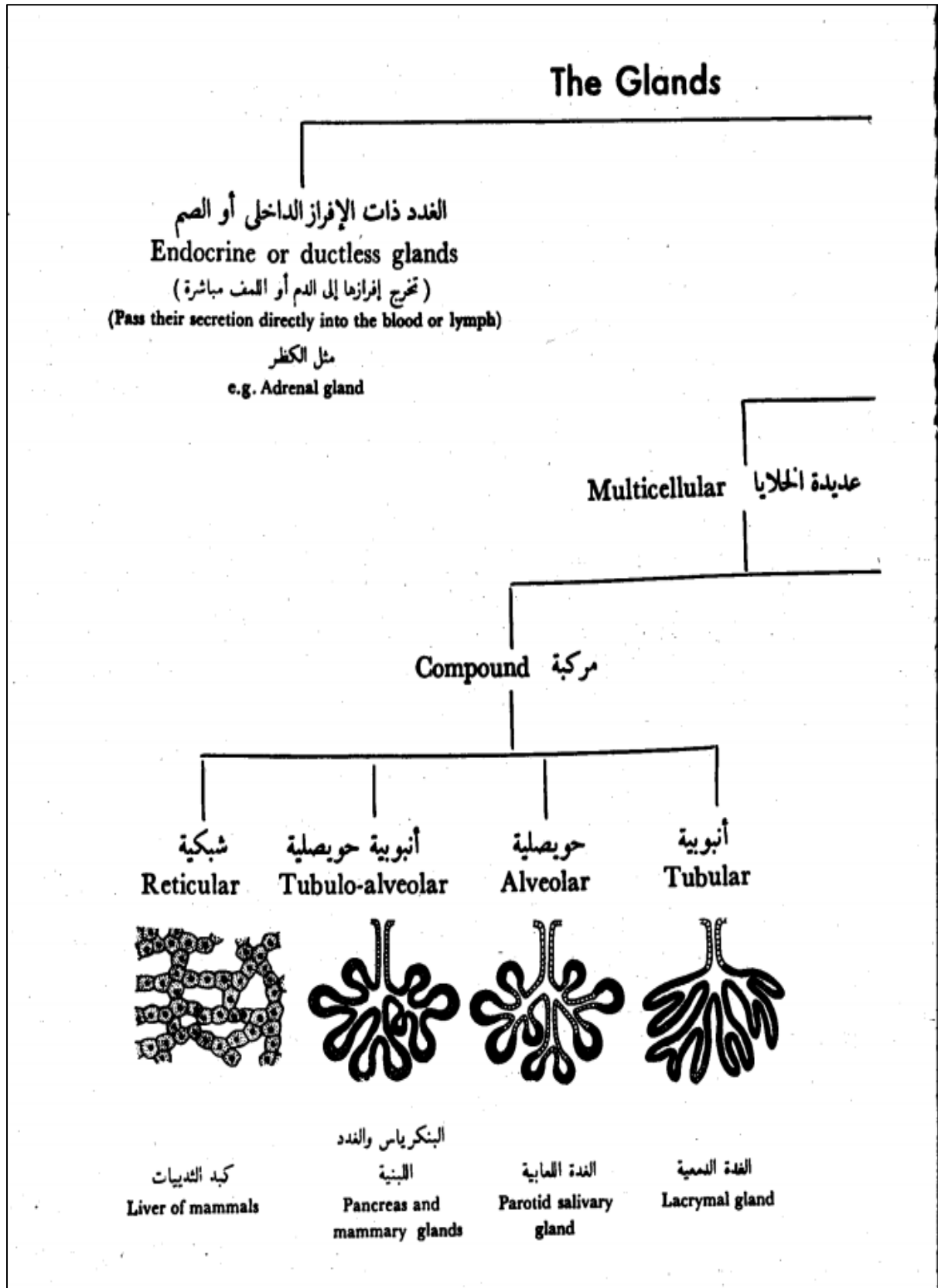


Draw



Glandular epithelium



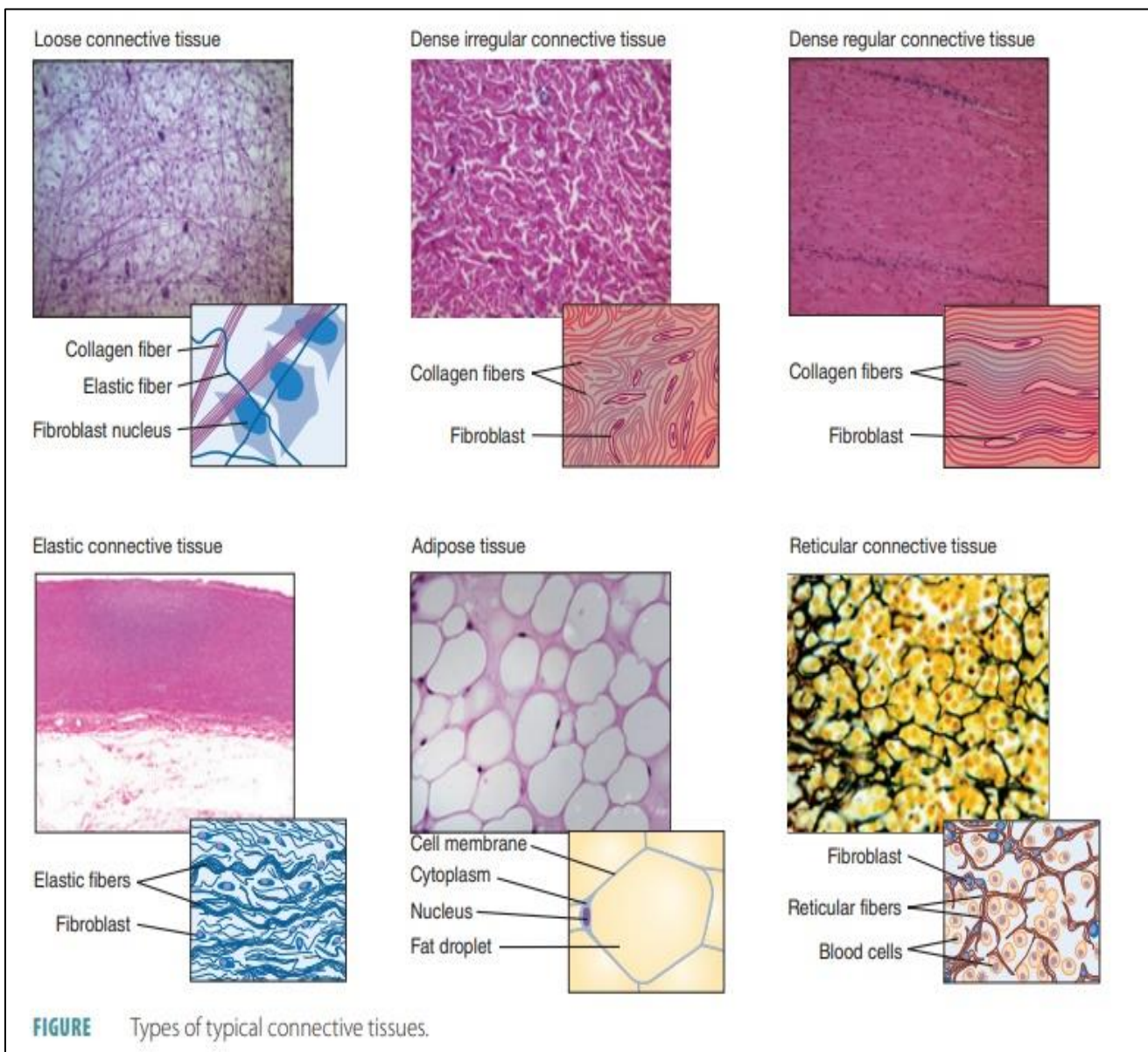


2. Connective Tissue

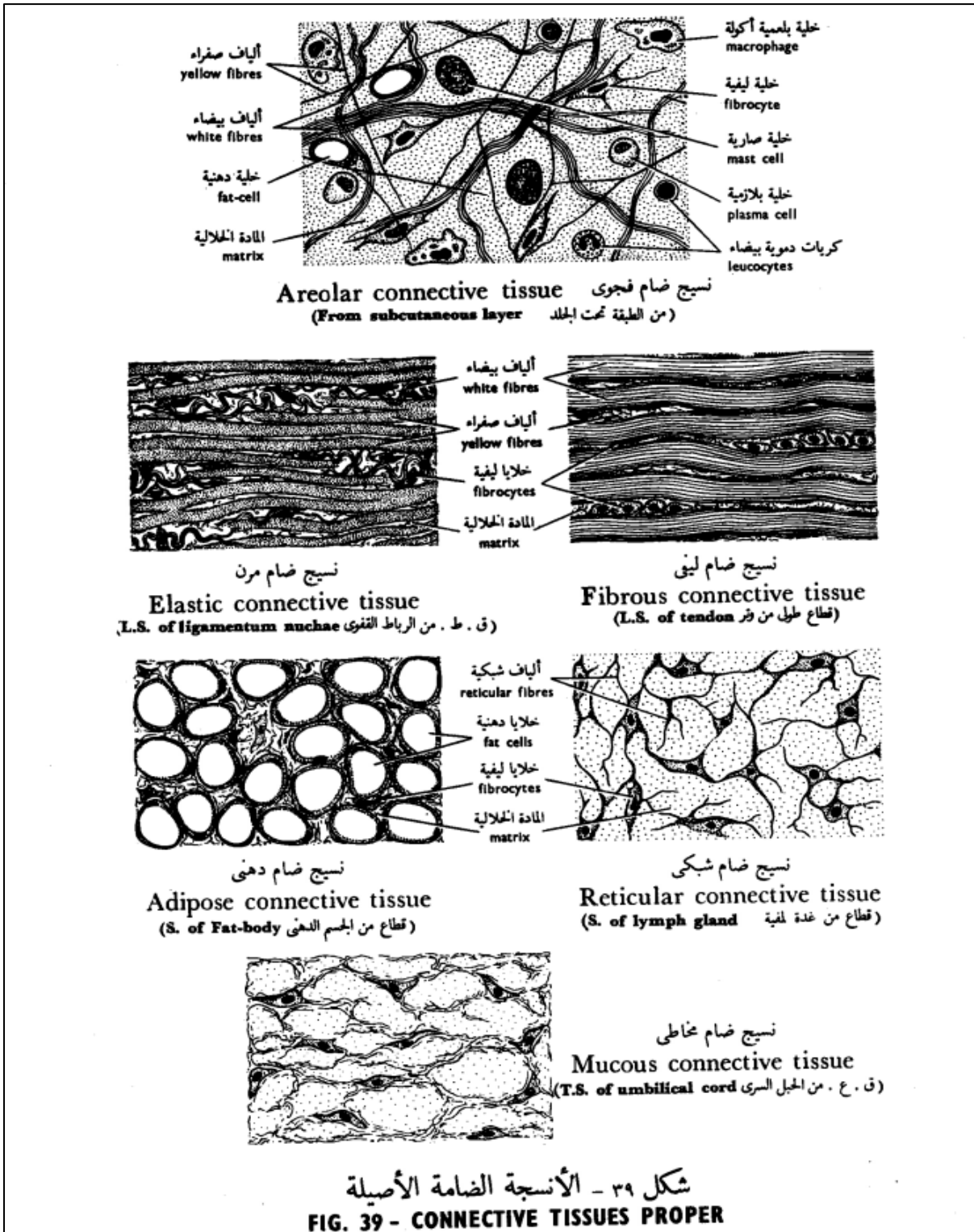
Types of Connective tissue

A-Loose (ordinary or areolar) connective tissue

1. Dense irregular connective tissue
2. Dense regular connective tissue
3. Dense regular elastic (Elastic ligaments)
4. Reticular connective tissue
5. Adipose tissue



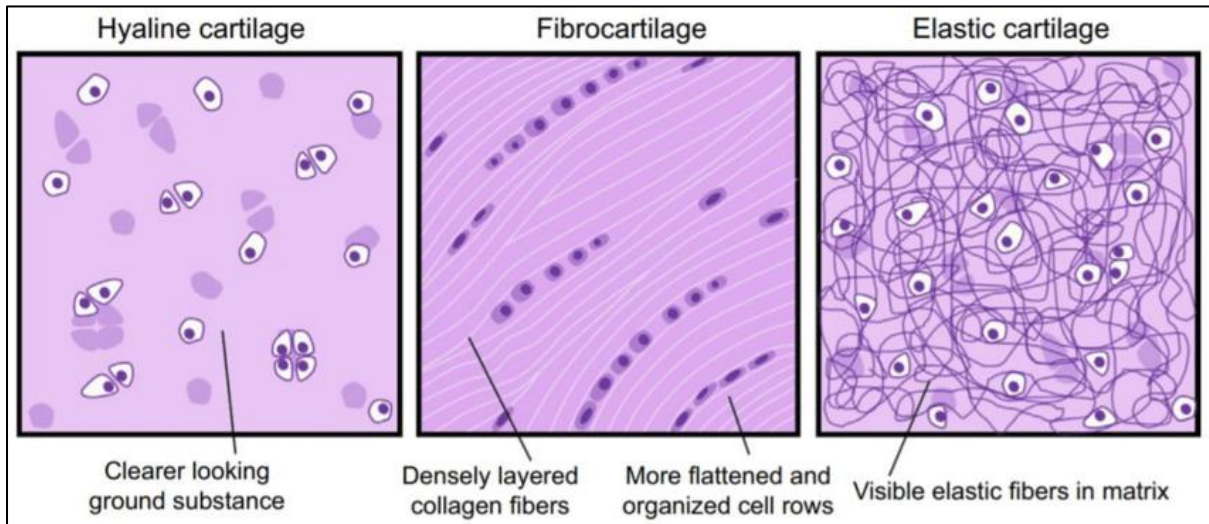
Draw



B-Skeletal Connective tissue (Cartilage& Bone)

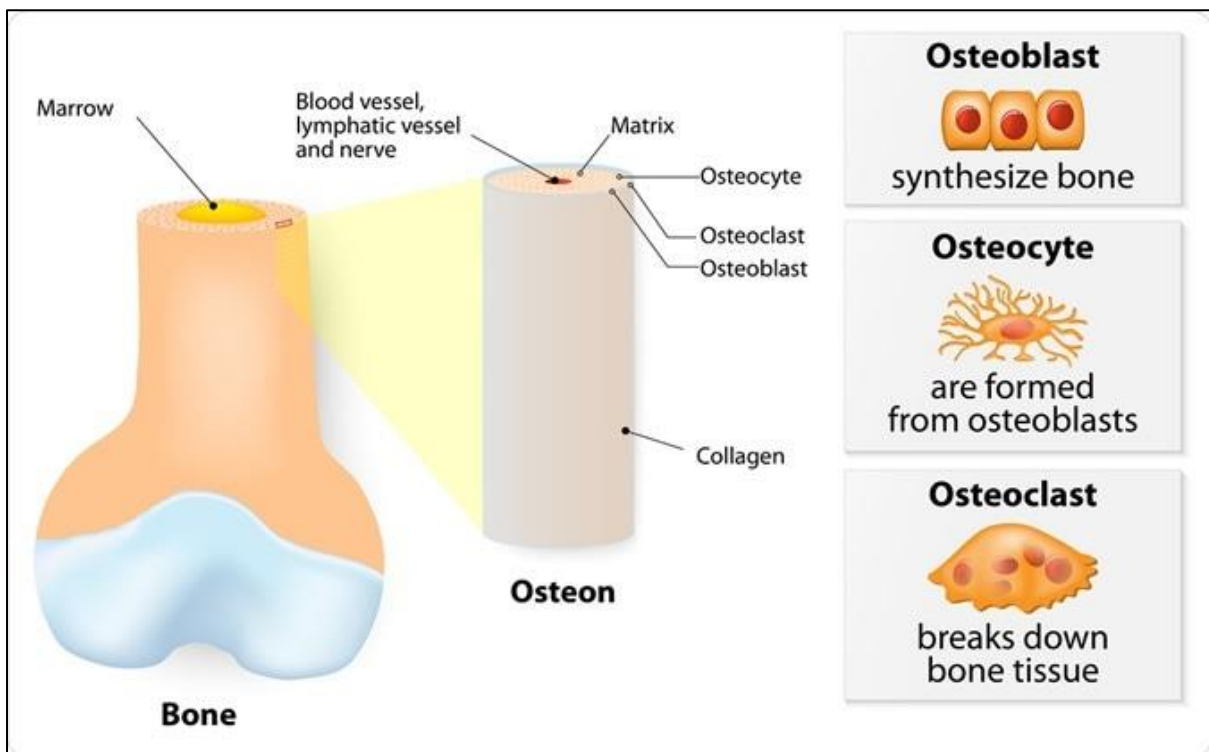
1- Cartilage

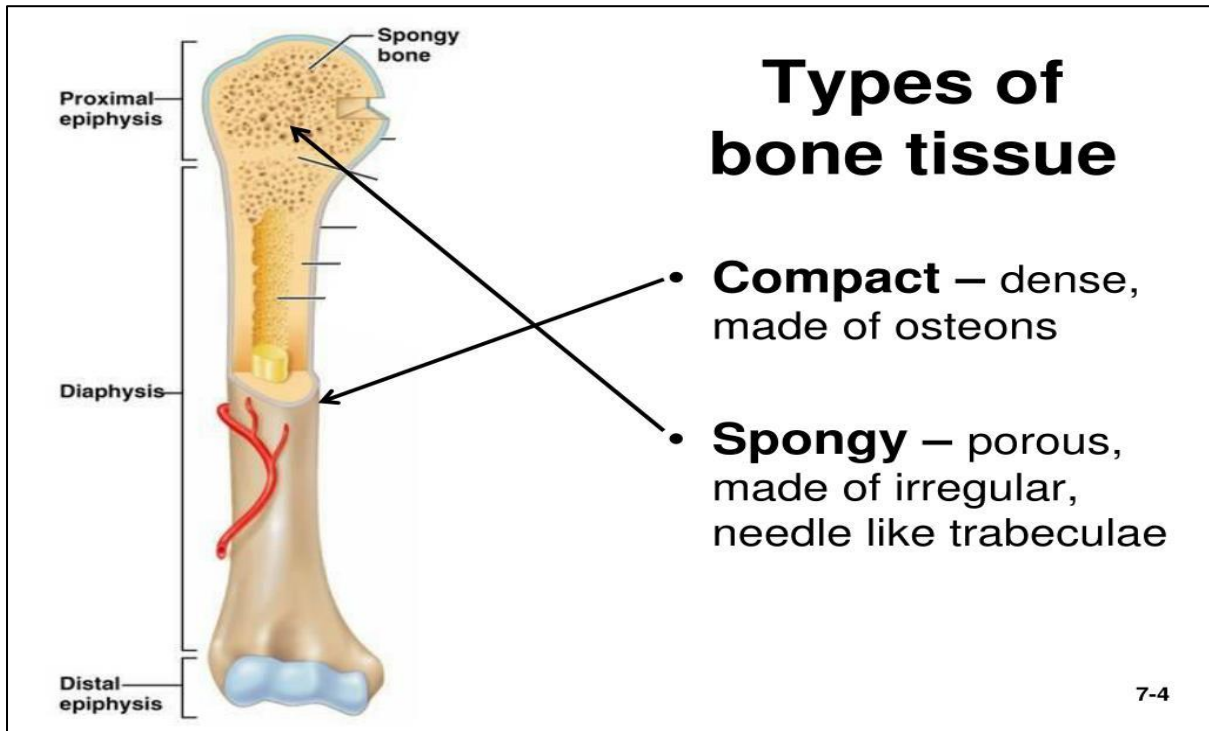
- ✓ Hyaline cartilage
- ✓ Elastic cartilage
- ✓ Fibrocartilage



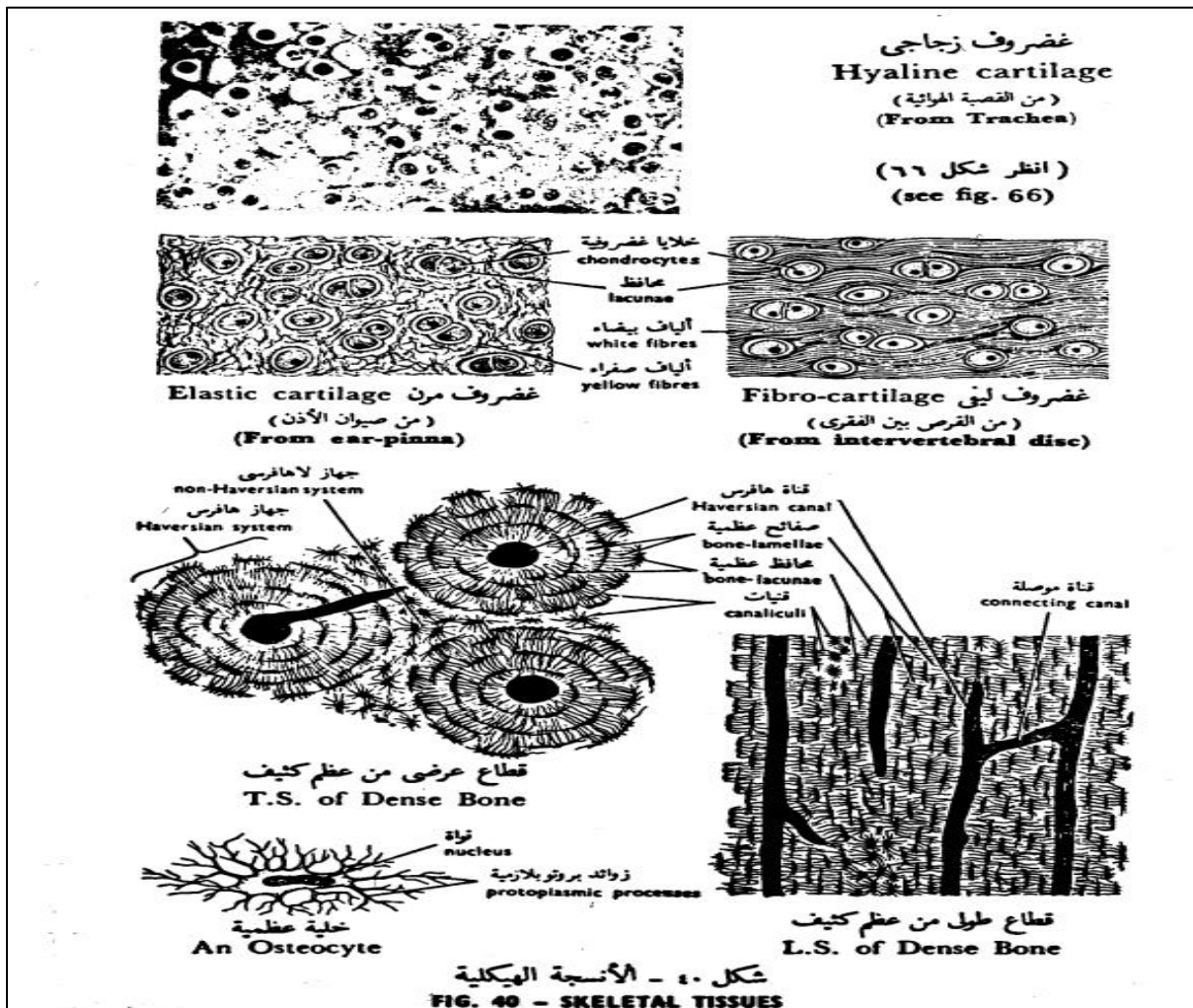
2- Bone

- ✓ Compact bone
- ✓ Cancellous or spongy bone



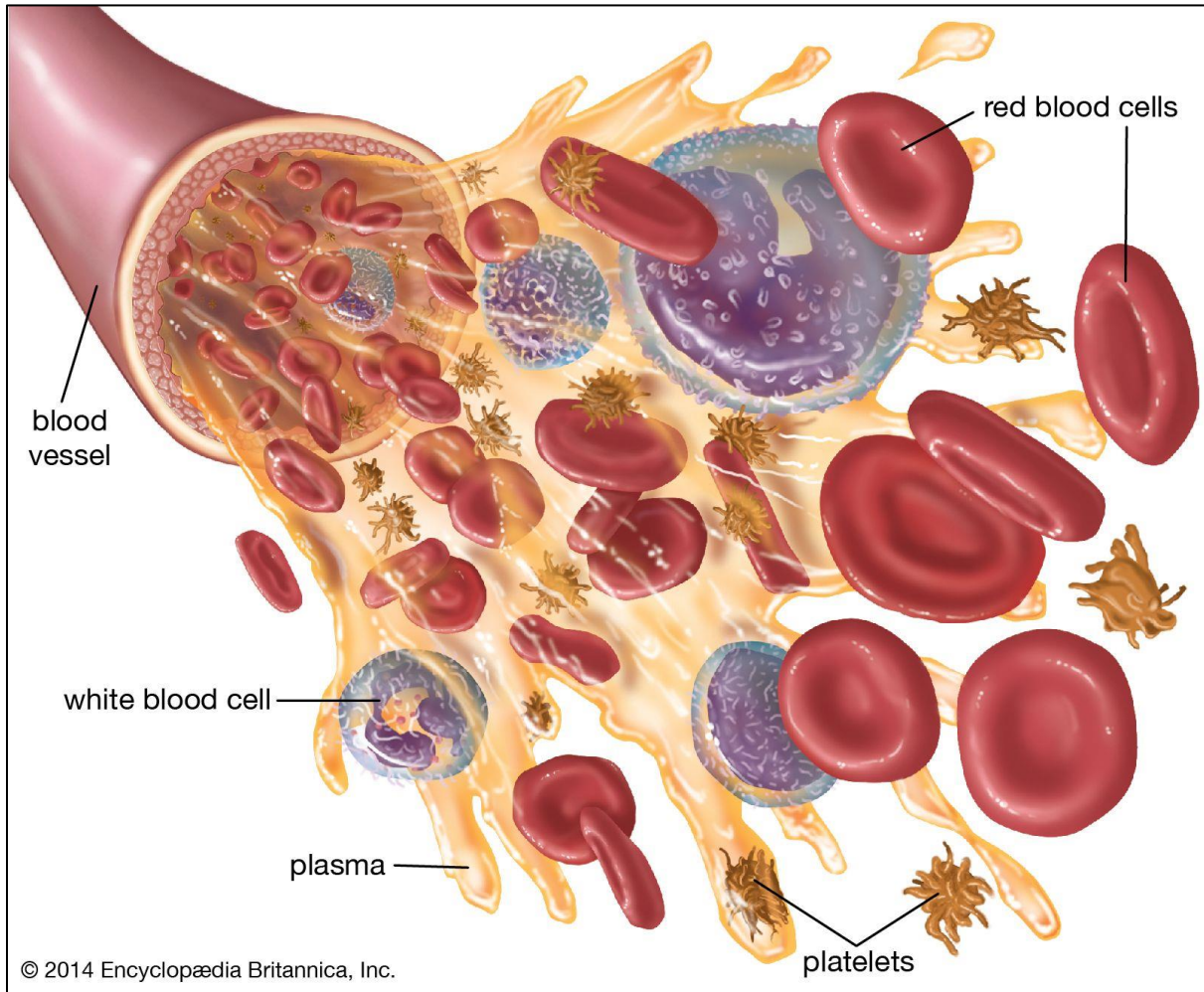


Draw

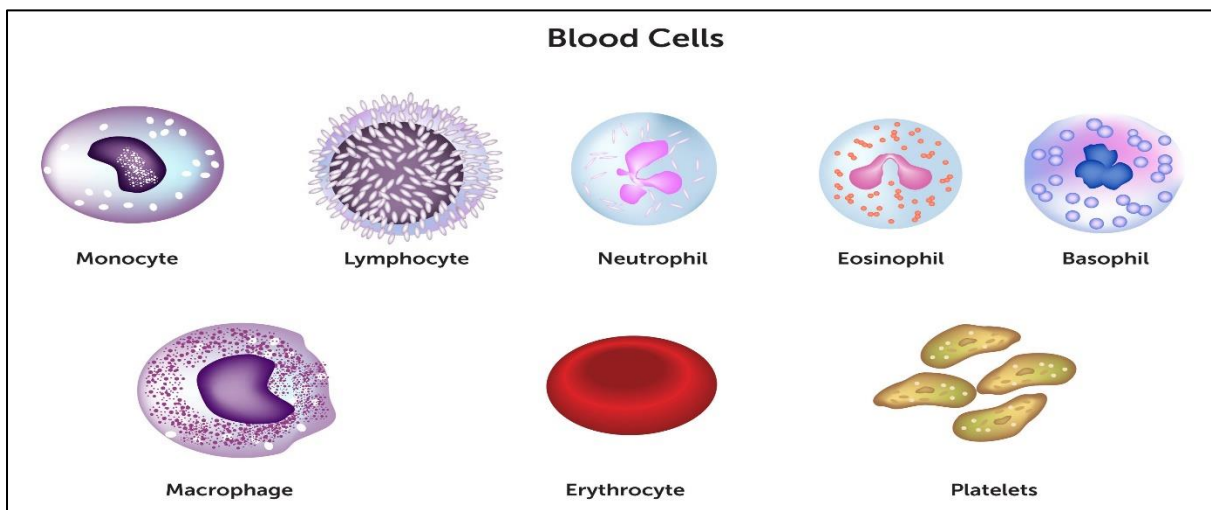


C-Vascular connective tissue (Blood& Lymph)

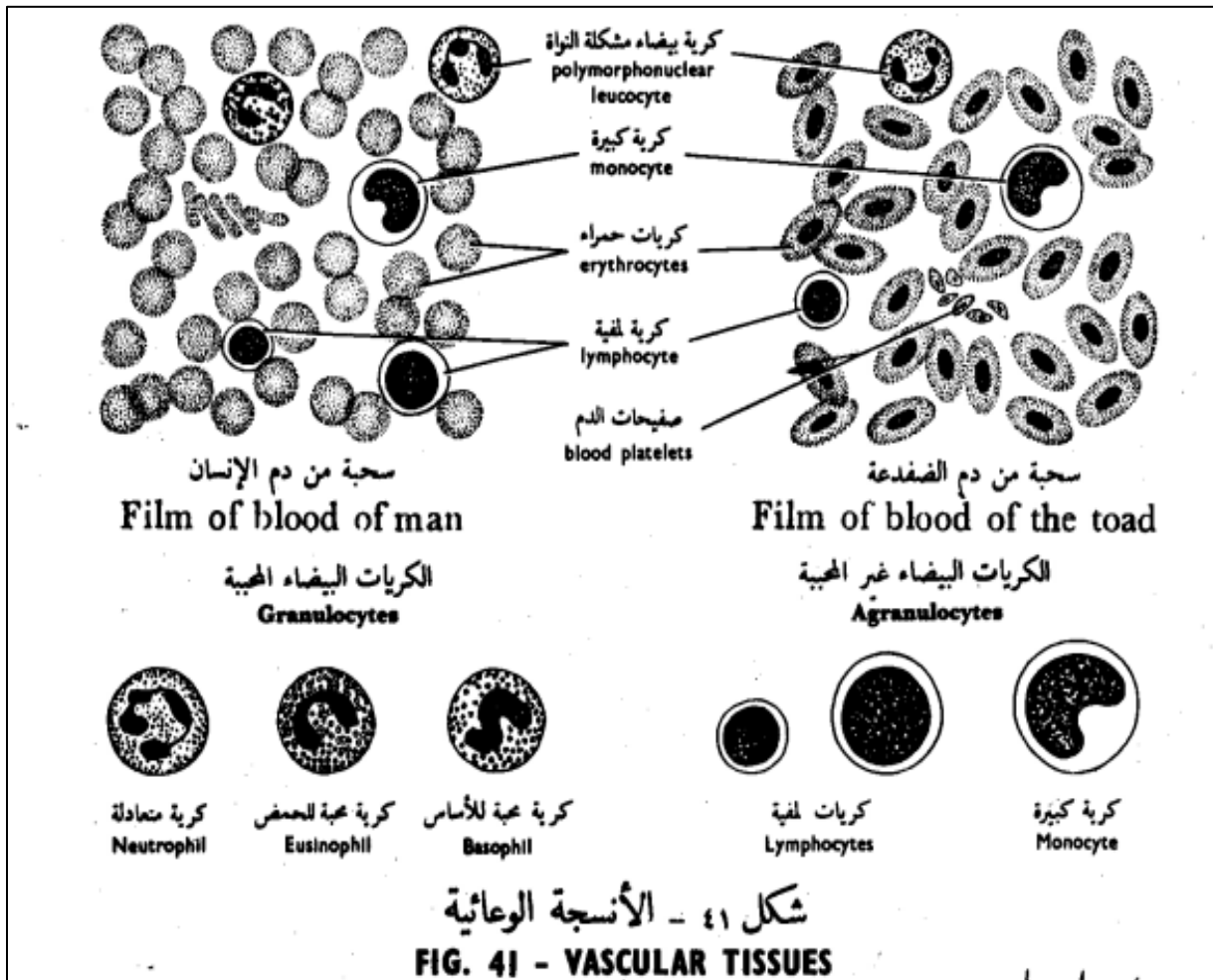
Blood



The blood cells are grouped into three main categories: red blood cells (erythrocytes), white blood cells (leukocytes) and blood platelets (thrombocytes).



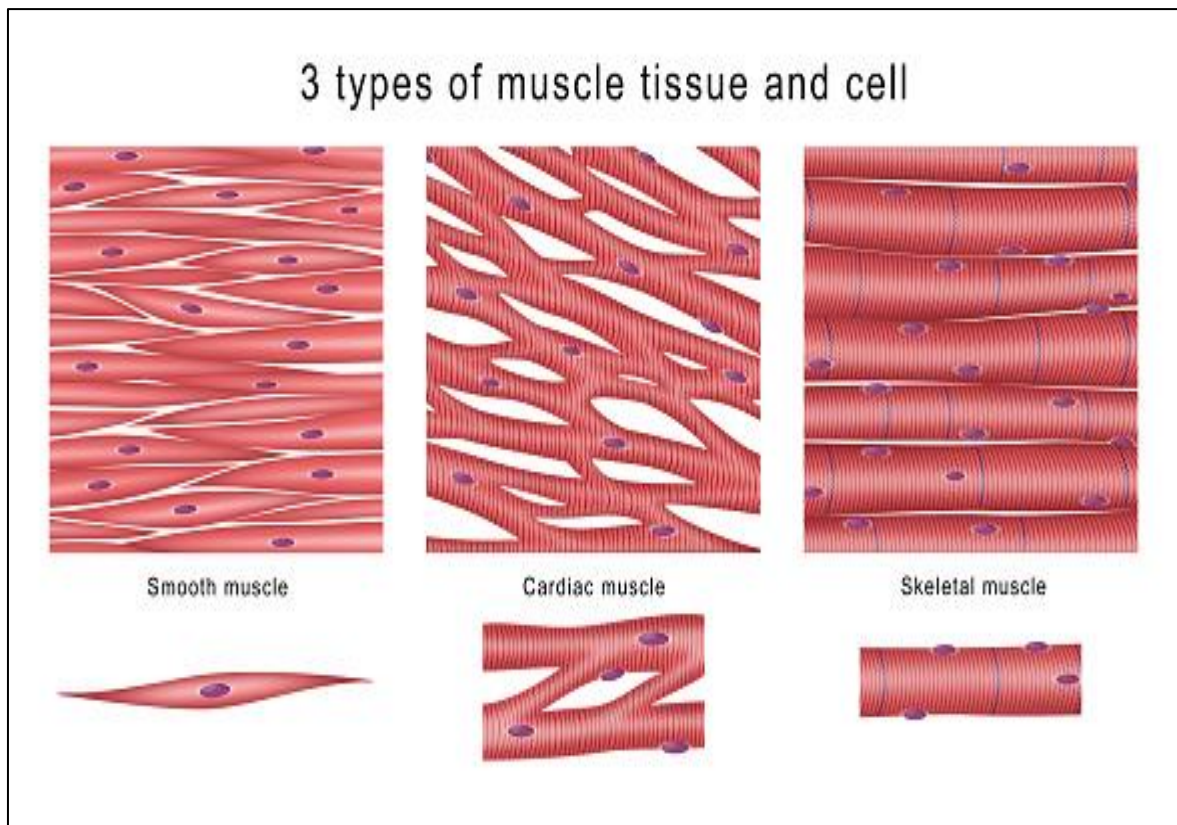
Draw



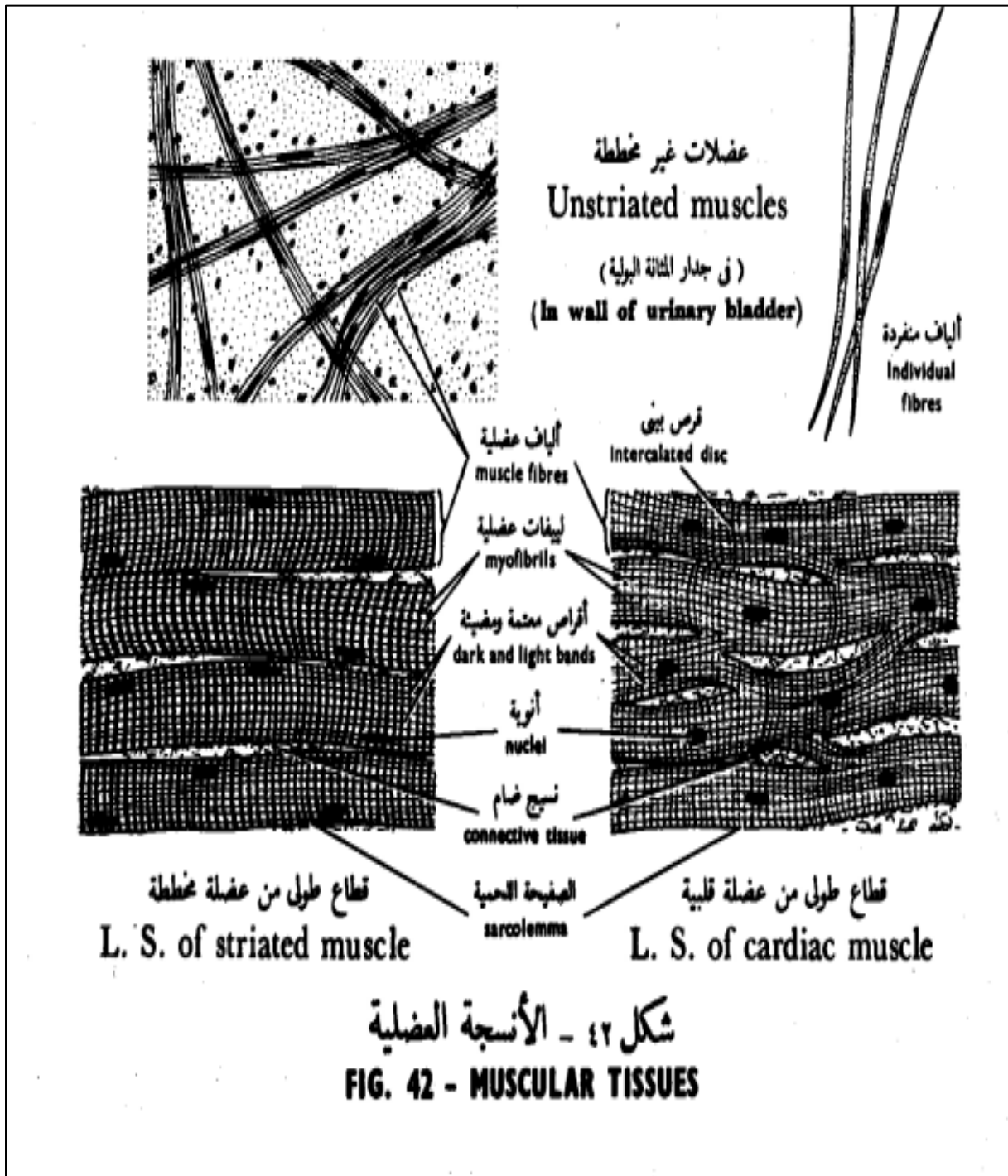
3- Muscular tissue

It is one of the four basic types of tissues primarily responsible for locomotion and movement of the various body parts.

- ✓ Skeletal muscle (Striated and voluntary myofibers)
- ✓ Cardiac muscle (Striated and involuntary)
- ✓ Smooth muscle (Visceral muscle)



Draw

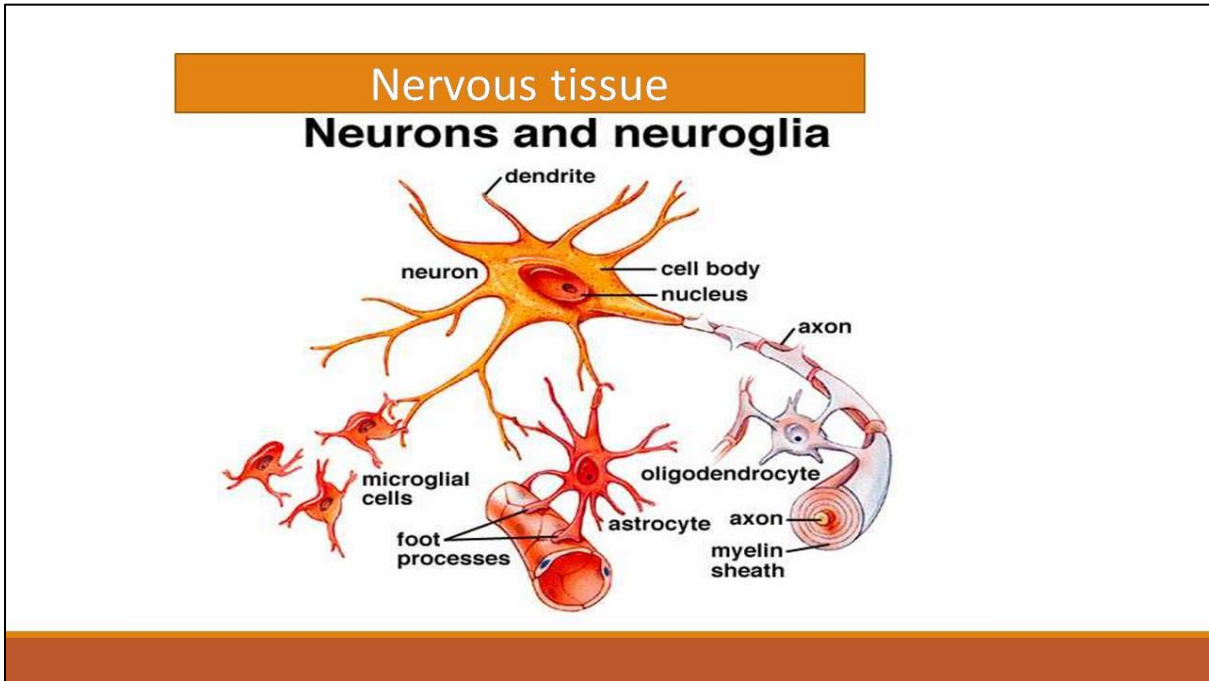


4- Nervous tissue

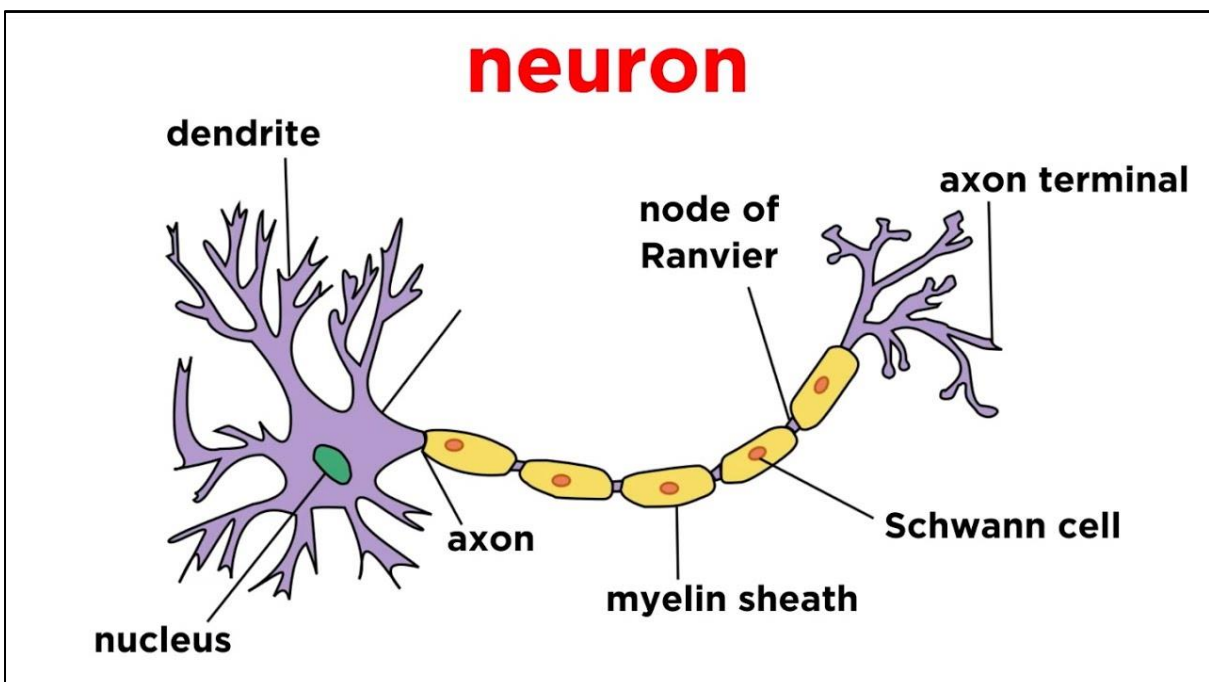
It is one of the four primary basic tissues.

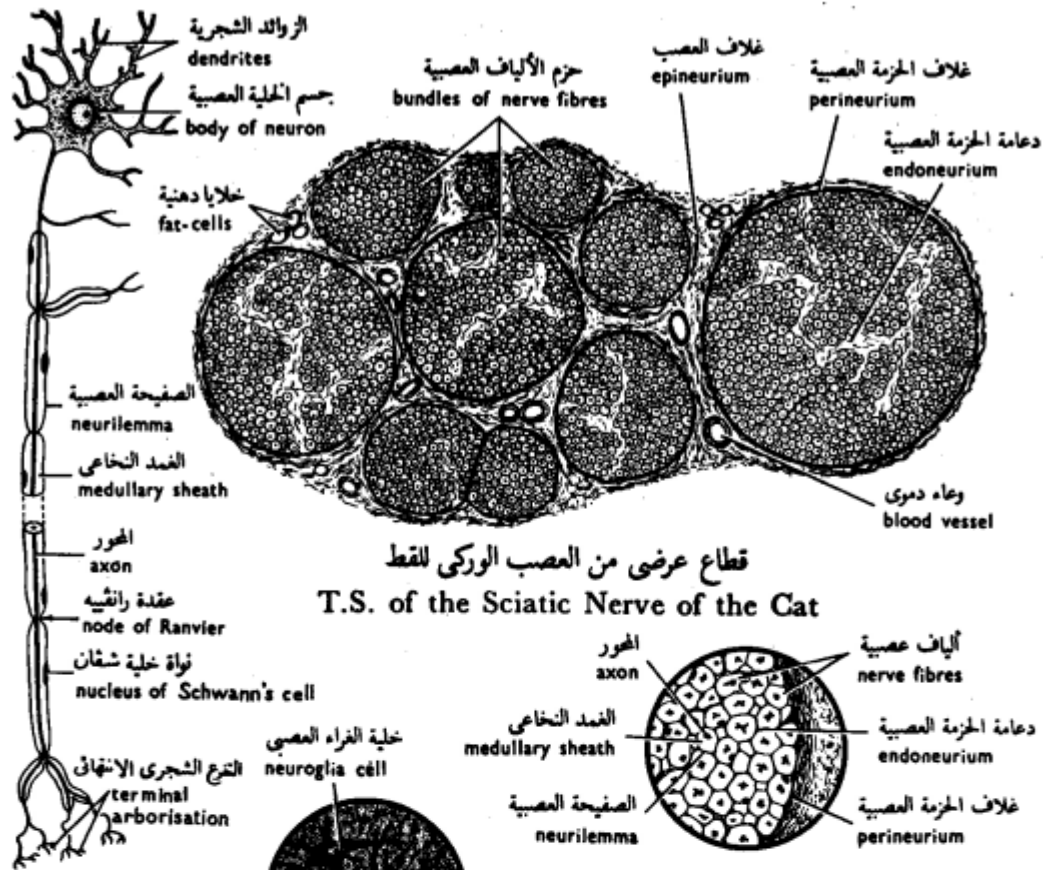
It consists of two types of cells:

- ✓ Neurons (nerve cells)
- ✓ Neuroglia (supporting cells).



Draw



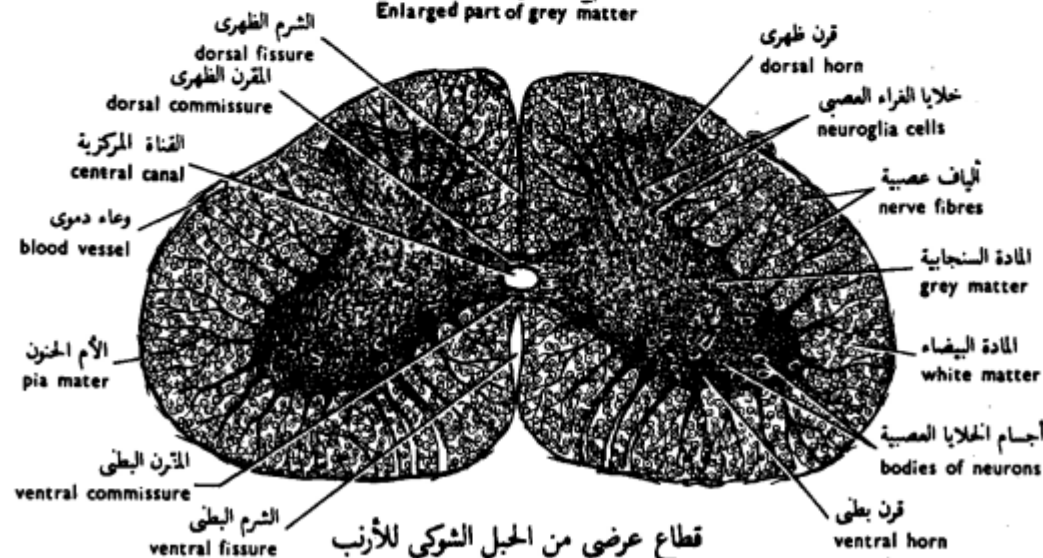


قطاع عرضي من العصب الوركي للقط
T.S. of the Sciatic Nerve of the Cat

خلية عصبية حركية
Motor Neuron

جزء مكبر من حزمة الألياف العصبية
Enlarged part of nerve bundle

جزء مكبر من المادة السنجابية
Enlarged part of grey matter



قطاع عرضي من الحبل الشوكي للارنب
T.S. of the Spinal Cord of the Rabbit

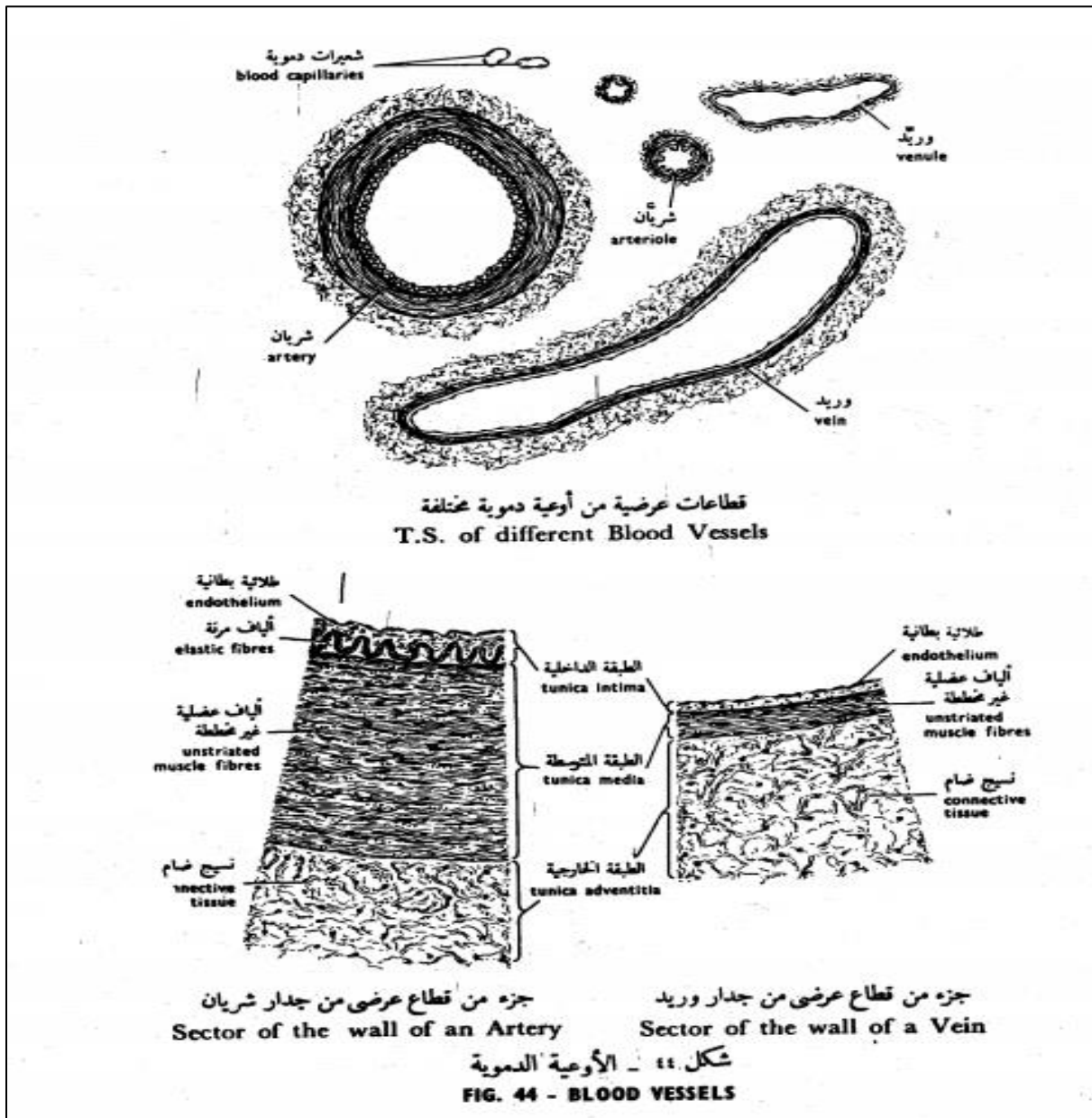
شكل ٤٣ - الأنسجة العصبية

FIG. 43 - NERVOUS TISSUES

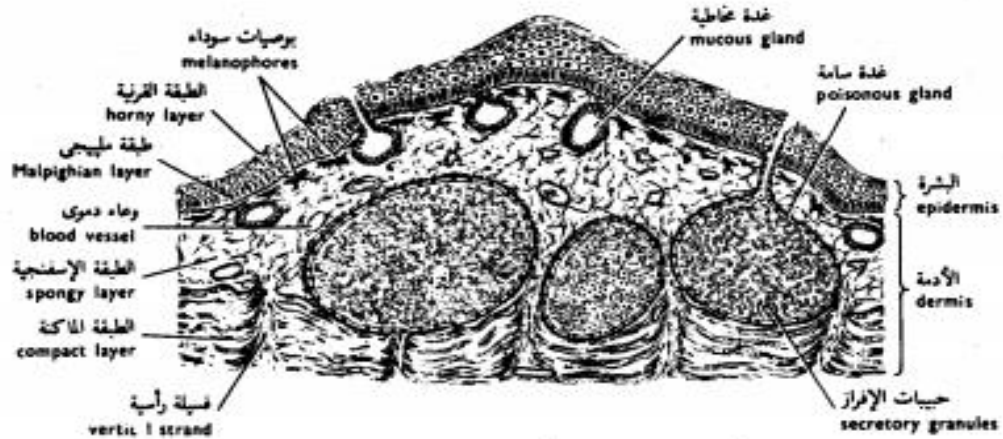
The Organs

Write the types of tissues in the following organs?

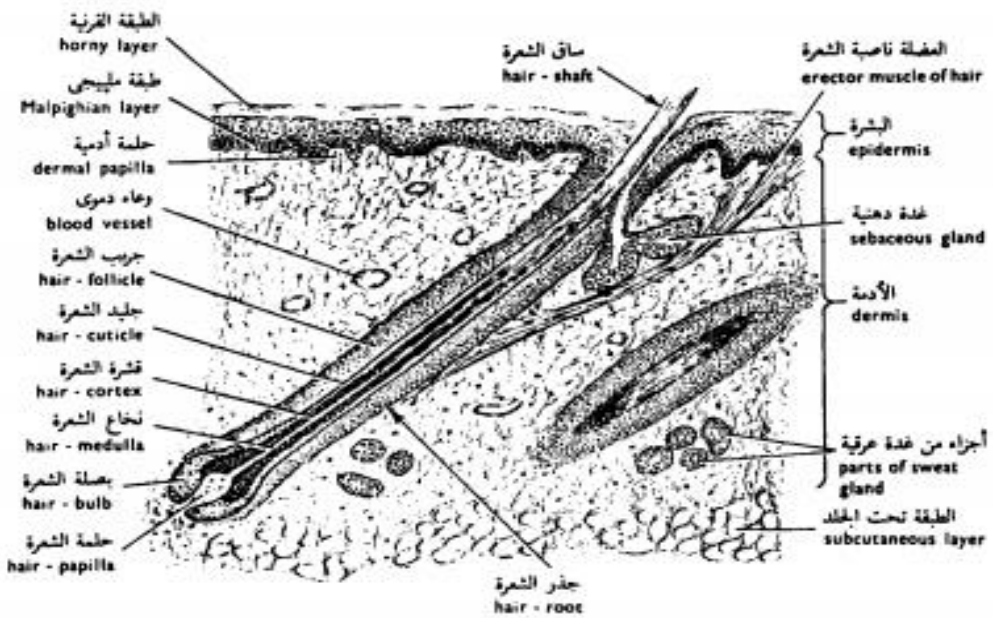
Blood vessels



Skin

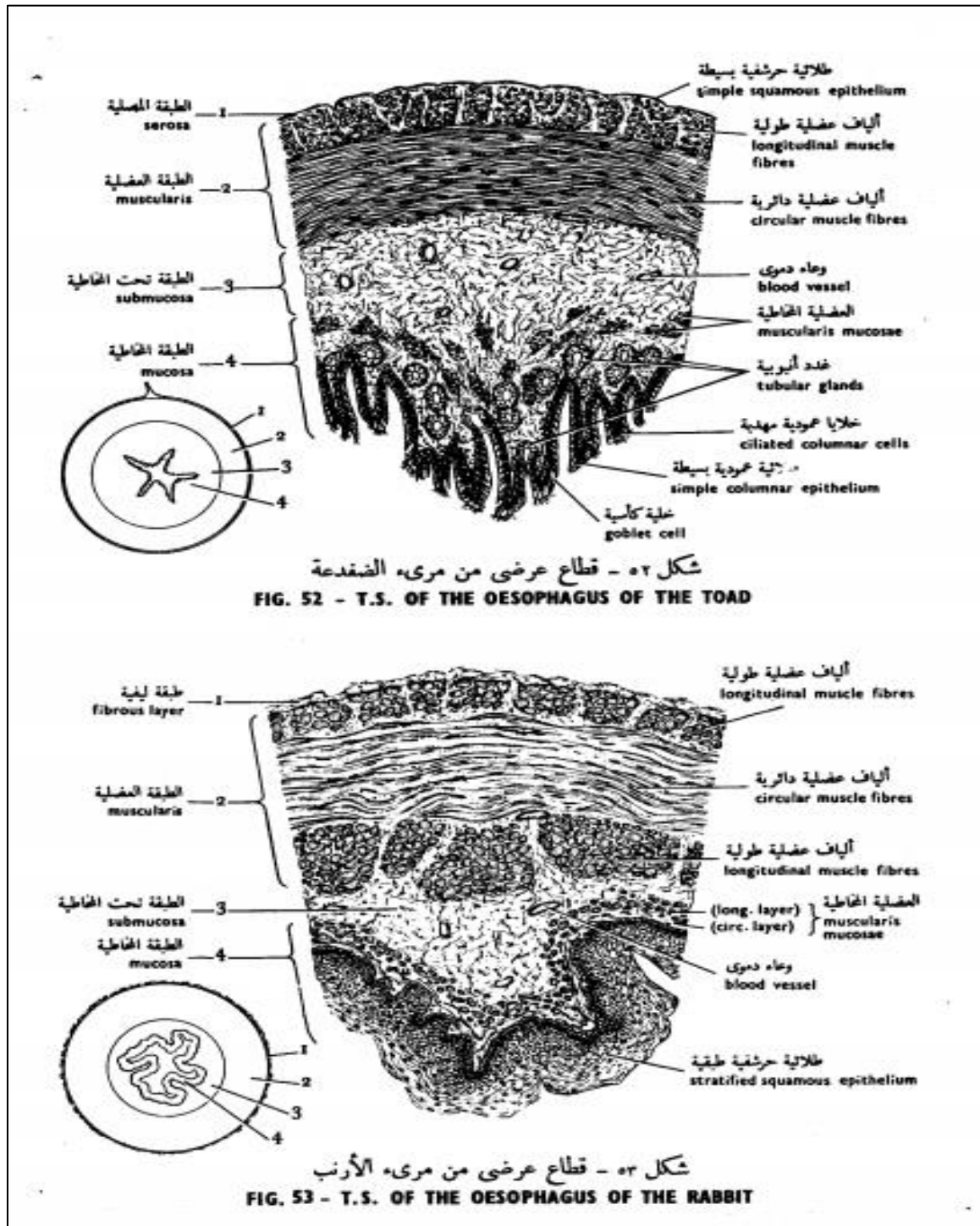


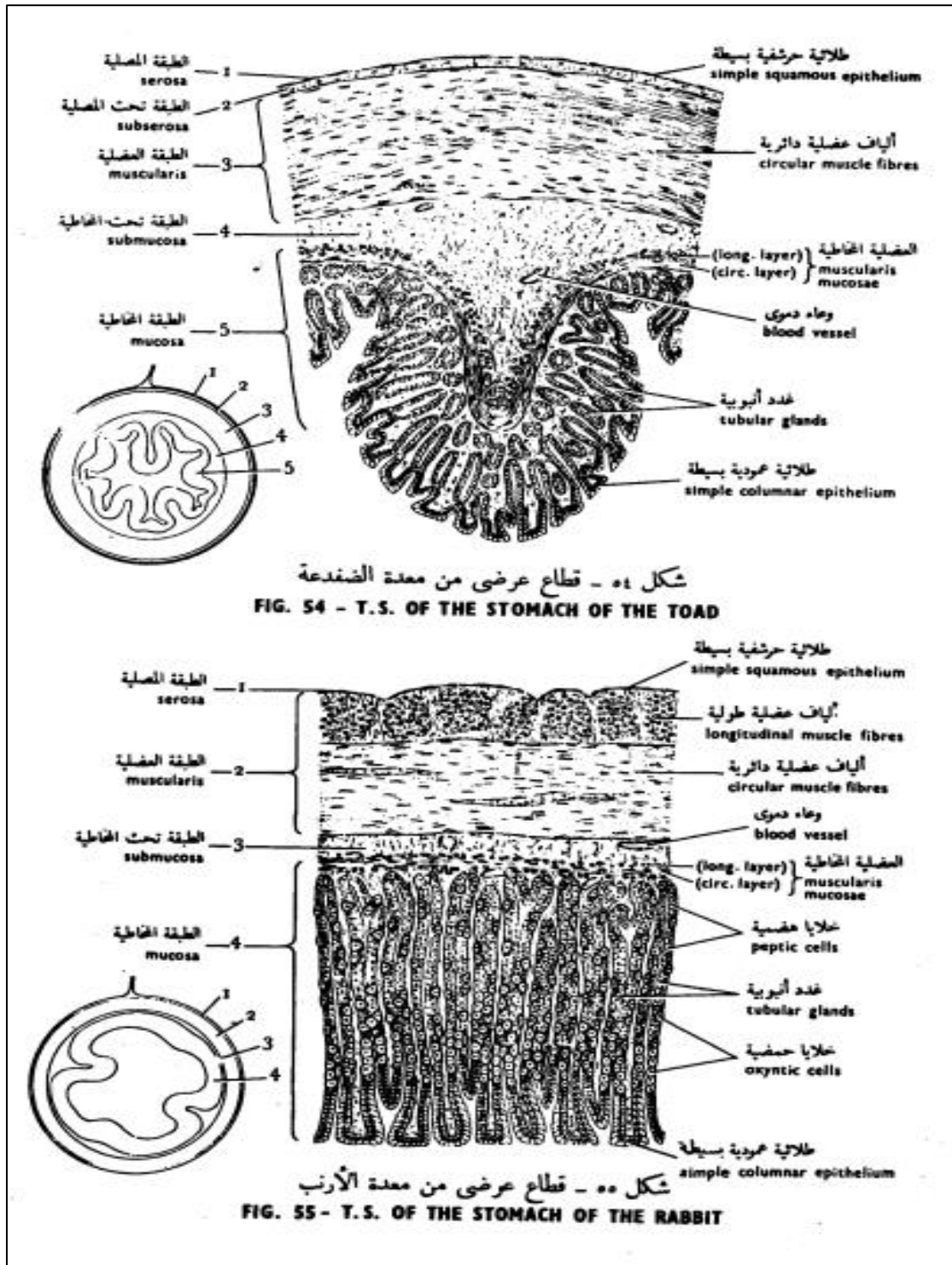
شكل ٤٥ - قطاع رأسي من جلد الضفدعة
 FIG. 45 - V.S. OF THE SKIN OF THE TOAD

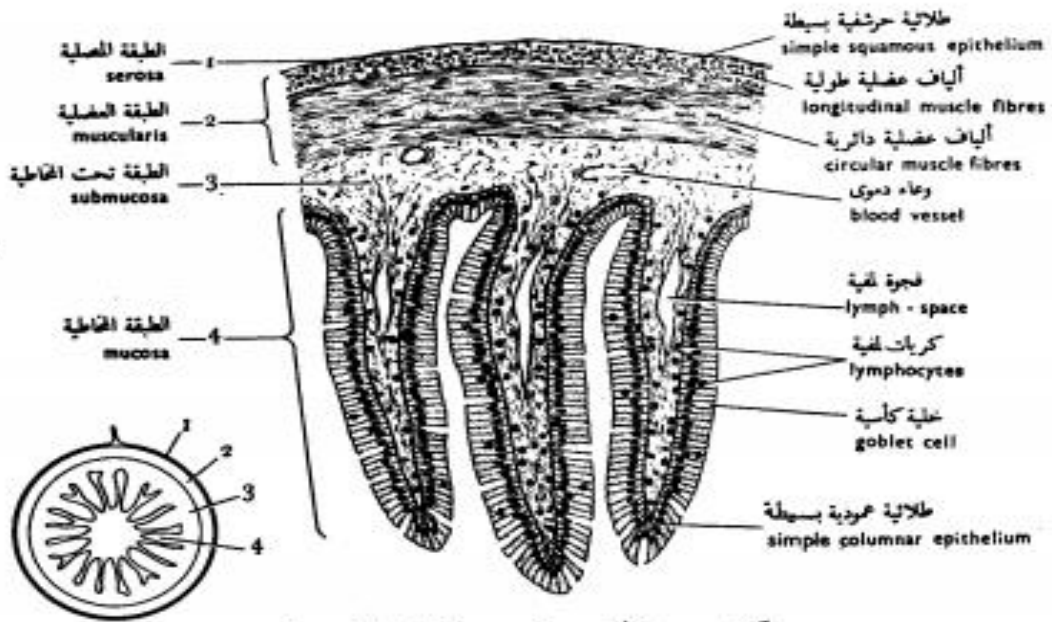


شكل ٤٦ - قطاع رأسي من جلد الخنزير
 FIG. 46 - V.S. OF THE SKIN OF THE PIG

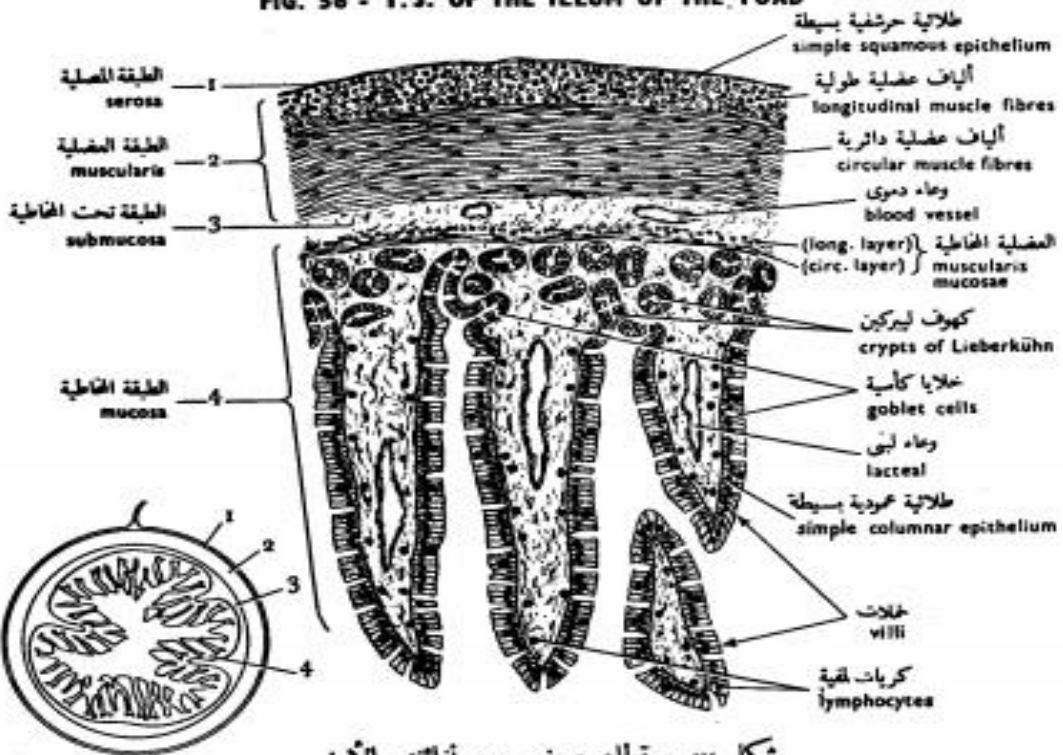
Digestive tract







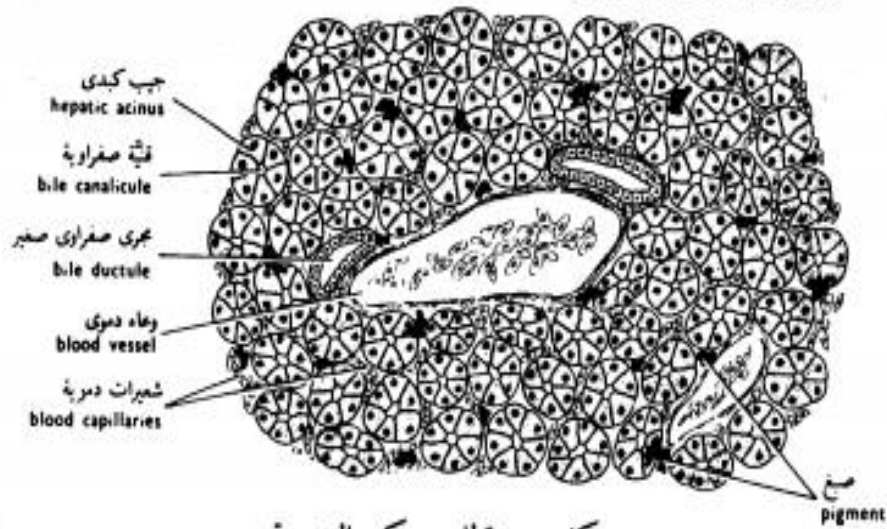
شكل ٥٦ - قطاع عرضي من لفائف الضفدعة
 FIG. 56 - T.S. OF THE ILEUM OF THE TOAD



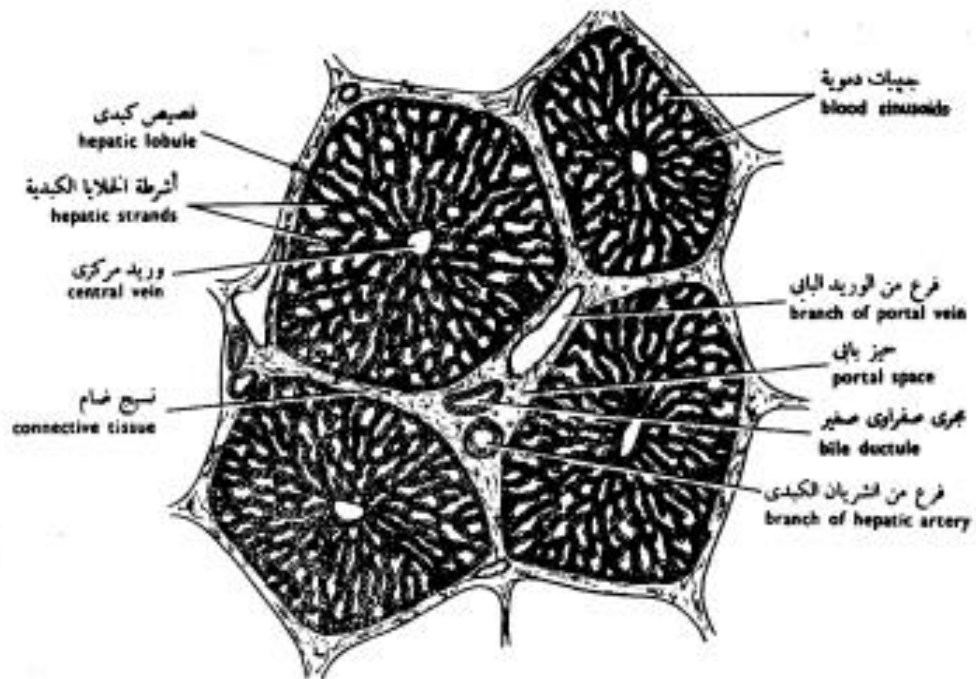
شكل ٥٧ - قطاع عرضي من لفائف الأرنب
 FIG. 57 - T.S. OF THE ILEUM OF THE RABBIT

Liver

of the Toad's Liver



شكل ٥٩ - قطاع من كبد الضفدعة
 FIG. 59 - S. OF THE LIVER OF OF THE TOAD

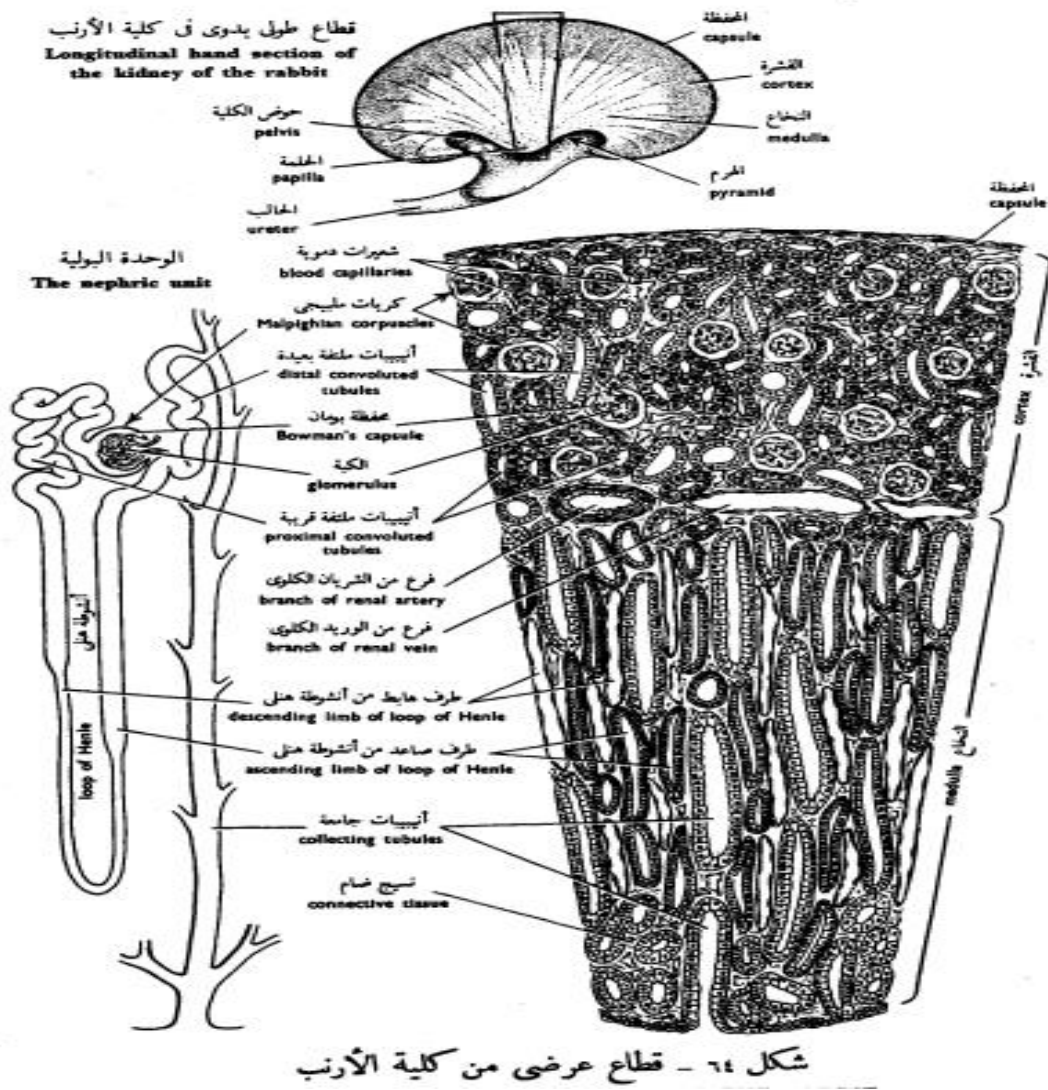


شكل ٦٠ - قطاع من كبد الخنزير
 FIG. 60 - S. OF THE LIVER OF THE PIG

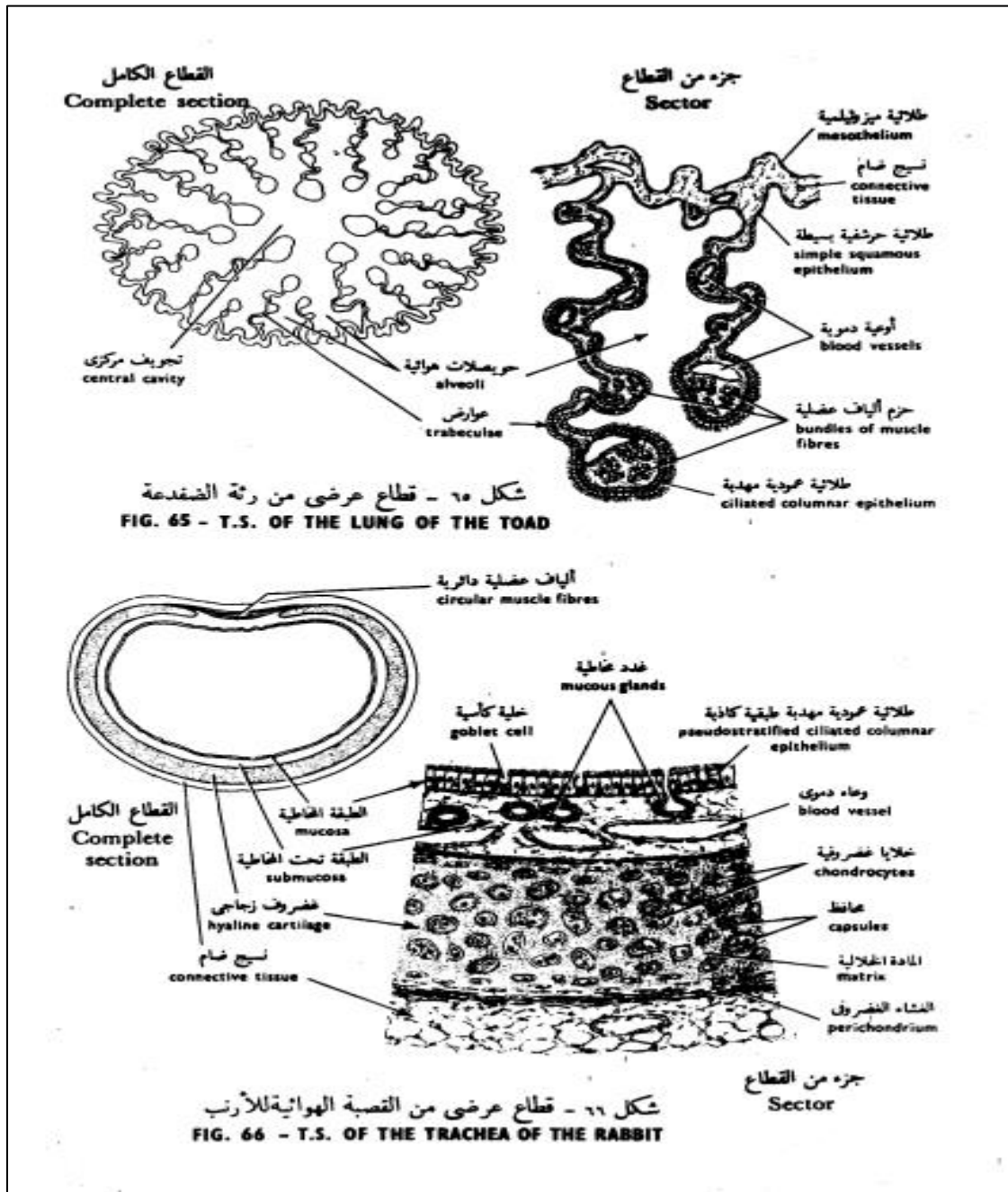
Kidney

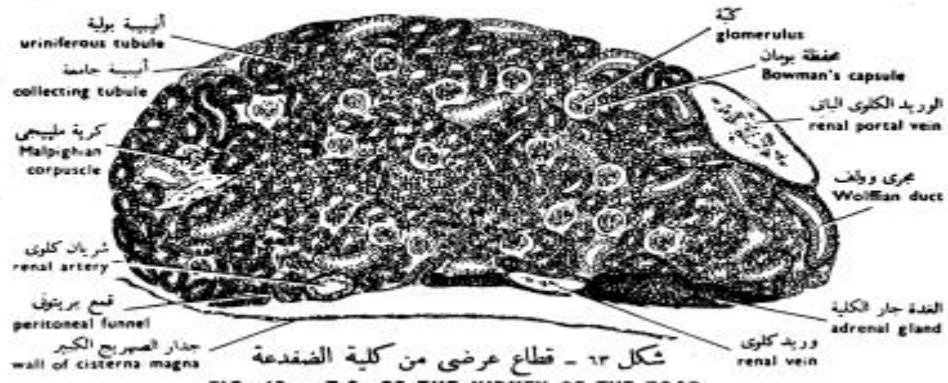

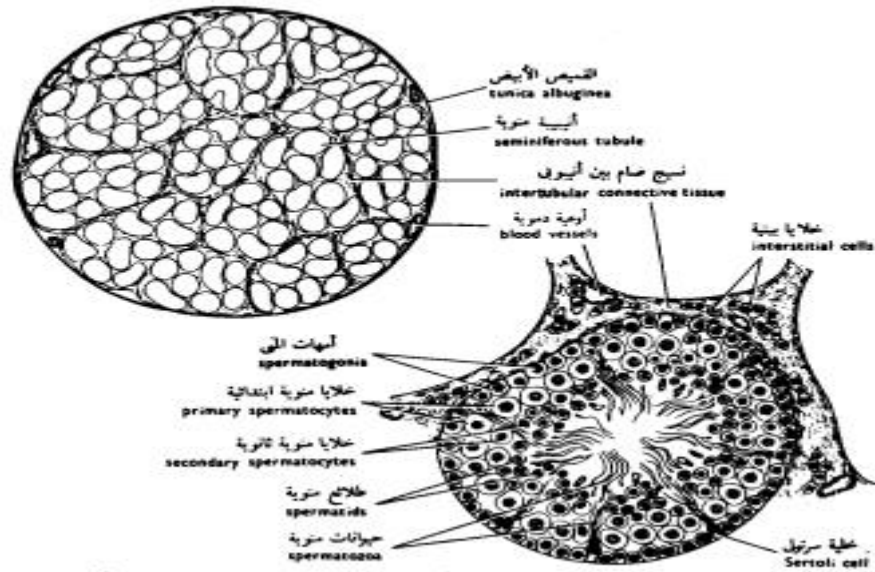
FIG. 63 - T.S. OF THE KIDNEY OF THE TOAD



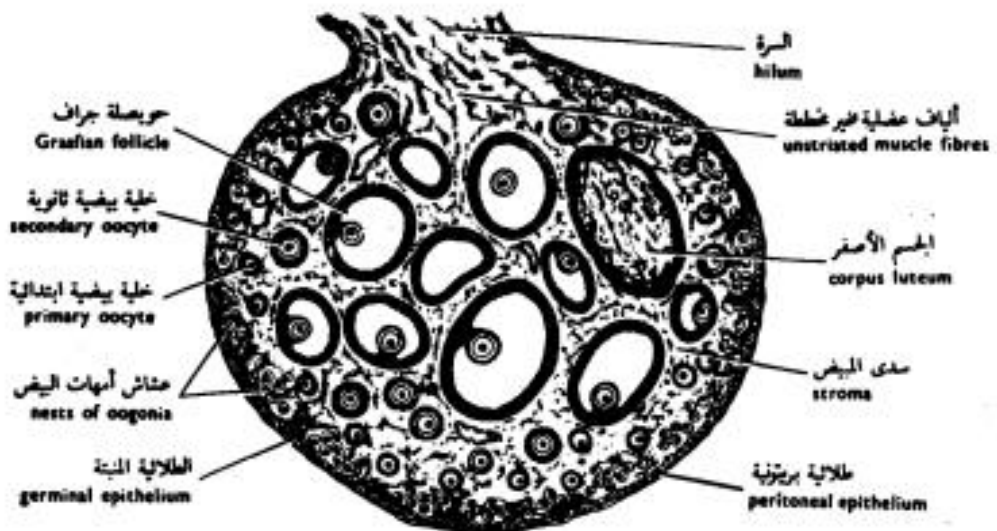
Lung



Testis and Ovary



شكل ٦٧ - قطاع عرضي من خصية الفأر
 FIG. 67 - T.S. OF THE TESTIS OF THE RAT



شكل ٧١ - قطاع عرضي من مبيض القطاة
 FIG. 71 - T.S. OF THE OVARY OF THE CAT