



Zoology 8

Comparative anatomy

Practical part

Second term

By

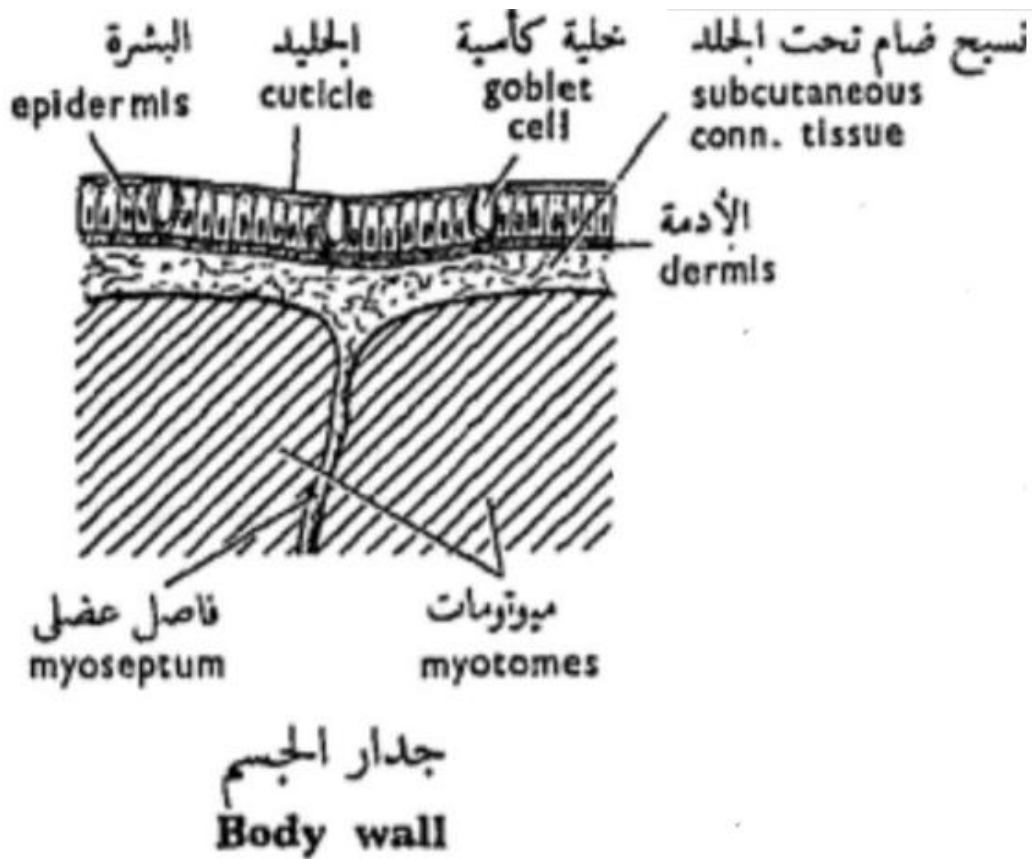
1- Dr: Nermean Moamen Hussein

(Professor of Parasitology, Zoology department)

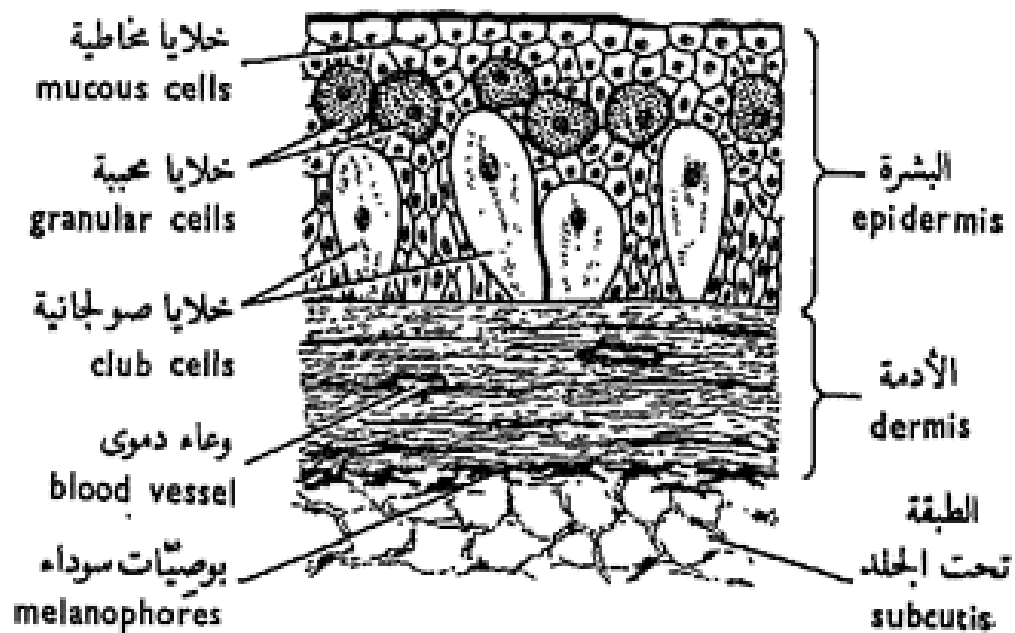
Faculty of Science

2023-2024

The Book data

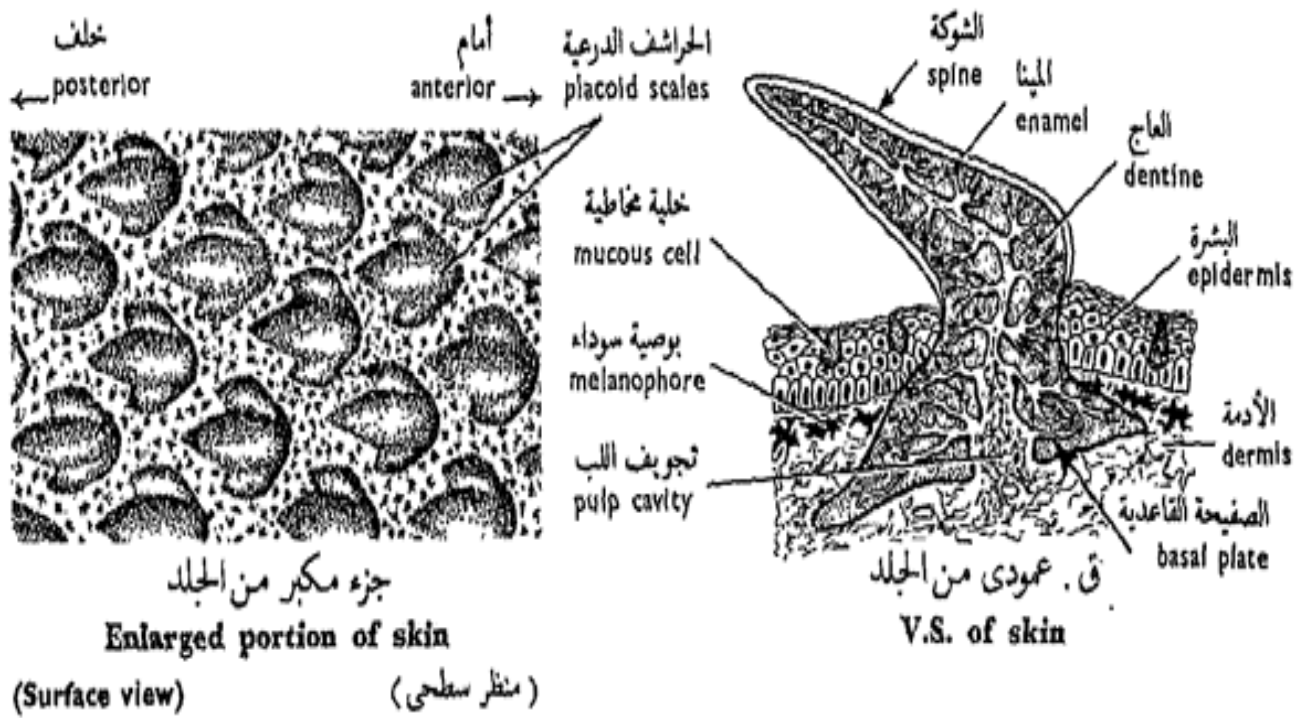


v.s in the of protochordata (*Amphioxus lanceolatus*)

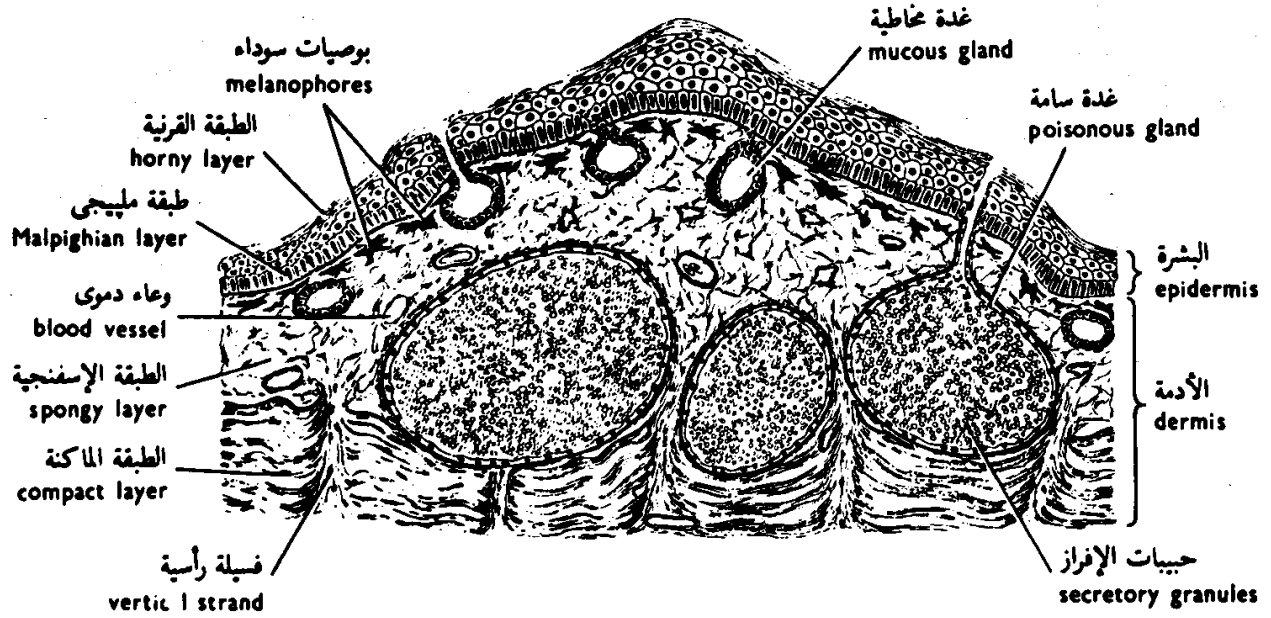


قى . عمودي من الجلد
 V.S. of skin

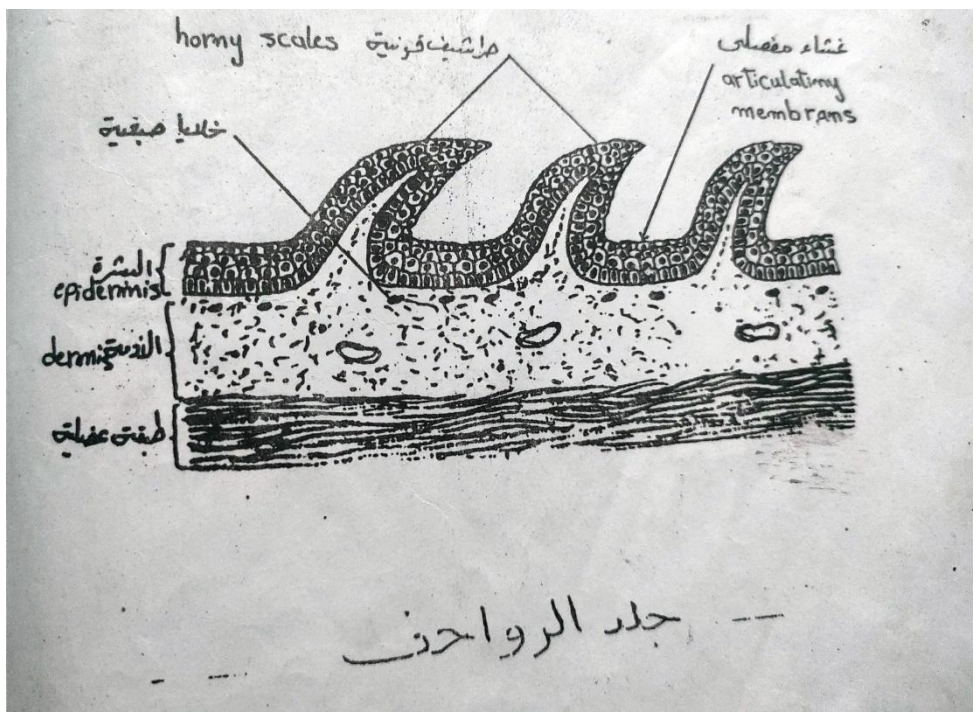
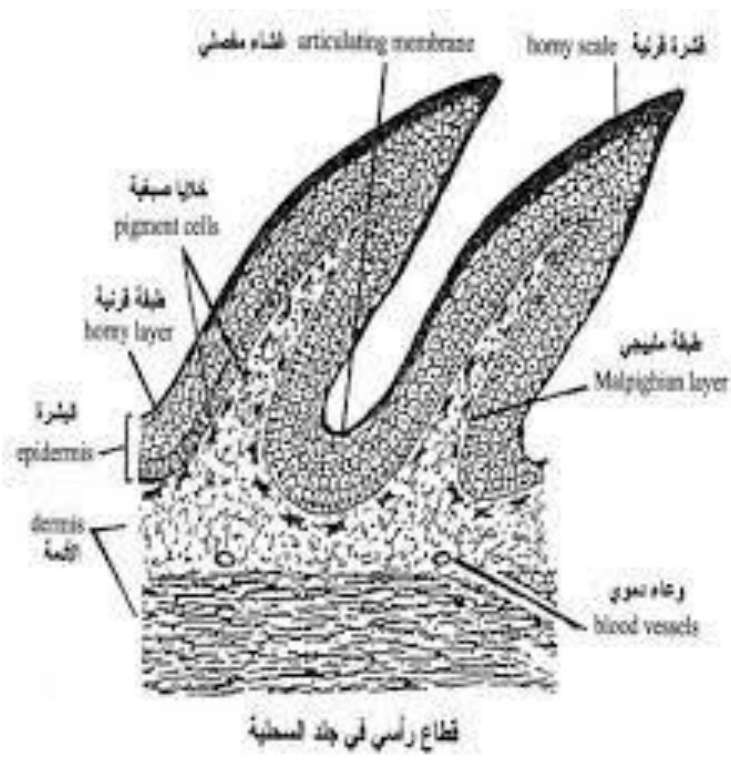
v.s in the skin of cyclostomata (*Petromyzon sp.*)



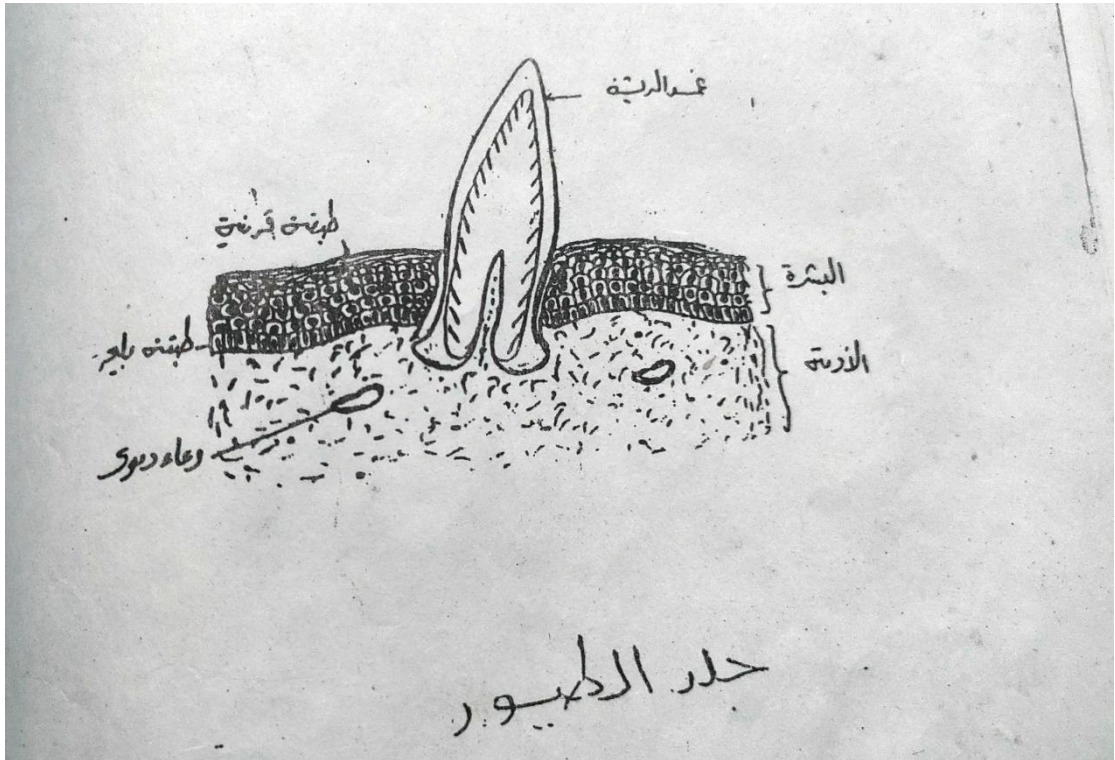
v.s in the skin of dog fish



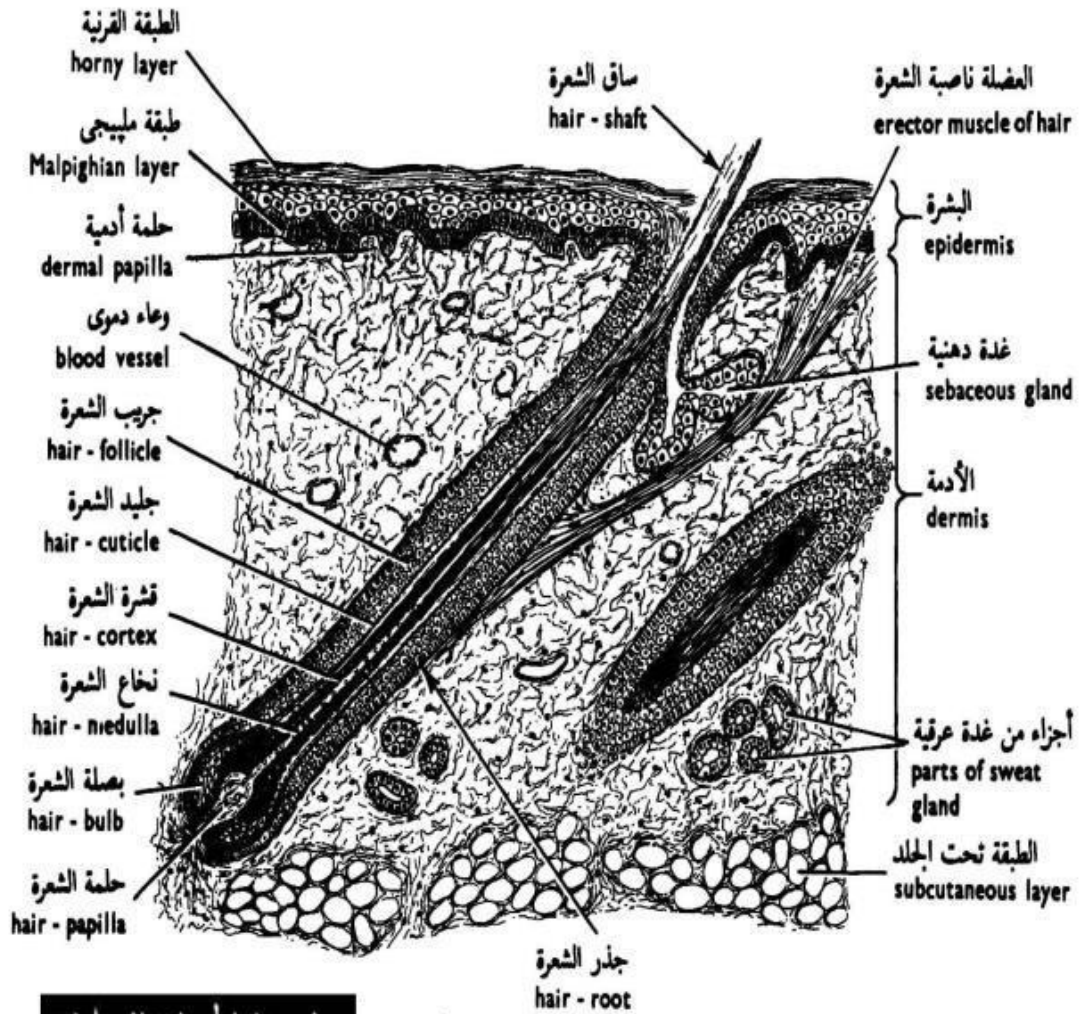
شكل ٥٤ - قطاع رأسي من جلد الضفدعة
 FIG. 45 - V.S. OF THE SKIN OF THE TOAD



v.s in the skin of Reptilia

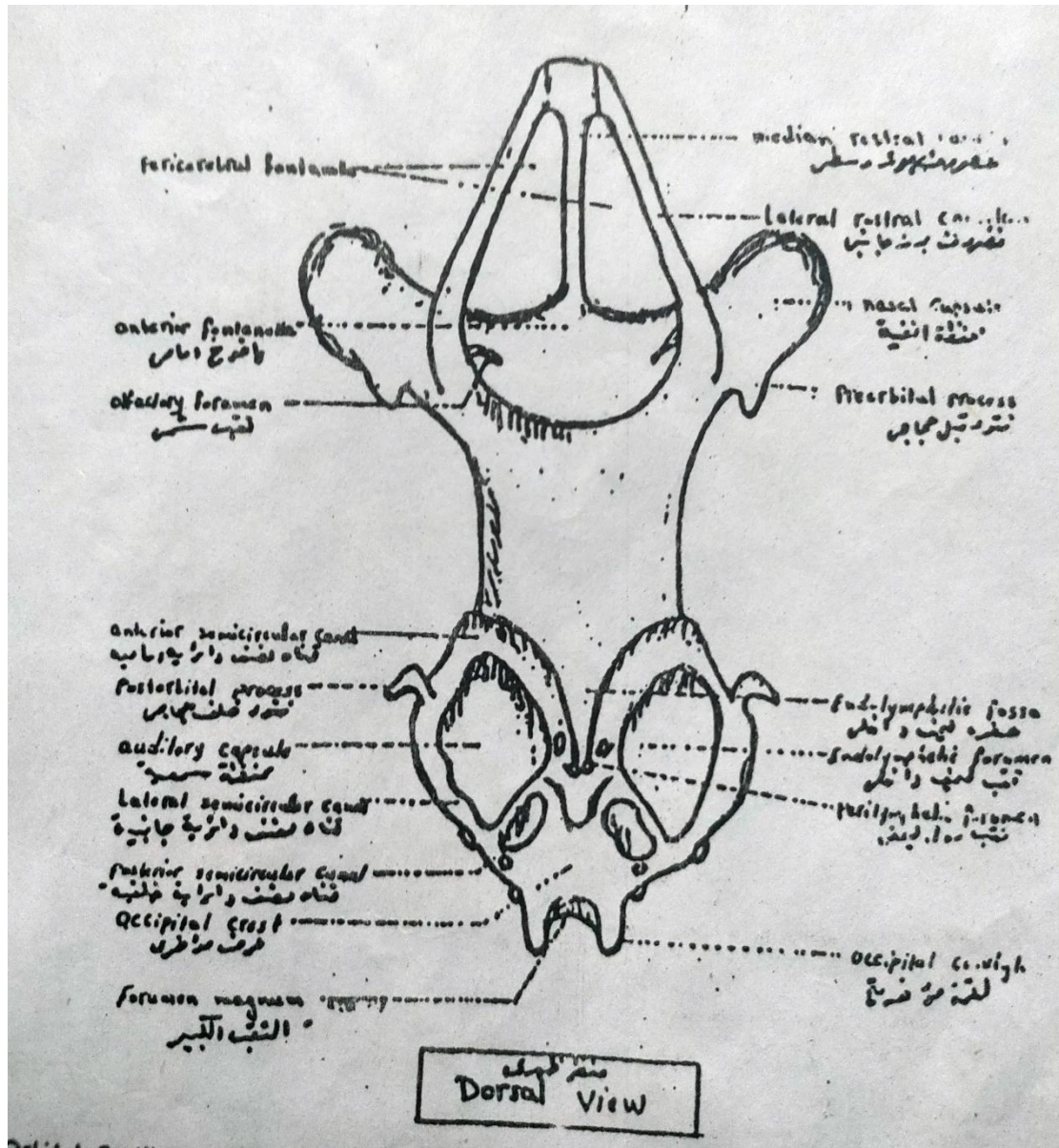


v.s in the skin of Aves

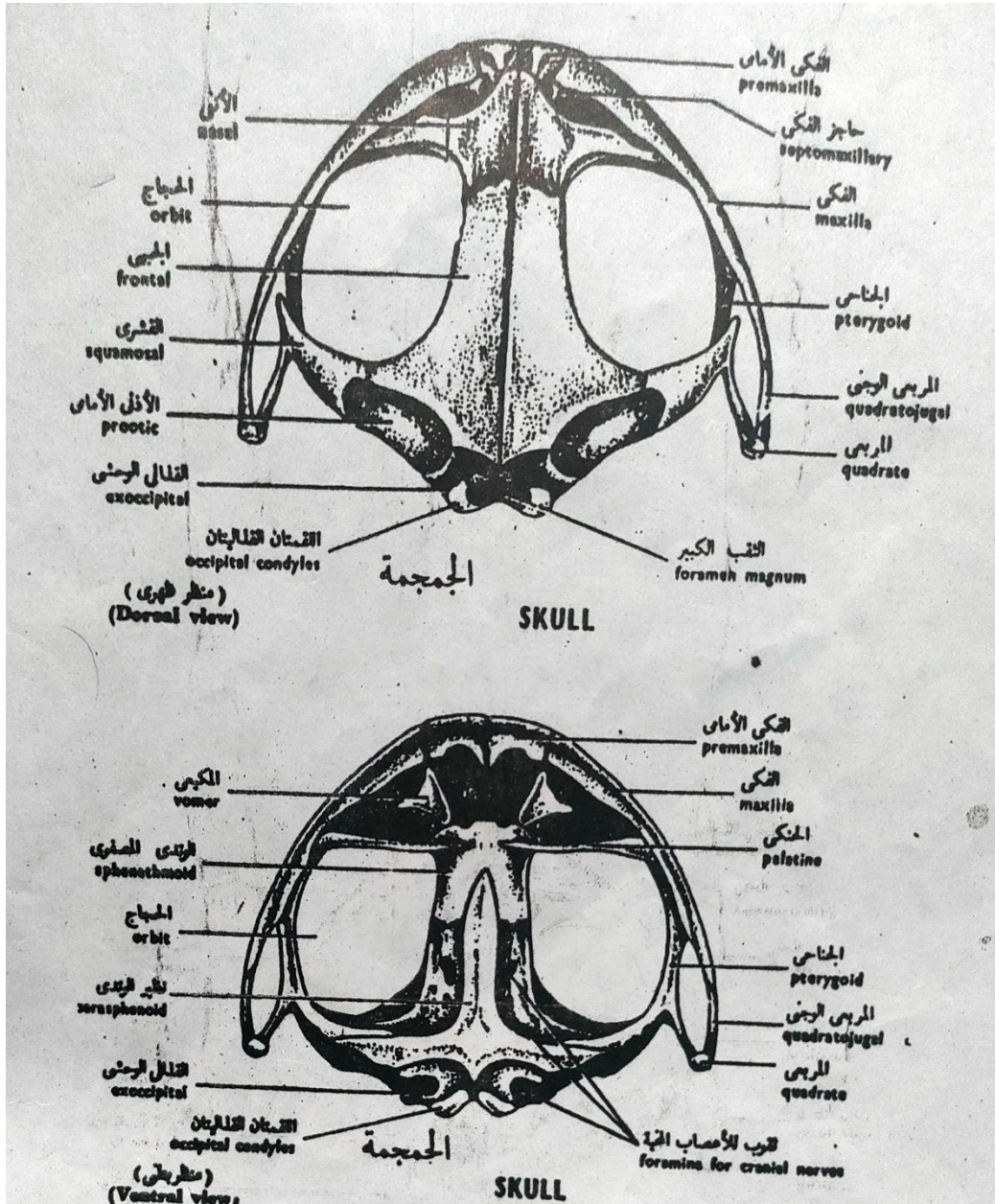


بيولوجية الحيوان العملية
 قطاع رأسي من جلد الخنزير

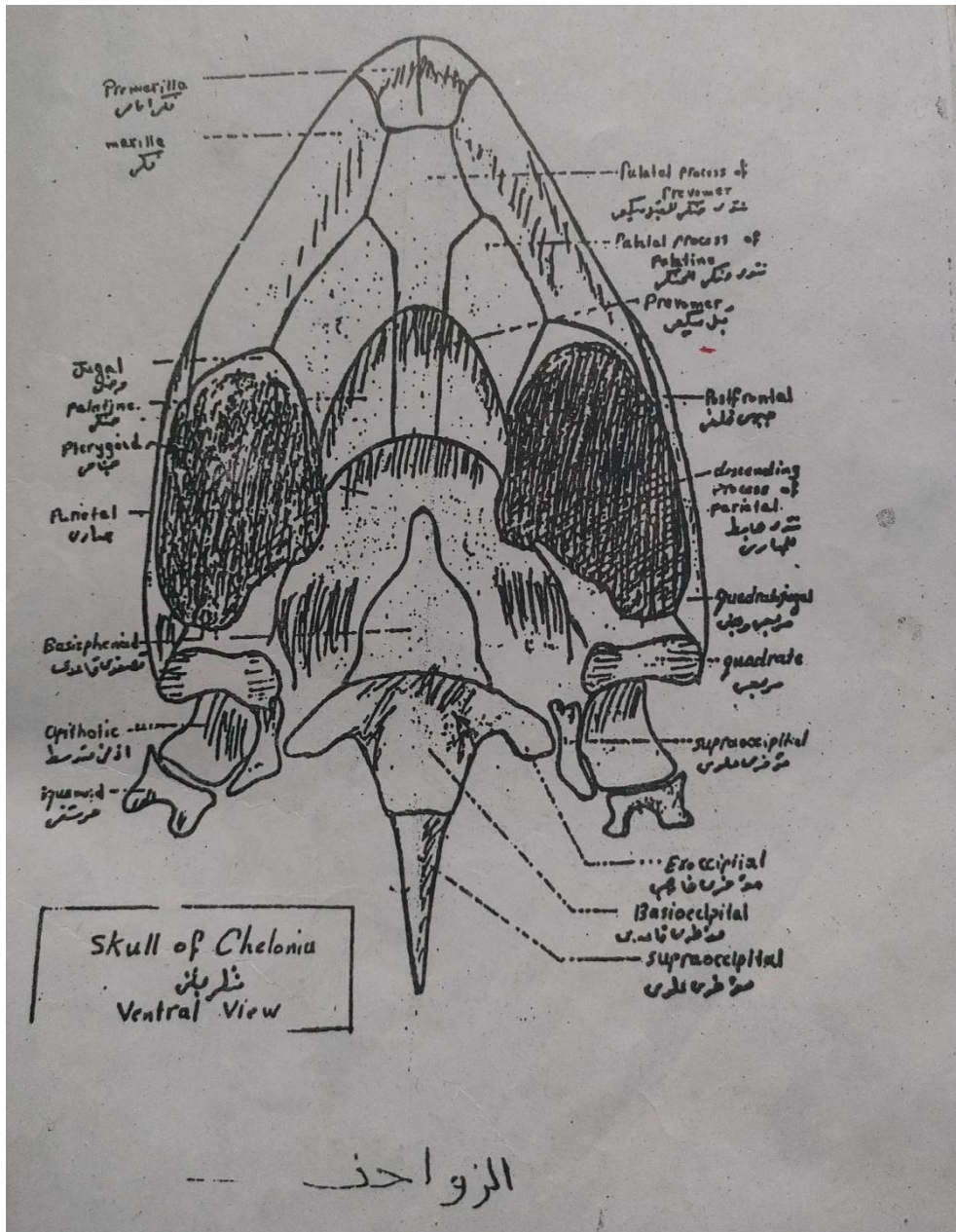
v.s in the skin of Mammalia



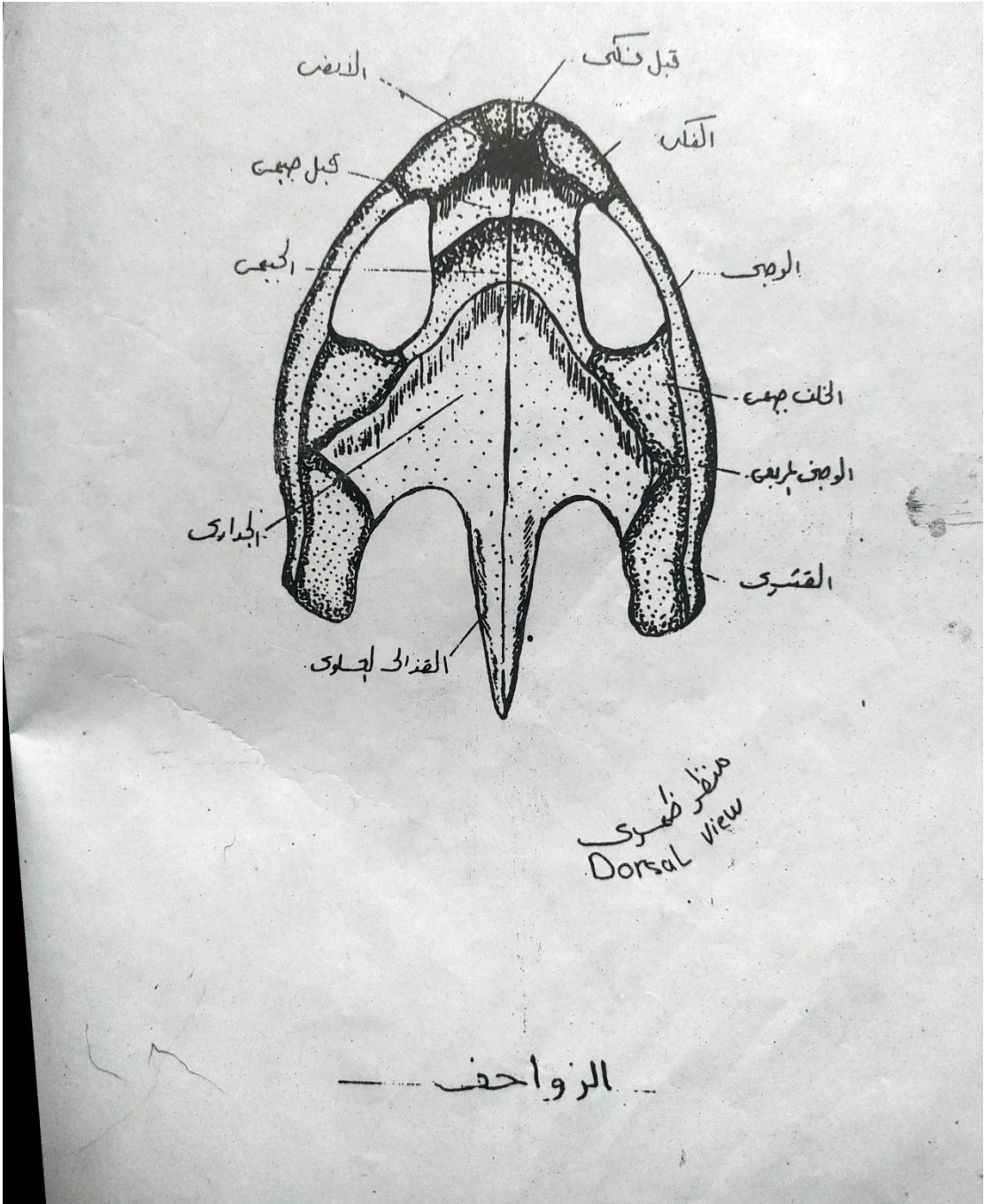
Dorsal view of dog fish skull



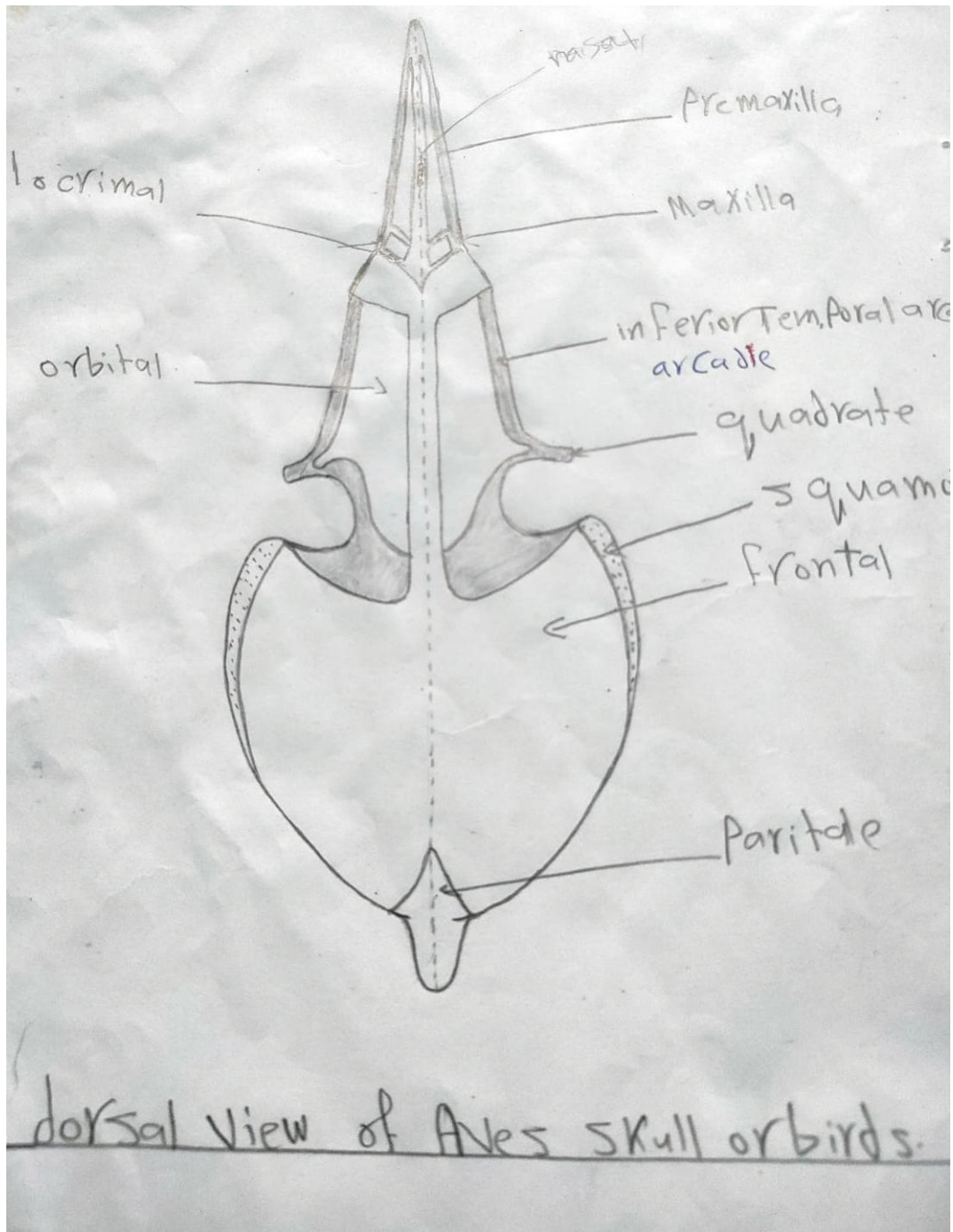
The skull of Toad



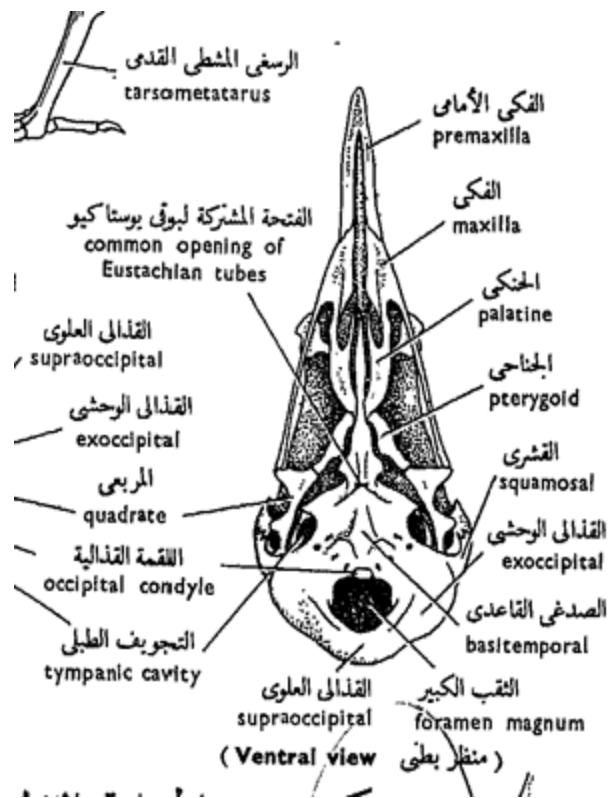
Ventral view of Chelonia skull



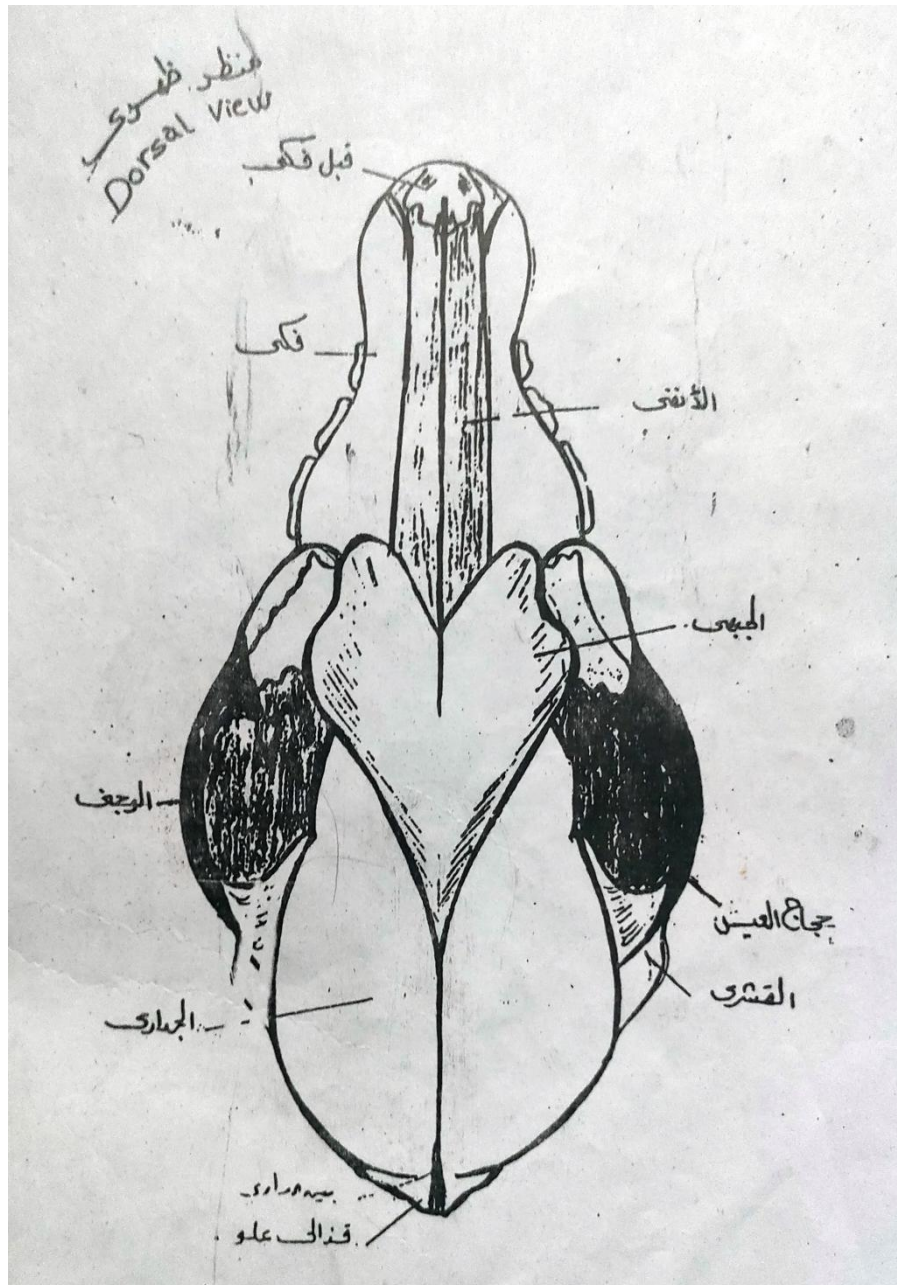
Dorsal view of Chelonia skull



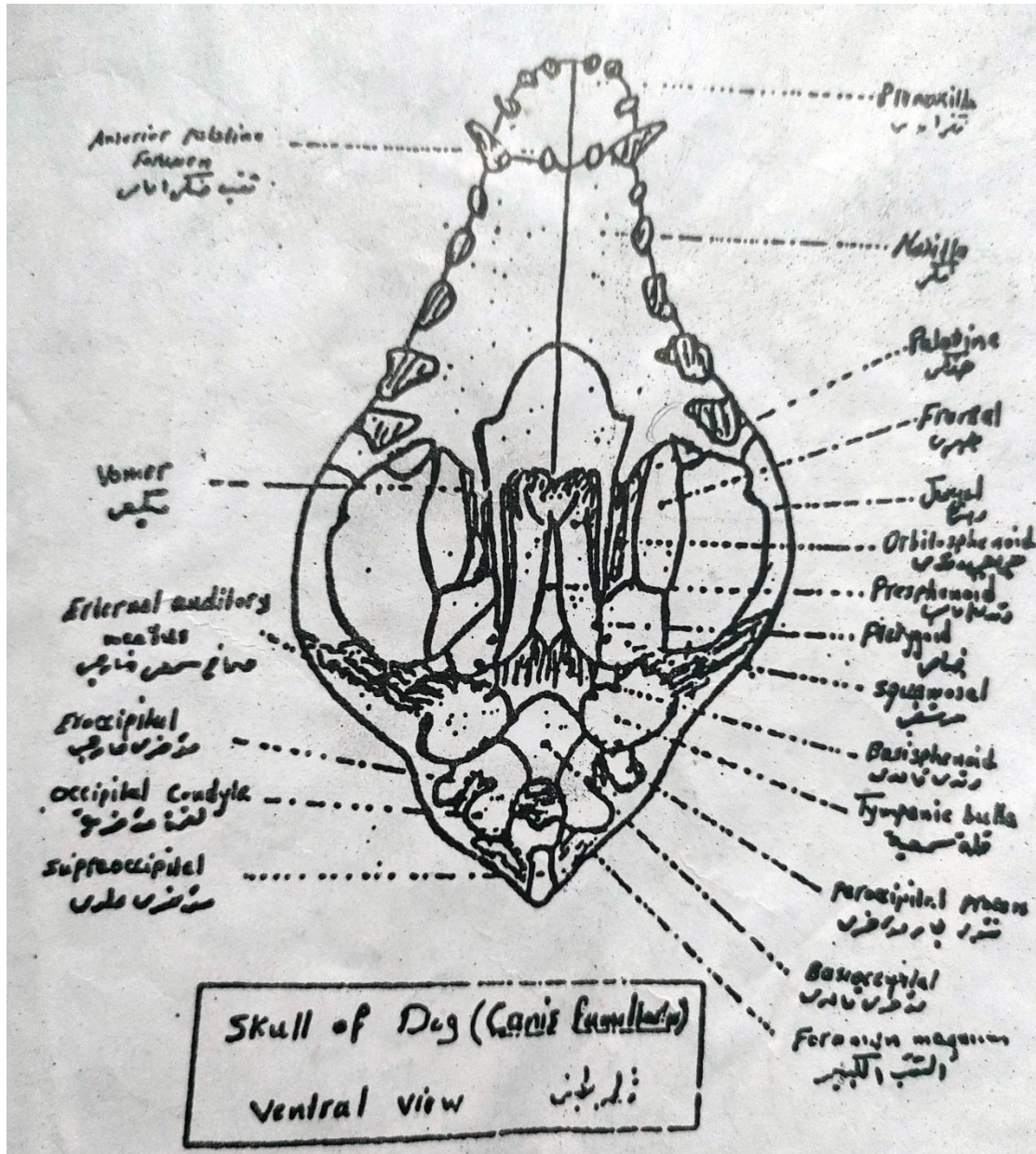
Dorsal view of Aves skull



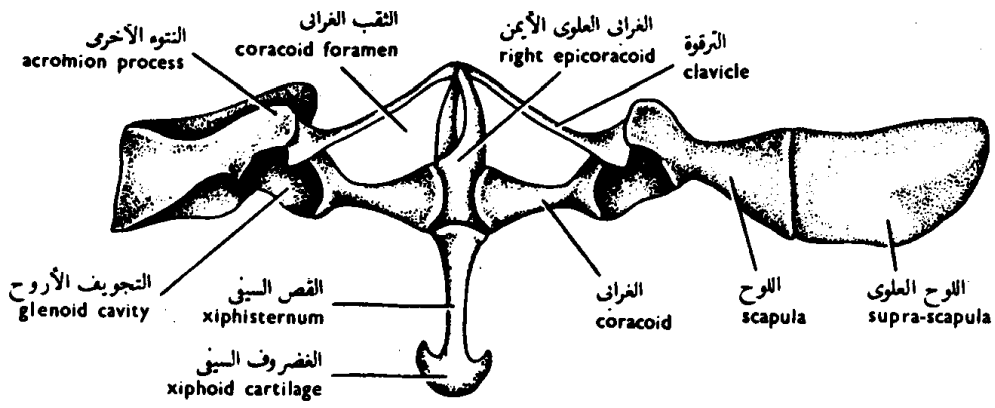
Ventral view of Aves skull



Dorsal view of Dog skull (Mammalia)

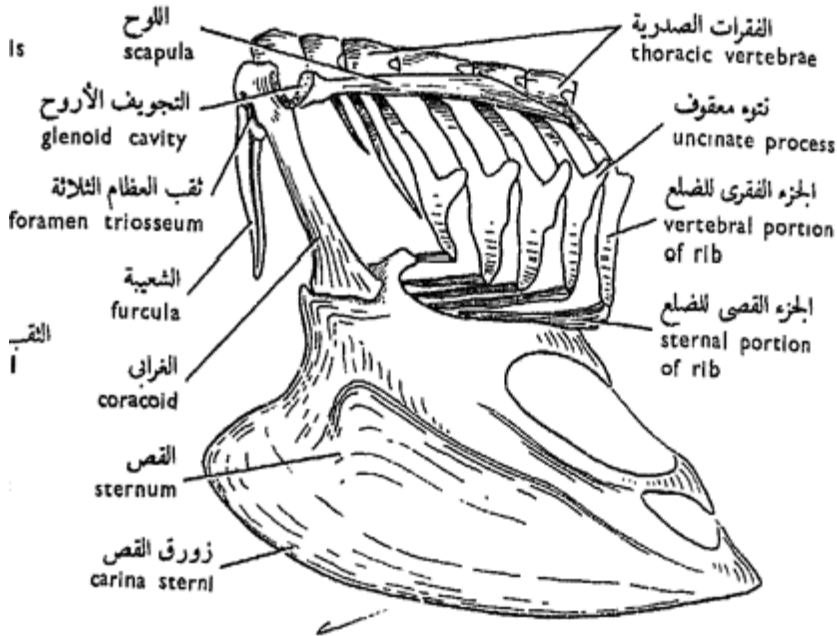


Ventral view of Dog skull (Mammalia)



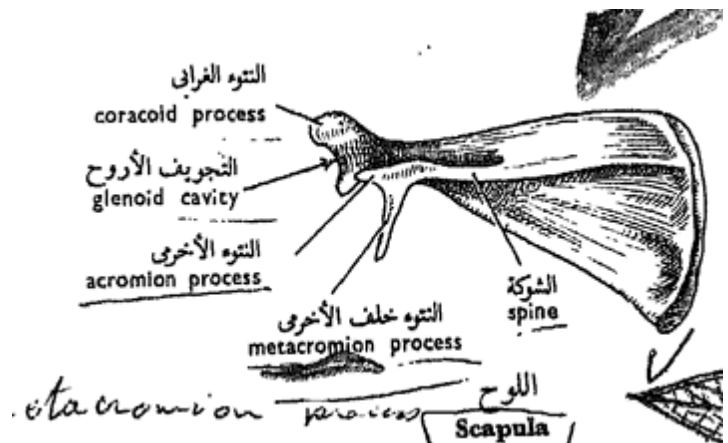
شكل ٣٣ - الحزام الصدري والقص.
FIG. 33 - PECTORAL GIRDLE AND STERNUM

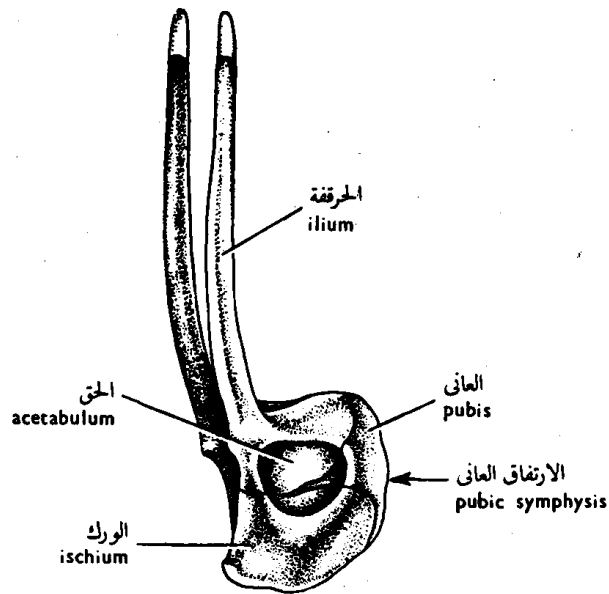
Toad



Skeleton of
 thorax in Aves

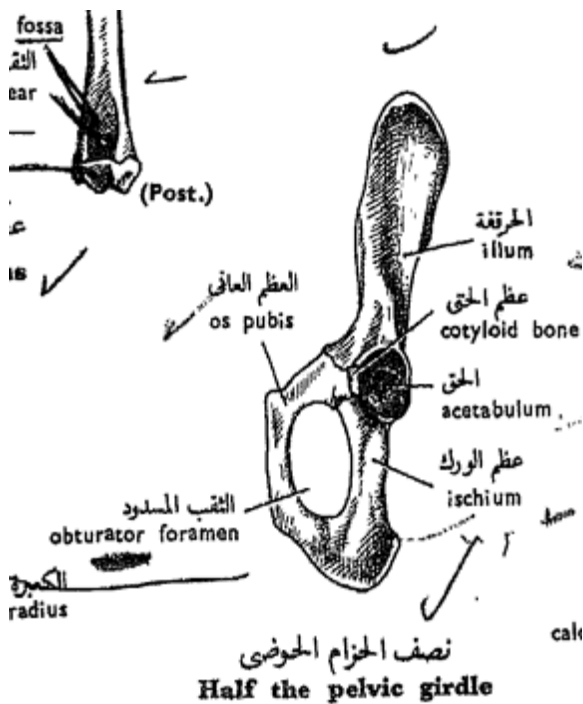
Scapula in Mammalia



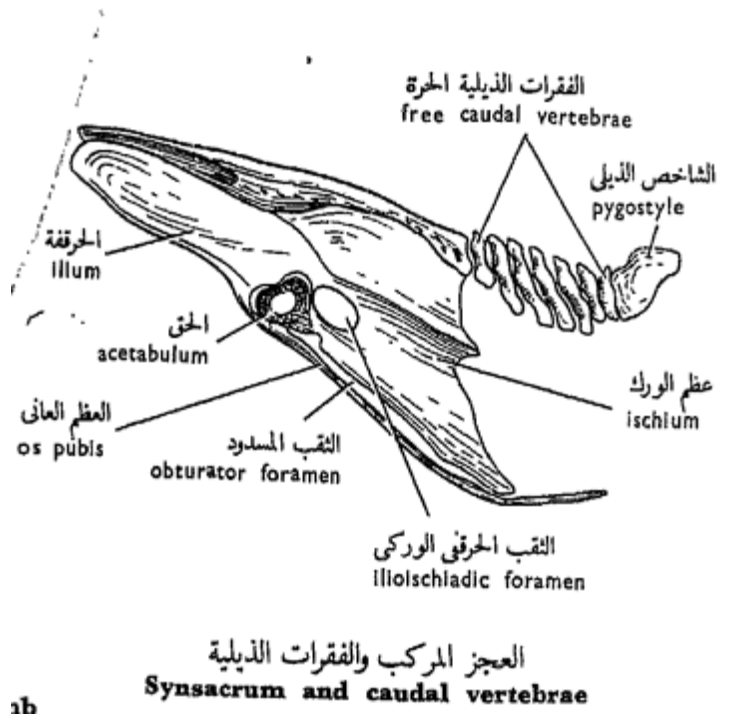


شكل ٣٥ - الحزام الحوضي
FIG. 35 - PELVIC GIRDLE

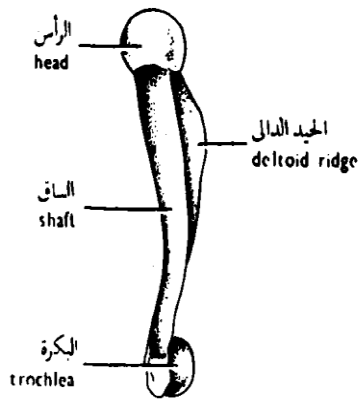
Toad



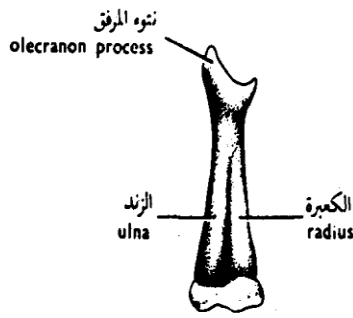
Mammalia



Aves

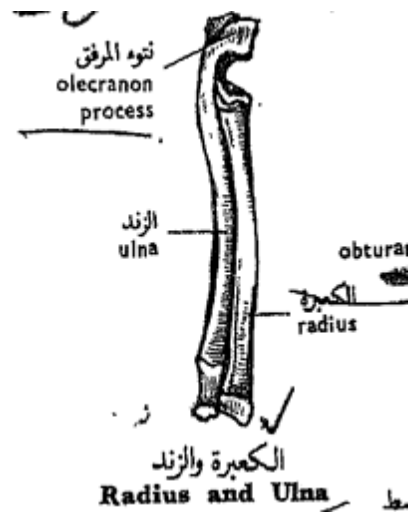
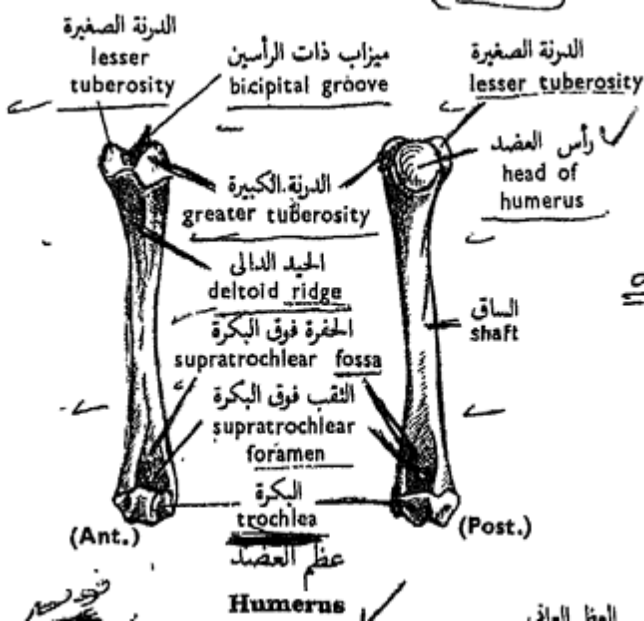
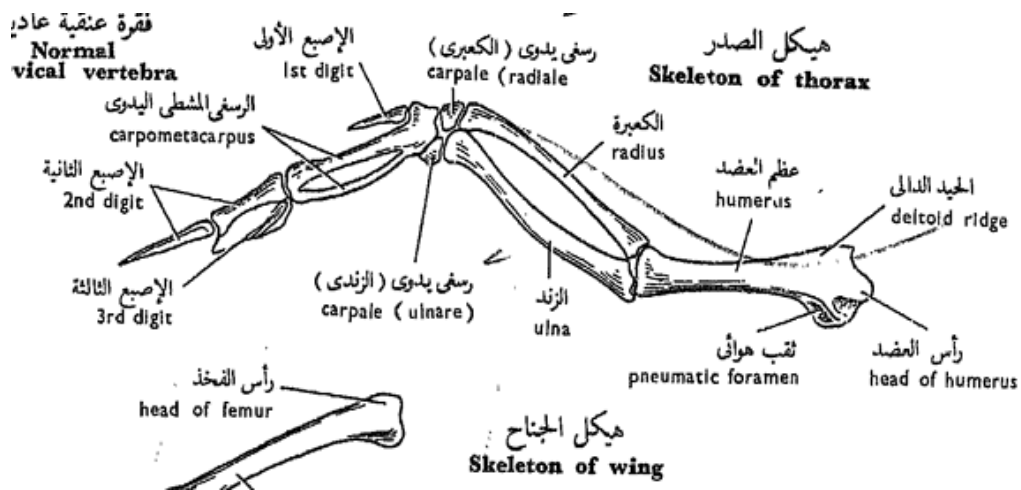


عظم العضد
HUMERUS

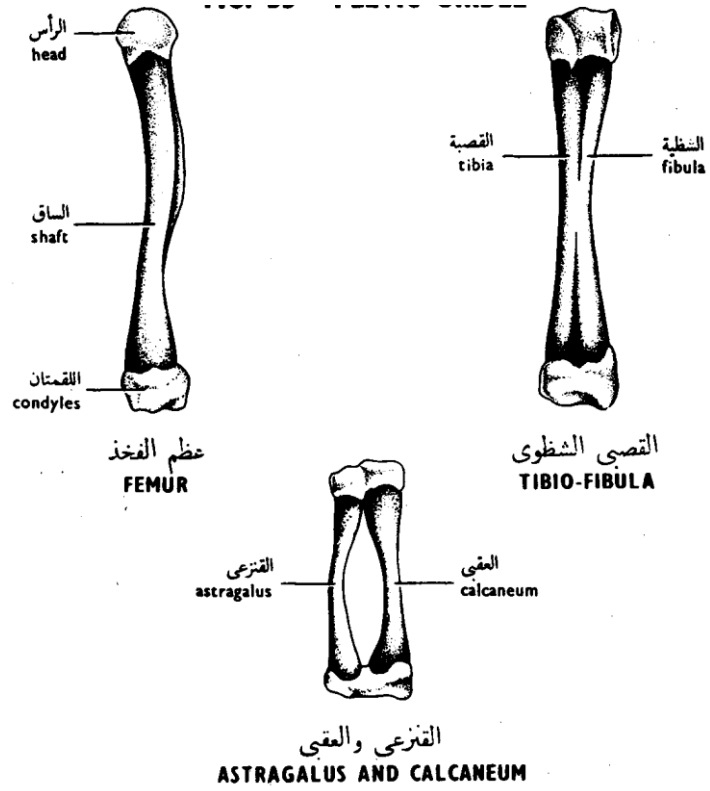


الكعبري الزندي
RADIO-ULNA

شكل ٣٤ - عظام الطرف الأمامي
FIG. 34 - BONES OF FORE-LIMB



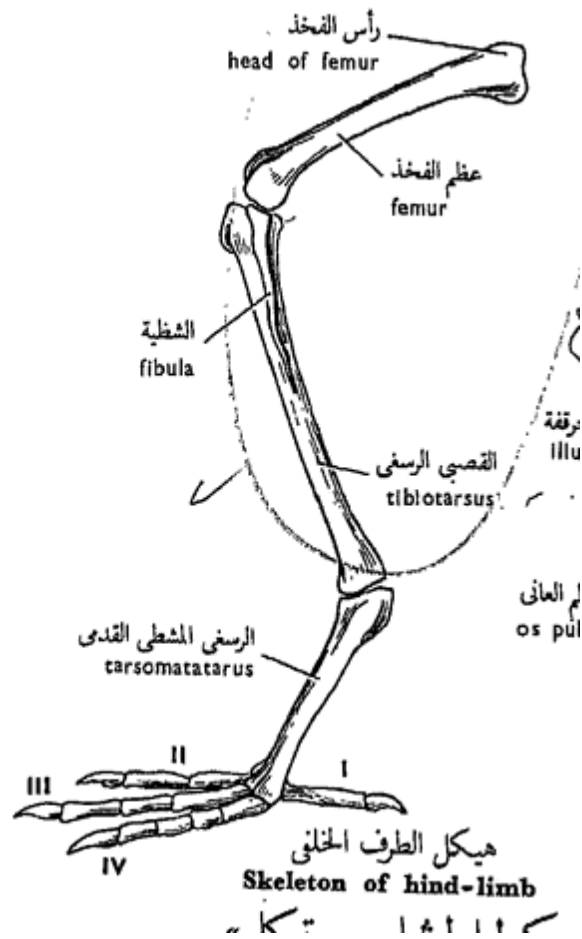
الكعبرة والزند
Radius and Ulna



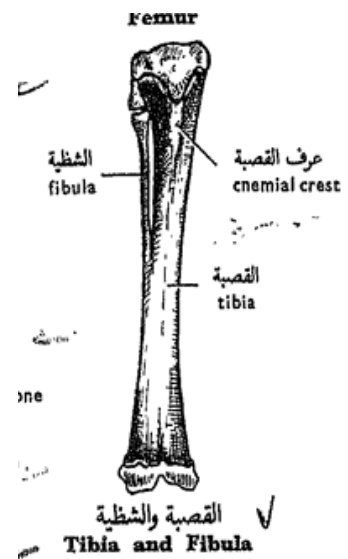
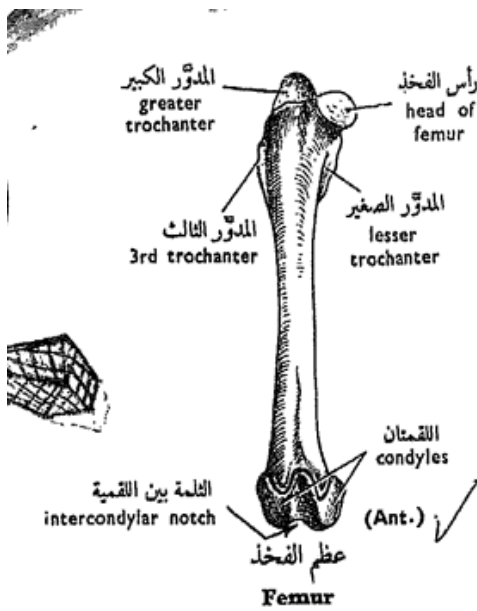
شكل ٣٦ - عظام الطرف الخلفى
FIG. 36 - BONES OF HIND-LIMB

Toad

Aves



Bones of hind -limb in mammalia



References

- كتاب بيولوجيا الحيوان العملية
- مذكرة تشريح تجمع رسومات الدروس العملية مجهزة من قبل قسم علم الحيوان