



**Zoo 101– Zoology I (حيوان عام 1) مقرر**  
**لطلاب الفرقة الأولى بكلية العلوم شعبة البيوتكنولوجي**  
**للعام الدراسي 2024-2025 الترم الأول**

**الجزء النظري**

**إعداد**

**دكتوراه سهام علي مبارك**

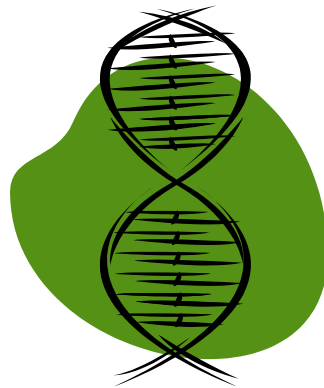
**القائم بالتدريس**

**دكتوراه مريم ابوبكر فاوي**

# Introduction



- Biology – The study of **Life**
  - What does it mean to be ALIVE?
  - How do you know if something is ALIVE?



# Characteristics of Life

**All living things share some basic properties**

Reproduction

Growth

Homeostasis

Response to stimuli

Energy processing

Adaptation

Evolution

Movement

Respiration

Excretion

Metabolism

Organization

# Microscopes

## Types of microscopes

- 1 Light microscope.
- 2 Phase contrast microscope.
- 3 Polarizing microscope.
- 4 Fluorescence microscope.
- 5 Electron microscope.

## 1- Light microscope

### I- Illuminating system (source of light):

- Day light.
- Electric light.

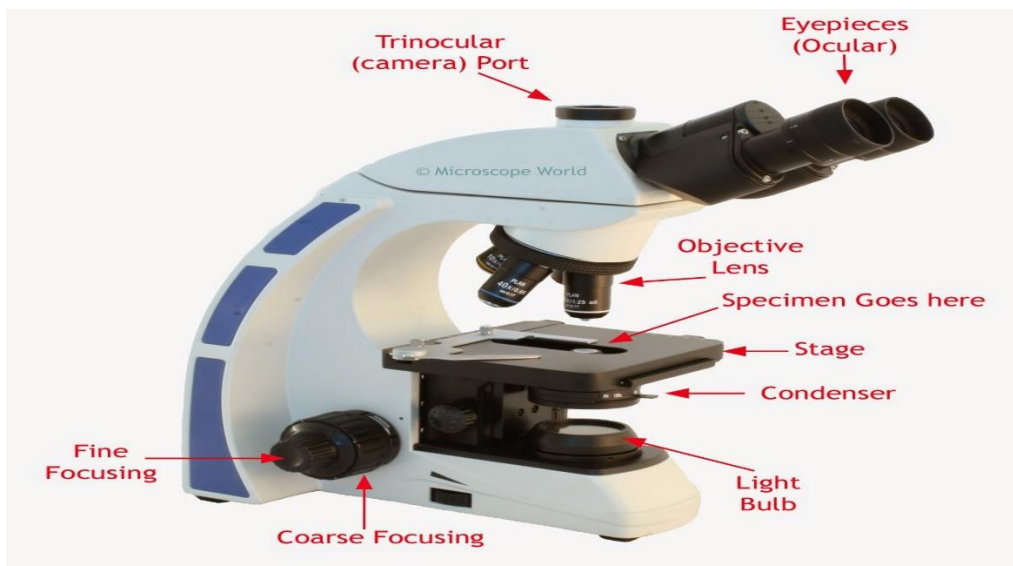
### II- Optical system:

- *Condenser lens*: collect and focus light on the specimen.
- *Objective lenses*: provide initial magnification (x4, x10, x40, x100).
- *An ocular lens (eyepiece)*: magnifies the primary

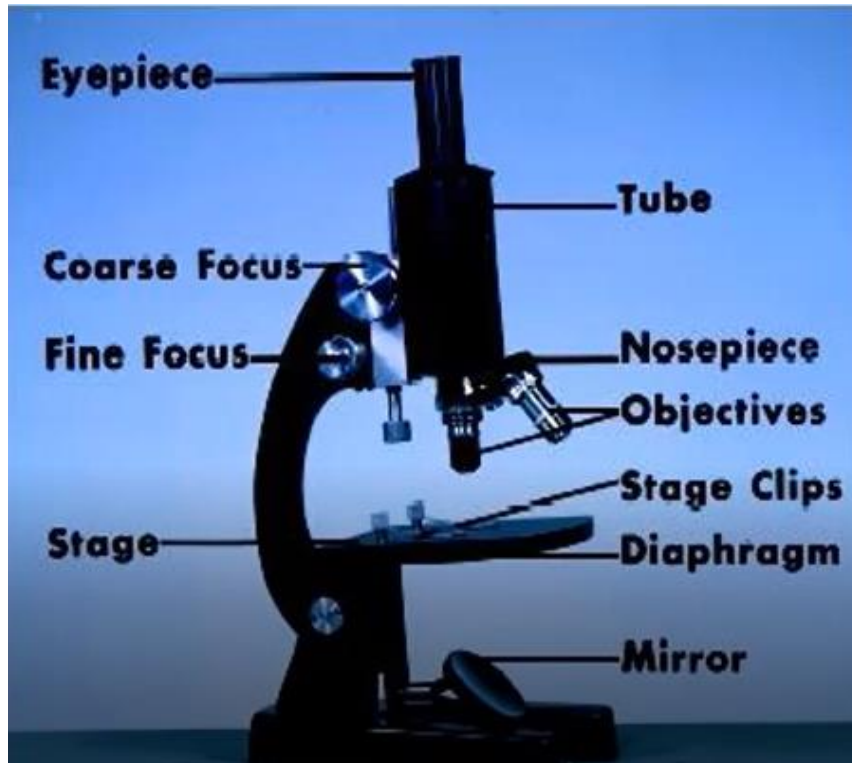
image a second time (x5, x10, x15).

### III- Focus adjustment knobs: focus the image by

moving the stage up and down.

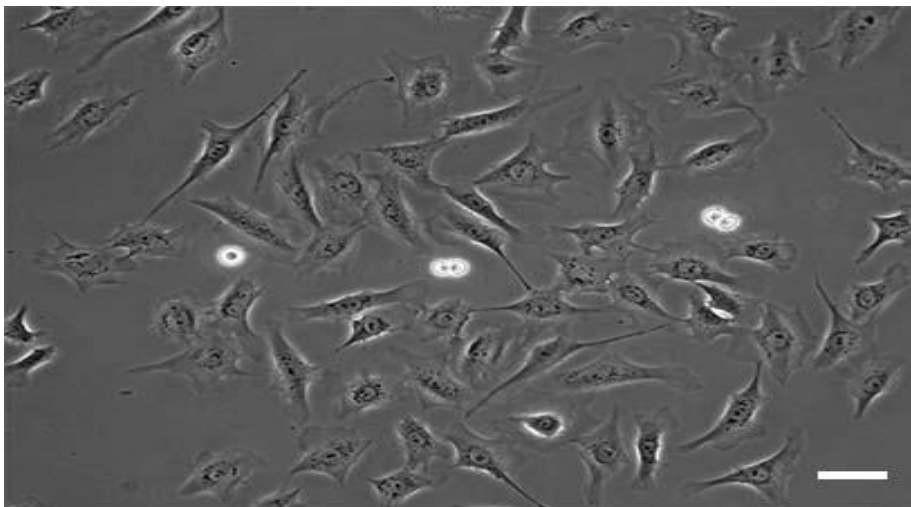
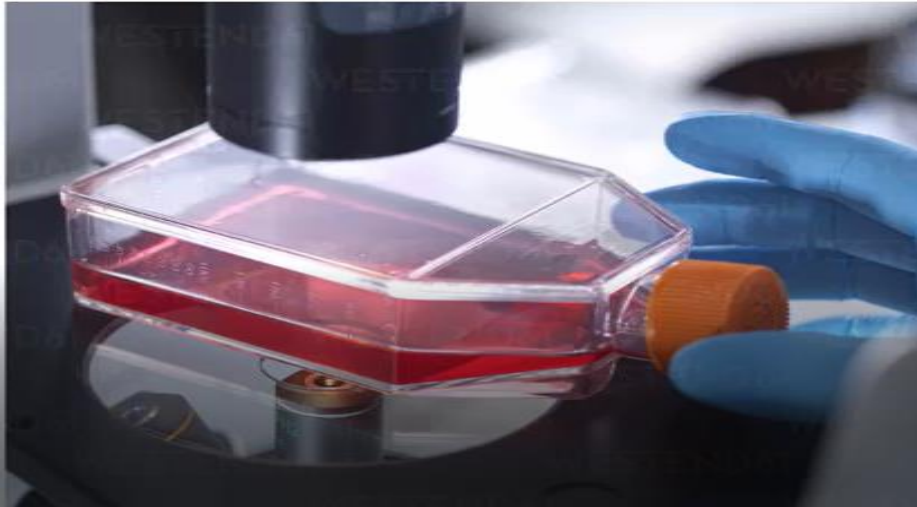


Total magnification= Magnifying power of the objective lens x magnifying power of ocular lens



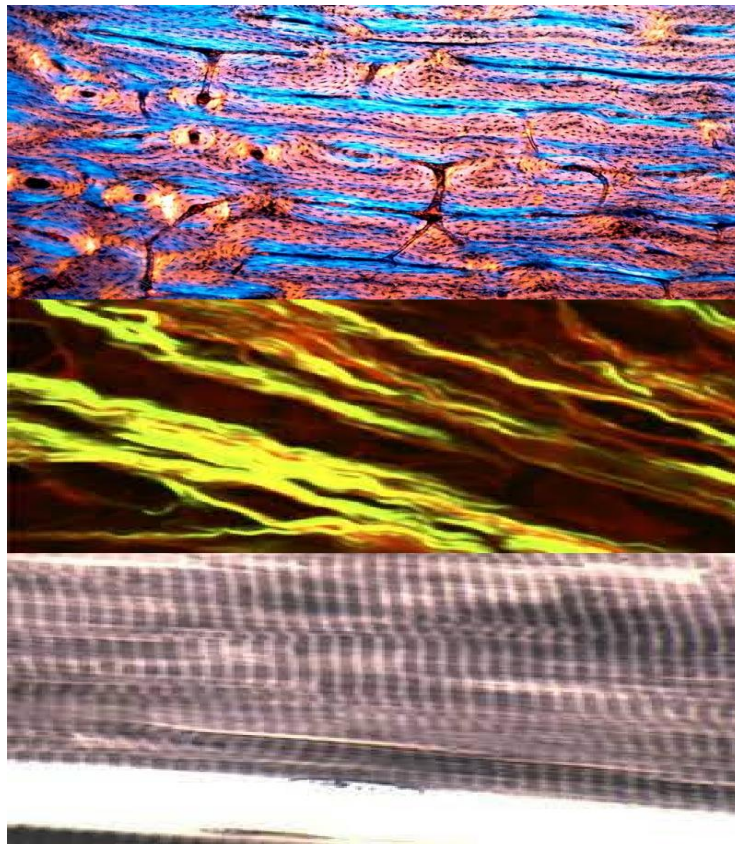
## 2- Phase contrast microscope

- **Use:** for unstained living histological specimen.



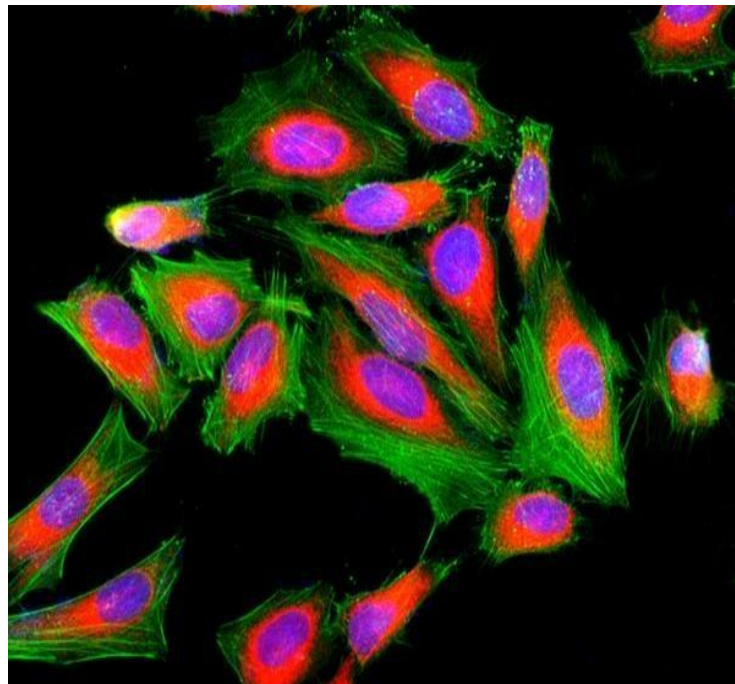
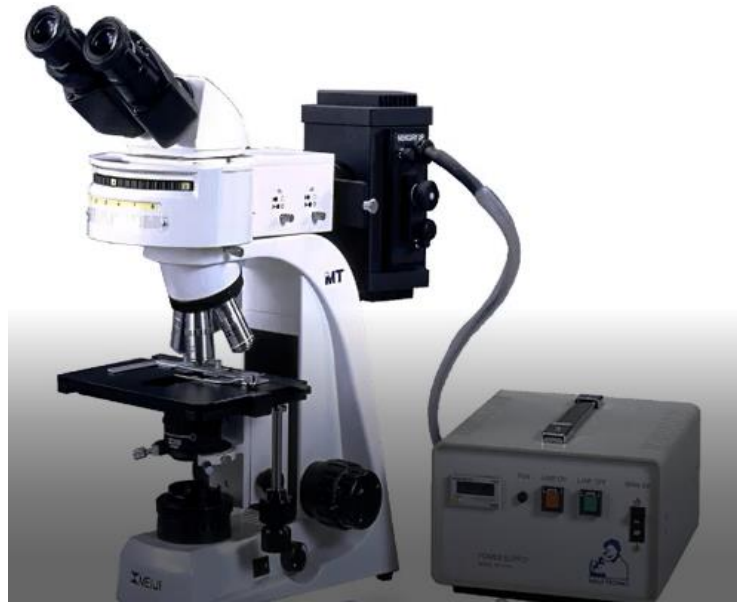### 3- Polarizing microscope

- Use:
  - Regularly oriented structures (bone).
  - Structures with linear symmetry (collagen, muscle, microtubules, cilia & flagella).



#### 4- Fluorescence microscope

- **Light source:** ultraviolet light source.
- **Stain:** fluorescent stain.
- **Idea:** the specimen absorbs the UV light and emits light of a longer wavelength.
- **Use:** immunohistochemistry.





## 5- Electron microscope

- **Illuminating system:** electron beam.
- **Types:**

### 1- Transmission EM:

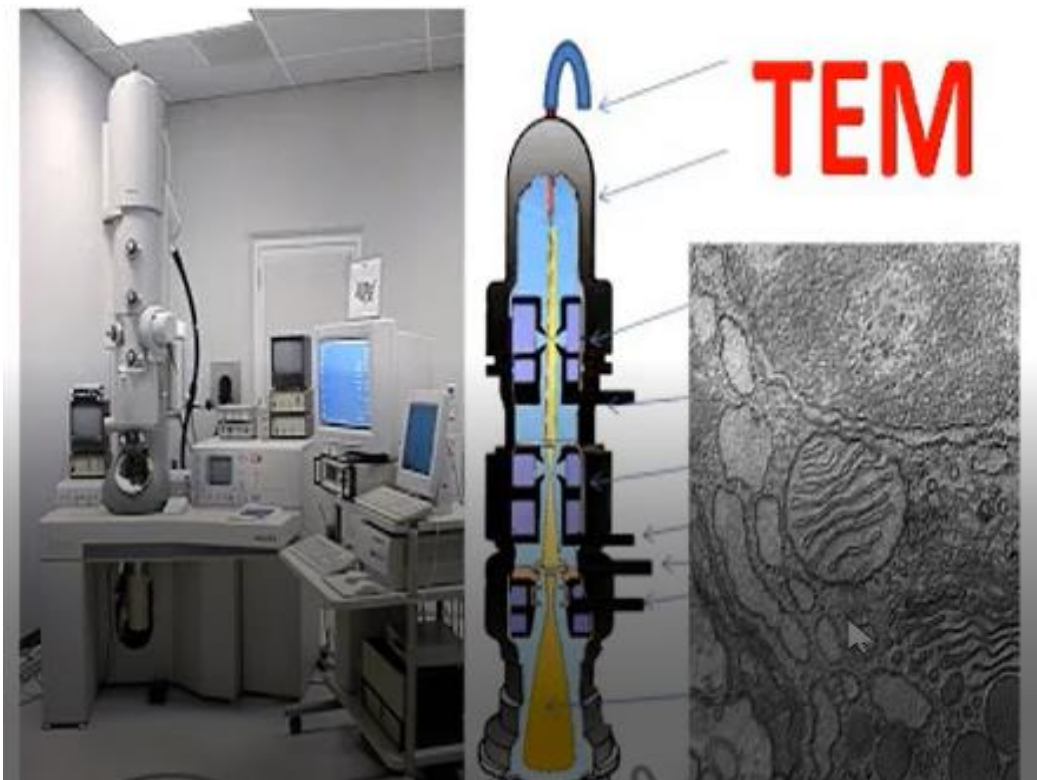
- It gives details about the cellular and intercellular structures.
- An electron gun at the top of a TEM emits electrons.
- An electromagnetic lens focuses the electrons into a very fine

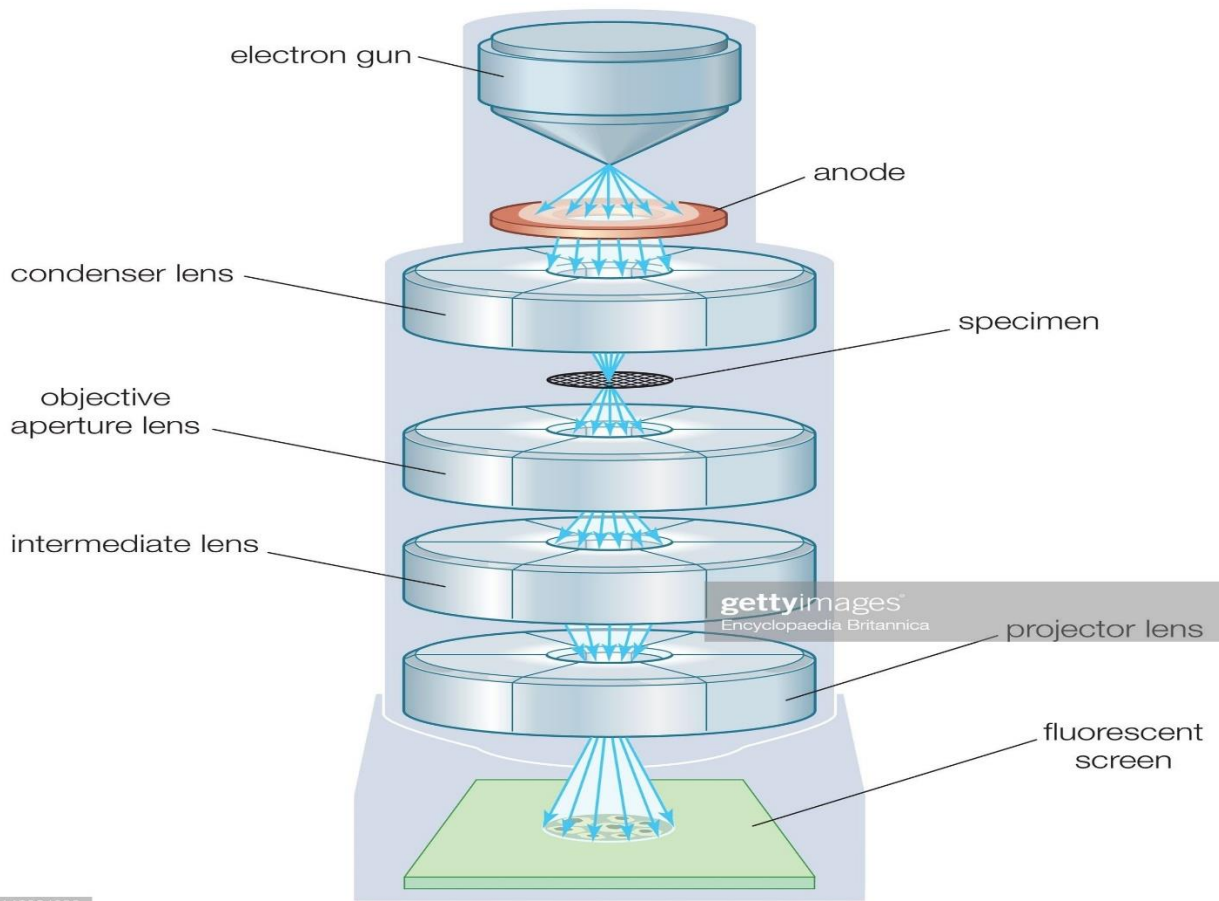
beam.

- This beam then passes through a very thin specimen.
- Another electromagnetic lenses form and magnify the image.
- The final image is viewed on a fluorescent screen.

### 2- Scanning EM:


- Gets 3-D image of the surface of the specimen.





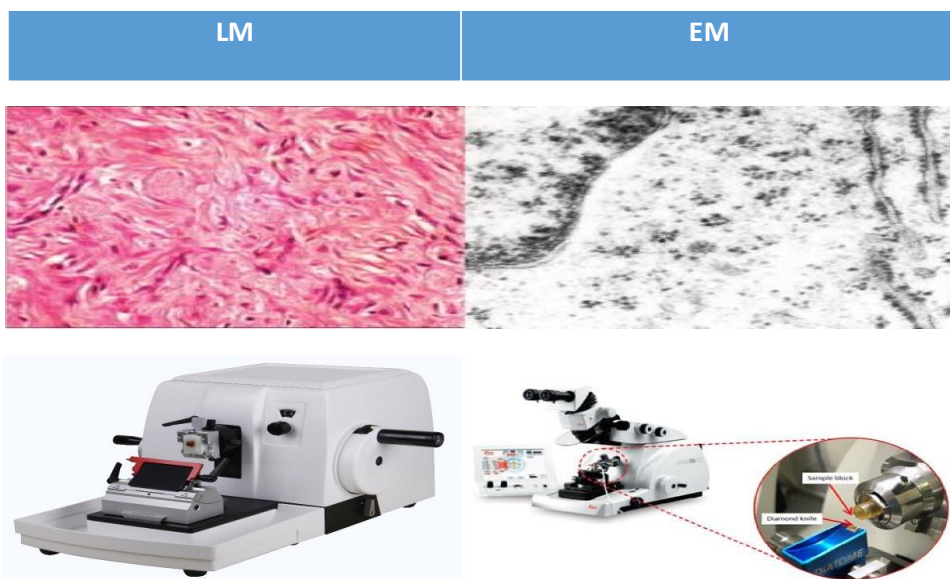
143064900

**SEM**



Type of microscope	LM	EM
<b>1- Source of light</b>	Day or electric light.	Beam of electrons.
<b>2- Lenses</b>	Glass lenses.	Magnetic fields.
<b>3- Magnification</b>	Up to 1500.	Up to 1000.000.
<b>4- Embedding</b>	Paraffin.	Plastic.
<b>5- Sectioning knife</b>	Rotatory microtome: steel knife.	Ultra microtome: glass or diamond knife.
<b>6- Staining</b>	Any stain.	Lead citrate & osmium tetroxide.
<b>7- Thickness of section</b>	5-9 microns.	50-90 nm.
<b>8- Microphotographs</b>	Colored according to stain.	Black & white.

15

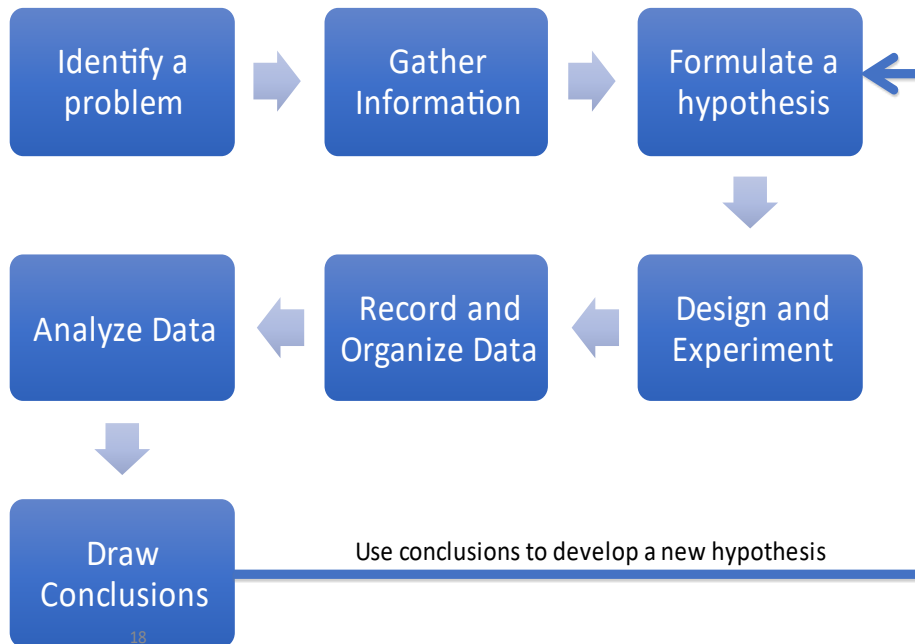


16

# Steps of the Scientific Methods

## Introduction

- A logical, problem solving technique



## Step 1: Identify a Problem

- **Observe the world around you**
  - Using observations, identify a problem you would like to solve
    - **Example: Why do termites follow the ink line?**
- **This is a question you DO NOT know the answer to and can't look up.**
- **“Why” and “What would happen if..” are good beginnings of scientific questions.**

# Remember?

## Observation

- Uses our senses to gather information
- Qualitative: uses our 5 senses
  - The termites follow a circle made with a blue pen on white paper
- Quantitative: uses numbers
  - 3 termites follow a circular blue pen line that is 5 cm in diameter

## Inference

- A logical interpretation of events based on prior knowledge or opinion
  - Educated guess
- Termites follow the blue line because they like it.

Do we use observations or inferences when identifying a problem?

## Step 2: Gather Information


- Use references to do background research

- Books
- Journals
- Magazines
- Internet
- TV
- Videos
- Interview Experts



- Example: Termites

- Live underground
- Don't have compound eyes (can only see light and dark)



# Step 3: Formulate a Hypothesis

## Hypothesis

- Possible answer to a question that can be tested
- based on **observations** and knowledge
- “If” “Then” “Because” statement



22

## Example: Termites

- Termites:
  - I hypothesis that **if** the termites follow a dark colored pen on a dark background **then** they follow the dark pen on a light background **because** of the color contrast since they see light and dark, but not color.

Do we use observation or inference to formulate a hypothesis?

# Step 4: Develop an Experiment

## Materials:

- **A list of all the things you need**
- Supplies

## Procedure

- Step by step instructions
- Identifies the variables used in the experiment



23

How would you describe how to make a Peanut Butter and Jelly Sandwich to someone who had never done it?

To someone who didn't know what peanut butter or jelly is?

# Variables: Independent Variable

- The variable **I** (the scientist) change or manipulate
- Examples:
  - The color of paper under the termites
  - The color of pen used
  - The brand of pen used



24

# Variables: Dependent Variable

- Is **measured** in the experiment
- Changes because of the independent variable
- “Depends” on the independent variable
- Examples:
  - Does the termite follow the line (yes/no)
  - How many termites follow the line (whole number)
  - How long do the termites follow the line (time)



25

# Variables: Constant

- All the factors in the experiments that are kept the **same**
- Everything except the independent variable
- Keeps the experiment 'fair'



## Examples:

- If you test color of paper, keep the color of pen constant
- If you test the smell of pen, keep the color and type of pen constant (only change smell)
- The exact termites used
- The time of day and how long the termites are there
- The shape of the line drawn

# Variable:Control

- The normal condition that you compare the other conditions to
- Recreate the conditions you first observed
- Example:
  - Termites in a Petri dish on white filter paper and draw a blue line with a blue pen in the same shape as before.



## Step 5: Record and Organize Data

- Write all observations and measurements
- Use a table to organize your data
  - List your **independent** variable on the left side
  - Record your dependent variables on the **right side**
    - If you have more than one dependent variable, use a new column for each dependent variable

Independent Variable	Dependent Variable: Did they follow the line?
Blue ink on white paper	Yes/No
Blue ink on black paper	Yes/No

Which one of these independent variables is the control?

28 Which part of the independent variable is the constant?

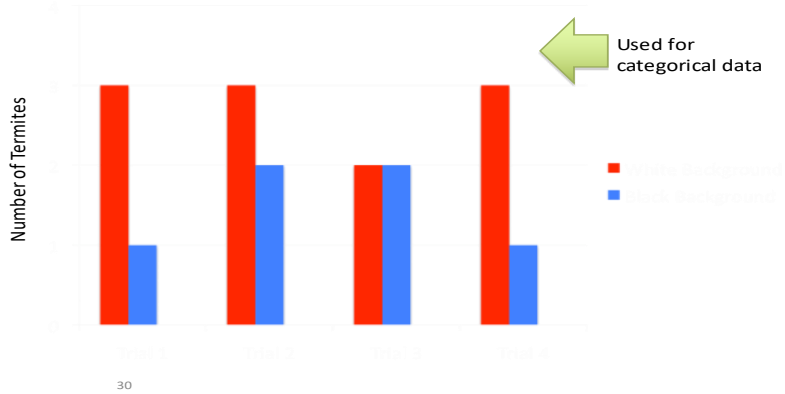
## Step 6: Analyze Data

- “A picture is worth a thousand words ”
- Compare and look for trends and patterns using graphs



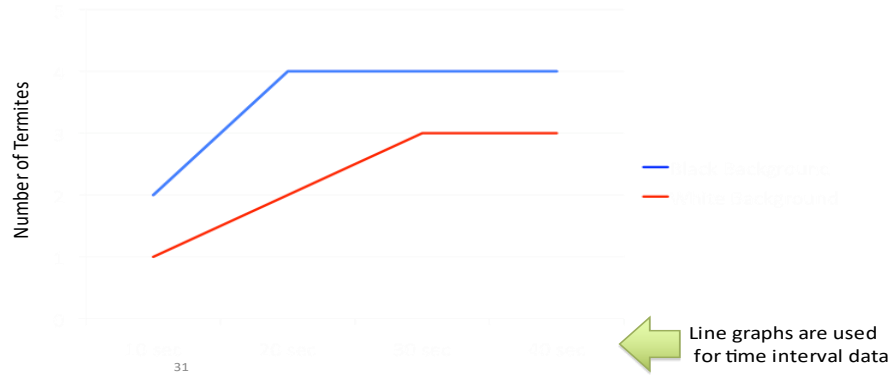
29

# Bar Graph



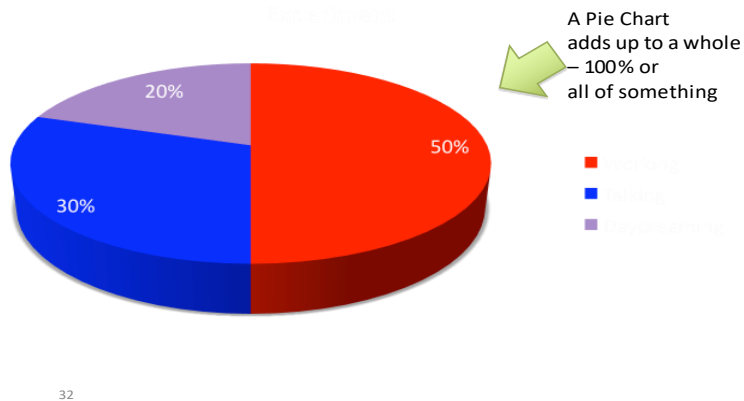
# Line Graph

Number of termites on the ink line for 40 seconds



# Pie Chart

What activities were going on during the Multiple-Termite Experiments?

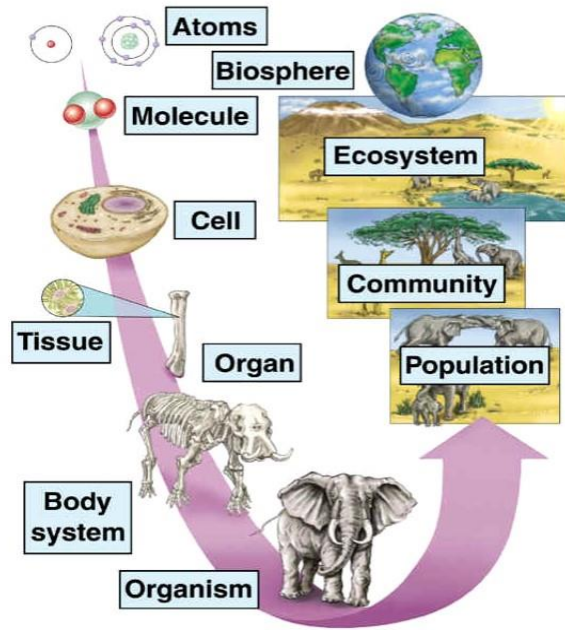


## Step 7: Make Conclusions

- You must repeat the experiment to make the data valid
- You should run your experiment at least **3** times to confirm your results
  - You can run all the experiments at one time, or run one after the other
- Each separate experiment is called a **Repetition** (or Rep).

How many times?

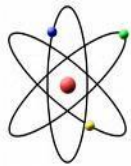# Levels of Organization in BIOLOGY...



34

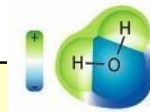
Harcourt, Inc.

## From the smallest level.



### 1. ATOMS

**The smallest unit of matter that cannot be broken down into anything simpler by chemical means.**

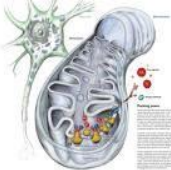


### 2. Molecules

**The smallest units of most compounds formed by the chemical bonding of atoms.**

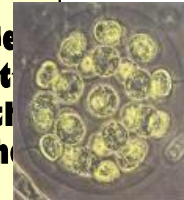
### 3. Organelles

**Specialized structures that perform important cellular functions within cell**



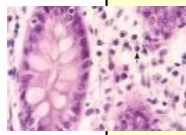
### 4. Cell

**The smallest unit of life collections of living matter enclosed by a barrier that separates them from the surroundings.**



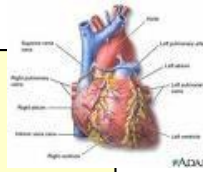
35

# From the smallest level.



5. Tissues

**Groups of similar cells that perform a particular function.**

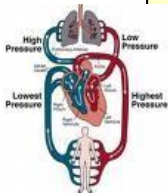


6. Organs

**Groups of tissues that work together to perform closely related functions.**

7. Organ Systems

**Groups of organs that work together to perform closely related functions.**



8. Organisms

**Living things composed cells (multicellular organisms).**

Species = a group of organisms so similar to one another that they can breed and produce **FERTILE OFFSPRING.**



36

# ...to the largest level



9. Population

**Groups of individuals of the same species that live in the same area.**

10. Community

**Groups different populations that live together in a defined area.**

11. Ecosystem

**Groups of all the organisms that live in a particular place, together with their nonliving environment.**

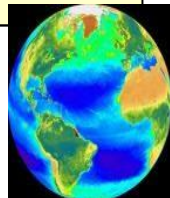
12. Biome

**Groups of ecosystems that have the same climate and similar dominant communities**



13. Biosphere

**Part of the Earth in which life exists including land, water, air and atmosphere.**

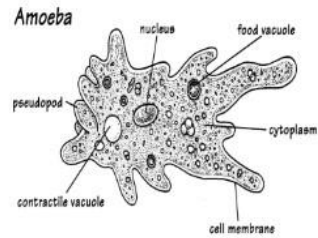


37

# Cytology

## Organisms and Cells

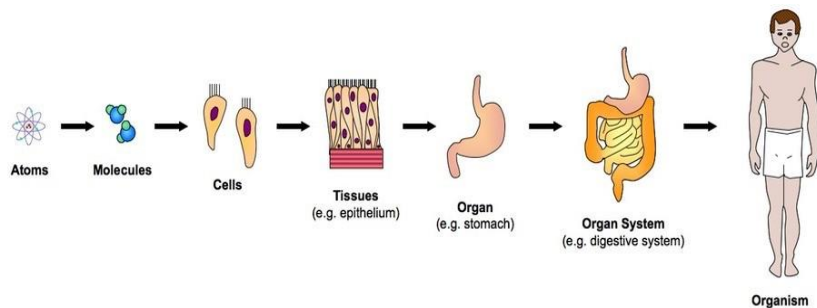
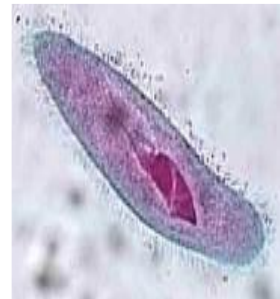
- Some organisms are unicellular.
  - This means they are made of only one cell.
  - Examples: bacteria, yeast
- Some organisms are multicellular.
  - This means they are made of many cells.
  - Examples: humans, trees



40

## Organisms and Cells

- Unicellular organisms have nothing but a single cell.
- However, multicellular organisms have many more levels of organization to make sure the whole body can work correctly, even when it is doing many things at the same time.



41

# There are 5 Levels of Organization in Multicellular Organisms:

- 1. Cells
- 2. Tissues
- 3. Organs
- 4. Organ Systems
- 5. Organisms

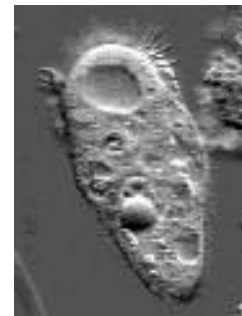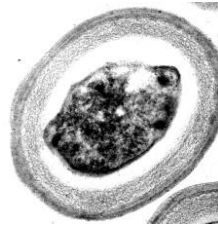42

## The CELL

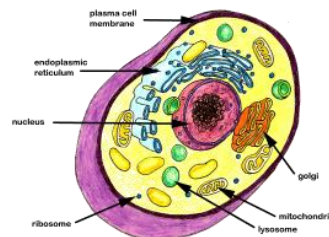
The cell is the basic unit of life.

Cells are specialized by size and shape for the job they do.

Example: skin cell



The paramecium above is made of only one cell and it must perform all the jobs of the organism.

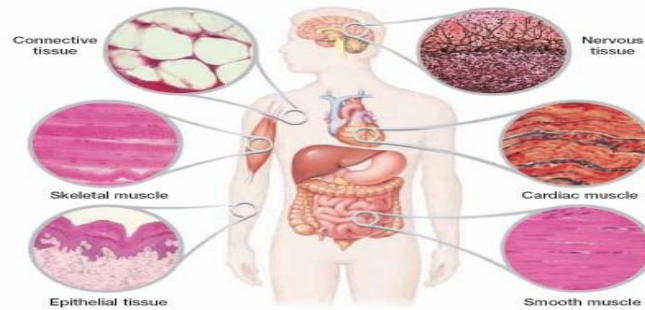

43

# TISSUES

Tissues are made of the same type of cells grouped together to do a specific job.

## Human Body Tissues



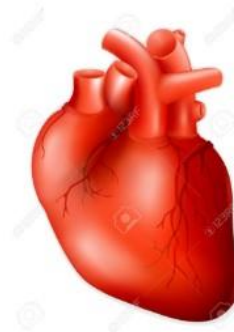Example: Humans have four kinds of tissue in their Bodies: Epithelia, Muscle, Connective, and Nerve.



## Organs

Organs are made up of different tissues that work together to do a job.

Example: a heart is an organ .



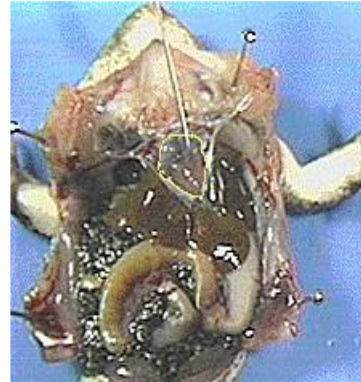

# Organ Systems

An organ system is a group of organs working together.

Examples:

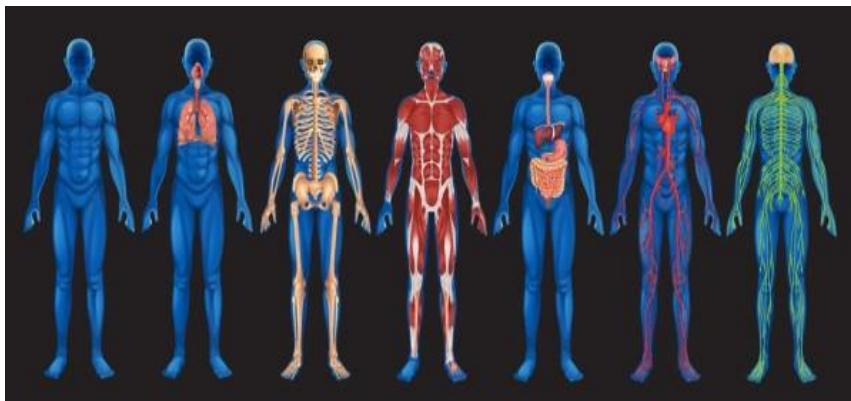- Human organ systems include circulatory, reproductive, digestive, nervous, respiratory.
- Plant organ system-roots, stems, leaves= transport system.



46

# Organisms

All cells, tissues, organs and organ systems working together makes an organism.



Example: a human<sub>47</sub>

# The Cell Theory

The cell theory (proposed independently in 1838 and 1839) is a cornerstone of biology.

All organisms are composed of one or more cells.

Cells are the smallest living things.

Cells arise only by division of previously existing cells.

All organisms living today are descendants of an ancestral cell.



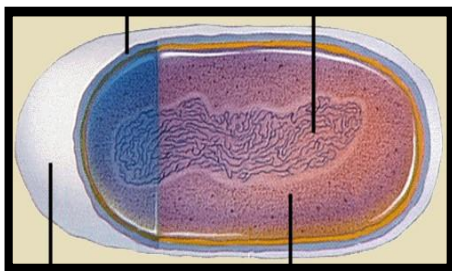
Schleiden



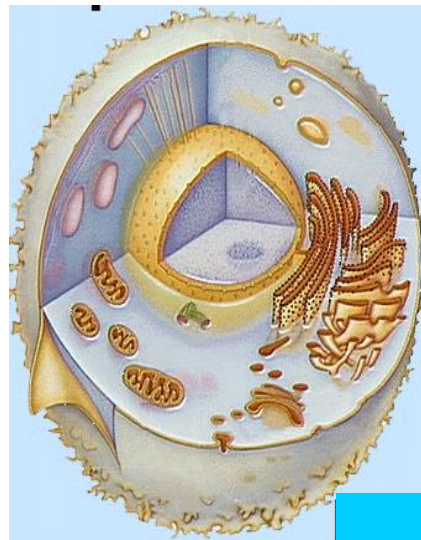Schwann

48

## Two Fundamentally Different Types of Cells









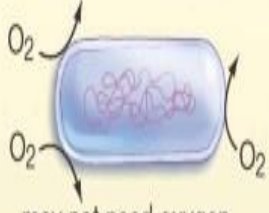



A prokaryotic cell



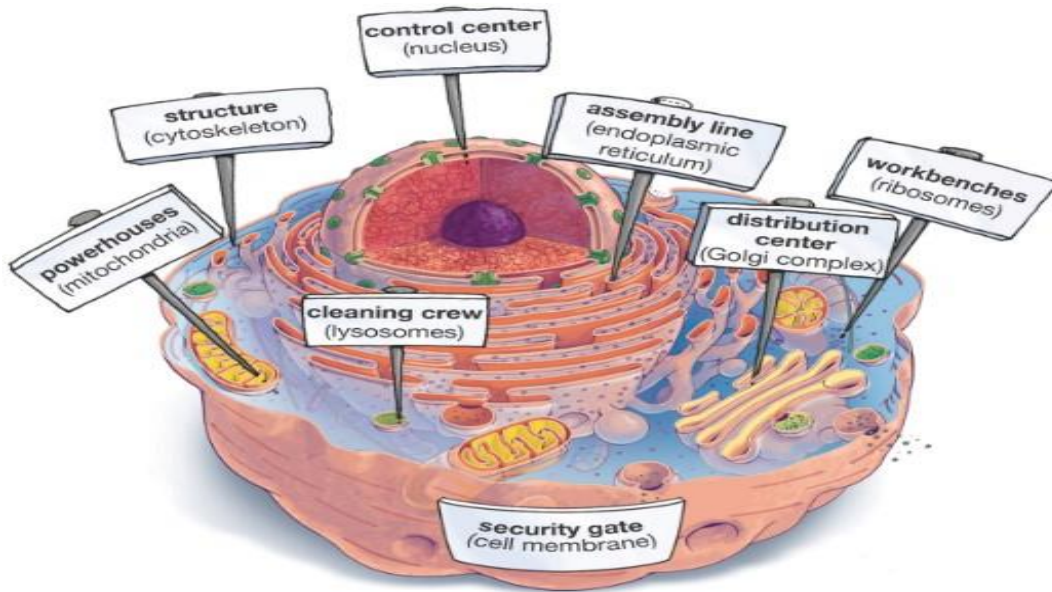
A eukaryotic cell

49

# Us vs. Them -Eukaryotes and Prokaryotes

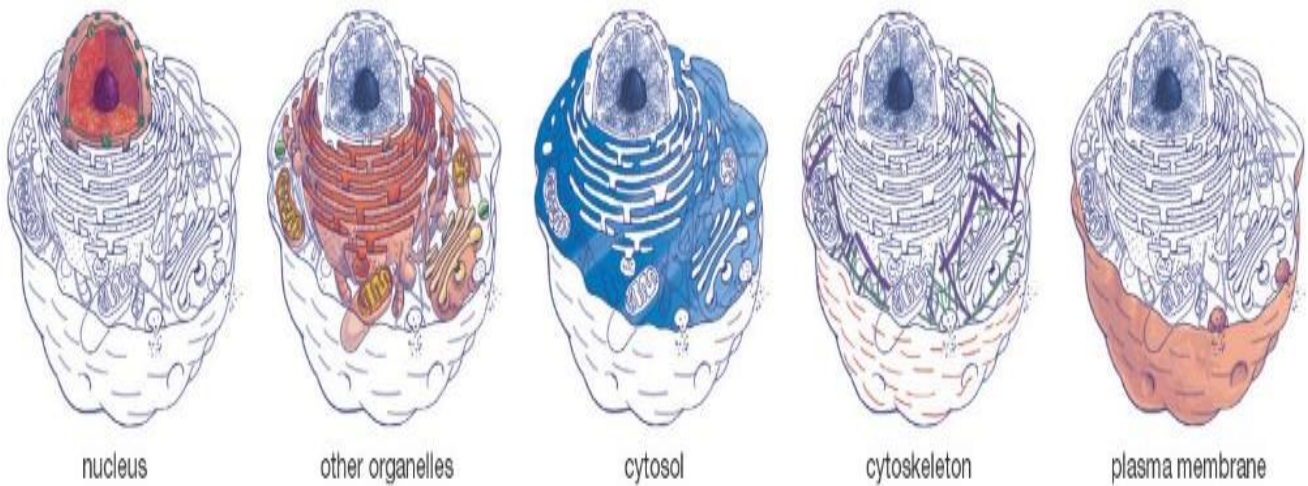
	Prokaryotes	Eukaryotes
<b>DNA</b>	 <p>in "nucleoid" region</p>	 <p>within membrane-bound nucleus</p>
<b>Size</b>	 <p>usually smaller</p>	 <p>usually larger</p>
<b>Organization</b>	 <p>usually single-celled</p>	 <p>often multicellular</p>
<b>Metabolism</b>	 <p>may not need oxygen</p>	 <p>usually need oxygen to exist</p>
<b>Organelles</b>	 <p>no membrane-bound organelles</p>	 <p>membrane-bound organelles</p>

## An Idealized Animal Cell



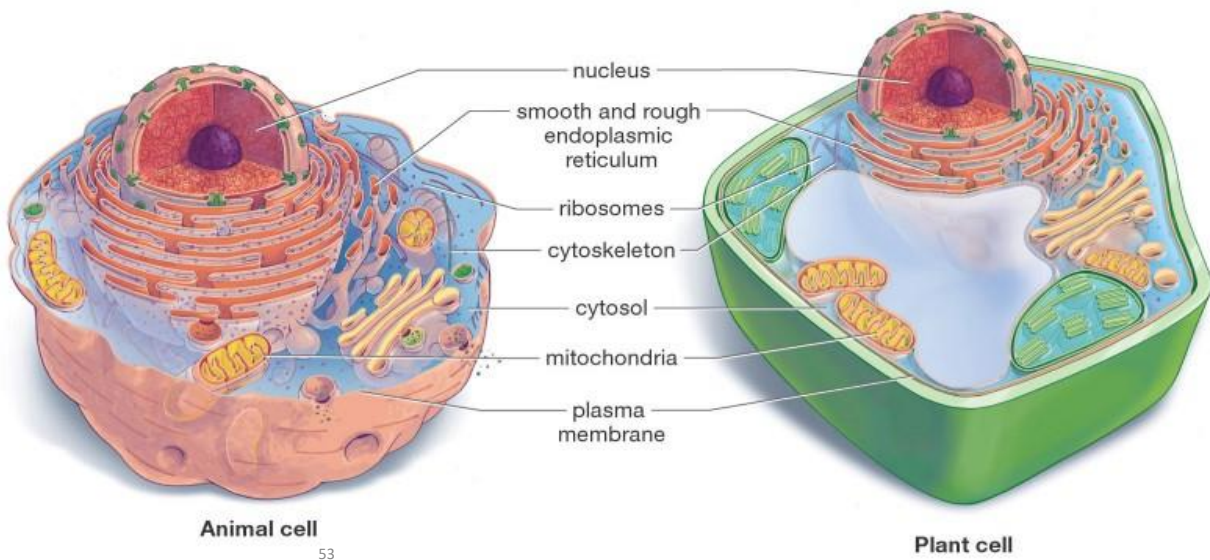
51

## Major Divisions of the Eukaryotic Cell



52

## Animal and Plant Cells Have More Similarities Than Differences



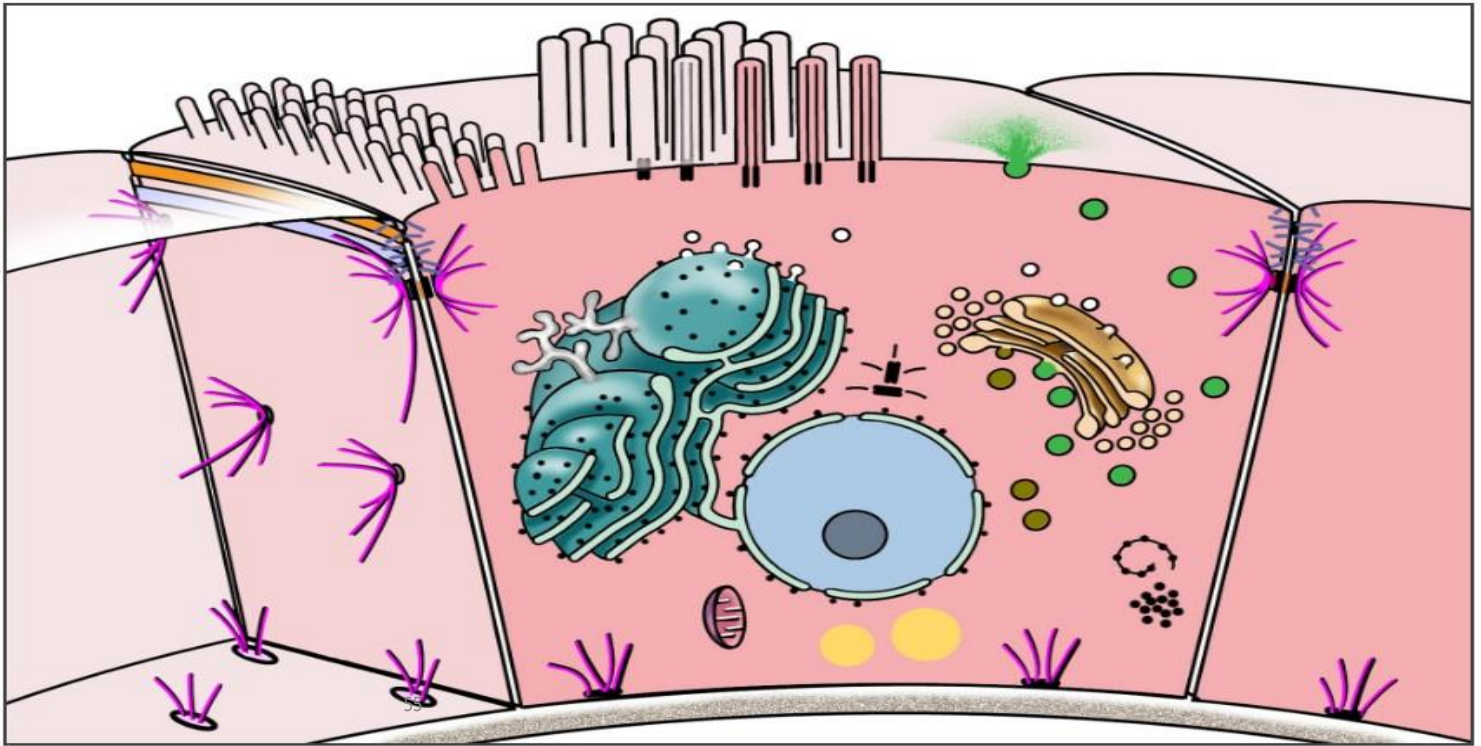
- Give the function (job) of each organelle below

- |                          |                 |
|--------------------------|-----------------|
| a. Nucleus               | e. Golgi body   |
| b. Cell membrane         | f. Vacuole      |
| c. Mitochondrion         | g. Lysosome     |
| d. Endoplasmic reticulum | h. Cytoskeleton |

54

- Overview of cell structures

- The cell consists of two major compartments, cytoplasm and nucleus. Located throughout the cytoplasm are membranous organelles, e.g., endoplasmic reticulum, lysosomes and mitochondria, as well as non-membranous organelles, e.g., polysomes and centrioles. The nucleus is surrounded by two membranes which are continuous with the endoplasmic reticulum.



- **Cells are the structural units of all living organisms .**
- Although there are approximately 200 different cell types in the body, cells are more alike than different. Specialization of function, (e.g., glandular cells for secretion or muscle cells for contraction) is really an emphasis of a function that all cells possess to some degree. In some cases, cells have become so specialized that some functions are lost altogether (e.g., cell proliferation).
- Cells vary in size and shape according to location and function .
- Cells widely vary in diameter, from the largest, the mature human ovum (120 microns) to the smallest, the red blood cell (7-8 microns).
- Cells vary in internal structure depending upon their function. Specialized cells possess abundant internal structures related to their specific function, e.g., contractile filaments in muscle cells or secretory granules in gland cells.
- Cells vary in their life history, for example, rates of cell renewal.

## **Functions of cells**

As you already know that a cell is a structural and functional unit of living. Let us study 6 of the most vital functions performed by a cell.

### **1- Structure and Support**

You know a house is made of bricks. Similarly, an organism is made up of cells. Though there are certain cells such as collenchyma and sclerenchyma are present for offering structural support however in general too, all cells generally provide the structural basis of all organisms.

### **2- Growth**

In complex organisms such as humans, the tissues grow by simple multiplication of cells. Hence, cells are responsible for the growth of the organism. The entire thing takes place via a process of mitosis.

### **3- Transport**

Cells import the nutrients that are used in the different chemical process which take place inside them. As a result of these processes, a waste product is produced. Cells then work to get rid of this waste. In this manner, the small molecules like such as oxygen, carbon dioxide, and ethanol pass through the cell membrane by

diffusion. This method is known as passive transport. On the other hand, the larger molecules like the proteins and polysaccharides, go in and out of the cell via active transport.

#### **4- Energy Production**

Organisms need energy to perform different chemical reactions. In plants, the energy comes from the process of photosynthesis while in the animals the energy comes via respiration.

#### **5- Metabolism**

Cell is responsible for metabolism that includes all the chemical reactions that take place inside an organism to keep it alive.

#### **6- Reproduction**

A cell helps in reproduction by the processes of mitosis (in more evolved organisms) and meiosis.

- **Chemical Composition of the Cell**

Chemical compounds in the cell can be divided into two major groups: Organic and Inorganic compounds

**Organic compounds** are chemical compounds that contain the element carbon. Organic compounds in the cell include carbohydrates, protein, lipids and nucleic acids. Some of these compounds are synthesized by the cell itself.

**Water** is an inorganic compound which is composed of hydrogen and oxygen. It is an important compound in the cell.



Table : inorganic chemical compounds in the cell.

Percentage of Body Weight	Element	Usage
65%	Oxygen	This element is obviously the most important element in the human body. Oxygen atoms are present in water, which is the compound most common in the body, and other compounds that make up tissues. It is also found in the blood and lungs due to respiration.
18.6%	Carbon 60	Carbon is found in every organic molecule in the body, as well as the waste product of respiration (carbon dioxide). It is typically ingested in food that is eaten.

9.7%	Hydrogen	Hydrogen is found in all water molecules in the body as well as many other compounds making up the various tissues.
3.2%	Nitrogen	Nitrogen is very common in proteins and organic compounds. It is also present in the lungs due to its abundance in the atmosphere.
1.8%	Calcium	Calcium is a primary component of the skeletal system, including the teeth. It is also found in the nervous system, muscles, and the blood.
1.0%	Phosphorus	This element is common in the bones and teeth, as well as nucleic acids.
0.4%	Potassium	Potassium is found in the muscles, nerves, and certain tissues.
0.2%	Sodium	Sodium is excreted in sweat, but is also found in muscles and nerves.
0.2%	Chlorine	Chlorine is present in the skin and facilitates water absorption by the cells.
0.06%	Magnesium	Magnesium serves as a cofactor for various enzymes in the body.
0.04%	Sulfur	Sulfur is present in many amino acids and proteins.
0.007%	Iron	Iron is found mostly in the blood since it facilitates the transportation of oxygen.
0.0002%	Iodine	Iodine is found in certain hormones in the thyroid gland.

- **The Importance of Organic Compounds in the Cell**

- **Carbohydrates**

- Supply energy for cell processes
- A means of storing energy
- Give structural support to cell walls

- **Lipids**

- Store large amounts of energy over long periods of time
- Act as an energy source
- Play a major role in the structure of the cell membranes
- Act as a source of metabolic water
- Reduce the loss of water by evaporation

62

- **Proteins**

- Act as building blocks of many structural components of the cell ; required for growth
- Form enzymes which catalyze chemical reactions
- Form hormones which control growth and metabolism

- **Nucleic acids**

- Contain the genetic information of cells
- Play a vital role in protein synthesis

63

- **The importance of water in the cell**

- Water is important for life because its chemical and physical properties allow it to sustain life.
- Water is a polar molecule which consists of 2 hydrogen atoms and 1 oxygen atom. A polar molecule is a molecule with an unequal distribution of charges. Each molecule has a positively charged and a negatively charged end. Polar molecules attract one another as well as ions. Because of this property, water is considered the solvent of life.
- It is the transport medium in the blood.
- It acts as a medium for biochemical reactions
- Water helps in the maintenance of a stable internal environment within a living organism. The concentration of water and inorganic salts that dissolve in water is important in maintaining the osmotic balance between the blood and interstitial fluid.
- It helps in lubrication
- Water molecules have very high cohesion. Water molecules tend to stick to each other and move in long unbroken columns through the vascular tissues in plants.<sup>64</sup>

## Quick review

**Definition of a cell**

Smallest functional unit within a living organism that can function independently

**Components**

Plasma membrane, cytoplasm, nucleus, membranous organelles, non-membranous organelles

**Membranous organelles**

Nucleus, Endoplasmic reticulum, Golgi apparatus, mitochondria, peroxisomes, lysosomes, transport vesicles

**Non-membranous organelles**

Ribosomes, microtubules, cytoskeleton (actin filaments, intermediate filaments, centrioles)

65

- ✓ The cell is the structural and functional unit of all tissues. It consists of a mass of protoplasm divided into nucleus and cytoplasm. The cytoplasm is the part of protoplasm located around the nucleus designed to perform synthetic and metabolic activities.
- ✓ The cytoplasmic matrix (cytosol) is the non-organelle component of the cytoplasm occupying the intracellular spaces between organelles and inclusions. It contains any soluble proteins, lipids, carbohydrates and small ions.
- ✓ Cytoplasmic Organelles

They are permanent, living cytoplasmic structures that perform specific functions. Two types of cytoplasmic organelles are recognized: membranous and non-membranous organelles.

### ► **Membranous organelles**

The membranous organelles are cytoplasmic organelles that possess a bounding membrane of their own and they include cell membrane, mitochondria, endoplasmic reticulum, Golgi apparatus, lysosomes, and peroxisomes.

#### **1- Cell membrane**

The cell membrane (plasmalemma or plasmamembrane) is the outer membrane of the cell that acts as a barrier between its internal and external environment.

With light microscope (LM) it is too thin (8-10 nm) to be seen. The cell boundary that is often seen is mainly due to condensation of cytoplasm on the inner aspect of the cell membrane, condensation of the stain (such as silver or PAS) on the carbohydrate-rich coat and obliquity of the sections.

With electron microscope (EM) it appears as a trilaminar structure consisting of outer and inner electron-dense layers separated by an intermediate electron-lucent layer.

## **The molecular structure of the cell membrane**

The most recent and currently acceptable model for the cell membrane is the

### **Fluid mosaic model**

According to this model, the cell membrane is made up of three major components phospholipids, proteins, and carbohydrates.

The phospholipids molecules form a central bimolecular layer. Each molecule is formed of two ends; polar or hydrophilic (has affinity with water) end, and non-polar or hydrophobic (has no affinity with water) tail. The phospholipids molecules are arranged with their hydrophilic ends are directed outward, while hydrophobic tails are directed inward toward the center of the membrane.

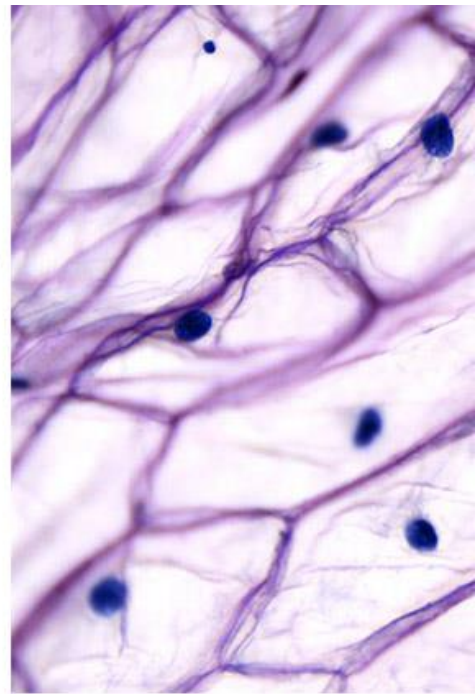
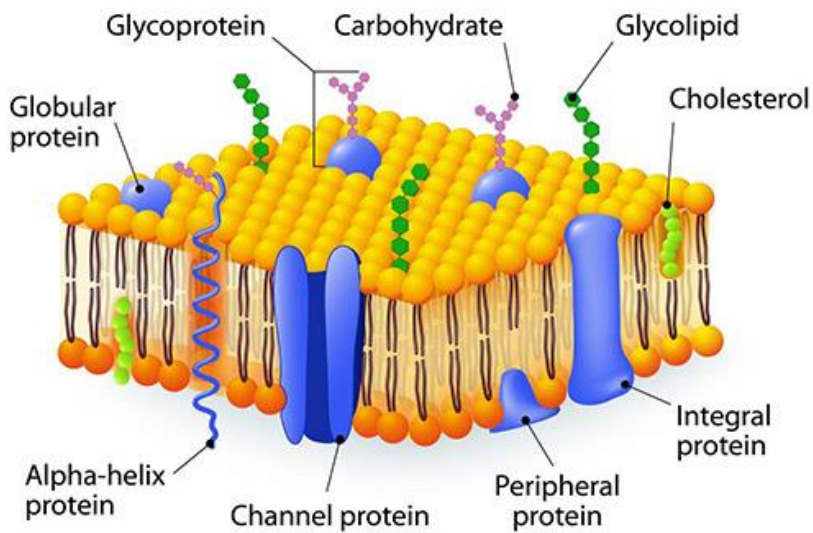
The protein is the second major constituent of the cell membrane. The protein molecules are arranged as globules moving freely within the lipid layer. Two types of protein globules are recognized: intrinsic or integral protein and extrinsic or peripheral proteins.

The intrinsic proteins are firmly attached to the lipid bilayer. Some of them extend throughout the entire thickness of the membrane and constitute transmembrane channels for the passage of water-soluble ions and molecules

The extrinsic or peripheral proteins are only partially embedded to either aspect of the membrane.

The carbohydrate fractions are conjugated with the protein (glycoprotein) and lipid (glycolipid) molecules of the cell membrane. These glycoproteins and glycolipids project from the outer surface of the cell membrane as cell coat or glycocalyx.

# CELL MEMBRANE



## Functions of the cell membrane

The cell membrane is the part of the cell that regulate the exchange of molecules and ions between its internal and external environment. This occurs by several ways:

1. **Passive Diffusion:** this involves the entrance of small molecules into the cytoplasm. It depends on the presence of a concentration gradient across the plasmalemma (e.g., diffusion of lipid soluble substances, oxygen, CO<sub>2</sub>, water and small ions).
2. **Facilitated Diffusion:** this type of diffusion is also concentration-dependent and involves the transport of large water-soluble molecules such as glucose and amino acids. It requires the presence of carriers to which the molecules have to bind in order to pass through the plasmalemma.
3. **Active Transport:** this process requires the utilization of energy provided as ATP. (e.g., sodium-potassium pump).
4. **Selective transport:** it depends on the presence of specific cell surface receptors to pick up specific molecules into the cytoplasm (e.g., hormones).

## 5. Endocytosis and Exocytosis

Endocytosis involves either the engulfment of solid particles (phagocytosis) or minute droplet of fluid (pinocytosis). The engulfed material is surrounded first by cytoplasmic extensions called pseudopodia. When the particles become surrounded, the plasma membrane fuses and the membrane surrounding the engulfed particles forms a vesicle, known as a phagosome or endocytotic vesicle, which detaches from the cell membrane to float freely within the cytoplasm.

Once the phagosome enters the cytoplasm it fuses with the lysosomes and their contents are subjected to enzymatic digestion.

## 6. Exocytosis

Exocytosis (Exo = out) is the process by which some membranous vesicles located within the cytoplasm fuse with the plasma membrane and release their contents outside the cell. It occurs in many secretory processes.

### **Functions of the cell coat (Glycocalyx)**

- Mechanical and chemical protection the cell membrane.
- Aids in the induction of immunological (antigen-antibody) response.
- Site for binding of hormones.
- Shares in the formation of intercellular adhesions.
- Contributes to the formation of the basement membrane.
- Cell recognition.

### **Other functions of the cell membrane include**

- Transmission of nerve impulses in muscle and nerve cells.
- Myelin sheath formation (Schwan cell around peripheral nerves).
- Share in the formation of microvilli, cilia, flagella and cell junctions.



## 2- Mitochondria

Mitochondria are membranous organelles involved primarily in cell respiration and energy production.

With LM, they appear as granules, rod-like or thread-like. Their size range from 5-10  $\mu\text{m}$  length and 0.5-1  $\mu\text{m}$  in diameter. The number is highly variable according to the energy requirements of the cells. Liver cells (active cells) contain as many as 1000 mitochondria. Small lymphocytes (inactive cells) contain very few.

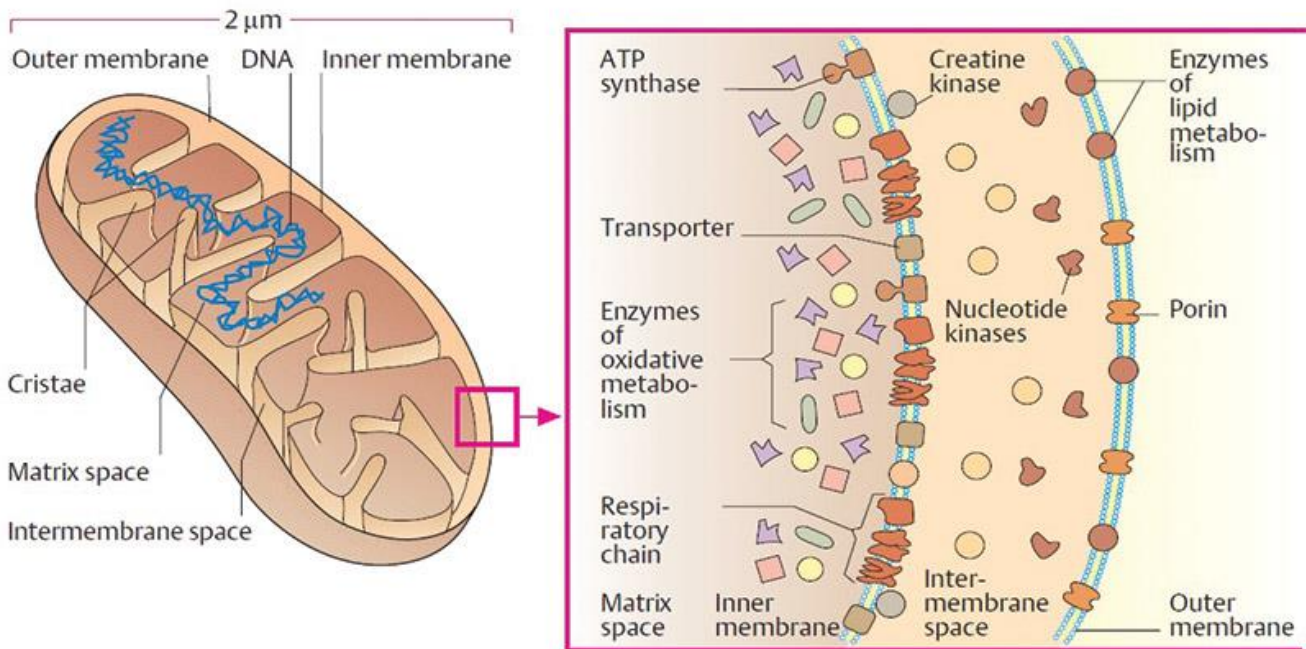
They are motile organelles and localize at intracellular sites of high-energy requirements such as basal regions of ion-transporting cells.

They could be selectively stained with iron hematoxylin, Janus green B in supravital staining of living cells.

With EM, they appear as ovoid or elongated structures bounded by two membranes. The outer membrane is smooth. The inner membrane is thrown into folds called cristae projecting into the inner cavity that is filled with an amorphous substance called matrix. The number of the cristae seen in mitochondria is directly related to the energy requirement of cell.

The inner membrane is covered with tiny spherical projections about 9  $\mu\text{m}$  in diameter supported at narrow stalks. These are called inner membrane spheres or elementary particles and are believed to represent an enzyme known as F<sub>1</sub>, which couple electron transport to the phosphorylation of ADP.

The mitochondrial matrix is also containing many electron-dense granules called matrix granules that are the sites for Ca<sup>++</sup> ions storage. The mitochondrial matrix contains DNA and RNA that explain the mitochondrial ability to grow, divide and synthesis some of their proteins.



## Functions

- They house the chains of enzymes that catalyze reactions that provide the cells with most of its ATP (adenosine triphosphate).
- On demands, the ATP yields its high-energy phosphate bond to another molecule and become transformed into ADP.
- Within the mitochondrial matrix, ADP is transformed again into ATP. These processes take place within the mitochondrial matrix and inner mitochondrial membranes.
- The matrix contains enzymes of Krebs cycle and fatty acid oxidation. The inner membrane contains the cytochromes and the enzymes involved in ATP production.
- Due to their role in energy production, the mitochondria are likened to powerhouses of the cells.
- Participate in regulation of calcium level within the cytosol.

### 3- Endoplasmic reticulum (ER)

The Endoplasmic reticulum (Endo=inside; plasm=cytoplasm; reticulum = network) is an irregular network of branching and anastomosing tubules, cisternae and vesicles. Two types of ER are recognized, rough and smooth.

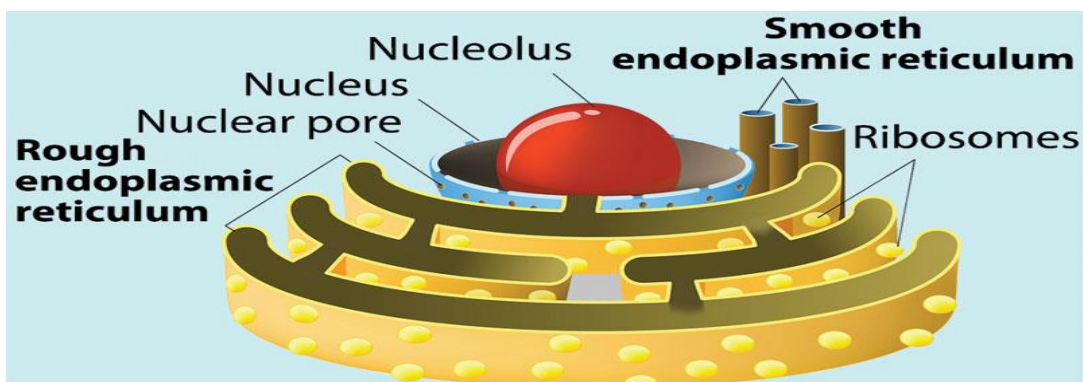
#### Rough endoplasmic reticulum (rER)

The rough endoplasmic reticulum is a membranous organelle concerned principally with synthesis and secretion of proteins. It is called rough due to the presence of large number of ribosomes attached to its limiting membrane. With LM, it appears as basophilic cytoplasmic areas that are referred to as the ergastoplasm or chromidial substances. The cytoplasmic basophilia may be diffuse (plasma cells), localized (pancreatic acinar cells) or arranged into clumps (Nissl granules in nerve cells) . Aggregates of rER appear basophilic mainly due to the presence of ribosomes on their outer surface .

With EM, it consists of an anastomosing network of tubules, vesicles and flattened cisternae that ramifies throughout the cytoplasm. Much of the surface of the rER is studded with ribosomes giving the reticulum a rough or granular appearance.

#### Functions:

- Synthesis of proteins for extracellular use (secretory proteins, lysosomal proteins and membrane proteins).
- Glycosylation of proteins to form glycoproteins.



## **Smooth endoplasmic reticulum (sER)**

The smooth endoplasmic reticulum is a membranous organelle consists primarily of a network of branching and anastomosing tubules and vesicles.

It differs from the rER in that its limiting membrane is smooth and devoid of ribosomes. With LM, it does not appear. The cytoplasm of the cells contained abundant sER usually appears acidophilic.

With EM, it appears as irregular network of membranous tubules and vesicles devoid of ribosomes in contrast to the flattened ribosome-studded cisternae of rER. The sER tubules may be continuous with those of rER and Golgi apparatus .

### **Functions**

- Steroid hormone synthesis in the testicular interstitial cells, the cells of the corpus luteum and adrenal cortex cells.
- Drug detoxification in liver cells.
- Lipid synthesis in the intestinal absorptive cells.
- Release and storage of  $\text{Ca}^{++}$  ions in striated muscle cells.
- Production of HCL in gastric parietal cells.

### **4- Golgi Apparatus (Golgi complex)**

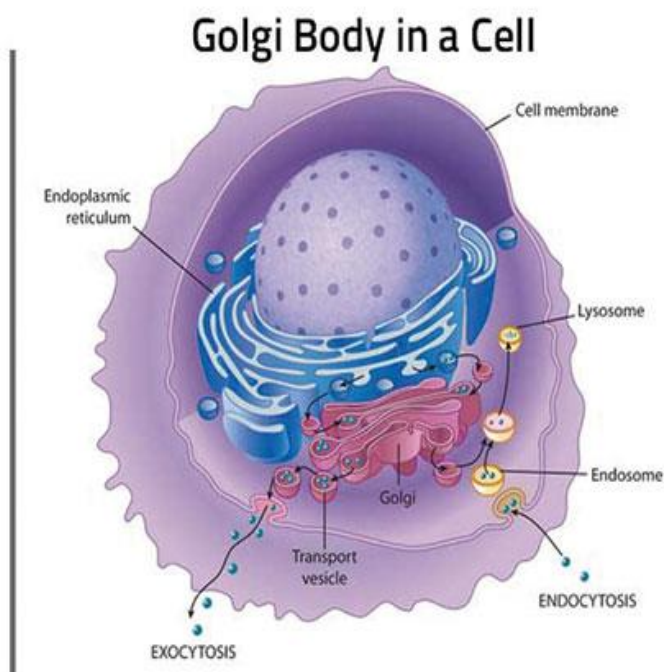
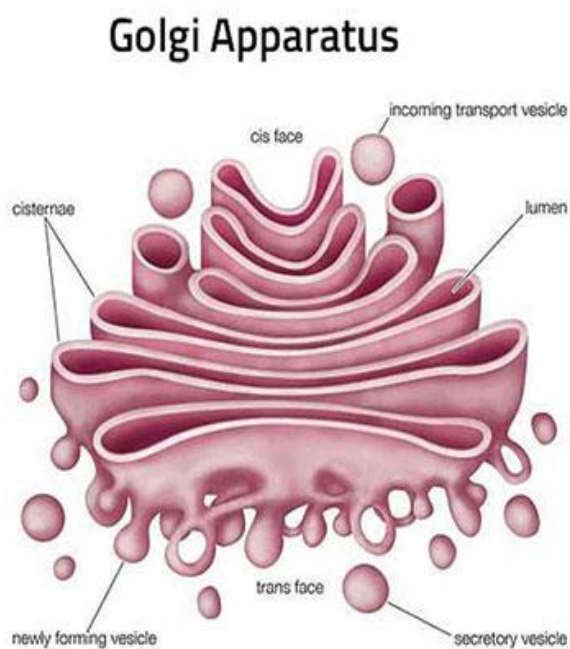
The Golgi apparatus is a membranous organelle concerned principally with synthesis, concentration, packaging and release of the secretory products.

With LM, it can be selectively stained with silver salts or osmium where it appears as a black network located near the nucleus. In H&E sections, it may be visible as a lighter-stained region called negative Golgi image. It is seen to great advantage in secretory cells such as osteoblasts.

With EM, the main structure unit of the Golgi apparatus is a flattened membranous vesicle called Golgi saccule.

The Golgi saccules are arranged in Golgi stacks that contain from 3-10 saccules. Most cell types possess several stacks of Golgi saccules forming an elaborate ramifying network termed the Golgi complex.

Each stack of saccules has 1) a forming face or Cis face that is convex in shape. 2) a maturing face or trans face that is concave. The Cis face is usually associated with a number of small transfer vesicles. The trans face characterized by being associated with much larger secretory granules.



## Functions

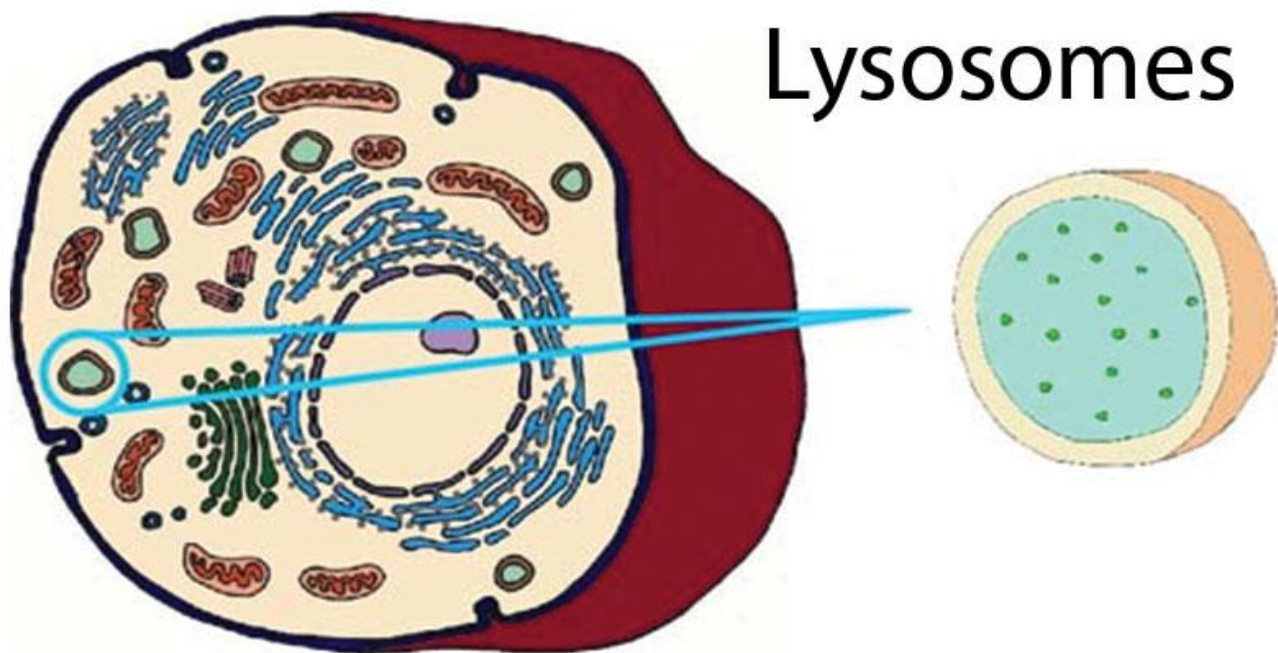
- Packaging and concentration of secretions.
- Modification of the secretory products such as glycosylation and sulfation of proteins to form glycoproteins and sulfated glycoproteins (mucus).
- Production of primary lysosomes.

## 5- Lysosomes

They are membrane-bounded vesicles (0.2-0.4 $\mu$ m) containing a number (more than 40) of hydrolytic enzymes that are active at acid pH (acid hydrolases) maintained within their interior. This group of enzymes can destroy all the major macromolecules (e.g., proteins and lipids) of the cells.

LM provides no direct evidence for the existence of lysosomes. The lysosomes are resolved at the LM level when their enzyme contents (e.g., acid phosphatase) are stained by histochemical methods.

With EM, the lysosomes appear as spherical membrane-bounded vacuoles with their contents showing varying degree of electron density.



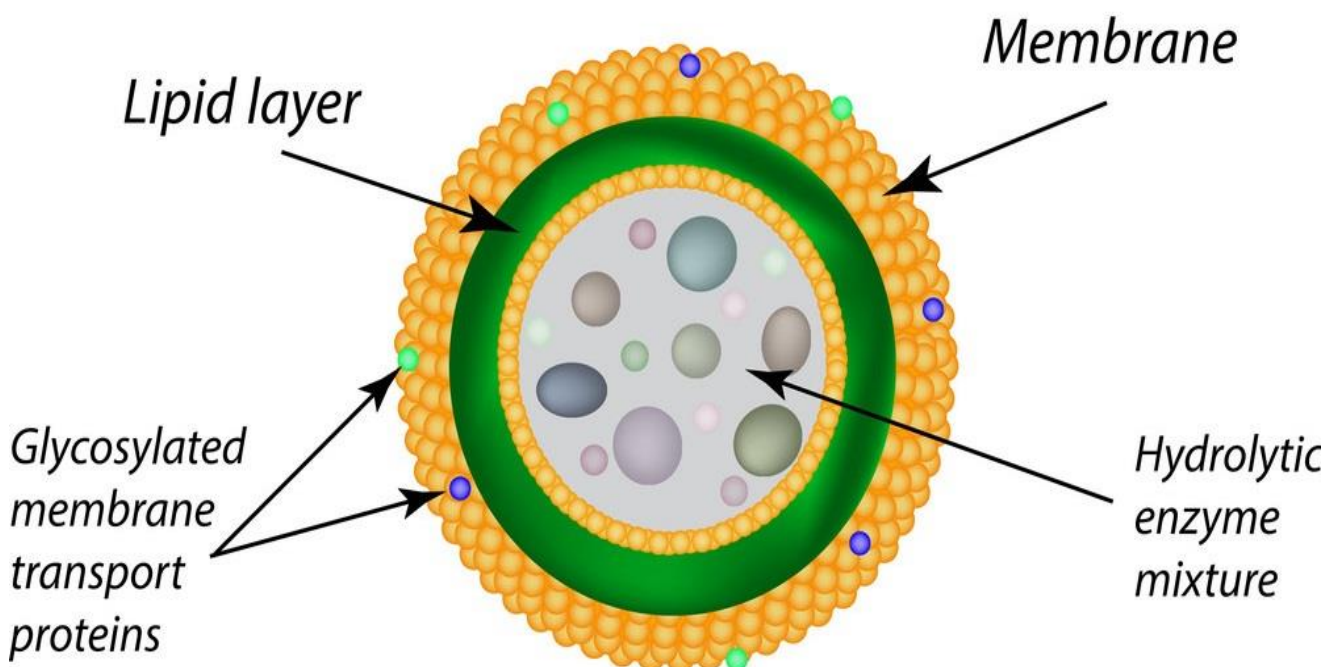
### Types of lysosomes

Primary lysosomes are lysosomes freshly formed from the Golgi or sER. They contain nothing but hydrolytic enzymes.

Secondary lysosomes formed as the result of fusion of primary lysosomes with phagosomes. A phagosome is a membrane-bounded vesicle containing either exogenous material (e.g., bacteria) and it is called heterophagosome or endogenous material (e.g., damaged organelle) and it is called autophagosome.

Multivesicular bodies are spherical forms of heterophagosomes. They are membrane-bounded vesicles containing a number of smaller vesicles.

Residual bodies are debris containing vacuoles representing the terminal stage of lysosomal activities. Their contents may either be extruded from the cell by exocytosis or accumulate in the cytoplasm as lipofuscin pigments.



### **Functions**

- Degradation of any exogenous macromolecules (phagocytosis and pinocytosis).
- Disposition of any organelles or cell constituents that are no longer useful to the cell (autophagy).

## 6- Peroxisomes

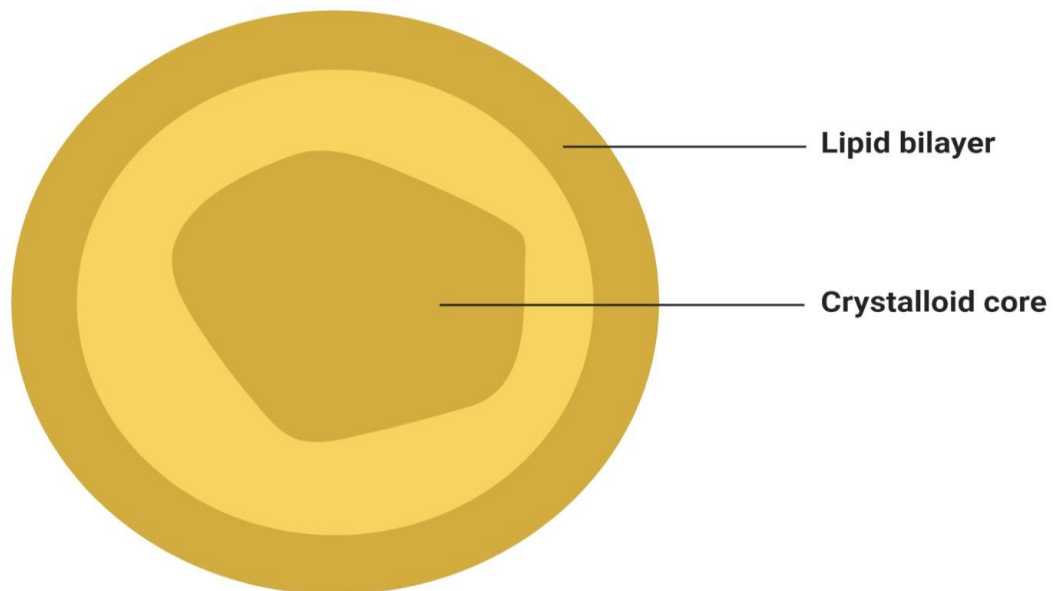
Peroxisomes are spherical, membrane-bounded organelles containing peroxide forming enzymes and catalase that are involved in the formation and degradation of intracellular hydrogen peroxide.

With LM, it does not appear. With EM, they are membrane-bounded vacuoles, vary in size and appearance depending on species and cell types. They are relatively large in hepatocytes and kidney cells and small in intestinal cells (microperoxisomes).

In human cell, they contain finely granular matrix of moderate density. In many other species, they have crystalline core called a nucleoid.

Such nucleoid is absent from liver peroxisomes from reptiles, birds, and human being which are species that lack urate oxidase, an enzyme that degrades urates.

### Peroxisome



**Figure: Peroxisome**, Image Copyright © Sagar Aryal, [www.microbenotes.com](http://www.microbenotes.com)



## Functions

- Peroxisomes contain at least three oxidase (D-amino acid oxidase, urate oxidase and catalase).
- The D-amino acid oxidase, urate oxidases are responsible for the production of hydrogen peroxide (H<sub>2</sub>O<sub>2</sub>).
- The catalase then utilizes the H<sub>2</sub>O<sub>2</sub> in oxidation (and therefor, detoxification) of various toxic substances such as phenol, alcohol and fatty acids.

### 1. Non-membranous organelles

They are cytoplasmic organelles that possess no bounding membrane of their own. They include ribosomes, and centrioles.

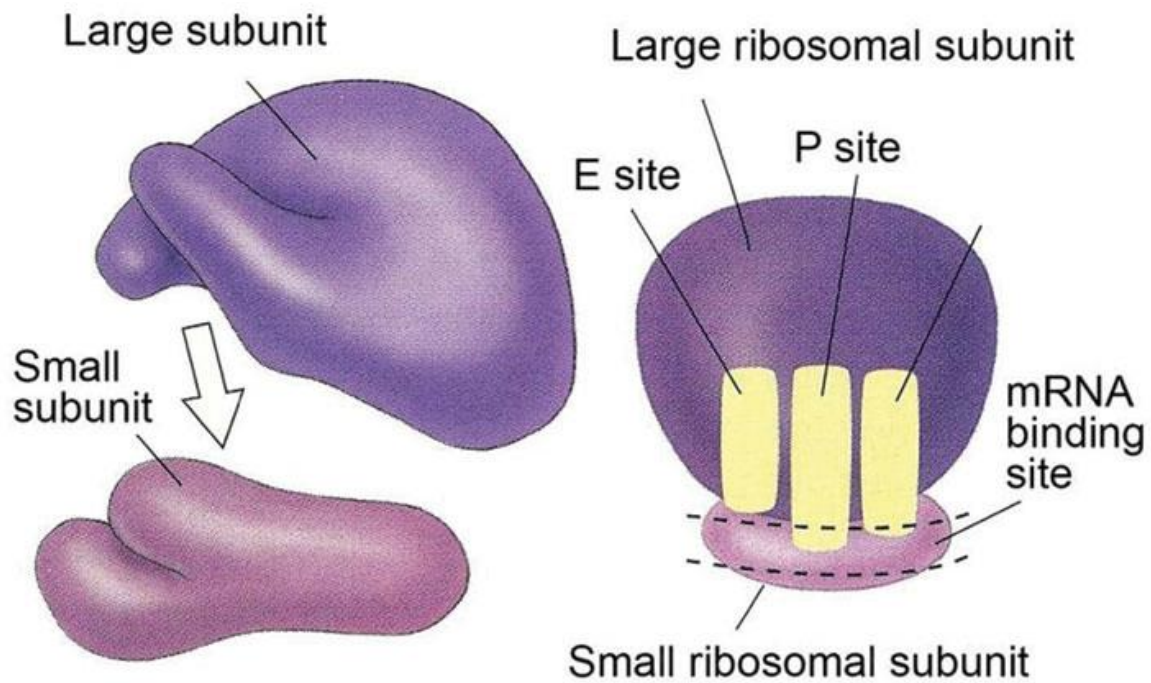
## 7- Ribosomes

They are rounded ribonucleoprotein particles, 20-30 nm in diameter that provide the intracellular sites where amino acids are linked together to form polypeptide chains (proteins).

With LM they are too small to be seen. However, cell containing abundant ribosomes usually has basophilic cytoplasm. Such cytoplasmic basophilia is largely due to the strong affinity of rRNA for hematoxylin.

With EM, the ribosomes are seen free in the cytoplasm either as separate entities or attached to messenger RNA molecules in small aggregation called polyribosomes or polysomes. Polyribosomes may also be attached to the surface of rER.

Each ribosome composed of a large and a small subunit that are made of rRNA and different types of proteins.



## Functions

Free ribosomes are responsible for synthesis of proteins for internal use (cytoplasmic proteins and enzymes).

Attached ribosomes are responsible for synthesis of proteins for external use (secretory or lysosomal enzymes).

## 8- Centrosome and Centrioles

The centrosome is a specialized zone of cytoplasm contains a pair of centrioles together known as a diplosome, spherical bodies, procentrioles organizer and centriolar satellites that function as microtubular organization center.

With LM, the centrioles are selectively stained with iron hematoxylin where they appear as two tiny dots located close to the nucleus. In some epithelial cells,

centrioles are located in the apical cytoplasm immediately beneath the ciliated surface. Such apical centrioles are called basal bodies and from which cilia originate.

With EM, each centriole is a hollow cylinder, closed at one end. The two centrioles of each diplosome are arranged with their long axes at right angles to each other. The wall of each centriole is made up of nine triplet of parallel microtubules connected to each other by fine filaments, the protein link.

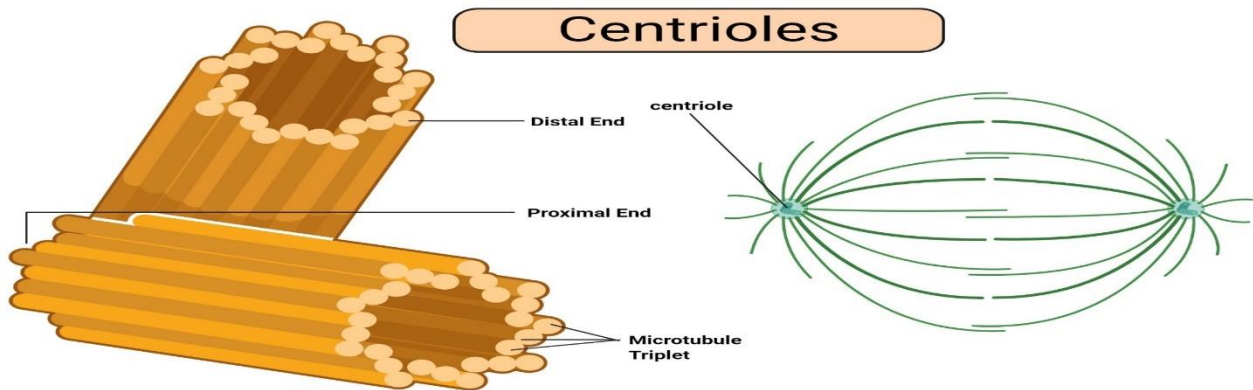


Figure: Centrioles, Image Copyright © Sagar Aryal, www.microbenotes.com

## Functions

Formation of mitotic spindle during cell division.

Microtubular organization center

Ciliogenesis by the formation of procentrioles from the procentrioles organizer.

## 9- Cytoskeleton

### Cytoskeleton

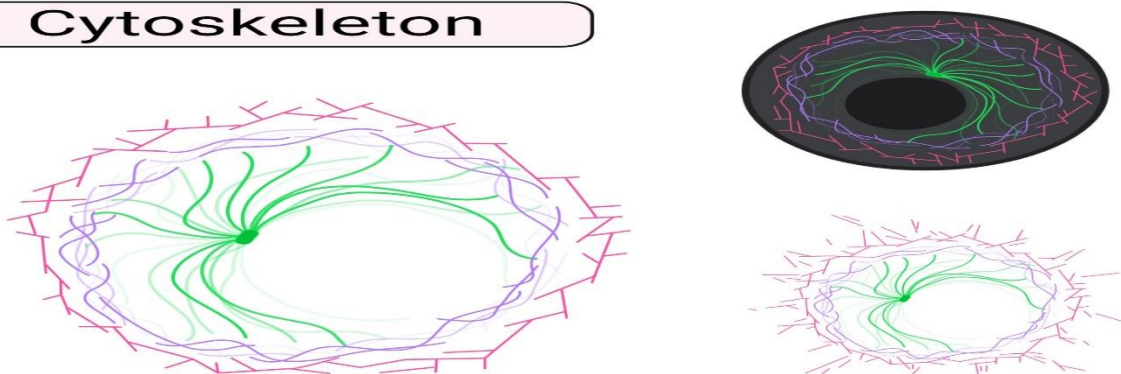
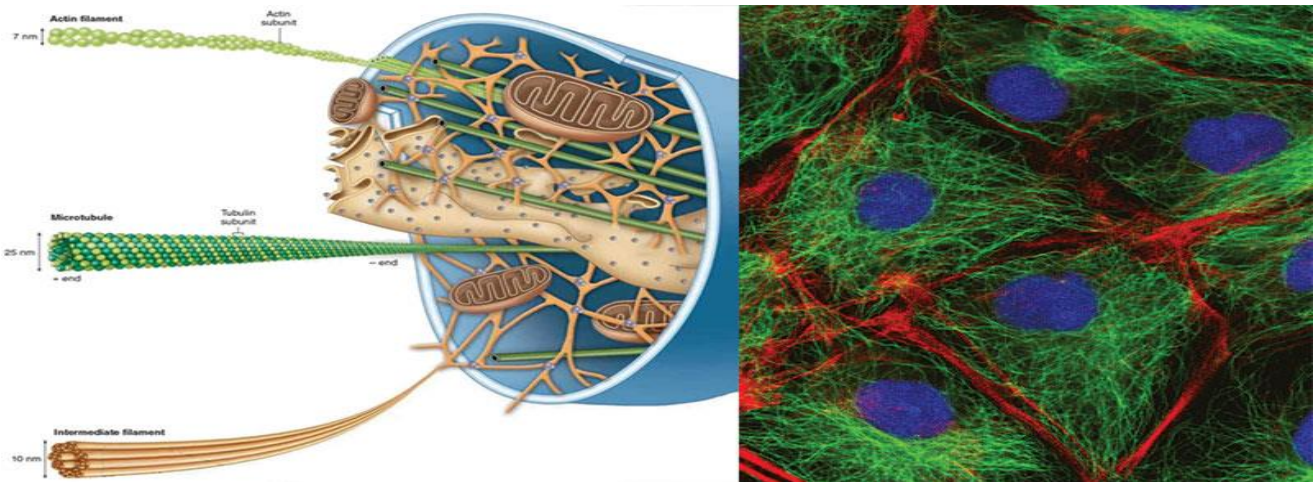


Figure: Cytoskeleton, Image Copyright © Sagar Aryal, www.microbenotes.com

The cytoskeleton is a complex network of minute filaments and tubules located within every cell, that maintain cell shape and stability and are responsible for some cell functions. It includes cytofilaments and microtubules.



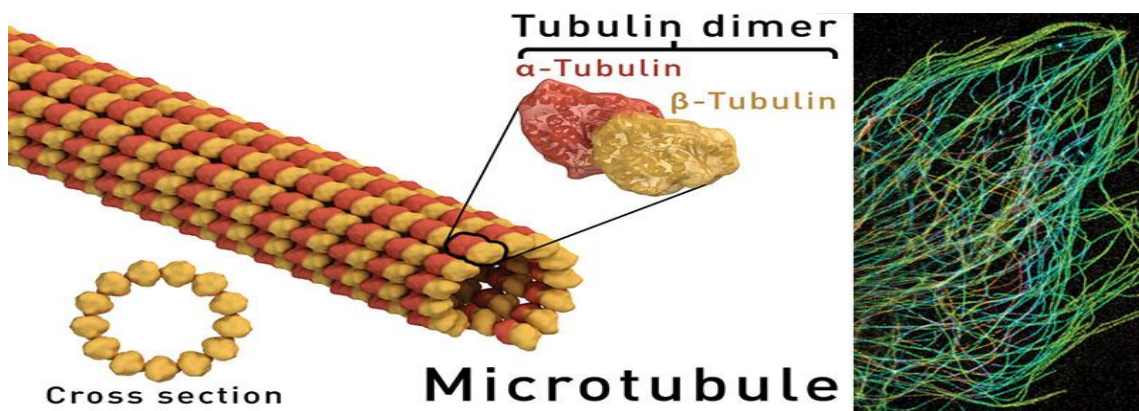
**Cytofilaments:** are minute thread-like structures of three types:

The Actin (thin filaments) is found in muscle cell, in the core of each microvillus, in motile cells such as macrophages and in developing nerve cells. Their diameter is about 5 nm.

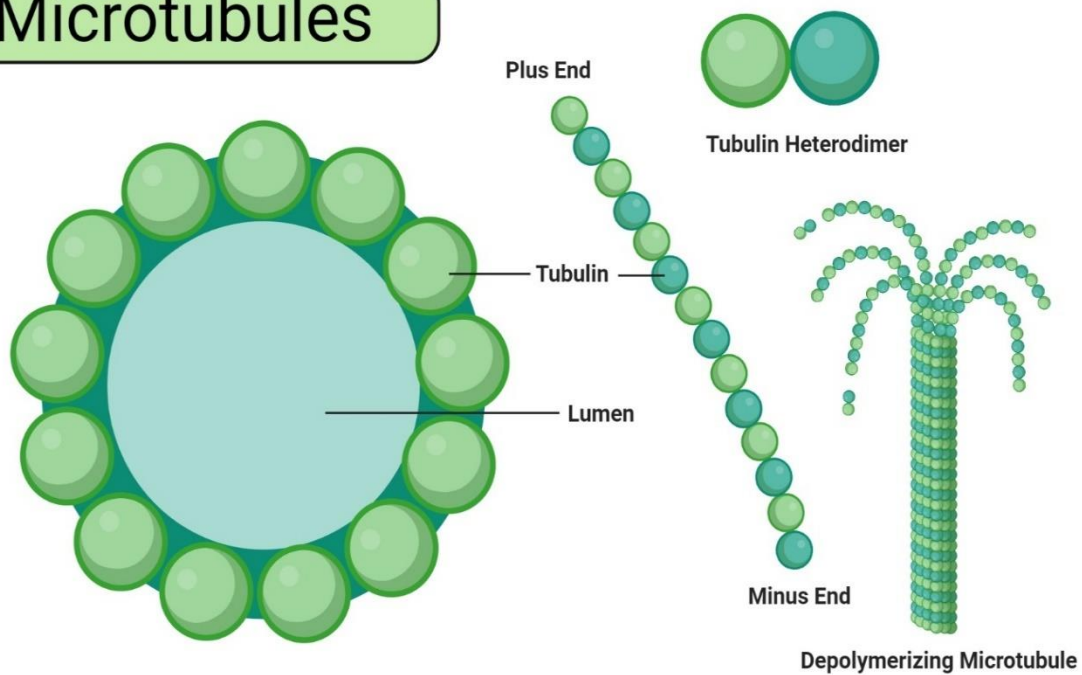
The Myosin (thick filaments) occurs mainly in muscle cells in association with actin filaments. They have a diameter of 15 nm.

The Intermediate filaments are 10 nm in diameter and include neurofilaments in neurons, glial filaments in astrocytes and tonofilaments in epithelial cells.

## Microtubules



# Microtubules



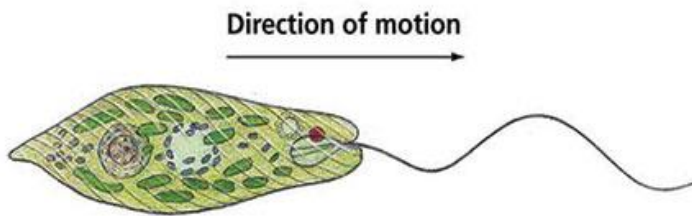
**Figure: Microtubules**, Image Copyright © Sagar Aryal, [www.microbenotes.com](http://www.microbenotes.com)

They are hollow tubular structures of variable length with a constant diameter of 25nm. Microtubules are stable permanent structures in cilia, flagella, centrioles and basal bodies. Each microtubule is made up of protein molecules (tubulin) that appear to organize into protofilaments that run parallel to the length of the tubule. A total of 13 protofilaments comprise the wall of a microtubule.

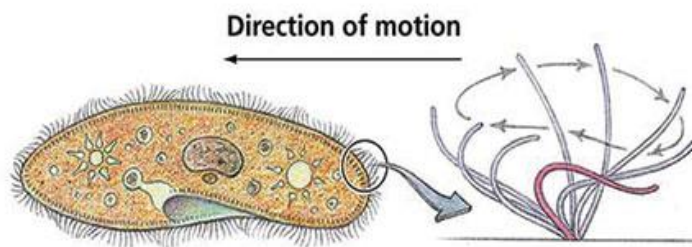
## Functions of the cytoskeleton

- It provides the structural support for the plasmalemma, cellular organelles and some cytosol enzyme system.
- It provides the means for the movement of intracellular organelles within the cytoplasm.

- It plays an essential role in cell motility as well as provides the framework of motile structures such as cilia and flagella.
- It is responsible for contractility of the muscle cells.
- It plays an important role in epithelial cell adhesion as well as cell division.

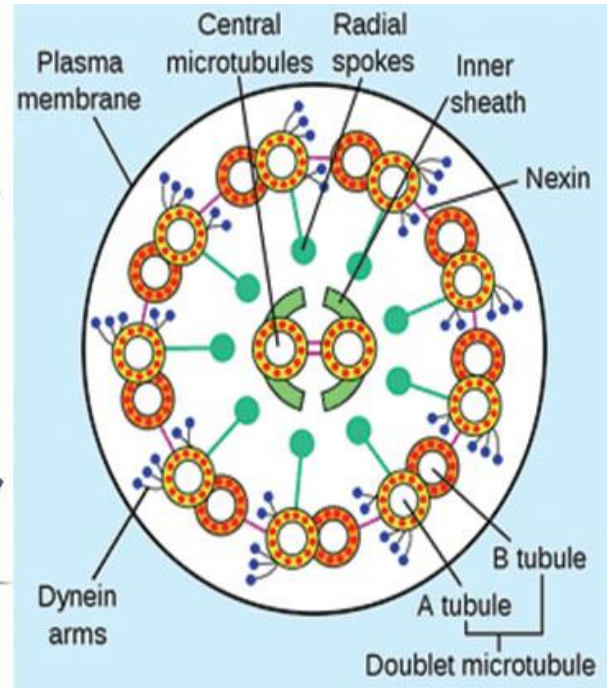


**(a) Flagella**



**(b) Cilia**

Copyright © 2006 Pearson Education, Inc., publishing as Benjamin Cummings.



# Cilia and Flagella

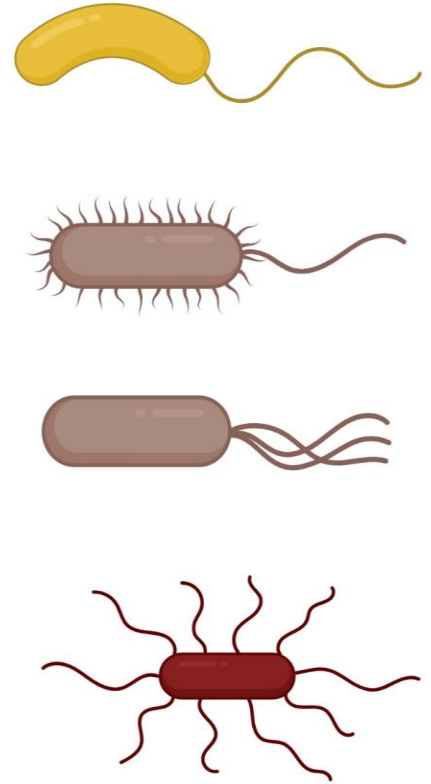
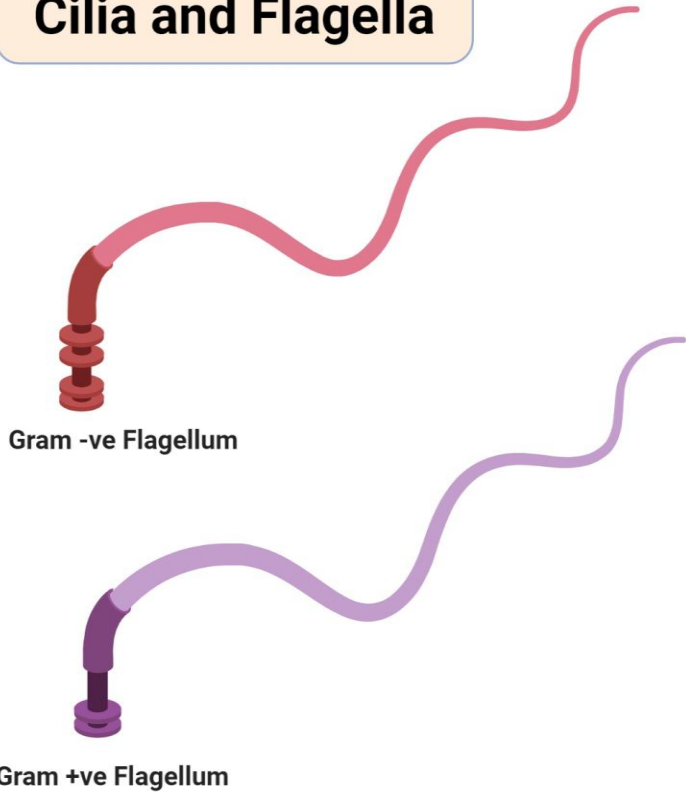


Figure: Cilia and Flagella, Image Copyright © Sagar Aryal, www.microbenotes.com

	Microfilaments	Microtubules	Intermediate filaments
<b>1- diameter</b>	7 nm.	25 nm.	10 nm.
<b>2- LM</b>	Seen only by immunohistochemistry.	Seen only by immunohistochemistry	Seen only by immunohistochemistry
<b>3- EM</b>	Thin electron dense filaments.	Fine tubules.	Thicker electron dense filaments.
<b>4- Structural proteins</b>	Monomers of G actin polymerize to form F actin.	Tubulin dimer polymerize to protofilaments. 13 protofilaments form a microtubule,	Woven ropes.
<b>5- Functions</b>	Dynamic 1- Muscle contraction. 2- Contractile ring in cell division. 3- Pseudopodia in migration. 4- Microvilli. 5- Cytoplasmic streaming.	Dynamic. 1- Transport of organelles & vesicles. 2- Formation of centrioles, cilia & flagella.	Not dynamic. Structural support.

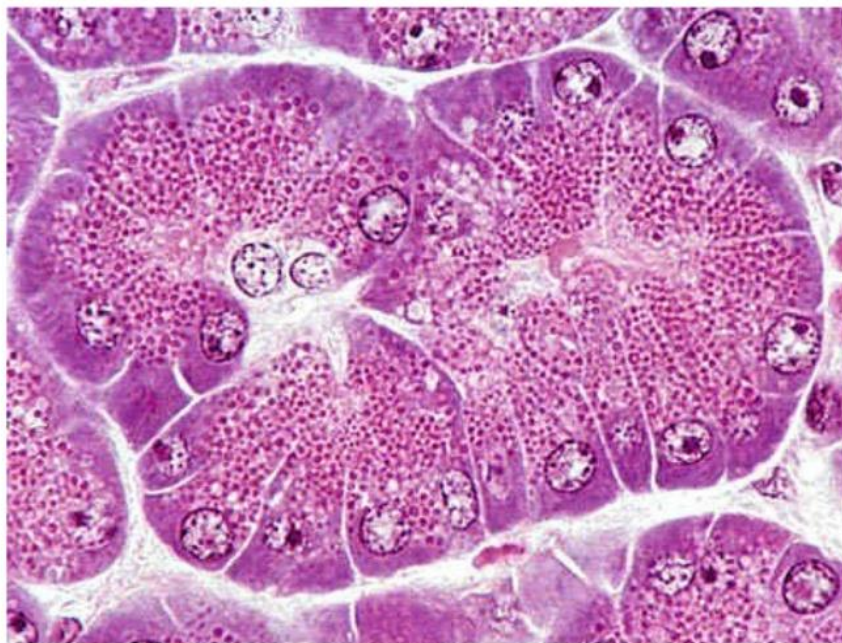

## 10- Cyttoplasmic Inclusions

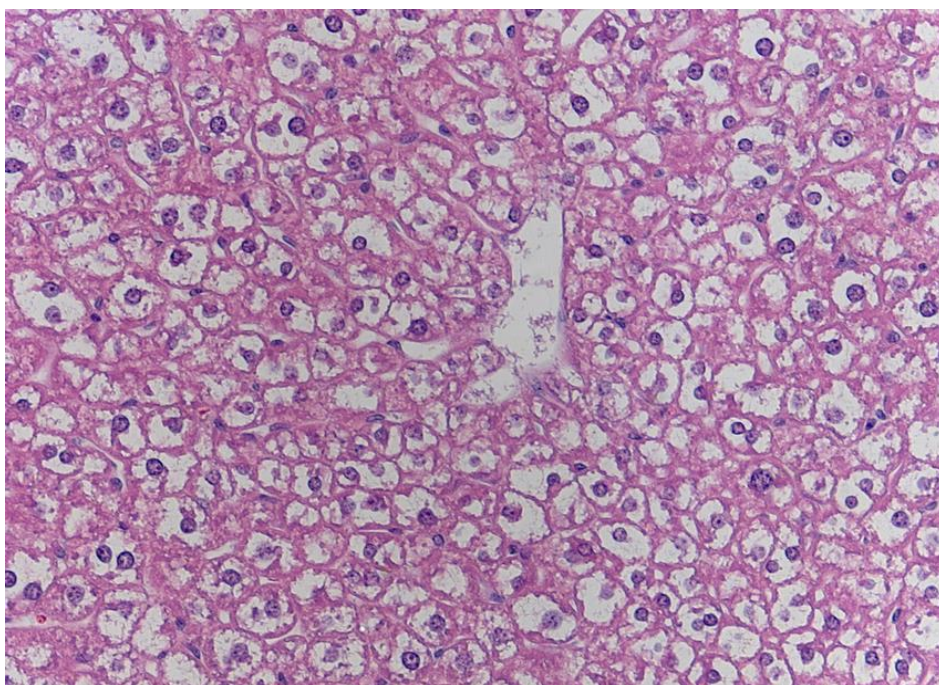
They are temporary lifeless accumulation of metabolites or cell products, such as stored food, pigments and crystals.

### 1. Stored food

Pancreas – Secretory acini w/ zymogen granules



### 2. Glycogen

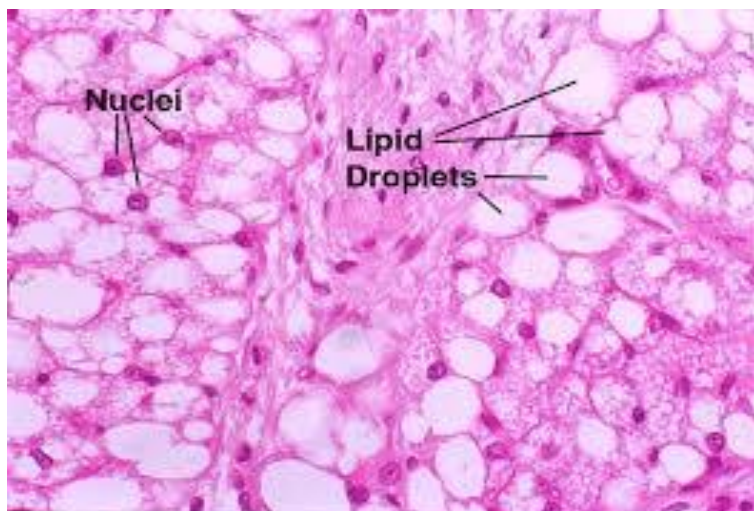




### 3. Lipids

The fat cells of adipose tissues and the fat storing cells of the liver store the lipids. Routine processing generally extracts lipids from tissue and therefore, in H&E sections, lipid droplets within cells appear as unstained vacuoles.

Lipids are best demonstrated in frozen sections stained by specific lipid methods such as osmium or sudan III with which lipids are stained black and orange respectively.



### 4. Pigments

They are substances that have their own color in their nature state.

#### a. Exogenous pigments

The exogenous pigments are those that have been produced outside the body. They include carotenes, dusts, minerals and tattoo marks.

#### 1. Carotenes

Carotenes are a family of fat-soluble compound found in vegetable such as carrots, tomatoes and vegetable juice. When animals fed on carotene-containing vegetables, it colors its body fat yellow. Carotenes are provitamins and may be converted into vitamin A.

Ingestion of large amount of carotenes cause the skin of the body to appear yellow or even reddish color due to its great contents of carotenes. This condition is called carotenemia (increase carotene level in the blood). It might be confused with the more serious pathological condition called jaundice (caused by increase bilirubin level in the blood).

## **2. Dusts**

The lungs of heavy smokers usually blackened due to accumulation of carbon particles in the alveolar macrophages located in the wall of the lung alveoli.

## **3. Minerals**

Silver causes a gray pigmentation of the body. Lead can impart a blue line to the gum.

## **4. Tattoo marks**

They are inorganic pigments inserted deeply into the skin with needles.

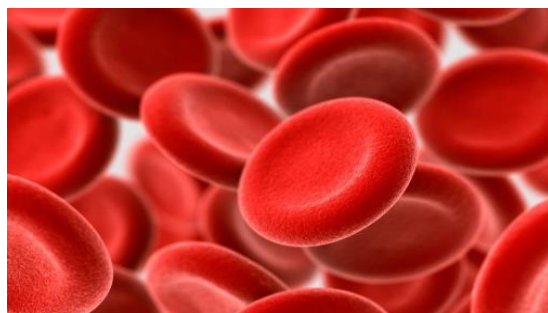The pigments are ingested by the subcutaneous macrophages and remain permanently within their cytoplasm.

### **b. Endogenous pigments**

They include hemoglobin, hemosiderin, bilirubin, melanin and lipofuscin.

#### **1. Hemoglobin**

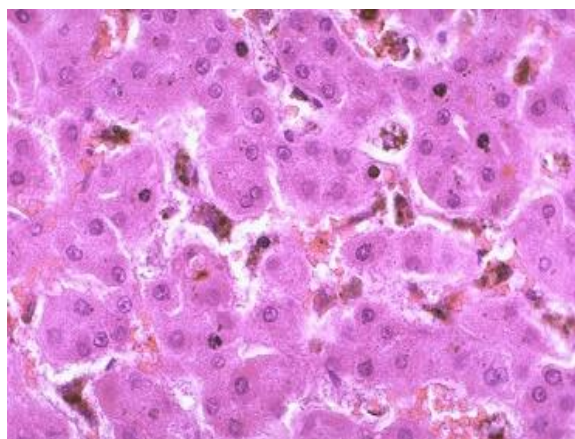
he hemoglobin is an iron-containing pigment of erythrocytes has the function of oxygen transport throughout the body.



## 2. Hemosiderin and bilirubin

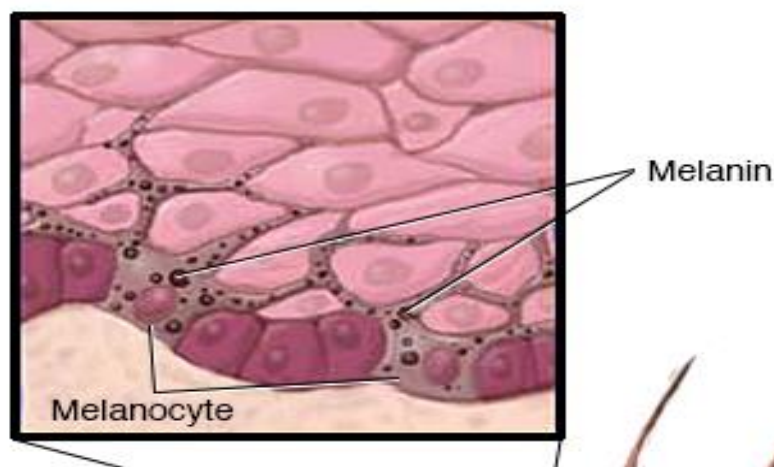
They are formed as the result of degradation of old erythrocytes by the spleen macrophages. Hemoglobin is degraded into hemosiderin and bilirubin. The hemosiderin is a golden brown iron-containing pigment usually seen within the cytoplasm of the splenic macrophages.

The bilirubin is yellowish-brown pigment. It has to be removed from the blood stream by the liver and excreted in bile.



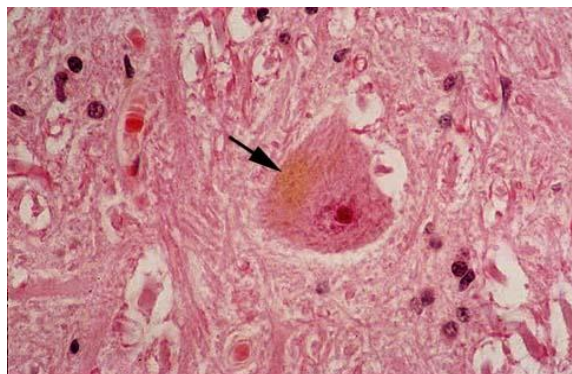
## 3. Melanin

The melanin is a brown-to-black pigment presents in skin, hair and eyes. There is two type of melanin: eumelanin, which has a brownish black color, and pheomelanin that has a reddish-yellow color.



#### **4. Lipofuscin**

The lipofuscin is a golden-brown intracellular pigment represents a normal product of organelle's degradation. It accumulates with increasing age particularly in long-lived cells such as neurons and cardiac muscle cells (hence, they are referred to as age pigments or wear and tear pigments).



#### **c. Crystals**

Such as calcium oxalate and calcium carbonate crystals can be seen in the cytoplasm during certain disease conditions.

#### **11. Nucleus**

The nucleus is the archive of the cell that carries the genetic information necessary to regulate the different cell functions. It consists primarily of DNA (20% of its mass), DNA-binding proteins, and some RNA.

The DNA-binding proteins are of two major type histones and non-histones. The histones are involved in the folding of DNA strands and regulation of DNA activity. The non-histones are involved in the regulation of gene activity.

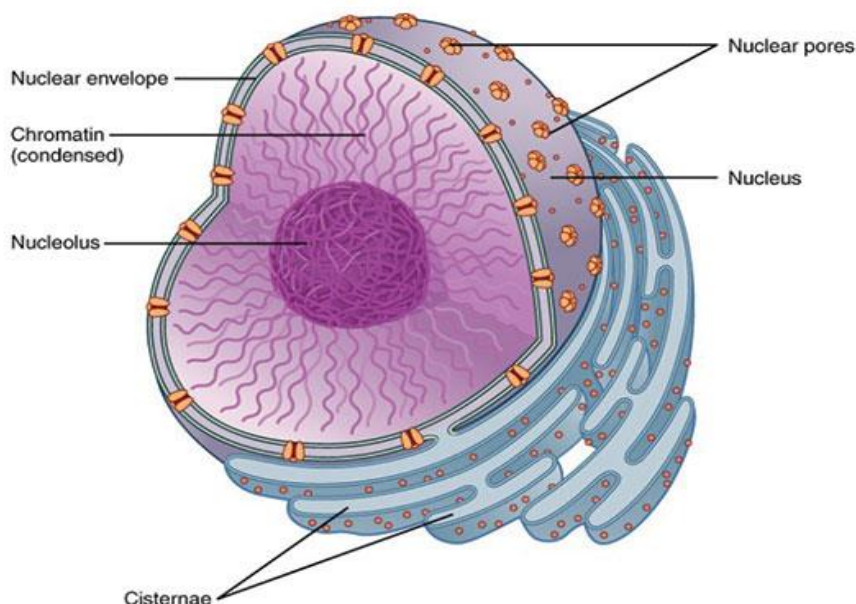
The nuclear RNA represents newly synthesized transfer and ribosomal RNA that has not yet passed into the cytoplasm.

With LM, the nuclei appear as basophilic structure located either centrally, eccentric or in a peripheral position. Most commonly nuclei are spherical or ovoid but they may be spindle-shaped (smooth muscle), bean or kidney-shaped (monocytes), or multilobulated (neutrophils).

Most often, cells are mononucleated. Some however, may be binucleated or even multinucleated. The interphase (not engaged in cell division) nucleus consists of nuclear envelope, chromatin, nucleolus and nuclear sap (karyolymph).

# Nucleus

## Structure and Functions



### 1. Nuclear envelope

With LM, it appears as a single basophilic line due to the presence of condensed chromatin adherent to its inner surface (peripheral chromatin) as well as ribosomes on the outer surface of the nuclear envelope.

With EM, the nuclear envelope consists of two membranes separated by a perinuclear space 25nm wide.

The outer membrane is continuous with the membranes of both the rER and sER and it may be studded with ribosomes. At the inner surface of the inner membrane, a layer of condensed chromatin known as granular lamina is usually encountered.

Numerous pores through which the nucleus communicates with the cytoplasm interrupt the nuclear envelope. The nuclear pore is guarded by two annuli, an outer and an inner annulus, each with eight globular subunits 15-20 nm diameter, projecting inwards from them are eight radially arranged spokes. In the center of the pore there is a central granule or plug. Such structure is called nuclear pore complex.

## **2. Chromatin**

Two types of chromatin are distinguished: heterochromatin and euchromatin.

### **Heterochromatin**

The heterochromatins consist of tightly coiled portions of chromosomes. The genes are repressed and transcription does not occur. It predominates in inactive cells.

With LM, they appear as fine and coarse basophilic granules scattered throughout the different regions of the nucleus.

With EM, it appears as electron-dense areas tend to be clumped around the periphery of the nucleus (peripheral chromatin), around the nucleolus (nucleolus associated chromatin) and also forms irregular clumps throughout the nucleus (chromatin islets).

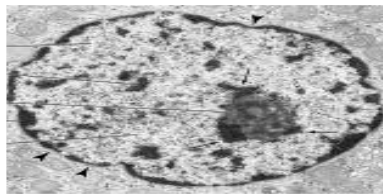
In females, the inactive X-chromosome forms a small mass located at the edge of the nucleus and is called Barr body.

### **Euchromatin**

The euchromatin is the extended, uncoiled portions of chromosomes in which the transcription of DNA is active. This type of chromatin is found in active cells. With LM, euchromatin is invisible because they are very thin and extended. With EM, they appear

as electron-dense nuclear materials represent the parts of the DNA that are active in RNA synthesis.

	Heterochromatin	Euchromatin
<b>1- LM</b>	Dense basophilic clumps.	Lightly stained basophilic areas.
<b>2- EM</b>	Electron dense filaments or granules distributed 1- around nucleolus. 2- associated with inner nuclear membrane. 3- swimming in nuclear sap.	Dispersed fine filaments or granules
<b>3- Function</b>	Inactive part acts as a reserve ( transformed into euchromatin when needed).	Active part (transcribed into RNA).
<b>4- Site</b>	Inactive cells.	Active cells e.g. dividing cells.



103

### 3. Nucleolus

It is a conspicuous, spherical, basophilic structure that is primary concerned with synthesis of ribosomal RNA.

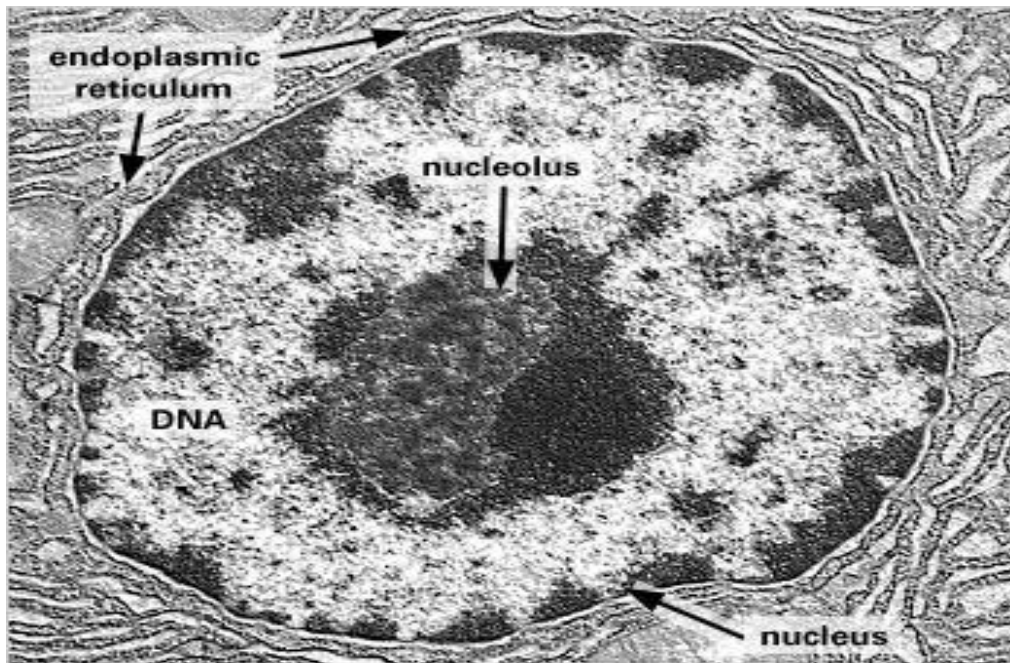
With LM, usually one, sometimes several nucleoli are seen. They are usually basophilic mainly due to nucleolus associated chromatin.

With EM, the nucleolus consists of a sponge showing dark materials of granular (pars granulosa) and fibrillar (pars fibrosa) both form the nucleonema which is ribonucleoprotein permeated by dispersed filaments of DNA (pars amorpha).

The primary function of the nucleolus is the synthesis of ribosomal RNA (rRNA). The genes that code for rRNA are known as nucleolar genes that lie along five different pairs of chromosomes.

#### 4. Nuclear sap (karyolymph)

The nuclear sap is a colloidal solution in which chromatin is suspended. It helps in the movement of RNA (rRNA, tRNA, and mRNA) toward the nuclear pores.



### Nucleus

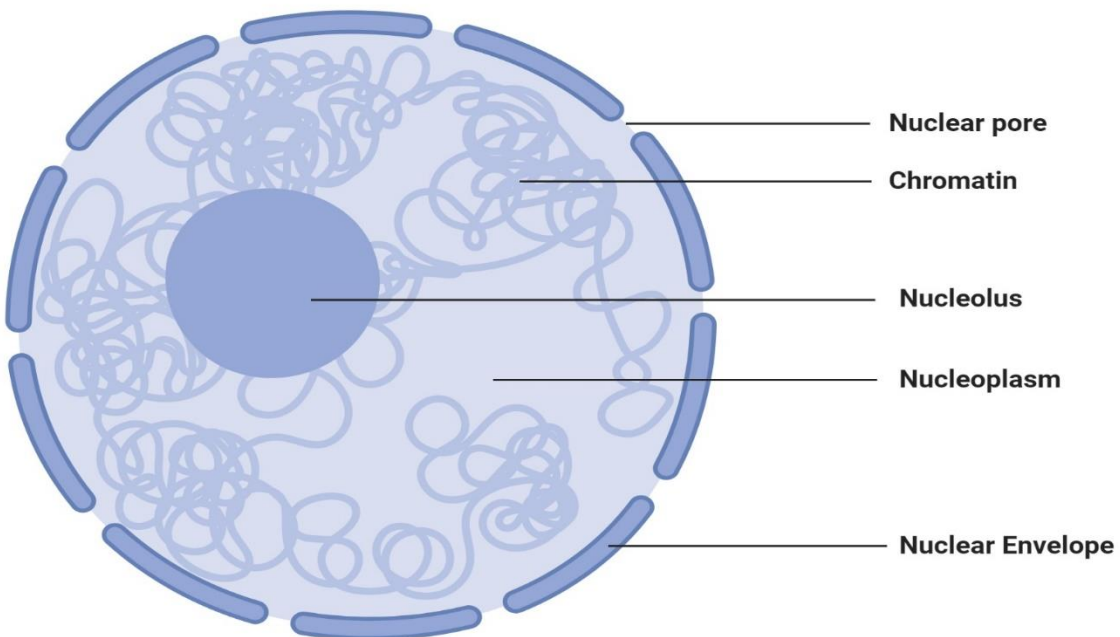


Figure: Nucleus, Image Copyright © Sagar Aryal, [www.microbenotes.com](http://www.microbenotes.com)

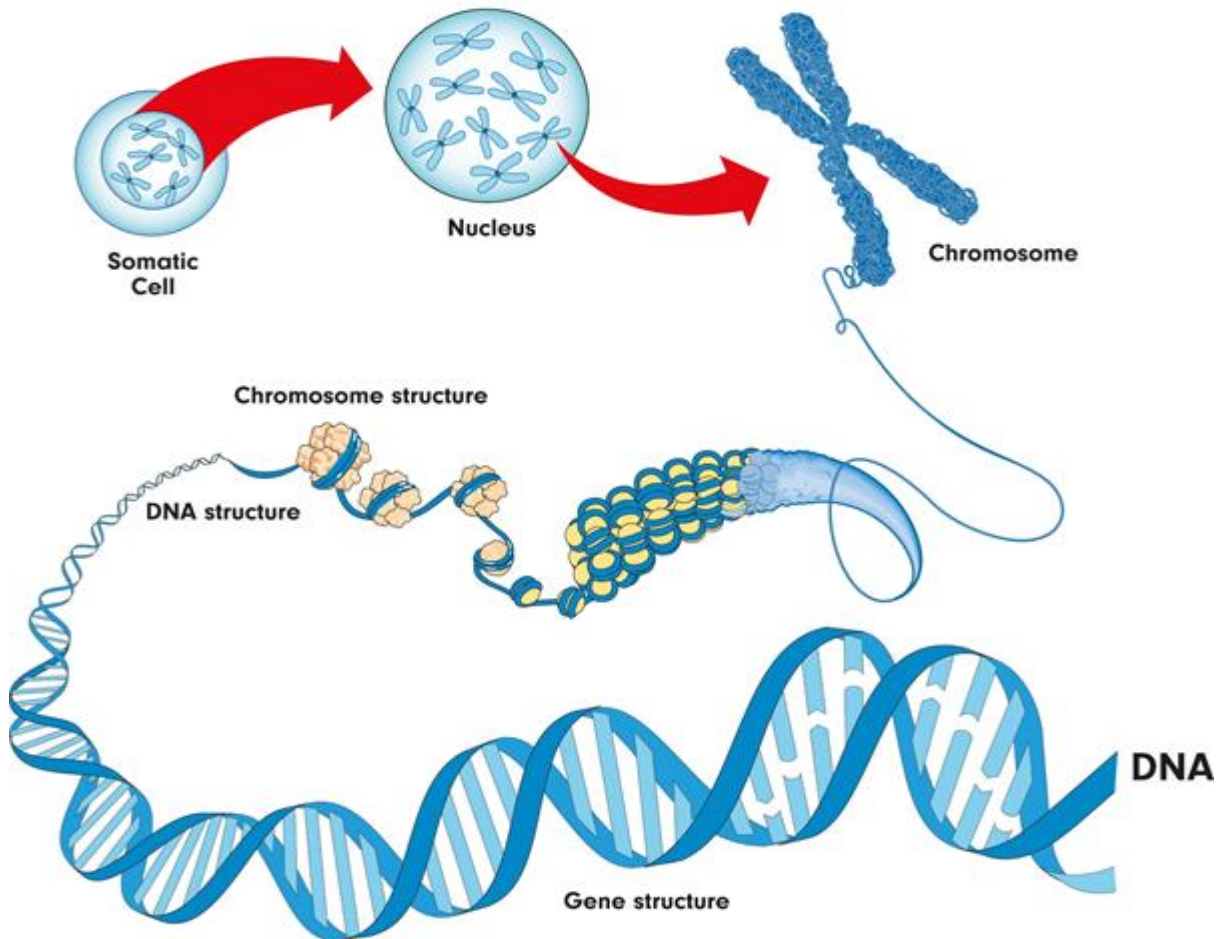


## DNA and chromosomes

Inside the nucleus of a cell, there are thread-like structures called chromosomes. Each chromosome is made out of a long, coiled up strand of DNA (genetic material), which means that each chromosome contains many genes.

Normally, there are 46 chromosomes inside the nucleus of each human body cell. Chromosomes are usually found in pairs.

### *Chromosome structure*



A **diploid** cell contains two complete sets of chromosomes in its nucleus, one from each parent. In humans, all body cells are diploid cells. Human diploid cells have 23 pairs of chromosomes (46 in total). The diploid number is often represented as  $2n$ , with  $n$  being the number of chromosomes. In humans,  $2n = 46$ .

The word **haploid** means half. It describes a cell that contains a single set of chromosomes. The symbol **n** is often used to show the haploid number. In humans,  $n = 23$ . Human sex cells (egg and sperm cells) contain a single set of chromosomes, so they are haploid cells.

- Sex cells are also called **gametes**

## **12- Vacuoles**

A vacuole may be described as a space inside the cell that does not contain cytoplasm. It is surrounded by a membrane and filled with a fluid. Vacuoles store various molecules including enzymes, waste products of the cell, water, and even food material depending on the type of cell.

In cases where vacuoles contain waste products of the cell, they are also involved in the exportation of waste from the cell thus protecting the cell from toxicity.

Some vacuoles also play a role in maintaining the internal hydrostatic pressure of the cell as well as regulating pH.

- **Other features of a cell include:**

- **Cell Wall**

- Some books do not consider the cell wall to be an organelle. However, it's one of the most important components of plant cells. The cell wall surrounds the cell membrane and serves to strengthen and protect the cell.
- For instance, in the cells of plant roots, the cell wall protects the cell as they grow deeper in the soil. The cell wall also serves as a filter that controls the movement of molecules in and out of the cell.
- **Cytoplasm** is also not considered as an organelle in some books. However, it is an important component of the cell. Cell cytoplasm is composed of protoplasm in which all the other cell organelles are suspended. Many of the cell processes

(protein synthesis, respiration etc) take place in the cytoplasm. The cytoplasm also plays an important role in the movement of various materials around the cell.

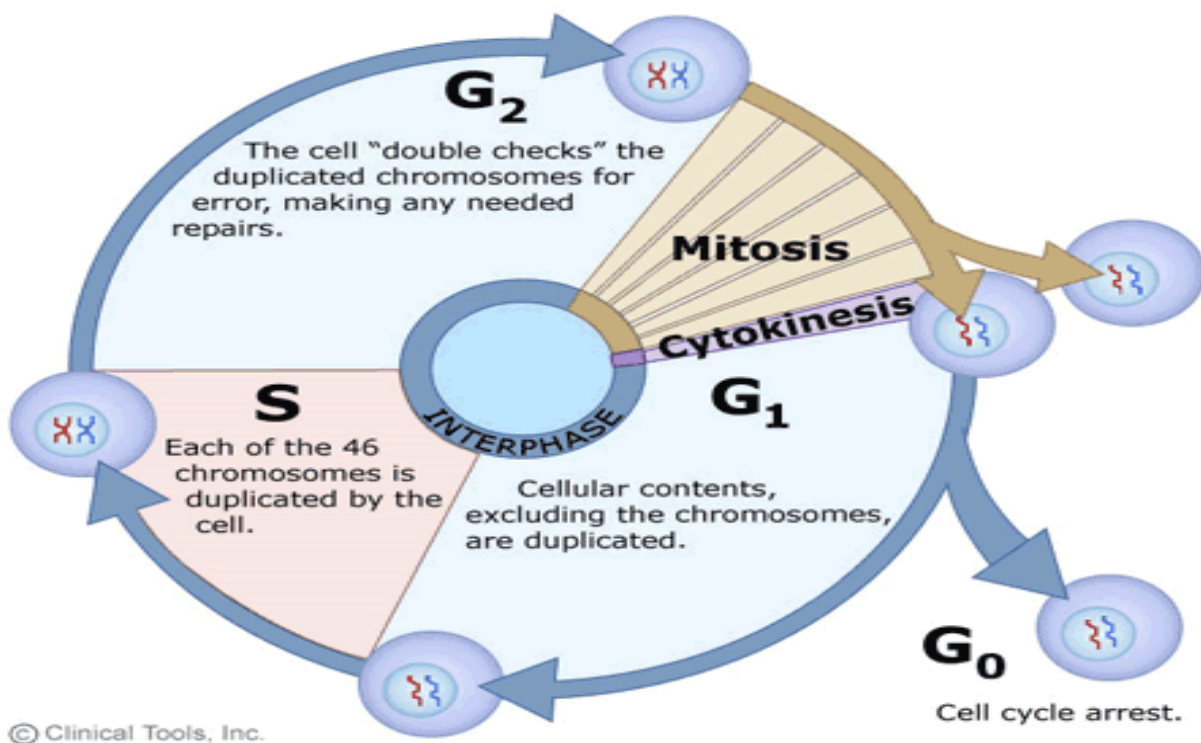
## Cell cycle & division

- Definition: it is the alternation between interphase and mitosis.

**I-Interphase:** a longer period:

- 1- The cell increases in size.
- 2- Performs its normal functions.
- 3- Replicates its DNA for preparing itself for division.

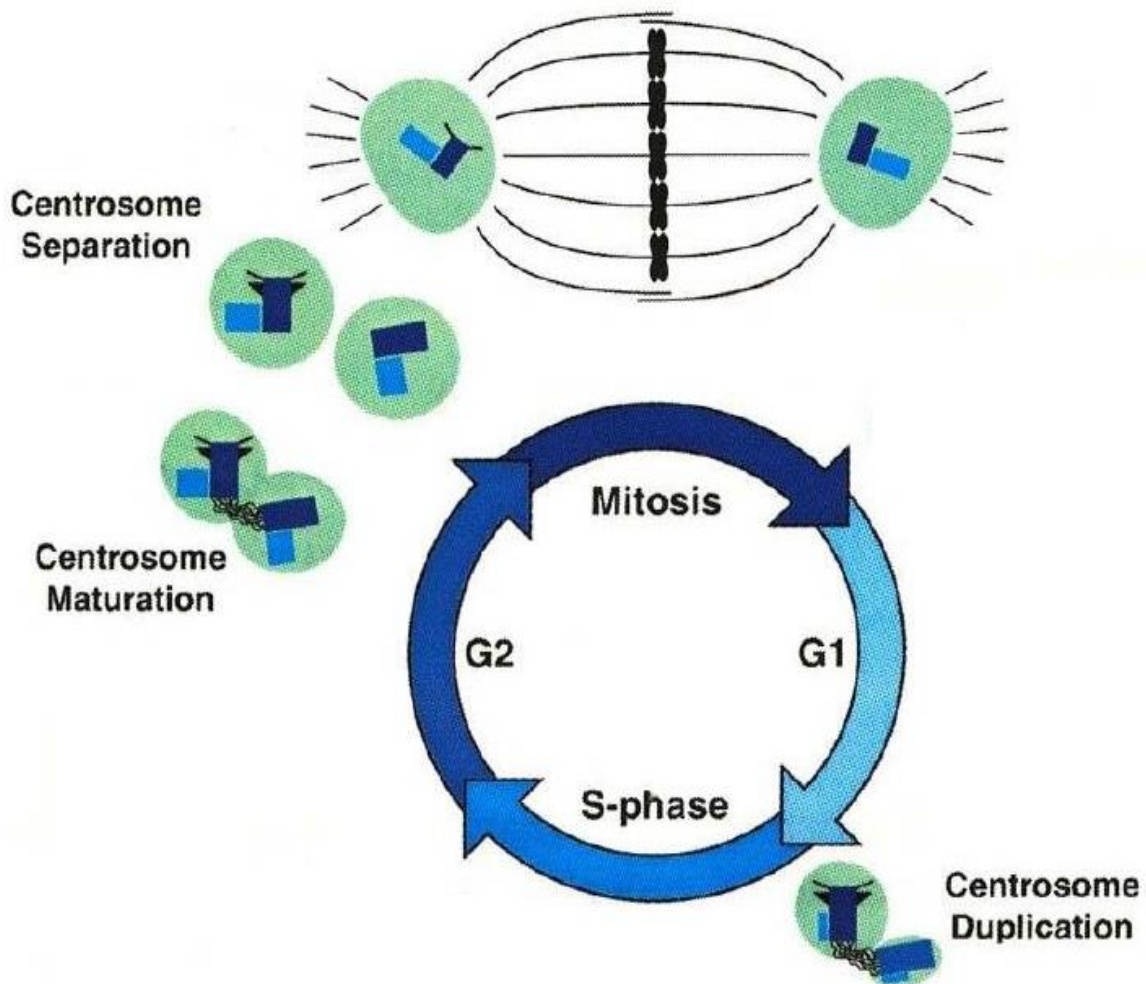
**II-Mitosis:** a shorter period during which parent cell gives 2 daughter cells each containing the same number of chromosomes (identical to the parent cell =46 chromosomes).



## I-Interphase

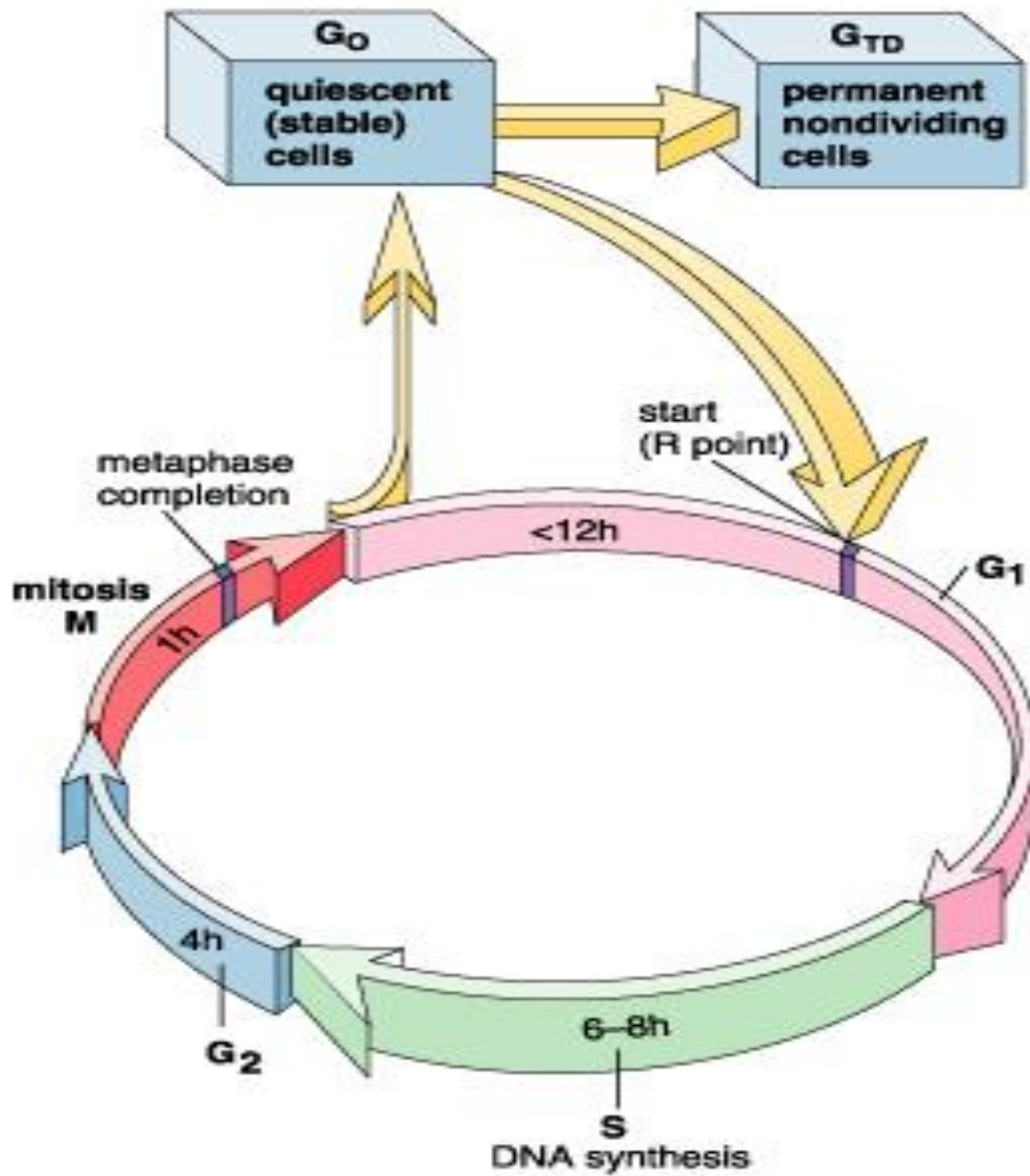
### First gap phase (G<sub>1</sub> phase)

- It is *the longest period* of the cell cycle between the end of mitosis and the beginning of DNA replication:
  - 1- The RNA and protein synthesis occurs.
  - 2- The cell attains its full size.
  - 3- The cell performs its function.
  - 4- Duplication of centrosomes occurs near the transition between G<sub>1</sub> and S phase.



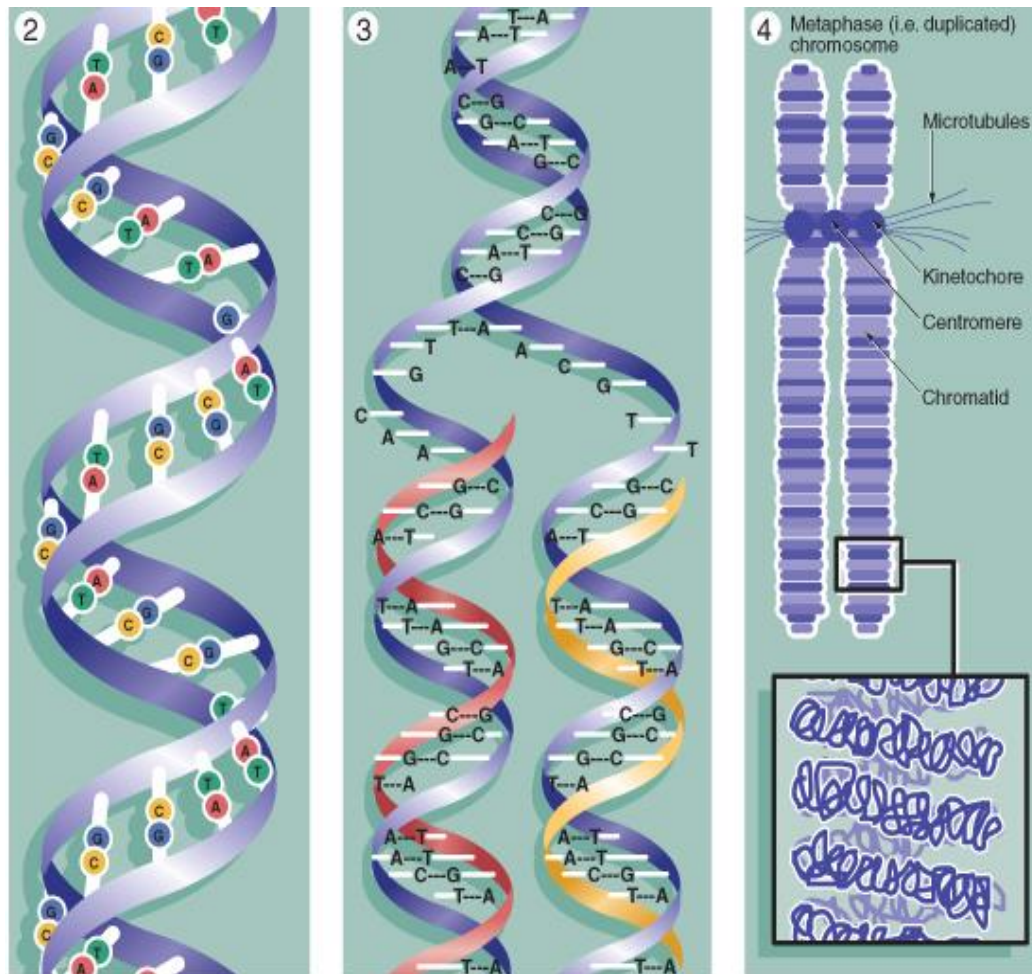
## GO Phase

- **Definition:** Differentiation of the cell to carry out specialized function and no longer divide ( *outside the cycle* ).
- GO may be *permanent* or *temporary*.



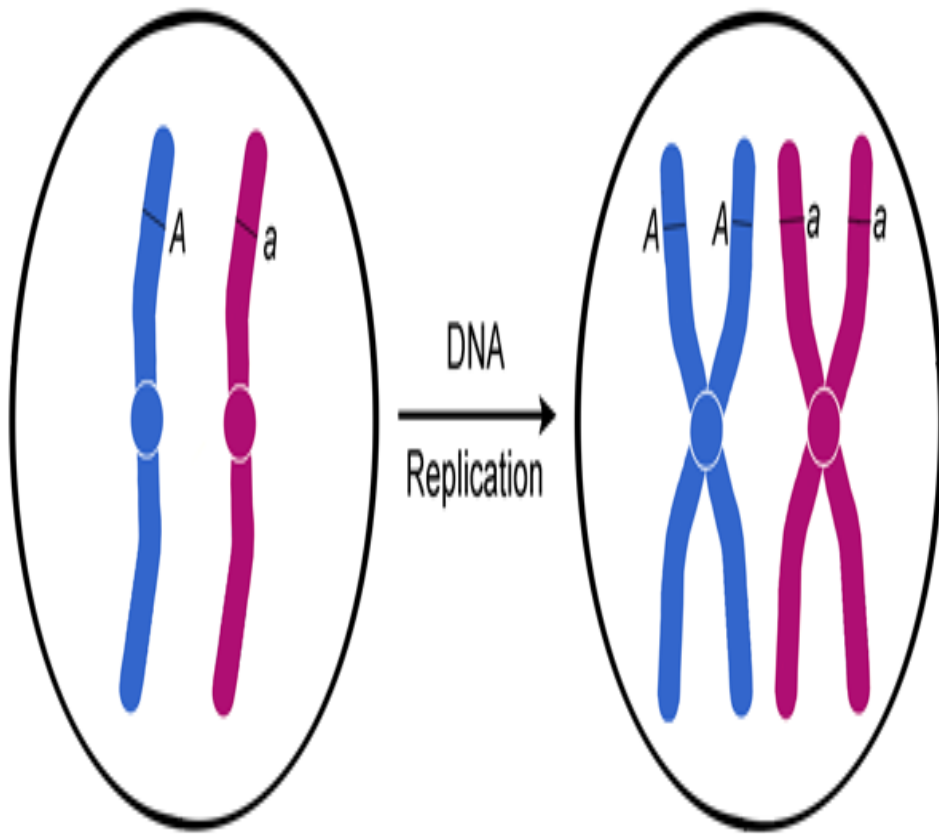
## DNA synthesis phase (S phase)

- Replication of DNA, thus the amount of DNA is doubled but *not the total chromosomal number*.

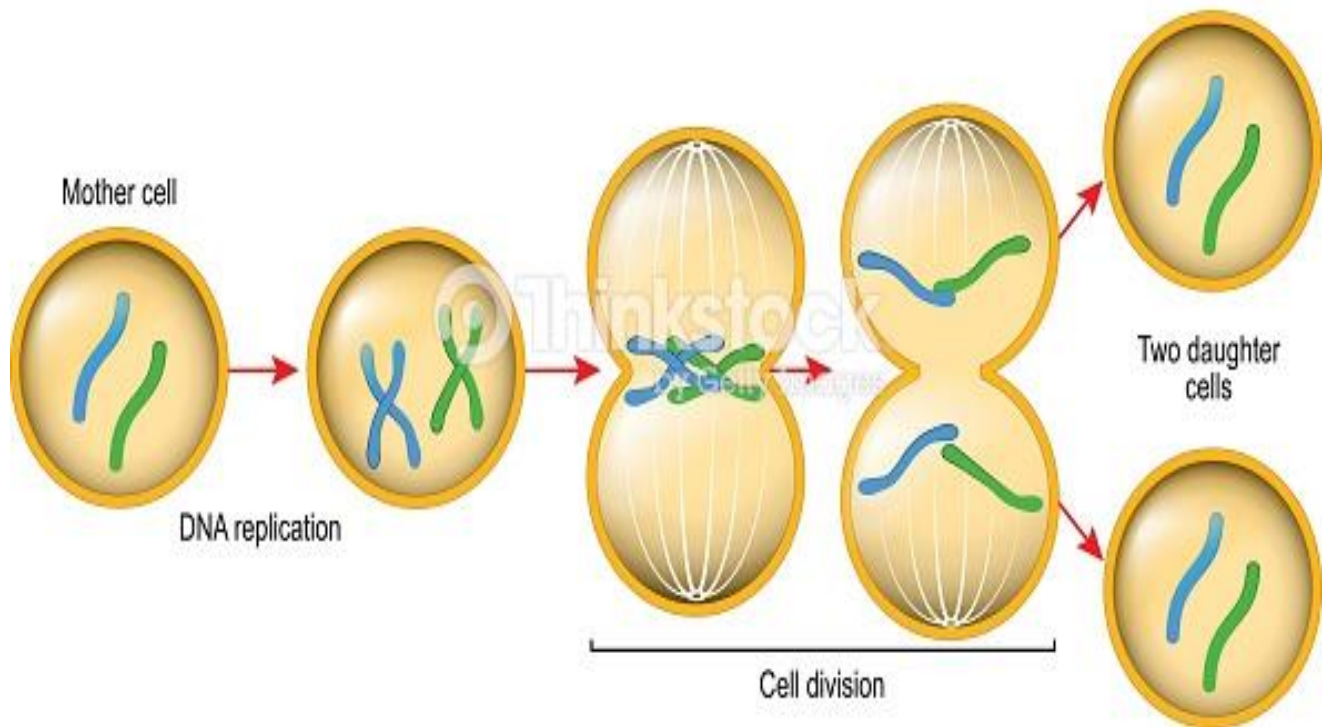


© Elsevier. Young et al. Wheater's Functional Histology 5e - www.studentconsult.com

- **Types of chromosomes** **s-chromosomes** made of one DNA molecule (interphase chromosomes = chromatin or chromatids).
- **d-chromosomes (mitotic chromosomes):** are formed during the S phase. Each d-chromosome is formed of two chromatids, linked at the centromere. Each chromatid is made of a DNA molecule.

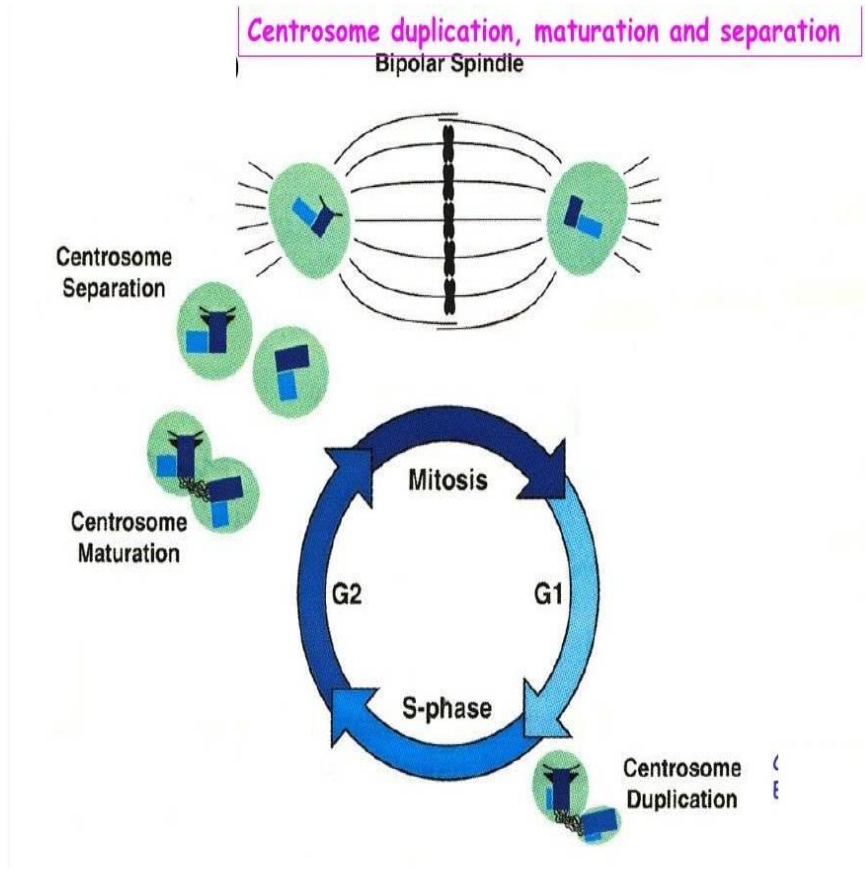


# MITOSIS



## Second gap phase (G<sub>2</sub> phase)

- It starts by the end of the DNA replication and lasts until the beginning of mitosis.
  - 1- Proteins and energy essential to mitosis are stored.
  - 2- Duplication of the centrosome is *completed*.

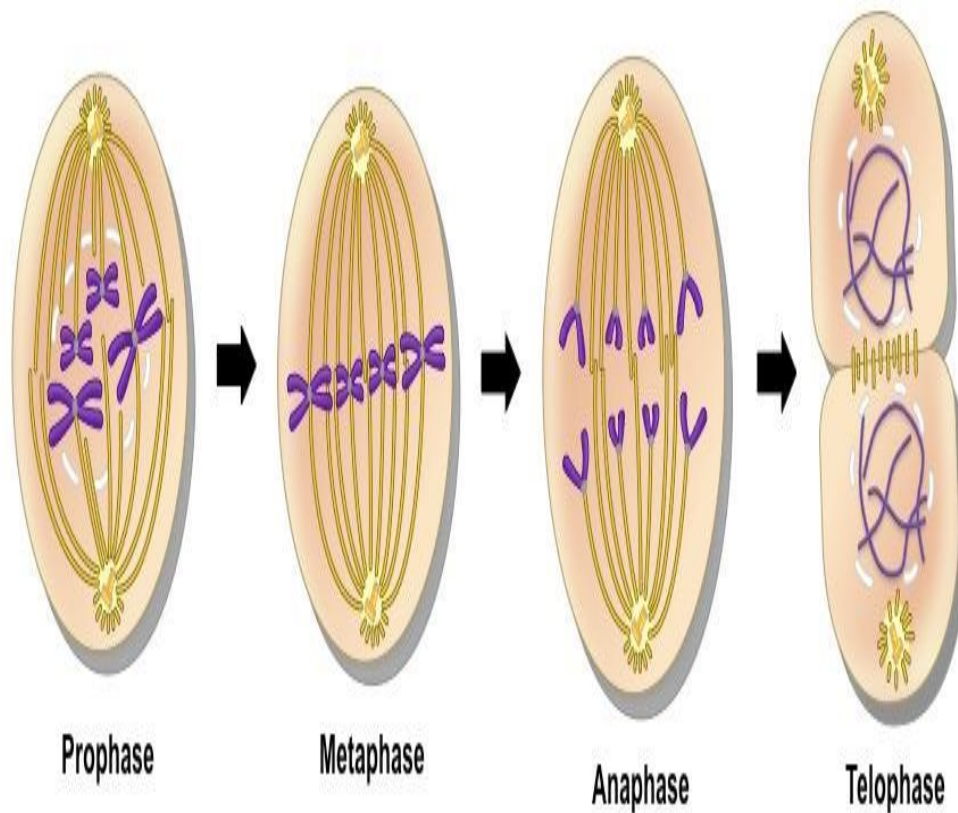




# Cell division

## Mitosis

- Definition: division of the somatic cell into two daughter cells identical to the mother cell.
- **Function:**
  - 1- Growth and development of the organism.
  - 2- Renewal and repair of cells.

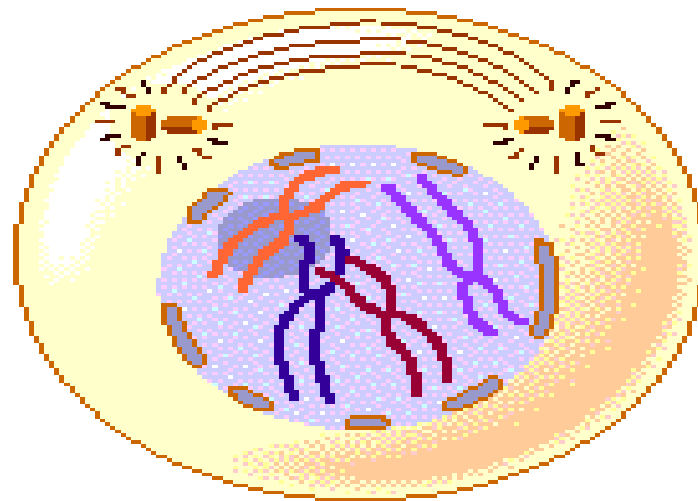
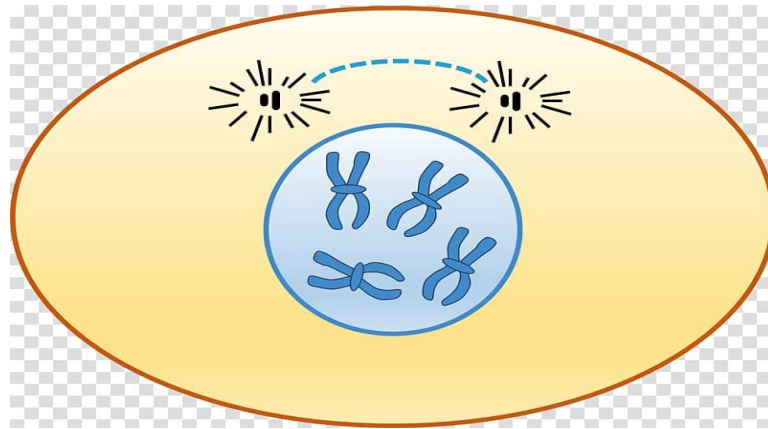


### I-Prophase

- 1- The *nucleolus* disappears.
- 2- Condensation of *chromatin* gives rise to 46 rod-shaped short d-chromosomes.

3- Each pair of *centrioles* migrates to opposite pole of the cell forming the mitotic spindles.

4- The *nuclear envelope* breaks up into small vesicles

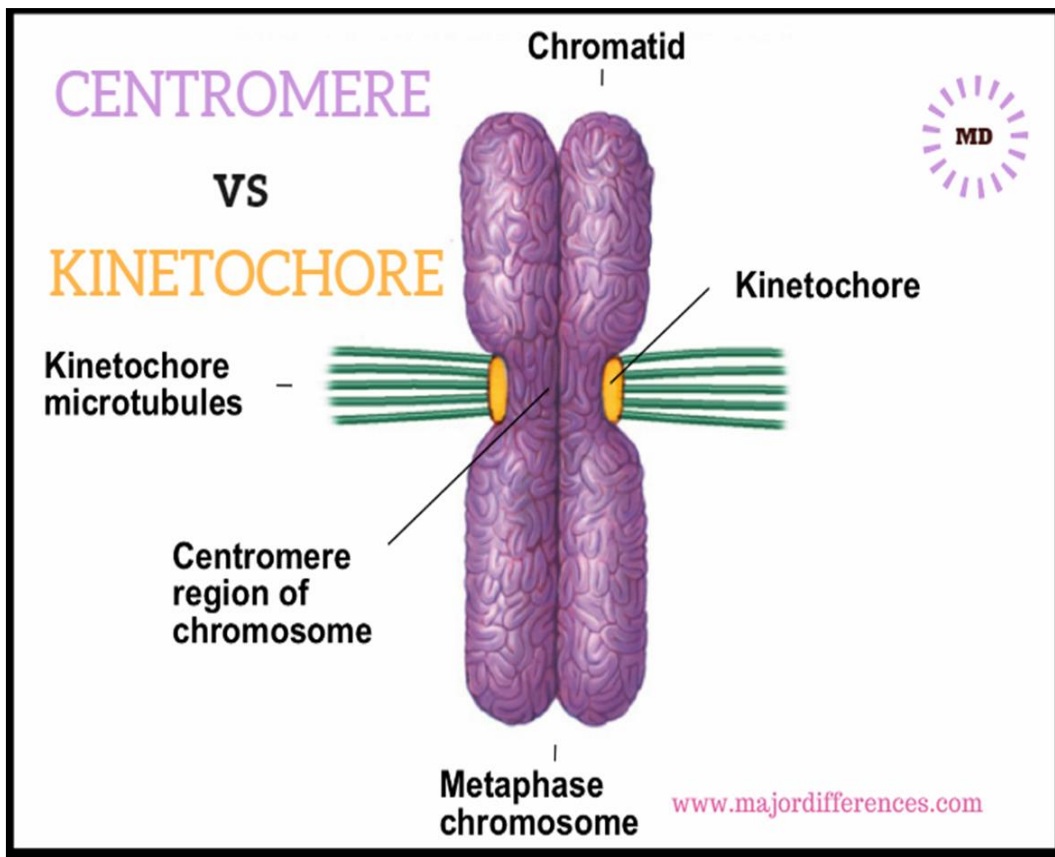


## 2-Metaphase

1- The 46 d-chromosomes become maximally condensed.

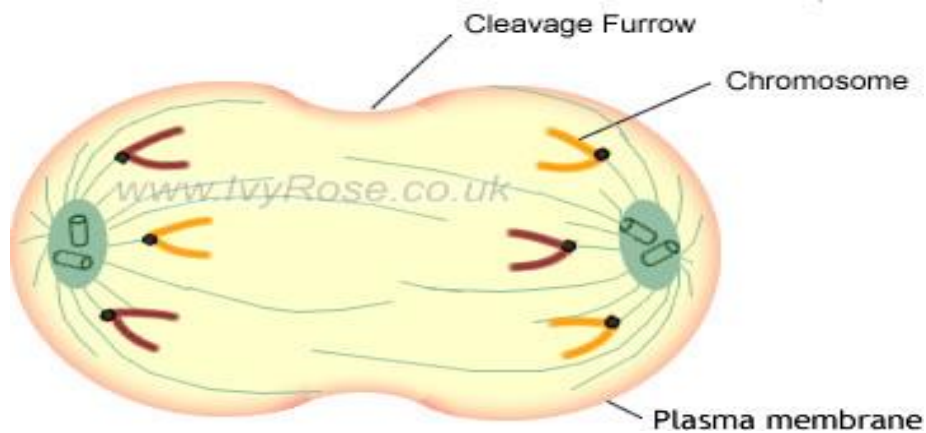
2- The chromosomes *aligned at the equatorial plate* of the cell.

- Each pair of sister chromatid is attached to the mitotic spindles at *the kinetochore*.



### 3-Anaphase

- 1- *Division of the centromere* results in the separation of the sister chromatids.
- 2- Each 46 chromatids migrate toward the opposite poles of the cell.
- 3- In late anaphase, a *constriction (cleavage furrow)* develops at the equatorial plate of the cell.



#### 4-Telophase

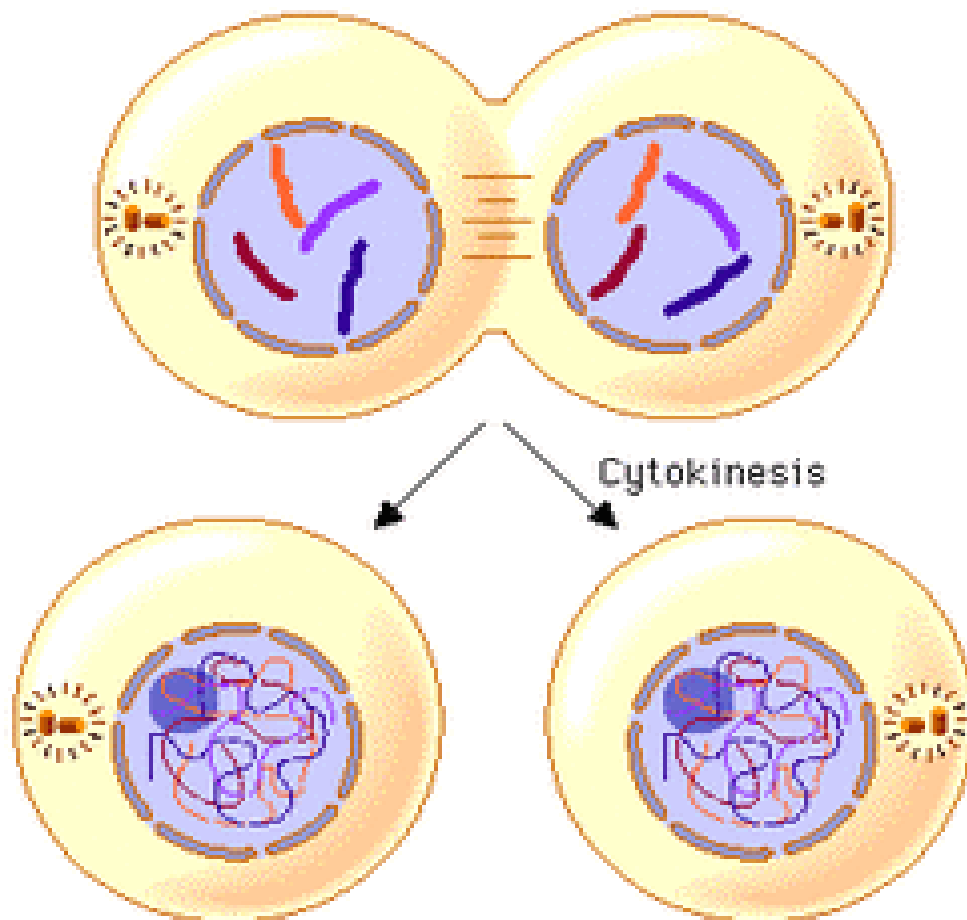
1- The *mitotic spindle* disappears.

2- The *nucleolus* reappears.

3- The *chromosomes* start uncoiling (46 s-chromosomes).

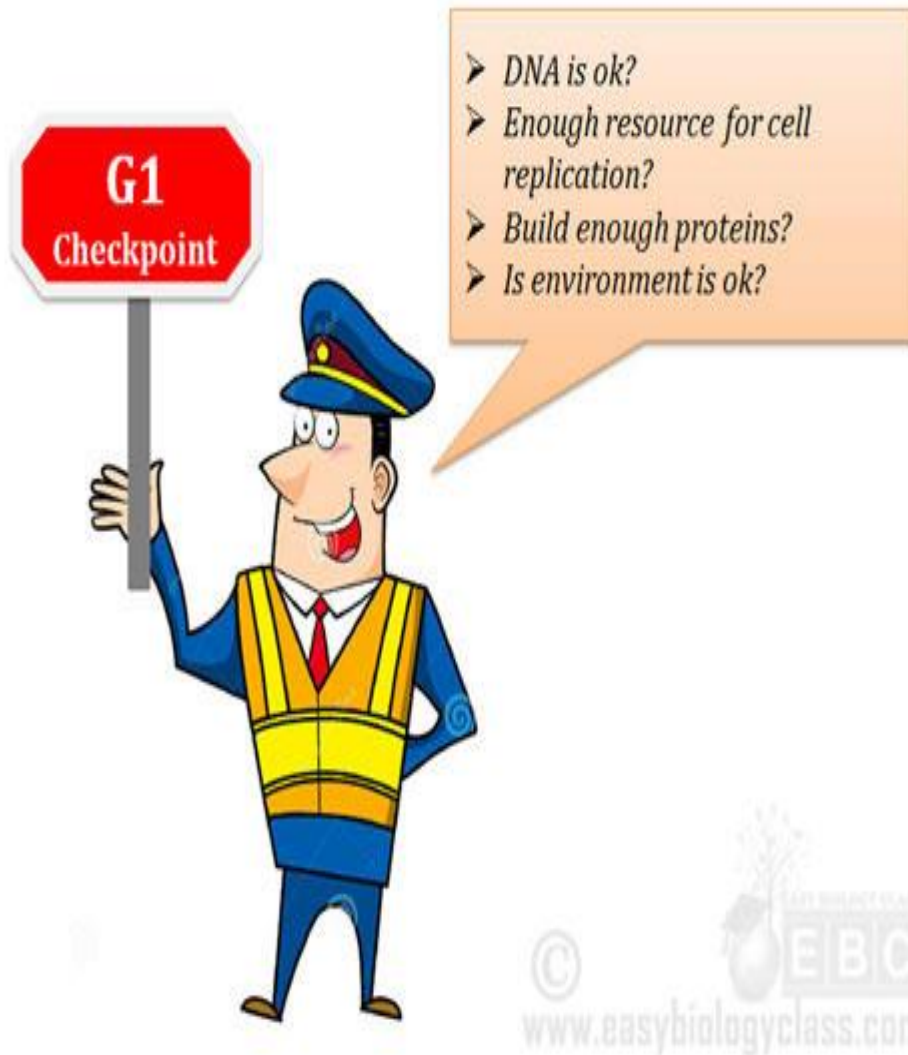4- The *nuclear envelope* is reformed around the new sets of chromosomes.

5- Division of the *cytoplasm* (cytokinesis): the cleavage furrow becomes deeper due to the formation of a contractile ring of microfilaments until it divides the cytoplasm and its organelles in half resulting into two daughter cells.



## Regulation of the cell cycle

- The cell cycle is regulated by growth factors that control cell proliferation to keep its coordination with the needs of the living organism.
- Several *checkpoints* control the transition between the cycle stages.
- Checkpoints detect external or internal problems and stop the cycle until the problem solved.



## Checkpoints of cell cycle

### 1-The restriction checkpoint

- It occurs in the G<sub>1</sub> phase.
- It detects *the cell size & its interactions with the surrounding environment*.
- Cells that do not receive appropriate growth stimuli do not progress past this point (G<sub>1</sub> phase) and will be die by apoptosis.

It is the most important checkpoint in the cell cycle

### 2-DNA damage checkpoints

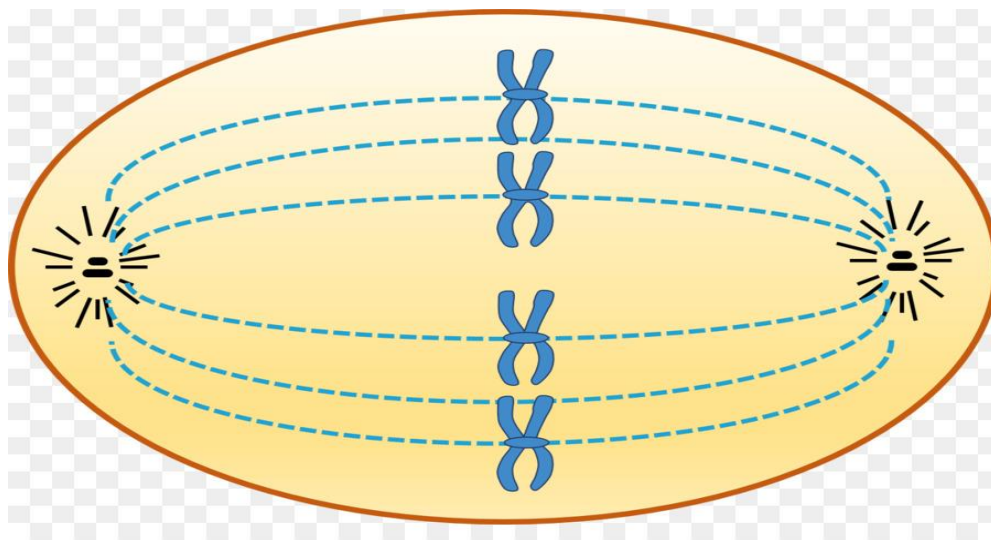
- It occur in G<sub>1</sub>, S, and G<sub>2</sub> phases.
- It blocks cell cycle progression until repair of the damaged DNA or cell apoptosis occurs.

### 3-The unreplicated DNA checkpoint

- It occurs in the G<sub>2</sub> phase.
- It prevents progression of the cycle into the mitosis before complete synthesis of DNA.

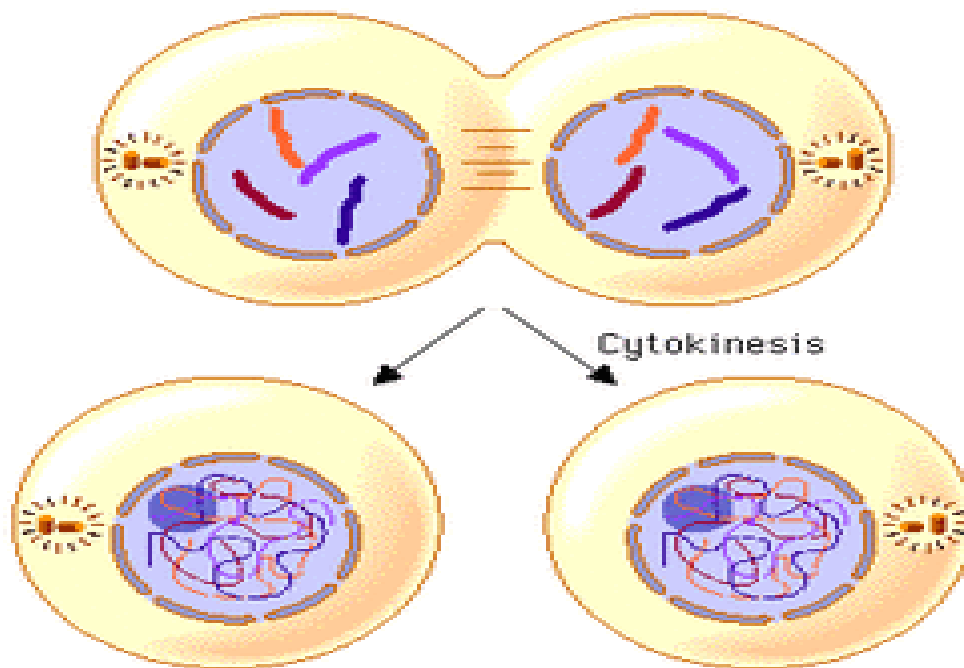
### 4- The spindle-assembly checkpoint (the metaphase checkpoint)

- It occurs in mitosis.
- It prevents entry into anaphase until all chromosomes have attached properly to the mitotic spindle.



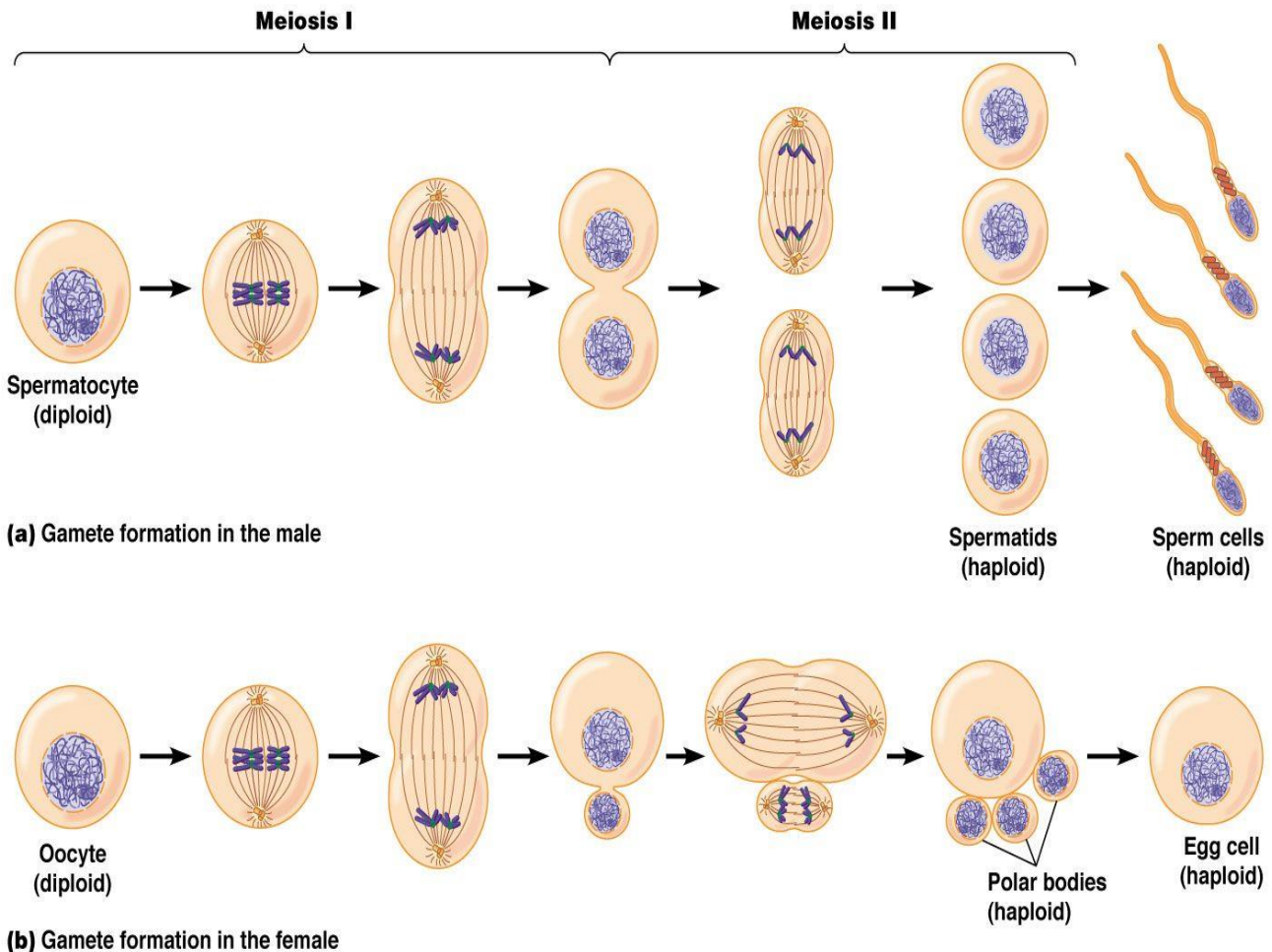
### 5- The chromosome-segregation checkpoint

- It occurs in telophase.
- It prevents the cytokinesis until all of the chromosomes have been correctly separated.



# Meiosis

- It occurs in *germ cells* and results in the formation of gametes.
- It results in formation of 4 *daughter cells* (each contains 23 s-chromosomes=haploid number).
- It consists of two successive divisions; *without an intervening S phase*.



© 2012 Pearson Education, Inc.

## I-First meiotic division (reductional division)

is preceded by interphase with an *S phase*, in which the chromosomes are replicated (46 s chromosomes → 46 d chromosomes).

### 1-Prophase I:

A- *Pairing of the homologous chromosomes* occurs forming tetrads(bivalent).



*B- Crossing-over* occurs between the chromatids of the homologous chromosomes so that each homologous chromosome is no longer solely paternal or maternal but a mixture of both.

3- The nucleolus and the nuclear envelope disappear and the mitotic spindle is formed.

### **2- Metaphase I:**

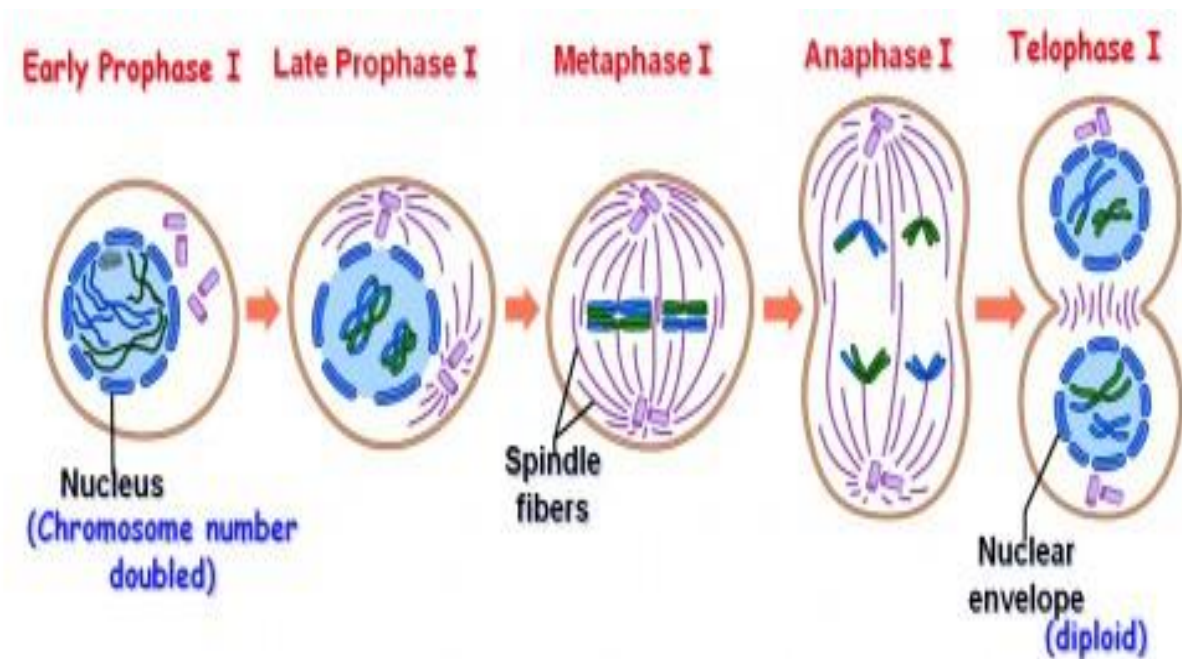
The *paired chromosomes* arrange themselves at the equatorial plate of the cell.

### **3- Anaphase I:**

The centromeres *do not divide*, instead, each chromosome of homologous pairs moves separately towards the opposite poles of the cell.

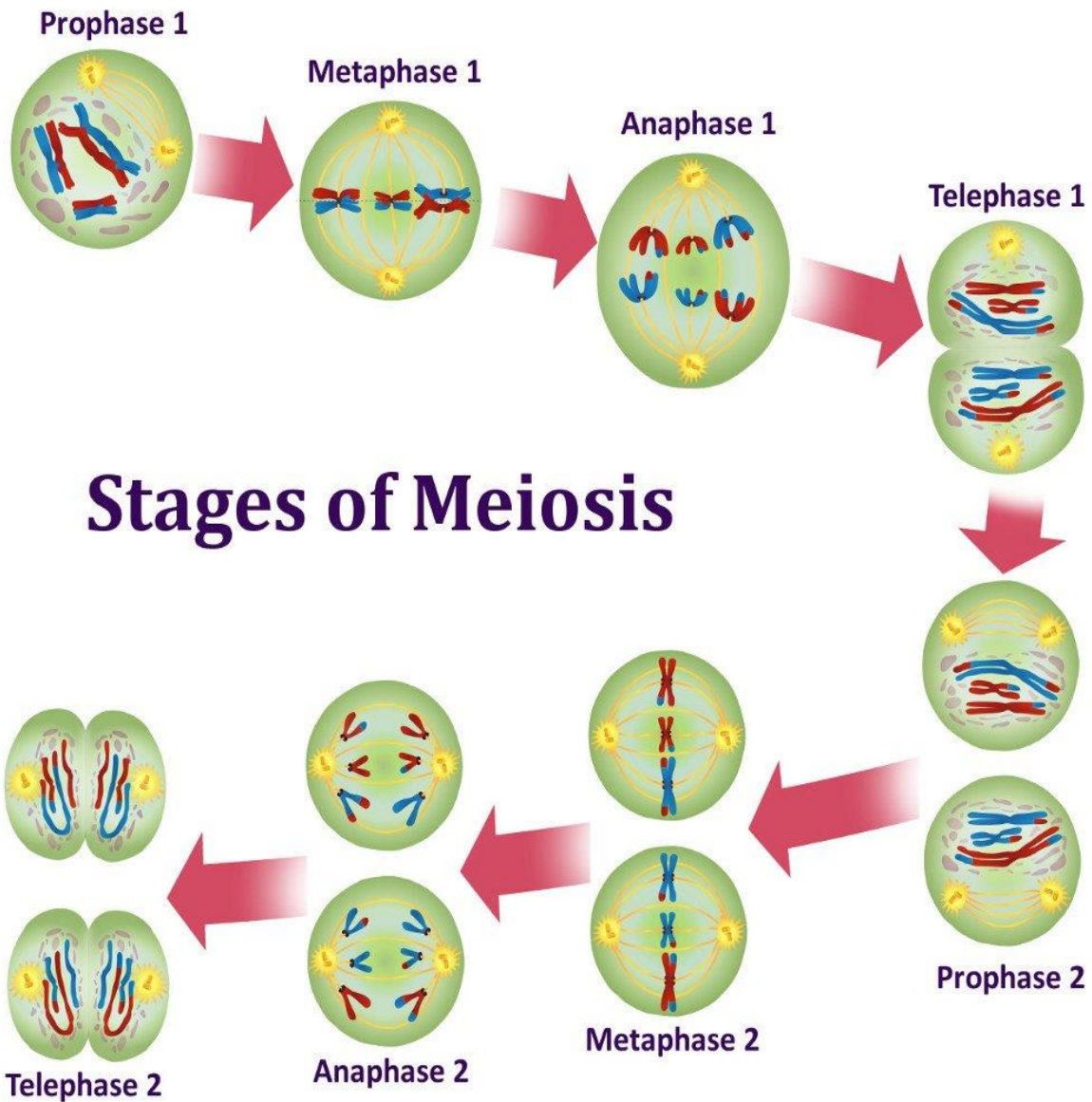
### **4- Telophase I:**

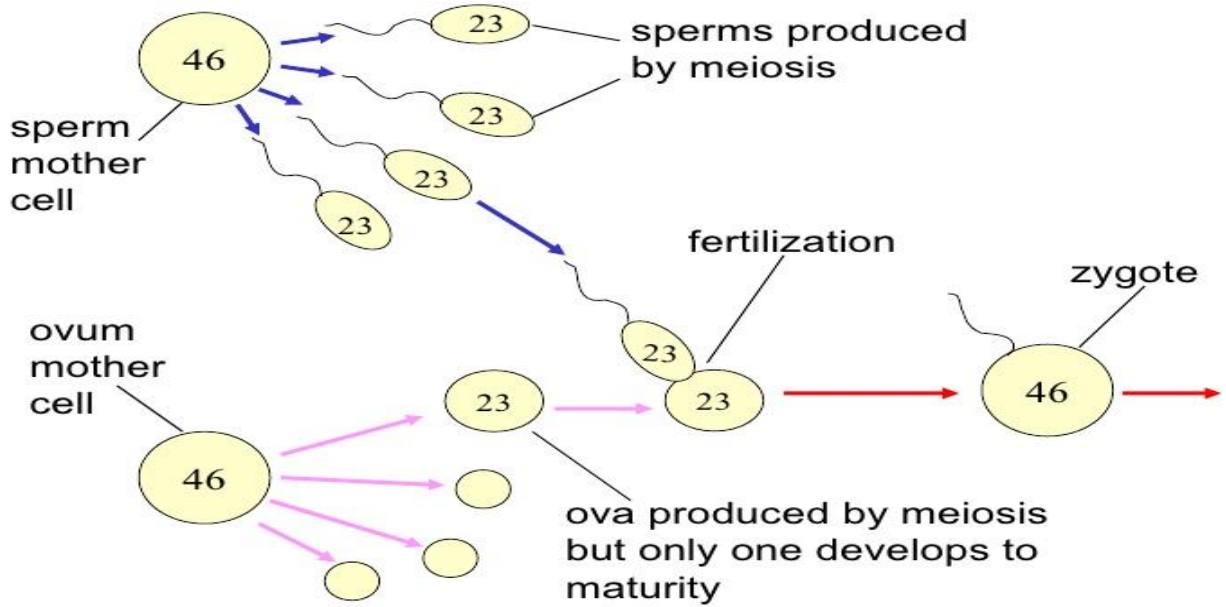
Cytokinesis occurs results in two daughter cells each containing the haploid number (23d-chromosomes).



## II-Second meiotic division (equatorial division)

- It is similar to mitosis but, it is *not preceded* by S phase.
- It results information of 4 *daughter cells*, each contains 23 s-chromosomes (haploid number).





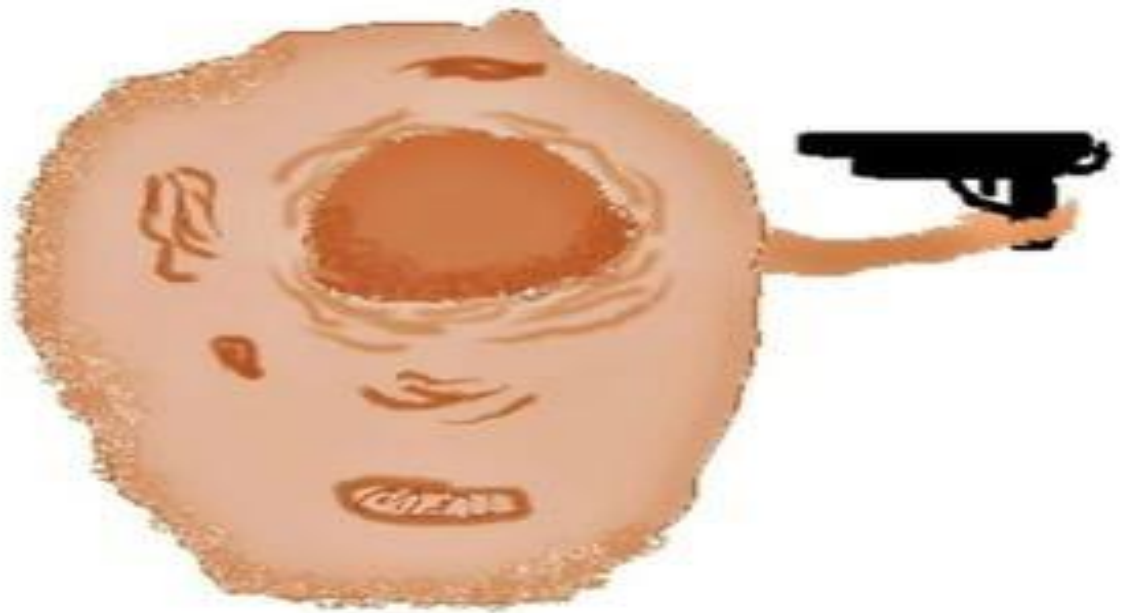
	Mitosis	Meiosis
<b>1-Types of cells</b>	Somatic cells	Germ cells of testis & ovaries
<b>2- Number of division</b>	Single division	2 successive divisions: Meiosis I & Meiosis II.
<b>3- Interphase</b>	Preceded by interphase with S phase	Meiosis I preceded by interphase with S phase, Meiosis II not preceded by S phase.
<b>3- Prophase</b>	No crossing over	Meiosis I: Crossing over occurs
<b>4-Metaphase</b>	46 d chromosomes arranged individually at the equatorial plane of the cells.	In Meiosis I :23 bivalent arranged at the equatorial plane of the cells.
<b>5- Anaphase</b>	Each chromosome divides at centromere into 2 chromatids	In Meiosis I: each chromosome of a bivalent moves apart.
<b>6- Cells produced</b>	Two daughter cells with diploid number of chromosomes (46 S) Daughter cells are genetically identical	Four daughter cells with haploid number of chromosomes (23 S) Daughter cells are genetically variable.

156

	Meiosis I	Meiosis II
<b>1- Preceded S phase</b>	Present (the cell enter the prophase with 46 d chromosomes).	Absent ( the cell enter the prophase with 23 d chromosomes).
<b>2- Prophase</b>	Pairing of homologous chromosomes result in 23 tetrad. Crossing over occurs between each tetrad .	No pairing No crossing over.
<b>3- Metaphase</b>	23 tetrad arranged at the equatorial plane of the cells.	23 d chromosomes arranged individually at the equatorial plane of the cells.
<b>4- Anaphase</b>	No division of the centromere. Each <b>chromosome</b> moves independently to the opposite pole of the cell.	Centromere splits so each <b>chromatid</b> moves independently to the opposite pole of the cell.
<b>5- Telophase</b>	Cytokinesis results in 2 daughter cells each with 23 d chromosomes.	Cytokinesis results in 4 daughter cells each with 23 S chromosomes.

157

# Cell death




When a cell want to die...

## Types of cell death

### Apoptosis



### Necrosis



## Necrosis = accidental cell death

- **Causes:** It is a *pathological process* due to e.g. hypoxia, radiation or pathogens such as viruses.
- **Morphological features:**
  - 1- *Damage of the cell membrane* with cell swelling & rupture.
  - 2- Breakdown of cell organelles.
  - 3- Denaturation or coagulation of cytoplasmic proteins.
  - 4- Inflammation with extensive damage of the surrounding tissue.

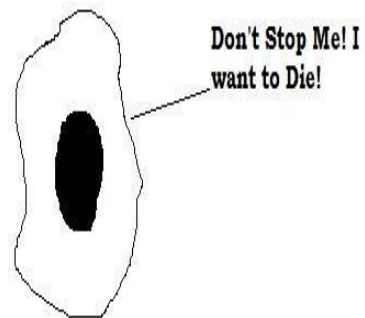
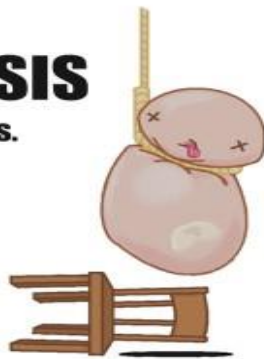
## Apoptosis = programmed cell death

It is a *physiological process* controlled by several genes (loss of mitochondrial function initiates several reactions that lead to cell death).

## What makes a cell decide to commit suicide?

### APOPTOSIS

Know the signs.



# Each cell receives

## Positive signals

From other cells and extracellular matrix that inhibit apoptosis

## Negative signals

Promote apoptosis



*There is a Balance Between them*

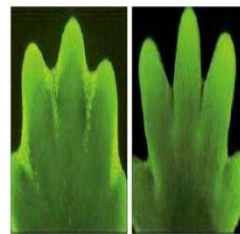
Receiving of negative signals **OR** Withdrawal of positive signals



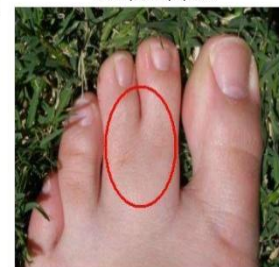*Apoptosis*

## I-During embryonic development

Removal of excess cells that have no function e.g. during morphogenesis and for determination of organ size



Development of toes

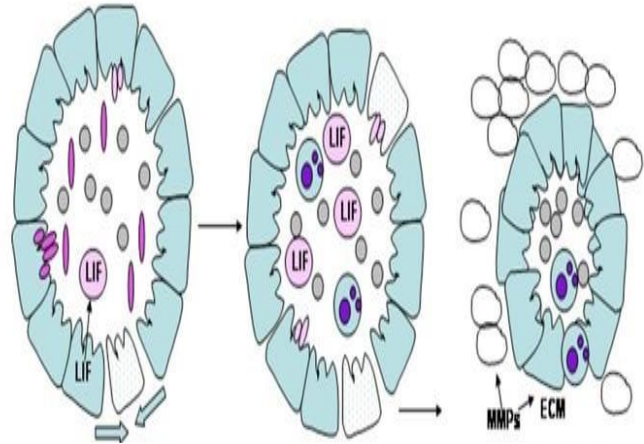


Incomplete apoptosis

## II-In adult

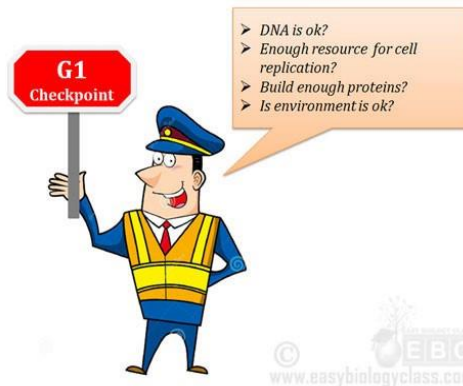### 1- Hormone-dependent:

- Involution of the endometrium during the menstrual cycle.
- Regression of lactating mammary gland after weaning.
- Regression of prostate in old males.



## II-In adult

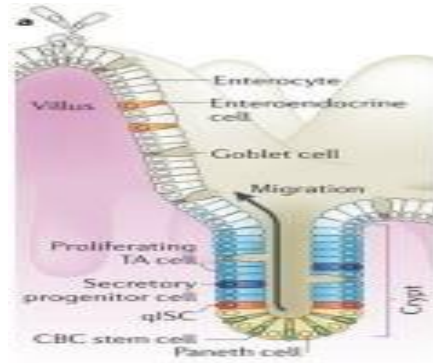
2- Elimination of cells during cell cycle when their DNA damage is not repaired.





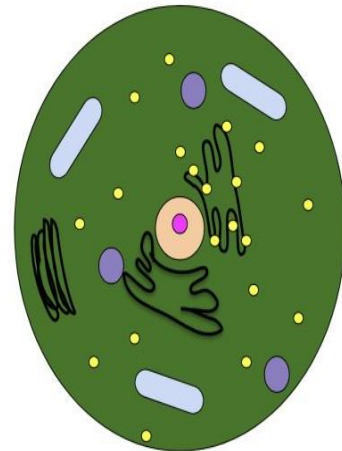
## II-In adult

3- Maintaining a constant number of cells in proliferating cell populations, e.g. intestinal epithelium.

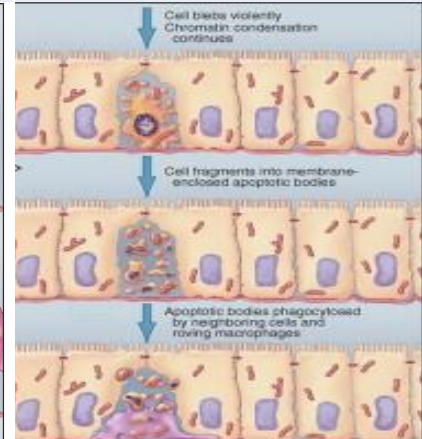
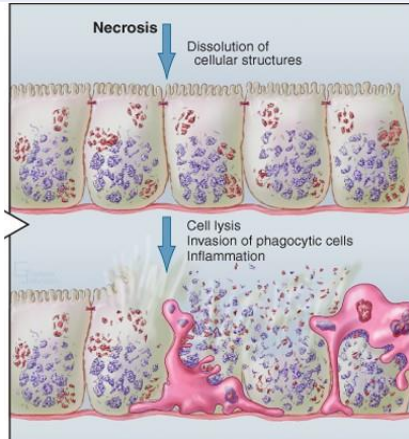


## Morphological features of apoptosis

- 1- Loss of microvilli and intercellular junctions.
- 2- Shrinkage of the cell with membrane blebbing.
- 3- Breakdown of DNA with hypercondensation of chromatin and its collapse against the nuclear periphery.
- 4- Change of cell membrane characters *without loss of its integrity*.
- 5- Cell organelles remain apparently normal but become clumped inside the cytoplasm.
- 6- Fragmentation of the cell into *apoptotic bodies* that contain fragments of the nucleus, mitochondria and other organelles.
- 7- The apoptotic bodies are removed by the phagocytic cells.

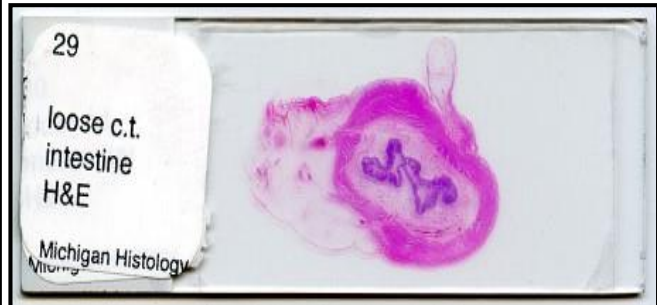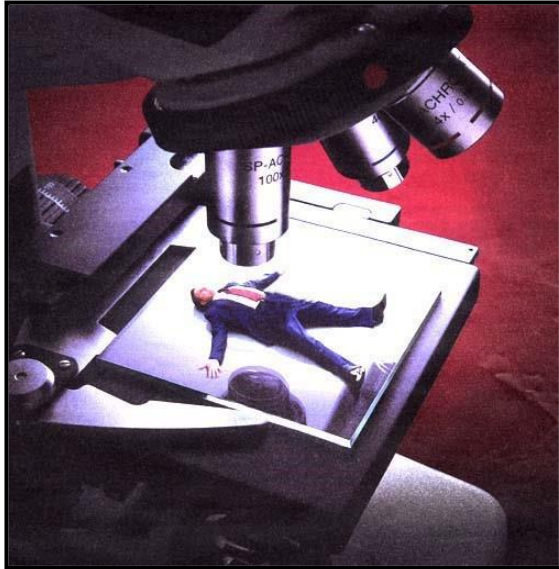


	Necrosis	Apoptosis
<b>1- Type</b>	Pathological.	Physiological.
<b>2- Cell membrane</b>	Damage with loss of its integrity.	Change of some characters without loss of its integrity.
<b>3- Organelles</b>	Broken down.	Intact.
<b>4- Proteins</b>	Denatured or coagulated.	Broken down of DNA with hypercondensation of chromatin.
<b>5- Apoptotic bodies</b>	Absent	Present
<b>6- inflammation</b>	Present	Absent



# HISTOLOGY

The study of cells and tissues a.k.a. micro-anatomy



## Tissue Preparation for Light Microscopy

1. Stabilize cellular structures by chemical fixation.
2. Dehydrate and infiltrate tissues with paraffin or plastic.
3. Embed fixed tissues in paraffin or plastic blocks.
4. Cut into thin slices of 10 micrometer thick; collect sections on slides.
5. Re-hydrate and stain with Hematoxylin (a basic dye): Stains basophilic structures (e.g. nucleic acids) blue/purple.
6. Counter-stain with Eosin (an acidic dye): Stains acidophilic or "eosinophilic" structures (e.g. proteins, membranes) red/pink.

"H & E" staining is routine, but other dyes and staining techniques may be used to visualize other structures.

**Types of tissues** (A group of cells that all perform the same specific function)

1. Epithelial Tissue – covers body surfaces and organs, lines body cavities
2. Connective Tissue – binds and supports body parts
3. Muscular Tissue – contracts producing movement

4. Nervous Tissue – responds to stimuli and transmits nerve impulses

## **1. Epithelial Tissue**

The epithelium is a sheet of aggregated cells of similar type that covers body surfaces, lines hollow organs or modified to form glands or neuroepithelium.

### **General Features of Epithelium**

- It may originate from all three embryonic germ layers (ectoderm, mesoderm and endoderm).
- It is composed of high number of closely applied cells with very little intercellular substances.
- It is separated from the underlying connective tissue by a basement membrane.
- It is avascular, blood and lymph vessels do not penetrate the basement membrane. Thus, it receives its nutritional support by diffusion.
- The epithelial cells have high capacity for regeneration.
- The epithelium can change from one form to another in a process called metaplasia.
- It performs many functions such as protection, secretion, excretion, absorption and sensory reception.

## II. Simple epithelium

It consists of single layer of epithelial cells resting on basement membrane.

### الأنسجة الطلائية

#### Simple بسيطة

(تنتظم خلاياها أساساً في طبقة واحدة)  
(Cells arranged principally in one layer)

مهدبة  
طباقية كاذبة

Pseudo-  
stratified  
ciliated



بطانة القصبة  
الهوائية  
Inner lining  
of trachea

طباقية كاذبة

Pseudo-  
stratified



الجدار المبطن  
لقنوات بعض  
الغدد الكبيرة  
Inner wall  
lining ducts  
of some large  
glands

عمودية  
مهدبة

Ciliated  
columnar



النشاء المخاطي  
المبطن لتجويف  
المنطقة الأمامية  
لقناة البيض في  
الضفدعة  
Mucous mem-  
brane lining  
the anterior  
region of the  
oviduct of  
the toad

عمودية

Columnar



النشاء المخاطي  
للغشاء الهضمية  
في الضفدعة،  
من المريء  
حتى المستقيم  
Mucous  
membrane of  
alimentary  
canal of the  
toad, from  
oesophagus  
to rectum

مكعبانية  
(مكعبة)

Cuboidal



جدار الغدة  
العرقية  
Wall of  
sweat gland

حرفشية

Squamous



البطانية ، في  
جدار محفظة  
بومان  
Endothelium;  
wall of Bow-  
man's capsule

#### a. Simple squamous epithelium

It consists of a single layer of thin flat, scale-like cells. On surface view, the cells have an irregular shape with a slightly serrated border. Each cell has a centrally located spherical or oval nucleus.

In a side view, the cells are so flat that they can only recognize by their elongated nuclei that bulge into the lumen. The cytoplasm is scanty and has sparse organelles.

Location: lung alveoli, glomerular capsule of the kidneys, lines the blood and lymph vessels (endothelium), lines the serous membranes (peritoneum, pleura and pericardium) and is called mesothelium, lines the subarachnoid and subdural spaces (mesenchymal epithelium), the anterior chamber of the eye and perilymphatic spaces of the ear.

#### b. Simple cuboidal epithelium

It consists of a single layer of cube-like cells whose width and heights are nearly equal. In sections, the cells are square with spherical centrally located nuclei. It is usually located in organs that have secretory or absorptive functions.

Locations: thyroid follicles, glandular ducts and kidney tubules.

#### c. Simple columnar epithelium

It consists of a single layer of tall, narrow cells having greater height than width. The nuclei are oval and are located near the base of the cells.

Locations: simple columnar absorptive with microvili (small intestine, gall bladder), simple columnar secretory (stomach) or simple columnar ciliated (oviducts and bronchioles).

#### d. Pseudostratified columnar epithelium

It is composed of single layer of irregular cells. All the cells rest on the basement membrane but not all the cells reach to the luminal surface. The nuclei are located at

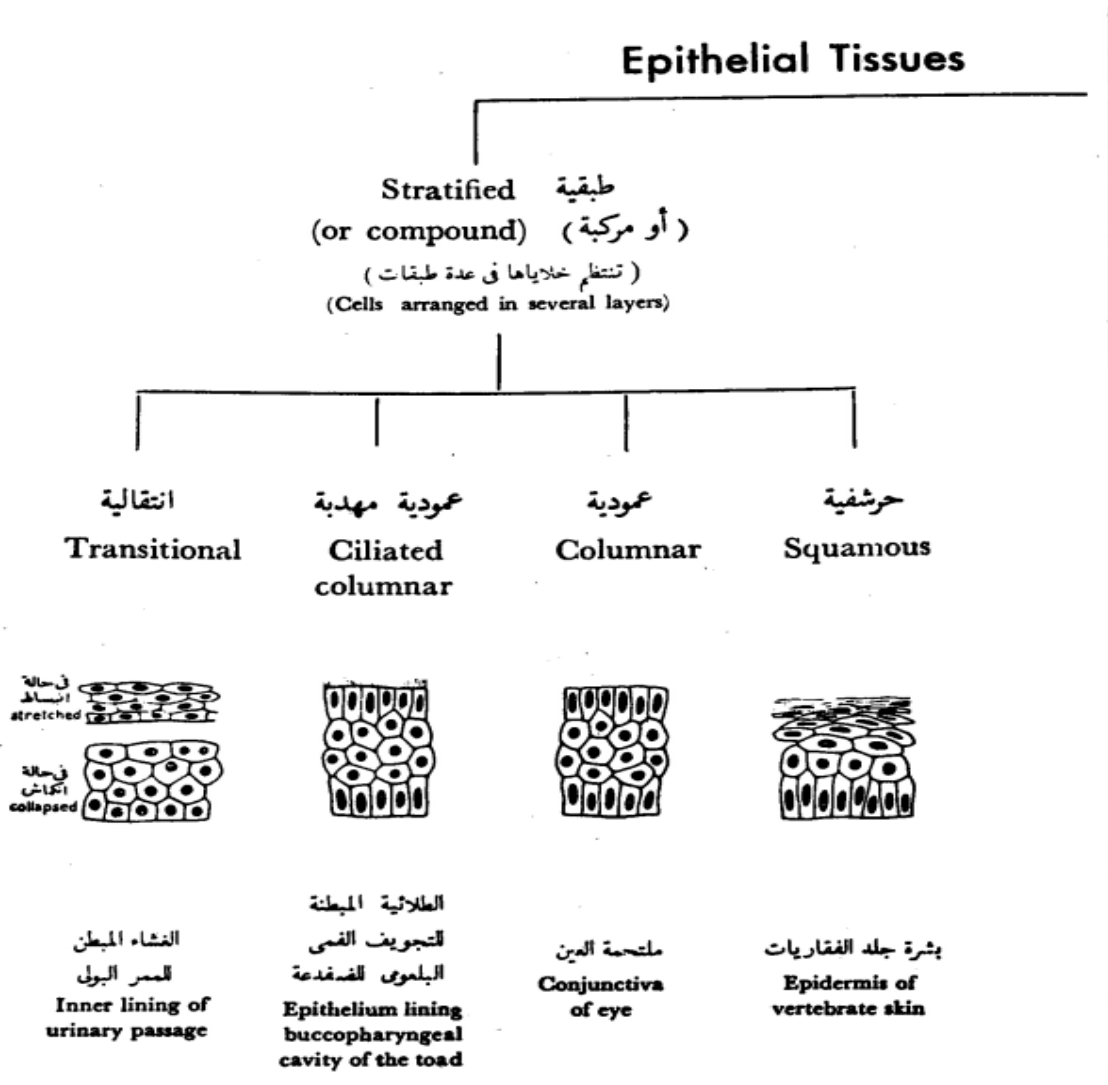
different levels, thus creating the illusion of cellular stratification. The cells reaching the surface are either ciliated or goblet cells.

The short cell acts as progenitors for the tall cells. The pseudostratified columnar ciliated epithelium may be differentiated from the stratified epithelium by 1) cilia are never exists on stratified epithelium. 2) the apical cytoplasm of the cell forming the pseudostratified epithelium does not contain nuclei.

Locations: in reproductive and respiratory epithelium.

## II. Stratified epithelium

It consists of two or more than two layers of cells.



## b. Stratified squamous epithelium

It consists of several layers of cells with only the superficial cells having squamous shape.

## c. Stratified squamous non-keratinized epithelium

It consists of three layers:

1. Stratum basale is a single layer of cuboidal to columnar cells rest on a wavy basement membrane.

2. Stratum spinosum is composed of several layers of polyhedral cells tightly adhere to each other by numerous desmosomes. In H&E sections, the desmosomal attachments appear as small spiny processes, hence the name of this layer (spiny layer or stratum spinosum). The stratum basale and the deep layer of stratum spinosum are involved in active mitosis, therefore this region is referred to as stratum germinativum.

3. Stratum squamosum is the superficial layer and is made up of few layers of flat squamous cells with ovoid small nuclei.

Locations: oral cavity, pharynx, esophagus, anal canal, and vagina. Such sites are normally subjected to moderate mechanical abrasion and are kept moist by local glandular secretions.

## d. Stratified squamous keratinized epithelium

It consists of five layers:

1. Stratum basale: consists of single layer of cuboidal to columnar cells resting on a wavy basement membrane.

2. Stratum spinosum: has the same structure as that of the stratified squamous non-keratinized epithelium.



3. Stratum granulosum consists of few layers of flattened cells having small pyknotic nuclei and rich in keratohyaline granules.
  4. Stratum lucidum found only in non-hairy skin. It is a layer of flattened, keratinized cells between the stratum granulosum and stratum corneum. It has a translucent or shiny appearance because the cytoplasm of these cells is rich in protenecious materials called eleidin.
1. Stratum corneum is the outermost layer and consists of dead, keratinized cells. The cells have lost their nuclei and their cytoplasm filled with keratin that is a water-resistant protein.
  2. Stratum disjunctum formed of groups of cells in the outermost layer of the stratum corneum that become loose and detach to constitute this layer.

Locations: epidermis, hoof and horns.

#### e. Stratified cuboidal epithelium

It consists of two or more layers of cells, with only the superficial cells having a cuboidal shape. It is frequently occurs as two-layered epithelium located in the large glandular ducts.

#### f. Stratified columnar epithelium

It consists of several layers of cells with only the superficial layer having tall columnar cells.

Locations: distal portion of the urethra, parotid and mandibular ducts, lacrimal sac and lacrimal duct.

#### g. Transitional epithelium

It is a form of stratified epithelium found only in the urinary tract (lines the ureter and urinary bladder). It is highly specialized to resist a great degree of stretch and to withstand the toxicity of urine.

In relaxed state (empty bladder) it consists of 4-5 layers of cells, the basal layer is cuboidal in shape rests on thin basal lamina . The intermediate layer consists of several layers of polyhedral or pear-shaped cells. The surface cells are large cuboidal or dome-shaped with convex outer surface and concave inner surface. Their nuclei are large, spherical with prominent nucleoli, some cells are binucleated.

In stretched state (full bladder) it appears only as two or three cell layers thickness. The intermediate and surface layers are extremely flattened. The superficial cells have a thicker plasmalemma that acts as a barrier against diffusion of fluid from the subepithelial tissue to the hypertonic urine.

### **Membrane specialization of epithelia**

The basal, luminal and intercellular surfaces of epithelial cells have a variety of specializations.

1. Basal surface
2. Basement membrane

The epithelium is separated from the underlying connective tissue by a thin membrane known as basement membrane . It consists of two layers; basal lamina and reticular lamina.

The basal lamina is synthesized by the adjacent epithelial cells and is located in contact with the epithelial basal plasmalemma. It is composed of type IV collagen embedded in an amorphous matrix of structural glycoprotein called laminin.

The reticular lamina is derived mainly from the underlying connective tissue and is located deep to the basal lamina. It consists of fine reticular fibers embedded in an amorphous ground substance.

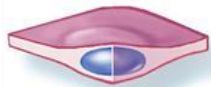In addition to underlying all epithelia, a basal lamina is found around muscle cells, neurolemmocytes and between epithelia in the renal corpuscle.

The basement membranes are difficult to resolve in common H&E sections, however, they can be selectively stained with silver (black) or PAS (magenta color).


### **Functions**

1. Support epithelial surfaces.
2. It may act as selective filter, such as the glomerular basement membrane of the kidneys.
3. It acts as a selective barrier to passage of cells between epithelia and connective tissue. For example, they permit the passage of the immune cells but prevent epithelial and connective tissue cells.


Cell shapes



Squamous

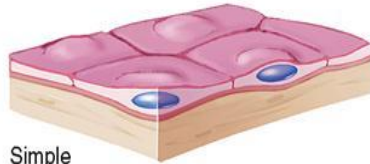

Cuboidal

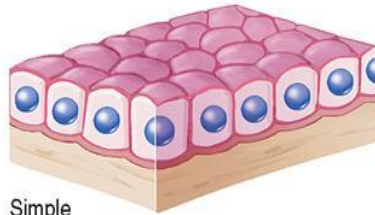


Columnar

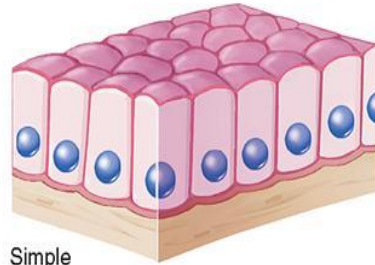
Simple



Simple squamous

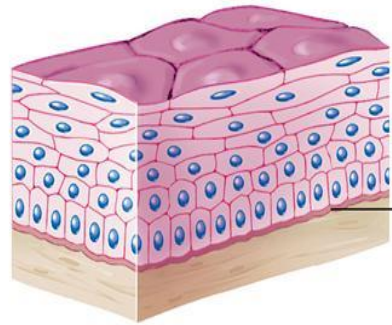


Simple cuboidal

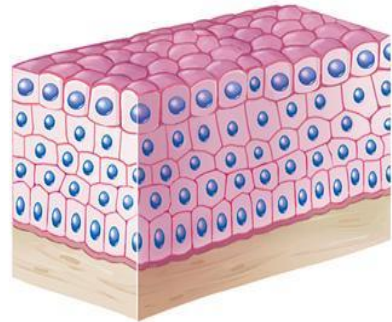


Simple columnar

Stratified

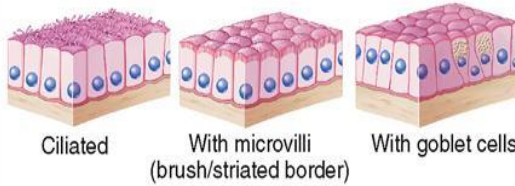


Stratified squamous



Stratified cuboidal

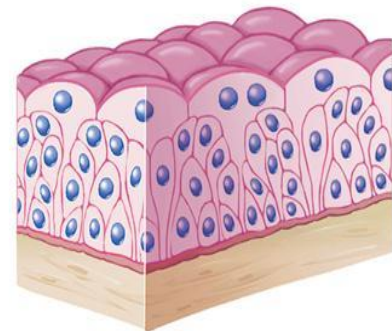
Examples of columnar tissue



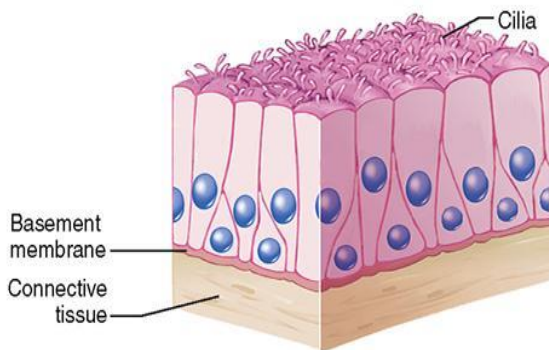
Ciliated

With microvilli (brush/striated border)

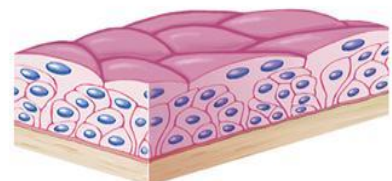
With goblet cells



Transitional, relaxed

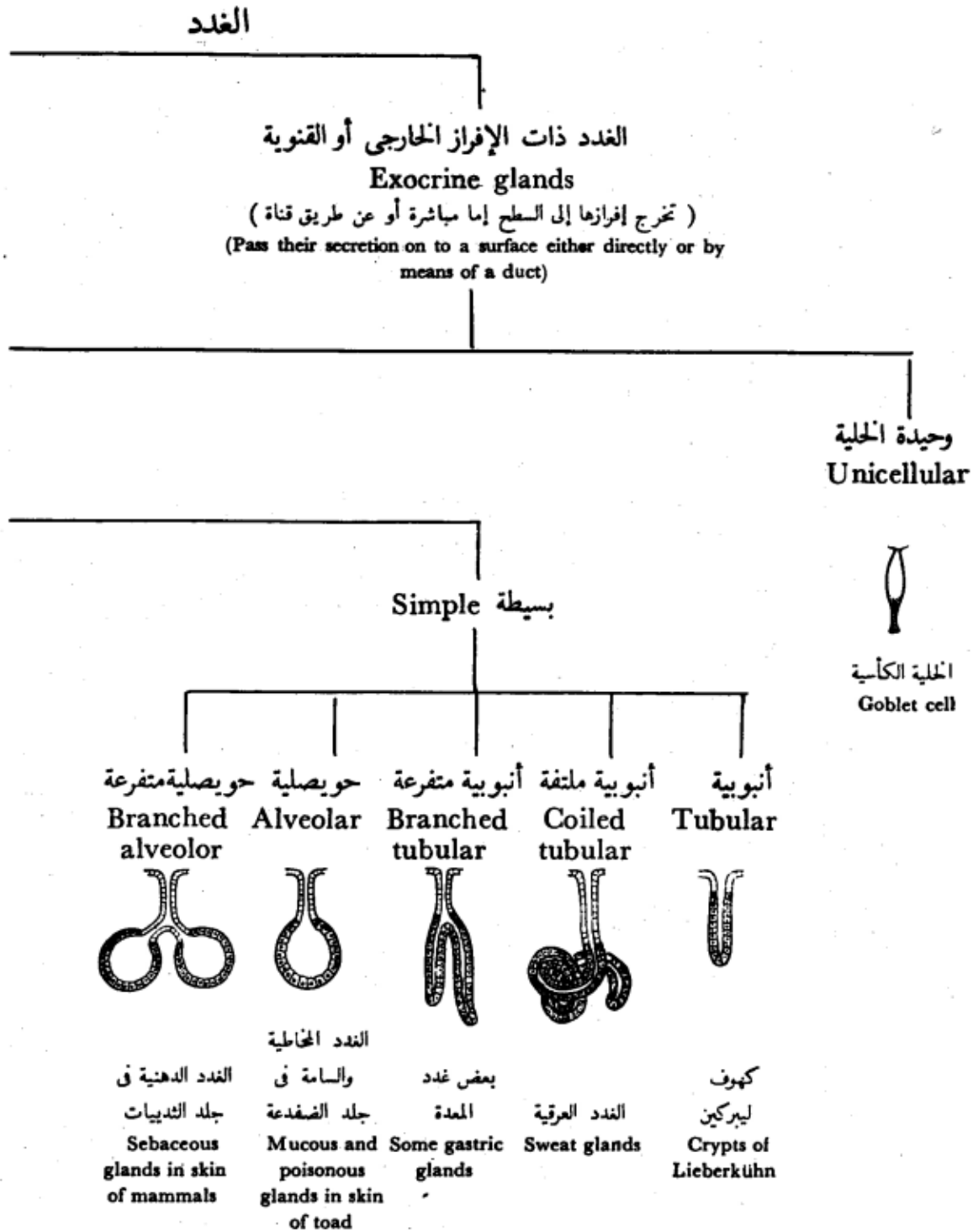


Pseudostratified columnar



Transitional, stretched

# Glandular epithelium




# The Glands

الغدد ذات الإفراز الداخلي أو الصم  
**Endocrine or ductless glands**  
 (تخرج إفرازها إلى الدم أو اللمف مباشرة)  
 (Pass their secretion directly into the blood or lymph)  
 مثل الكظر  
 e.g. Adrenal gland

Multicellular عديدة الخلايا

Compound مركبة

شبكة  
**Reticular**



كبد الثدييات  
**Liver of mammals**

أنبوبية حويصلية  
**Tubulo-alveolar**



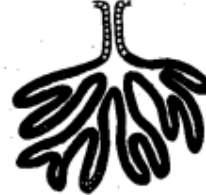البنكرياس والغدد  
 اللبنية  
**Pancreas and  
 mammary glands**

حويصلية  
**Alveolar**



الغدة اللعابية  
**Parotid salivary  
 gland**

أنبوبية  
**Tubular**



الغدة الدمعية  
**Lacrymal gland**

## **Classification**

### **1. According to the presence or absence of ducts**

#### 2. Exocrine glands

They are glands that have a duct system to convey their secretory products to the sites of utilization (e.g., salivary glands).

#### 1. Endocrine glands

They do not have a system of duct (ductless). The secretory product (hormone) reaches the site of utilization through blood or

lymph (e.g., pituitary gland and thyroid gland).

### **2) According to the number of cells forming the gland**

#### Unicellular glands

It consists of a single secretory cell in a non-secretory epithelium (e.g., goblet cells).

#### Multicellular glands

It is composed of more than one cell (e.g., salivary gland).

### **3) According to the morphology of duct and the secretory parts**

1. Simple tubular where the duct is not branched and the secretory part is in the form of tubule (e.g., glands of the large intestine).

2. Simple acinar or alveolar glands where the duct is not branched and the secretory part is in the form of alveolus or acinus (e.g., sebaceous gland and the glands of skin of amphibians).

1. Simple tubuloalveolar glands where the duct system is not branched and the secretory part is tubular and alveolar (are rare).

4. Simple branched tubular where the duct is not branched while the tubular secretory part is branched (e.g., glands of the stomach).
5. Simple branched alveolar where the duct is not branched while the alveolar secretory part is branched (e.g., sebaceous glands).
6. Simple branched tubuloalveolar where the duct is not branched while the tubular and alveolar secretory part is branched (e.g., minor salivary glands).
7. Compound tubular glands where the duct is branched and the secretory parts are tubular (e.g., liver).
8. Compound alveolar glands where the duct is branched and the secretory parts are alveolar (e.g., mammary glands).
9. Compound tubuloalveolar glands where the duct is branched and the secretory parts are tubular and alveolar (e.g., salivary glands and pancreas).

#### 4) **According to the nature of secretion**

##### 1. Mucous glands

They produce thick, viscous secretions (mucus). The cells of the mucous secretory units are cuboidal in shape and

filled with mucinogen, the precursor of mucus that stain light (foamy or vacuolated) in H&E.

The nuclei are flattened and rest on the basement membrane. The lumen is wide (e.g., palatine glands and the glands of the tongue).

##### 2. Serous glands



They produce thin watery secretion.

The cells of the secretory units are pyramidal in shape. The nuclei are spherical and situated near the center of the cells.

The cytoplasm has two zones, basal zone that appears basophilic due to the presence of rER and apical eosinophilic zone due to the presence of zymogen granules. (e.g., parotid glands and pancreas).

### 3. Seromucoid or mixed glands

They produce mixed secretions.

They consist primarily of mucous secretory units with crescent-shaped clusters of serous cells (serous demilunes)

located at the periphery of the mucous units.

The serous secretion reaches the lumen through intracellular canaliculi located between the mucous cells. (e.g., submandibular and sublingual salivary glands).

## 5) According to the mode of secretion

Merocrine glands (secretion without loss)

The cells of which remain intact and not destroyed during the process of secretion. The secretory granules are

discharged by exocytosis (e.g., salivary glands).

Apocrine glands (secretion with apical loss)

The apical parts of the cells are destroyed during the secretory process (e.g., some sweat glands and

mammary glands).

Holocrine glands (secretion with whole loss)

The whole secretory cells are discharged then destroyed to release the secretory product (e.g., sebaceous glands).

## **2. Connective Tissue**

It is one of the basic tissues of the body designed primarily to connect and support various others tissues.

### **General Features**

The connective and supportive tissues are derived from the mesoderm. However, the ectoderm of the head region may also contribute to their formation.

The connective tissues are made up of three main components:

Cells (widely separated from each other)

Fibers (different types)

Amorphous ground substances.

It is well vascularized.

It performs many functions:

a. Mechanical functions: Connection, Support, e.g., bone and Protection e.g., bone and cartilage.

b. Body defenses: Presence of phagocytes, Presence of immunocompetent cells and Physical properties of the ground substances which act against the spread of pathogenic organism.

c. Storage: Water and electrolytes, Fat in adipose tissue.

d. Temperature (heat) regulation: Adipose tissue.

e. Tissue repair: Formation of scar tissue.

### **The connective tissue proper is formed of:**

1. Cells
2. Fibers
3. Amorphous ground substance

#### **1. Connective tissue cells**

The cells of the connective tissue are divided into two main groups:

#### **Fixed or permanent cell**

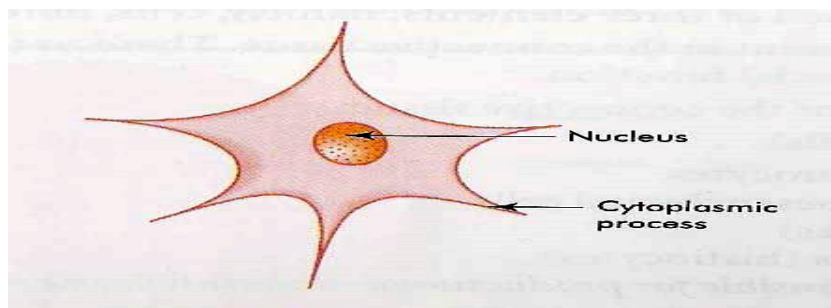
##### **Mesenchymal cells**

They have an irregular stellate shape with delicate branching cytoplasmic processes that form an interlacing network throughout the tissue. The nucleus is oval with dispersed chromatin and prominent nucleoli.

#### **Functions**

Mesenchymal cells are relatively unspecialized and are capable of differentiation into all types of connective tissue cells including that of the skeleton and smooth muscles.

Some mesenchymal cells remain in mature connective tissue and provide a source for other types of connective tissue cells.



## **Macrophages (histiocytes)**

The connective tissue macrophages may be seen in two forms: fixed macrophage or histiocytes and stimulated or active macrophage.

### **a. Fixed macrophages or histiocytes**

It is considered one of the fixed connective tissue cells. The cells are stellate or fusiform that are difficult to distinguish from fibroblasts.

They could be differentiated from fibroblasts through:

They have smaller and darker nuclei.

They give a strong positive reaction when stained for lysosomal enzymes such as acid phosphatase.

They can be stained vitally with vital dyes such as trypan blue.

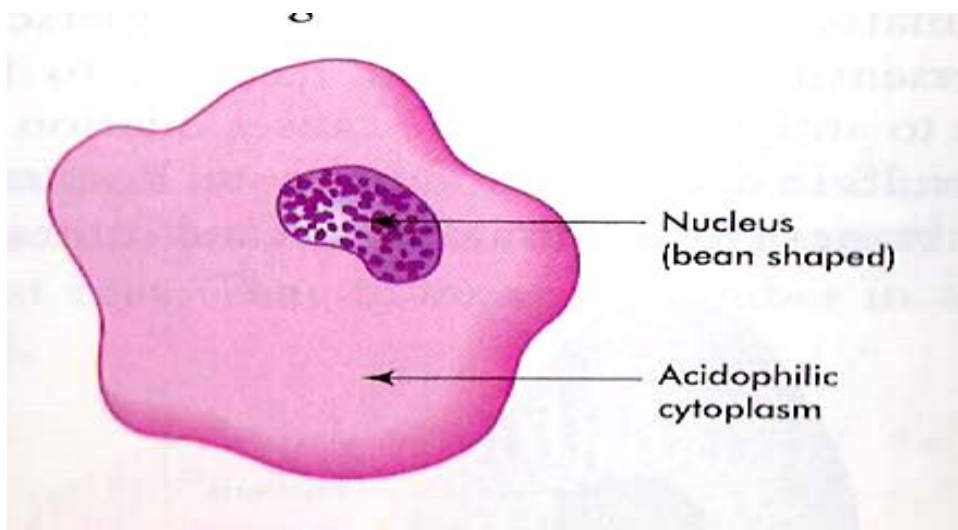
### **b. Stimulated or active macrophages**

They are large ovoid or spherical cells with eccentric kidney-shaped nuclei and foamy cytoplasm.

At the EM level, the macrophage nucleus is indented with heterochromatin typically clumped around the nuclear envelope.

Actively phagocytic cells exhibit irregular cytoplasmic projections or pseudopodia.

The cytoplasm shows well-developed Golgi apparatus, abundant lysosomes, many phagosomes and residual bodies, a few mitochondria and variable amount of free ribosomes and rER.



## Functions

Phagocytosis.

Antigen processing and antigen presentation thus participating in both humoral and cell mediated immunity.

Synthesis and secret many substances such as lysozyme (antibacterial agent), interferon (antiviral), interleukin that are essential for the proliferation of T and B-lymphocytes.

Many macrophages can fuse with each other forming large multinucleated cells called foreign body giant cells that can engulf large foreign bodies.

The macrophage and blood monocytes are considered identical. Monocytes circulate in the blood then they migrate to the connective tissue where they are called macrophages.

The macrophages are present practically in all organs, constituting a diffuse system called mononuclear phagocyte system.

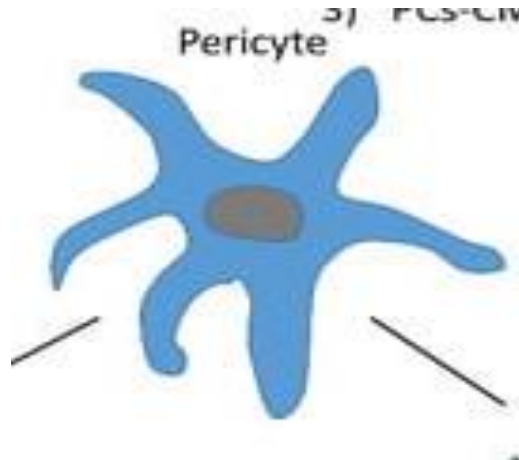
They may have other names such as: osteoclasts in bone; monocytes in blood; dust cells or heart failure cells in lung alveoli; Kupffer cells in liver, and microglia in the central nervous system.

## Pericytes

Pericytes are elongated connective tissue cells with long cytoplasmic processes located external to the endothelium of blood capillaries and small venules.

They share a common basal lamina with the adjacent endothelial cells.

They have a fusiform nucleus and scanty cytoplasm that contains many mitochondria, rER, free ribosomes, and small Golgi complex.



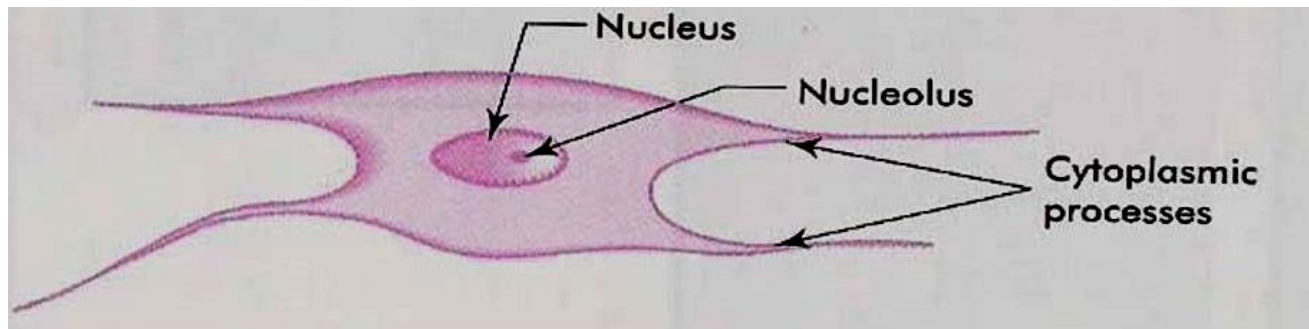
## Functions

The pericytes are undifferentiated cells, they serve as progenitor for fibroblasts, osteocytes, chondrocytes and smooth muscle cells.

## Fibroblasts and fibrocytes

Fibroblasts or fiber-forming cells are the most common type of fixed connective tissue cells. Active fibroblasts are demonstrated in healing wounds. They have large ovoid lightly stained nuclei with prominent nucleoli. The cytoplasm is extensive and strongly basophilic with numerous interconnected cytoplasmic extensions. At the EM level, the cytoplasm is rich in rER and the Golgi apparatus is well developed.

The inactive fibroblasts (fibrocytes) are smaller and appear spindle in shape with fewer processes. At the EM level, the small quantities of cytoplasm contain sparse network of rER, poorly developed Golgi and few organelles.



## **Functions**

Fibroblasts synthesis and secrete the precursors of collagen (tropocollagen), elastin (tropoelastin), the glycosaminoglycans, and all other extracellular components.

They are the principal cells involved in wound repair and growth of connective tissue.

## **Free, wandering or visitant cells of connective tissue**

### **Adipose cells (Adipocytes)**

There are two types of fat cells; white (monolocular) and brown (multilocular).

The white adipocytes are polygonal or spherical in shape. The cell occupied by a single large lipid droplet surrounded by a thin rim of cytoplasm.

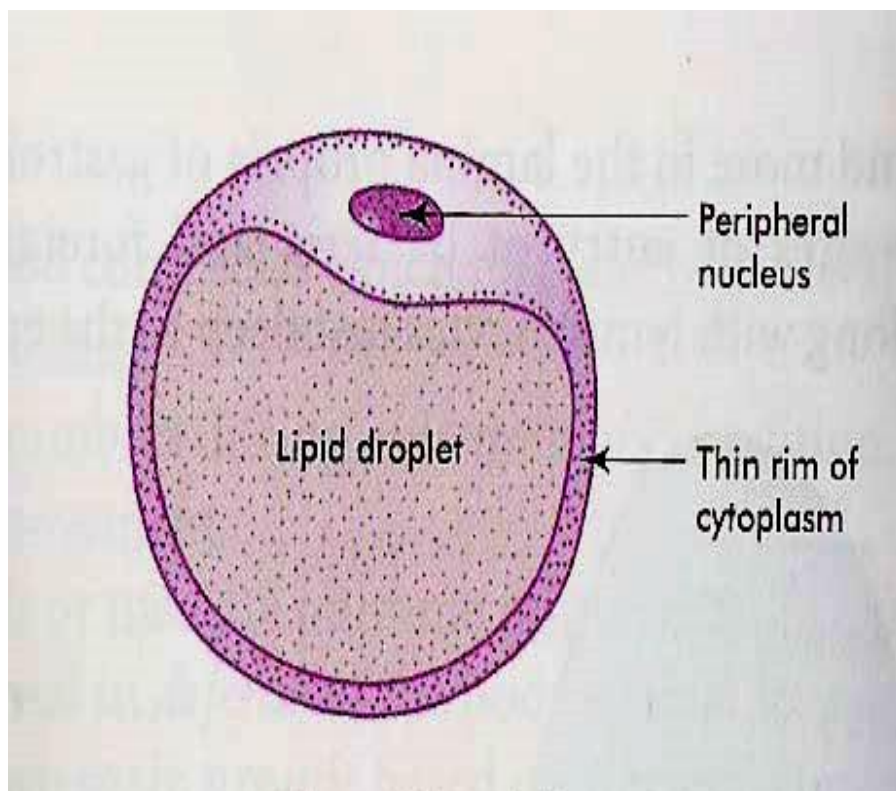
The nuclei are flattened and displaced to one side. In H&E sections, fat is dissolved during the dehydration and clearing processes.

Fat cells appear as large clear spaces surrounded by thin layer of cytoplasm giving the cells a signet ring appearance. With EM, the lipid droplet is surrounded by a thin layer of cytoplasm contains a flattened nucleus, a small Golgi apparatus, rER and

mitochondria. The lipid inclusion is not membrane-bounded, but the cytoplasm adjacent to its surface often contains microfilaments.

The white fat cells tend to occur along the course of blood vessels and they may also occur either singly or in-groups within the loose connective tissue layers.

The brown adipocytes are smaller than white one, the nuclei are oval, eccentricity located and surrounded by a significant amount of strongly acidophilic cytoplasm.



**They could be differentiated from the white adipose tissue on the basis of:**

Lipid is stored as multiple, small droplets (multilocular fat cells) that give the cytoplasm a vacuolated appearance.

Brown adipocytes have relatively large amount of cytoplasm contains abundant mitochondria that are rich in cytochromes, which give the brown color of this tissue.

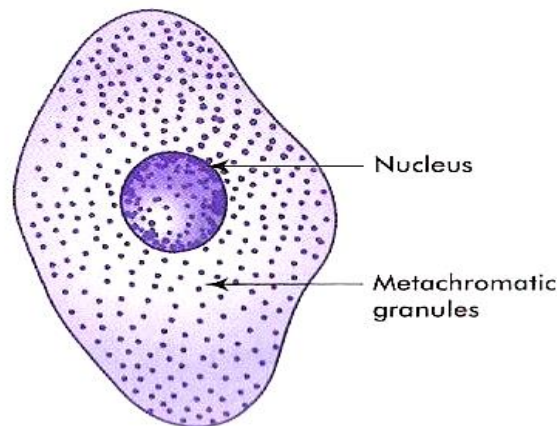
Brown adipose tissue is more vascular than the white one.



## Mast cells

Mast cells are found in the loose connective tissues specially that of the skin and intestine, particularly in association with blood vessels. They are large polymorphic, spherical or ovoid cells with spherical centrally located nuclei. The nuclei are completely obscured by numerous large metachromatic granules (they take a different color than that of the dye used. (e.g., when stained with toluidine blue they take red color). This property is known as metachromasia.

With EM, the granules are membrane-bounded and contain dense amorphous materials. The cytoplasm contains a prominent Golgi complex, cisternae of rER, free ribosomes and mitochondria.



**Fig. 4.6** Mast cell

## Functions

The surface of the mast cell contains specific receptors for immunoglobulin E (IgE). In allergic and anaphylactic reactions, the interaction of foreign antigen with the antibody bound to the surface of mast cells induces the release of the chemical mediators stored in mast cell granules that promote the immediate hypersensitivity reaction or anaphylaxis.

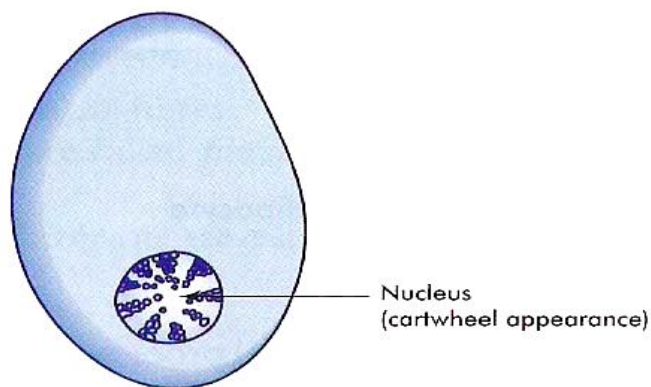
The granules of the mast cells contain histamine, heparin, ECF-A (eosinophil chemotactic factor for anaphylaxis) and serotonin in rat and mouse. The histamine causes dilatation of small vessels and increases capillary permeability. The serotonin is a vasoconstrictor. The heparin is a potent blood anticoagulant.

### **Plasma cells**

Plasma cells are spherical, oval or pear-shaped cells with spherical, eccentric nucleus. The nuclear chromatin is condensed peripherally giving the nucleus a characteristic “cartwheel” appearance. The cytoplasm is strongly basophilic with a prominent negative Golgi image.

With EM, the cytoplasm contains a prominent Golgi apparatus, abundant rER with dilated cisternae contain electron-dense spherical inclusion known as Russel bodies, free ribosomes and mitochondria.

They are located in the loose connective tissue specially that of the digestive, respiratory and female reproductive system. Plasma cells develop from B-lymphocytes.



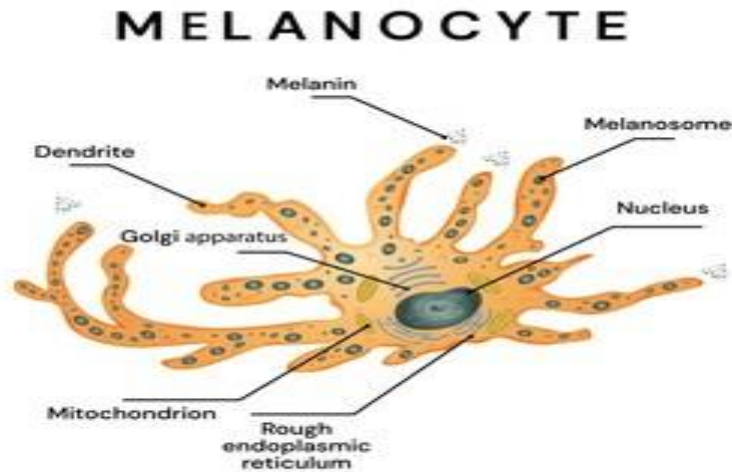
**Fig. 4.5** Plasma cell

### **Functions**

Production of antibodies.

## Melanocytes

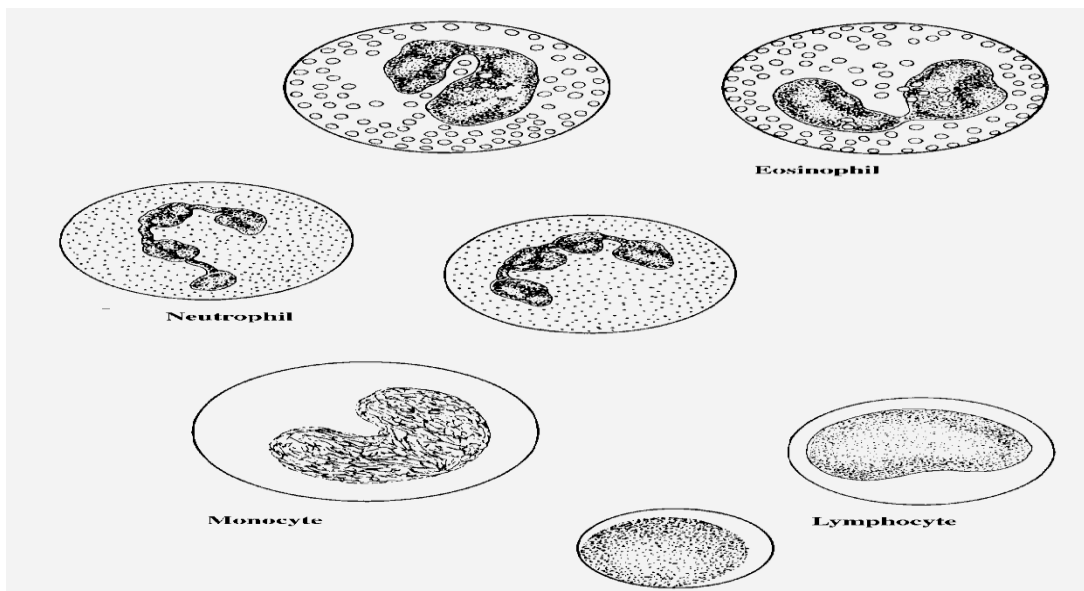
Melanocytes are derived from neural crest. They are large pigmented cells with numerous long branching processes. They occur in epidermis, uterine caruncles of sheep, meninges, choroid and iris.



shutterstock.com · 1449276722

## Other connective tissue cells

They include lymphocytes, monocytes and granulocytes (especially eosinophils and neutrophils).



## **2. Connective tissue fibers**

### **White collagenous fibers**

They are called white because they have a white color when fresh, called collagenous because on boiling they become hydrated and yield gelatin (glue). (Kolla=glue).

They are destroyed with weak acids and alkalis and digested by pepsin and collagenase (which is an enzyme produced by the testis and some pathogenic bacteria).

With LM, they are arranged into wavy bundles. The bundles may branch, but the individual fibers do not. They are acidophilic, they stain pink with H&E; red with Van Gieson's; green with Masson's trichrome stain and blue with Mallory stain.

With EM, they are formed of bundles of microfibrils know as collagen fibrils. The fibrils are formed of tropocollagen molecules, and they have a characteristic periodicity repeated at 64 nm intervals.

This periodicity is due to the unique arrangement of tropocollagen molecules where they are arranged in end-to-end manner with each molecule overlapping the adjacent one by one quarter of its length.

Collagen is secreted into the intercellular matrix as tropocollagen molecules that polymerize to form collagen of 5 different types:

### **Collagen type I**


It constitutes about 90% of total collagen in the body. It is found in fibrous connective tissue, skin tendon, ligaments and bone. The tropocollagen molecules are arranged to form fibers. Parallel collagen fibers are further arranged into strong bundles. These bundles are visible with LM and are responsible for the great tensile strength of this type.

## **Collagen type II**

It is found in hyaline cartilage and consists of collagen fibrils dispersed in the ground substance.

## **Collagen type III (reticular fibers)**

They form delicate supporting network in liver and lymphoid organs.



## **Collagen type IV and V**

They do not form fibrils; type IV collagen is present in basement membranes and type V is found in small amount in most connective tissue.

## **Yellow elastic fibers**

Elastin is a rubber-like material that is arranged as fibers and discontinuous sheets (in the wall of arteries). When present in sufficient number, elastic fibers give a yellow color to the fresh tissue (e.g., ligamentum nuchae of ruminants).

Elastic fibers are resistant to boiling and to hydrolysis by acid or alkali. They are also resistant to digestion by trypsin, but elastase from pancreas will digest it.


The elastic fibers can be stretched as much as 2.5 times their original length, to which they return when, released. They are found in organs whose normal function requires great elasticity such as vocal cords, lung, ligamentum nuchae, skin and arteries.

They are not identified in H&E sections but the large elastic fibers in elastic ligaments and the elastic sheets in arterial walls are seen as highly refractile light pink strands.

They can be selectively stained by Verhoeff's stain, orcein (brown) and resorcin fuchsin (blue).

With EM, elastic fibers have two main components: Elastin that appears as an amorphous protein of low electron density. Microfibrils that are embedded in the periphery of the fibers and occurring in small fascicles in its interior.

They are synthesized by fibroblasts and smooth muscle cells as tropoelastin. The microfibrils are secreted prior elastin and provide scaffolding on which elastin forms fibers and sheets.



## **Reticular fibers**

The reticular fiber form delicate network rather than coarse bundles around capillaries, muscle cells, nerve, adipose cells and liver cells. They also constitute the fibrous supporting tissue of endocrine, lymphoid and blood forming organs.

With LM, reticular fibers are not visible in H&E sections but can be selectively stains black by silver impregnation (hence the term argyrophilic or argentaffin fibers) or with the periodic acid-schiff (PAS) reagent.

With EM, they are actually individual collagen fibrils (type III collagen) coated by glycoproteins. They have the same 64-periodicity typical of collagen fibrils.

### **3. Ground substance**

The ground substance is an amorphous gel-like material composed of polysaccharide chains (glycosaminoglycans) bound to protein.

With LM, in H & E sections, they are not visible when present in low concentration. However, at higher concentration (as in hyaline cartilage), they stain basophilic. When stained with toluidine blue or crystal violet, they are metachromatic (take a different color than the color of the dye used). The ground substance includes two major groups:

Non-sulfated glycosaminoglycans (hyaluronic acid)

The hyaluronic acid consists of long molecule that form a network whose spaces are filled with tissue fluid forming gel-like material. The hyaluronic acid predominate in loose connective tissue, vitreous humor, synovial fluid and umbilical cords.

Sulfated glycosaminoglycans

Chondroitin-4-sulfate and chondroitin-6-sulfate are abundant in cartilage, bone, skin, and cornea.

Dermatan sulfate is found in skin, tendon, ligamentum nuchae, sclera and lung.

Keratan sulfate is present in cartilage, bone and cornea.

Heparan sulfate in arteries and lung.

Heparin in mast cells, in lung, liver and skin.

### **Functions of the ground substance**

The glycosaminoglycans and proteoglycans are highly hydrophilic. The tissue fluid within the meshes permits the diffusion of nutrients and metabolites between the connective tissue cells and circulatory system.

The gel-like nature of the hyaluronic acid is thought to act as a barrier against the spread of bacteria that may enter the tissues. Invasive bacteria produce the enzyme hyaluronidase that facilitates their spread.

## **Types of Connective tissue**

### **I) Embryonic connective tissue**

#### Mesenchyme

The mesenchyme is primitive embryonic connective tissue from which all other connective tissue types are derived. It consists of primitive mesenchymal cells that have an irregular, stellate shape with delicate branching cytoplasmic processes that form an interlacing network throughout the tissue. The extracellular material consists of non-sulfated amorphous ground substances with no fibers.

#### Mucous connective tissues

The mucous connective tissue is found in many parts of the embryo especially under the skin and in the umbilical cord “Warton’s Jelly”.



In adults, it is found in omasal laminae and in the comb and wattles of the chickens. It consists of large stellate, fibroblasts with branching and anastomosed cytoplasmic processes. Few macrophages and lymphoid cells are also present. The intercellular substance is rich in mucin and contains thin collagenous fibers which increase with age.

## **II) Adult connective tissues**

### **Loose (ordinary or areolar) connective tissue**

It is the most widely distributed type of connective tissue in the adult animals. It consists of all types of connective tissue cells, fibers that are embedded in non-sulfated amorphous ground substances. The cells are relatively more abundant than fibers that are loosely arranged leaving comparatively wide spaces in between.

The loose connective tissue is present around blood vessels and nerves and between muscle bundles. It supports the epithelial lining of gastrointestinal tract, respiratory and urinary tracts, also forms the deeper layers of skin and occurs as loose interstitial packing in many other organs.

#### **1. Dense connective tissue**

The fibers are more abundant than cells and amorphous ground substances. According to the arrangement of its fibrous component, two types are identified:

#### **2. Dense irregular connective tissue**

It is formed of the same cell types like the loose connective tissue (all connective tissue cell type), although fibroblasts usually predominate, they are inactive with highly condensed nuclei and minimal cytoplasm.

The collagen fibers predominate, and they are arranged in coarse irregular interwoven bundles with very narrow space in-between.

It is found in lamina propria of the initial portion of the digestive tract, the capsule of the lung, the capsule of various organs (spleen, liver, kidney, testis), fascia, joint capsule and dermis.

### 3. Dense regular connective tissue

#### a. Dense regular collagenous (tendon)

The tendon consists of bundles of parallel collagen fibers that are bounded together by sparse, loose connective tissue contains small blood vessels, nerves and active fibroblasts (peritendineum interna).

The peritendineum interna is continuous with the peritendineum externa that is a loose connective tissue capsule that covers the outer surface of the tendon.

The active fibroblasts that are located in the loose connective tissue layer between the bundles are responsible for the repair of tendons whenever the need arises.

The fibrocytes located between the collagen fibers are inactive cells and appear as long, flat cells with wing-like cytoplasmic processes extending between adjacent collagen fibers, giving them a stellate appearance (bird cells) in cross sections.

#### b. Dense regular elastic (Elastic ligaments)

It consists of branching and interconnected parallel elastic fibers surrounded by loose connective tissue (e.g., ligamentum nuchae and the elastic fascia of the abdominal muscle of herbivores).

### 4. Reticular connective tissue

It is made up of stellate reticular cells and a complex network of delicate thin branched and anastomosed reticular fibers.

It forms a delicate supportive framework for many highly cellular organs such as endocrine glands, liver and lymphoreticular organs (tonsils, spleen, and lymph nodes).

## 5. Adipose tissue

It is a special type of connective tissue designed to perform many functions such as mechanical protection, thermal insulation and body metabolism. There are two types of adipose tissue white and brown adipose tissues.

## 6. White adipose tissue


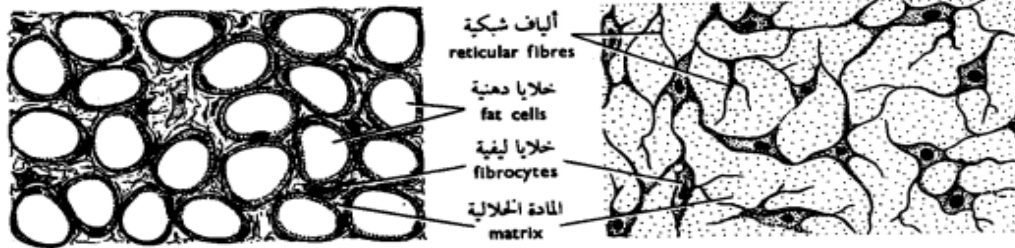
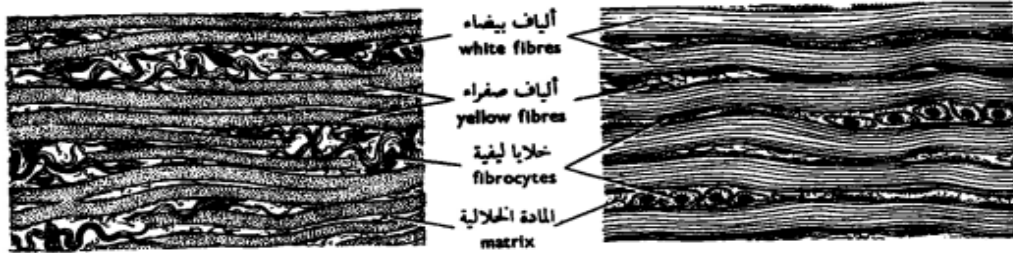
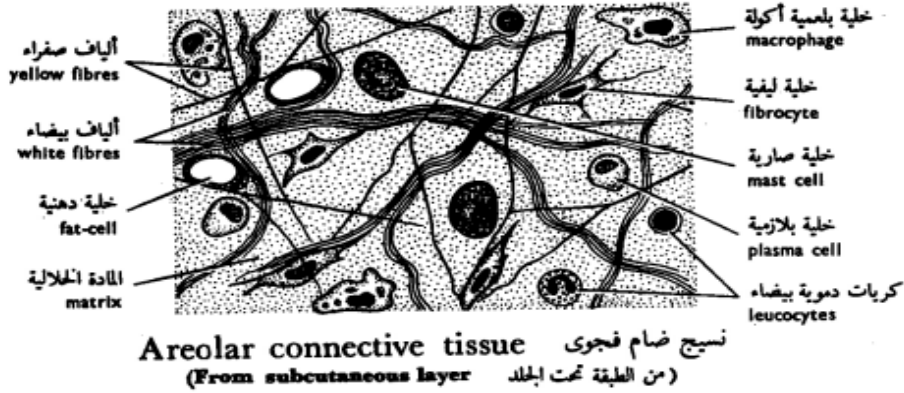
It is distributed throughout the body especially in the deep layer of the skin and around the kidneys. White fat is divided by septa of loose connective tissue into clusters of adipose cells known as lobules. A delicate network of collagen and reticular fibers that support a dense capillary plexus and nerve fibers surrounds each adipocyte. In addition, the narrow intercellular spaces contain a few fibrocytes, mast cells, and scanty amorphous ground substance.

Fat stored in adipocytes as single large droplet (monolocular fat cell) which occupies most of the cytoplasm. The nucleus is compressed and displaced to one side of the cytoplasm giving the cells their characteristic signet ring appearance.

## 7. Brown adipose tissue

It is a highly specialized form of adipose tissue found in newborn mammals, rodents and some hibernating animals, where it plays an important part in body temperature regulation.

The brown adipose tissue is more vascular than the white ones. The brown adipocytes are smaller than white one, the nuclei are oval, eccentricity located and surrounded by a significant amount of strongly acidophilic cytoplasm.



شكل ٣٩ - الأنسجة الضامة الأصلية  
**FIG. 39 - CONNECTIVE TISSUES PROPER**

## **Skeletal Connective tissue**

### **1- Cartilage**

The cartilage is a semi-rigid, flexible, avascular form of connective tissue designed to perform a supportive function. It is composed of cells and matrix (fibers and amorphous ground substance).

Types of cartilage

#### **1. Hyaline cartilage**

The hyaline cartilage consists of:

Perichondrium

It is a vascular connective tissue capsule that invests the external surface of cartilage. It is composed of two layers: a) Outer fibrous layer, composed of dense irregular connective tissue containing blood vessels and nerves. b) Inner cellular or chondrogenic layer made up of chondroblasts that are actively involved in production of matrix during cartilage growth and regeneration.

#### **Cartilage cells**

Chondroblasts (cartilage forming cells)

They are found mainly in the inner chondrogenic layer of the perichondrium. They are oval or spindle-shaped cells with oval euchromatic nuclei. The cytoplasm is basophilic rich in ribosomes, rER and Golgi saccules. They secrete matrix around themselves and become deeply buried in the cartilage matrix where they are called chondrocytes.

Chondrocytes (mature cartilage cells)

They are located in tiny spaces within the cartilage matrix known as lacunae.

Beneath the perichondrium, chondrocytes are small and their lacunae are elliptical with their long axes parallel to the surface.

Deep within the cartilage, the cells are larger and polyhedral with short processes. They have a spherical nucleus with one or more nucleoli. The cells accumulate glycogen and lipid in their cytoplasm those appear vacuolated.

Some lacunae contain only one cell; others contain two, four, or sometimes six cells. These multicellular lacunae are called cell nests or isogenous groups because each cluster is the progeny of one cell.

### Matrix

The hyaline cartilage matrix is an amorphous gel consists mainly of sulfated glycosaminoglycans that are strongly basophilic, PAS positive and metachromatic.

The fibrous component represented by fine collagen fibrils made up of type II collagen that has the same index of refraction as the amorphous ground substance, therefore, they can not be seen in common H&E sections.

The hyaline cartilage occurs in many places such as articular surface, fetal skeleton, nasal septum, larynx, trachea and bronchi.

## **2. Elastic cartilage**

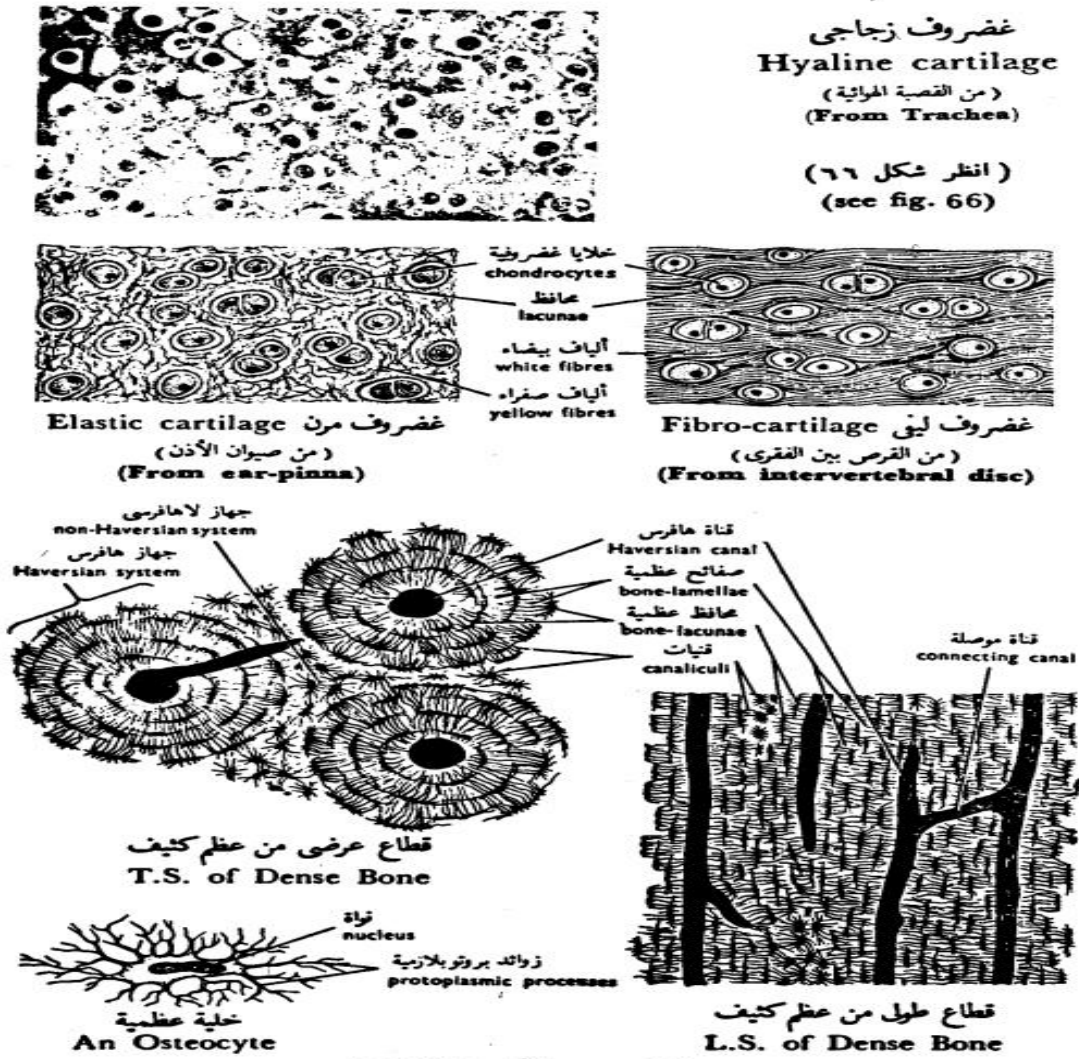
The histological structure of the elastic cartilage is similar to that of the hyaline cartilage except: 1) cell nests are few. 2) The matrices contain a dense network of elastic fibers that are visible in H&E sections.

The elastic cartilage occurs in the external ear and external auditory canal, the epiglottis, corniculate and cuneiform cartilage of the larynx.

### 3. Fibrocartilage

It is a transitional form between hyaline cartilage and dense regular connective tissue. It consists of regular parallel bundles of collagen fibers separated by encapsulated chondrocytes that occur singly, in pairs or sometimes form rows. The ground substances are little and only found around the chondrocytes. The fibrocartilage is found in the intervertebral discs, menisci of the stifle joint and at the attachment of tendons and bones.

Calcification of the cartilage matrix may occur in aging and during bone development. In this case, diffusion is blocked and the cartilage cells die.



شكل ٤٠ - الأنسجة الهيكلية  
FIG. 40 - SKELETAL TISSUES

## 2- Bone

The bone is a specialized form of connective tissue in which the extracellular components are mineralized. Like other connective tissues, bone is composed of cells (osteogenic cells, osteoblasts, osteocytes, osteoclasts) and matrix (a mixture of collagen fibers, ground substance and mineral salts).

### Bone cells

#### Osteogenic cells

They are undifferentiated cells found in the endosteum, the inner osteogenic layer of the periosteum and the lining of the osteonal canal. The cells have pale-staining oval or elongated nuclei and little acidophilic or faintly basophilic cytoplasm.

They develop from the mesenchymal cells and they are capable in times of need (i.e. bone growth or fracture repair) to divide and transform into any of the other bone cells.

#### Osteoblasts (bone forming cells)

They are small, ovoid branching cells. During active bone formation, they are arranged in an epithelial-like layer of cuboidal cells connected to each other by short slender processes.

The nucleus is oval, eccentric (at the cells end away from the bone surface), and euchromatic with prominent nucleolus.

The cytoplasm is deeply basophilic and shows a negative Golgi image near the nucleus.

With EM, the cytoplasmic features reflect a high rate of protein synthesis with abundant rER and prominent Golgi apparatus.



## **Functions**

Osteoblasts are responsible for the formation of organic components of bone matrix (osteoid tissue).

They secrete matrix vesicles that participate in the nucleation of crystalline bone minerals.

Resorption of osteoid tissue (unmineralized matrix).

Osteocytes (mature bone cells)

The osteocytes are the principal cells of mature bone. They are located inside lacunae within calcified bone matrix. They are less active than osteoblasts and can not divide inside their lacunae. The cell body is flattened with numerous cytoplasmic processes that extend through tiny channels within the bone matrix called canaliculi.

The processes of the adjacent cells are interconnected with each other via gap junctions permitting flow of ions and small molecules between blood and osteocytes.

With LM, the nuclear and cytoplasmic characteristics are similar to those of osteoblasts except the Golgi region is less prominent and the cytoplasm is less basophilic.

With EM, the rER and the Golgi are still prominent, however, osteocytes situated deeper in bone matrix may have less prominent rER and Golgi saccules.

## **Functions**

Preserve and maintain the integrity of the bone matrix.

Osteoclasts

They are large (about 50  $\mu$ m) multinucleated cells lining in depressions on the bone surface called Howships lacunae. With LM, the cell has an irregular shape with an

acidophilic foamy cytoplasm. The part of the cell border facing the bone surface has striated border-like structure.

With EM, the striated border seen with LM is formed of: 1) Ruffled border that is made up of branching finger-like processes projecting from the cell membrane. 2) Collagen fibrils exposed through extracellular digestion of bone matrix.

Osteoclasts originate from blood monocytes, which fuse with each other to form multinucleated osteoclast.

## **Functions**

Degradation of mineralized bone matrix through:

Focal decalcification through production of organic acids (carbonic, lactic and citric) to generate local acidic environment capable of dissolving calcium from the bone matrix.

Extracellular digestion of the organic components of the bone matrix through liberation of acid hydrolase to the extracellular matrix.

## **Bone matrix**

It consists of organic and inorganic elements:

### **Organic matrix**

It is made up of a mixture of glycoprotein ground substance and type I collagen.

### **Inorganic matrix**

It consists of mineral salts, mainly calcium phosphate that is deposited as submicroscopic hydroxyapatite crystals within the collagen fibers.

## Types of bone

### Compact bone

This type forms the dense wall of the shaft or diaphysis of the long bone

### Cancellous or spongy bone

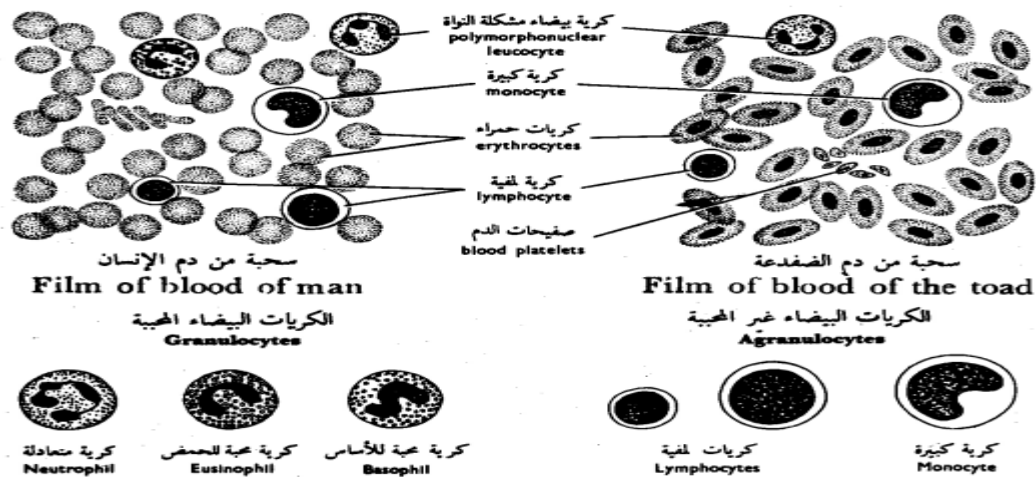
The cancellous bone is composed of a network of bony trabeculae separated by interconnecting spaces containing bone marrow. The trabeculae are thin and composed of bone matrix with lacunae containing osteocytes, which exchange metabolites via canaliculi with blood sinusoids in the marrow cavity.

The trabeculae are lined by endosteum that contains osteogenic cells, osteoblasts and osteoclasts. Cancellous bone forms the epiphysis of the long bone and the cores of flat and irregular bone.

### Vascular connective tissue

## Blood

Blood is one of the body fluid that is formed of a variety of cells suspended in a fluid medium, the plasma.



شكل ٤١ - الأنسجة الوعائية  
**FIG. 41 - VASCULAR TISSUES**

## **Blood cells**

The blood cells are grouped into three main categories: red blood cells (erythrocytes), white blood cells (leukocytes) and blood platelets (thrombocytes).

### **2- Red blood cells (Erythrocytes)**

The mature red cells of domestic mammals are non-nucleated , biconcave discs.

In pig and goat, red blood cells have no biconcavity and therefore appear as flattened discs.

In tylopoda (camels and ilama), they are elliptical, biconcave and non-nucleated. In birds, reptiles, fishes and amphibian, they are oval, biconvex and nucleated.

The size of RBCs range from 4-7 mm, the largest erythrocyte is found in the dog (7mm) and the smallest in the goat (4 mm).

The number of the RBCs varies among species, in dog is about 7 million/mm<sup>3</sup>, cattle 6.3 million, goat 14 million and horse 9.5 million.

With LM, the erythrocytes in a stained blood smear are stained pink due to their high content of hemoglobin. They have a central pale staining region due to their biconcave disc shape.

The erythrocytes sometimes adhere to each other via their broad surface and become arranged in long chains similar to a stack of coins. This arrangement is called rouleaux.

With EM, the shape of the erythrocytes depends on the plane of section through the cell. The cytoplasmic content of erythrocytes appears electron dense due to the iron atoms of hemoglobin.

When placed in hypotonic solution (lower concentration than plasma), the RBCs swell and ruptures. This is called hemolysis.

In hypertonic solution (higher concentration than plasma), the cell volume diminishes and the cells become crenated.

The life span of erythrocytes is about 120 days. Spleen, bone marrow and liver phagocytes engulf old RBCs. The iron of the hemoglobin is reused in formation of new cells. The porphyrin portion is used to form bilirubin or bile pigment.

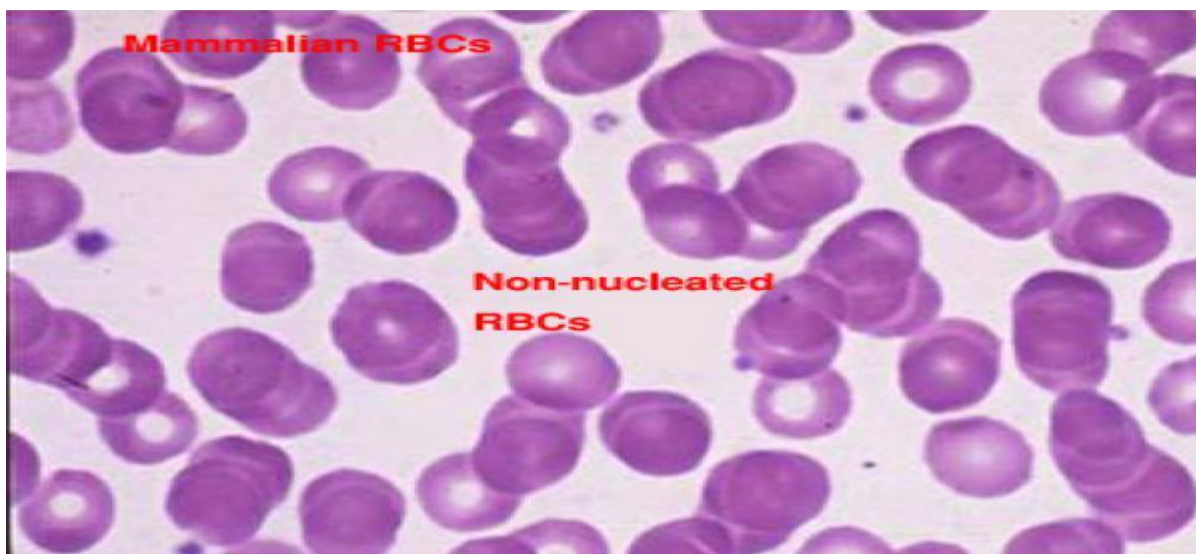
The erythrocytes are highly adapted to their function that is the transport of oxygen and carbon dioxide:

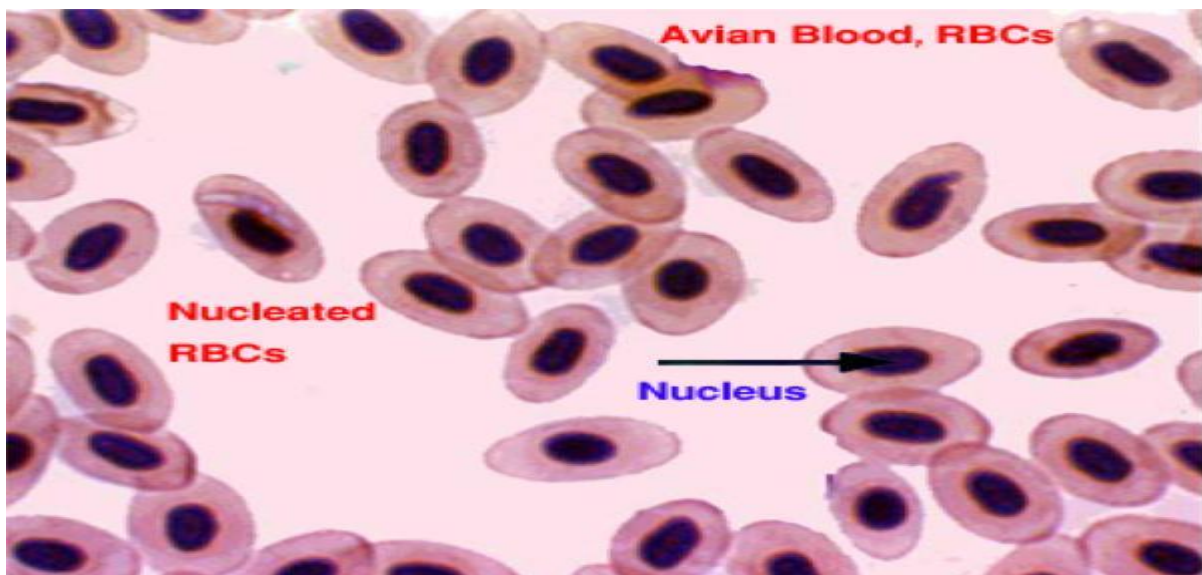
The plasma membrane is highly selective. It is permeable to water and electrolytes, but it is impermeable to hemoglobin.

The elasticity of the plasma membrane allows the erythrocytes to deform and pass through the smallest capillaries (2-4  $\mu\text{m}$  in diameter).

The biconcave shape provides a large surface area relative to cell volume, which greatly enhance gaseous exchange.

Before release into the circulation, the nucleus is extruded and by maturity, all cytoplasmic organelles degenerate which give more space to carry more hemoglobin.





## **Reticulocytes**

They are immature RBCs that are released into the peripheral circulation from the bone marrow. They are slightly large than mature RBCs and when stained with supravital dyes such as brilliant cresyl blue, blue-stained fine networks are seen inside their cytoplasm. This is due to ribosomal RNA still remaining in their cytoplasm. The number of reticulocytes increases in circulation after blood loss.

### **3- White blood cells (leukocytes)**

There are five cell types of the WBCs that are subdivided into two main groups:

#### *Granulocytes*

##### **Neutrophils**

They are the most common type of leukocytes and account for about 28 % (cattle) and 70 % (dog) of the total leukocytic count. The mature cell is about 10-12  $\mu\text{m}$  in diameter.

In mature cell, the nucleus is lobulated or segmented consists of 2-5 lobes connected by fine chromatin strands. Young neutrophil has U-V- or S-shaped, non-segmented nucleus

and is called band or non-segmented cells. Band cells increase in number during bacterial infection.

In female neutrophils, the quiescent X-chromosome or Barr bodies appear as a small drumstick-shaped appendage of one of the nuclear lobes. The cytoplasm contains purplish granules called azurophilic granules that are large lysosomes. Numerous smaller specific granules, are also present but they are poorly stained.

With EM, neutrophil has few cytoplasmic organelles. The specific granules are relatively smaller rod-like containing bactericidal substances (phagocytins) and alkaline phosphatase. The non-specifics (azurophilic granules) are larger in size and fewer in number. They are considered lysosomes containing hydrolytic and peroxidase enzymes. Besides, glycogen granules are found. Actively migrating cells protrude pseudopodia, which are cytoplasmic extensions of the cell contain a few glycogen granules but are largely devoid of organelles.

## Functions

Phagocytosis of invading microorganisms particularly bacteria.

They are the main WBCs type involved in acute inflammatory response. Dead leukocytes are called pus cells.

## Eosinophils

They account for 1-6 % of the total leucocytic counts. The cell size range from 12-15  $\mu\text{m}$ . Eosinophil has a bilobed, less deeply stained nucleus. The cytoplasm is packed with coarse, large, refractile, eosinophilic granules.

With EM, the cytoplasm is filled with large, ovoid, specific granules containing dense crystalloid in the long axis of the granules (dog, cat and goat). They are membrane-bound

and their matrix contains a variety of hydrolytic enzymes including histaminase. Other cytoplasmic organelles such as mitochondria, rER and Golgi are relatively sparse.

### Functions

The number of eosinophils in circulating blood increases during parasitic infestations and allergic conditions.

Phagocytosis of the antigen-antibody complex.

Deactivate histamine produced during inflammatory or allergic response.

### **Basophils**

They are about 10-12  $\mu\text{m}$  in diameter. They are the least common cell types that constitute less than 1% of the total leucocytic count. The nucleus is bilobed and completely obscured by numerous large deeply basophilic granules.

With EM, the bilobed nucleus is clearly visible and the cytoplasm is filled with membrane-bound electron dense granules.

### Functions

The specific granules of the basophils contain heparin, histamine, other inactive amines, and slow reacting substance of anaphylaxis (SRS-A).

The contents of the specific granules are released by exocytosis in response to interaction of antigen with antibodies attached to the basophil cell membrane.

Heparin is anticoagulant. Histamine causes dilatation of small blood vessels and increase capillary permeability leading to exudation of fluid. SRS-A Cause contraction to the smooth muscle cells.



## **Agranulocytes**

### **Lymphocytes**

They are the second most common leukocytes in circulating blood. They account for 20-45% of the total leukocytic counts. A round, densely stained nucleus and a relatively small amount of pale basophilic non-granular cytoplasm characterize them. According to their size, there are three types: small (6-8  $\mu\text{m}$ ), medium (8-10  $\mu\text{m}$ ) and large (10-14  $\mu\text{m}$ ).

With EM, the nucleus is small spherical and often slightly indented. The little cytoplasm contains a few mitochondria, a rudimentary Golgi apparatus, little or no rER and large number of free ribosomes accounting for the LM basophilia. Azurophilic granules (lysosomes) are also present.

On the basis of their functional properties, small lymphocytes are classified into two main groups: T and B-lymphocytes. Their functions will be considered with the immune system.

### **Monocytes**

They are the largest members of the white blood cell series that account for 2-10% of the total leucocytic count. They are highly motile cells and migrate into connective tissue where they are called histiocytes or tissue fixed macrophages. The large eccentricity located nucleus is bean or kidney-shaped with less densely stained chromatin than that of other leukocytes.

With LM, The cytoplasm is extensive and is filled with azurophilic granules (lysosomes). It has a frosted-glass appearance.

With EM, lysosomes are abundant, the Golgi is well developed, rER is diffuse and mitochondria are abundant than other leukocytes. It is also rich in microtubules and

microfilaments. Pseudopodia are prominent reflecting their capacity for amoeboid movement and phagocytosis.

## Function

The principal function of the macrophage is phagocytosis and destruction of the cellular debris.

Antigen presentation and antigen processing thus participating in both humoral and cell-mediated immune response.

## **4- Blood platelets (thrombocytes)**

They are small, non-nucleated cells formed in the bone marrow by budding from the cytoplasm of huge cells called megakaryocytes. In birds, platelets are nucleated hence they are called thrombocytes.

With LM, they are round or oval biconvex discs about 2-3  $\mu\text{m}$  in diameter.

The cytoplasm has a purple-stained granular appearance due to its high contents of organelles. The organelles are concentrated towards the center of the cell (granulomere). The peripheral cytoplasm (hyalomere) contains microfilaments and microtubules arranged underneath the plasmalemma. It has few organelles and is very poorly stain.

With EM, the cytoplasm is rich in membrane bound granules of two types: 1) very dense granules are sparse and contain serotonin, ADP, ATP and calcium. 2) Alpha granules which are more common and contain hydrolytic enzymes.

## Functions

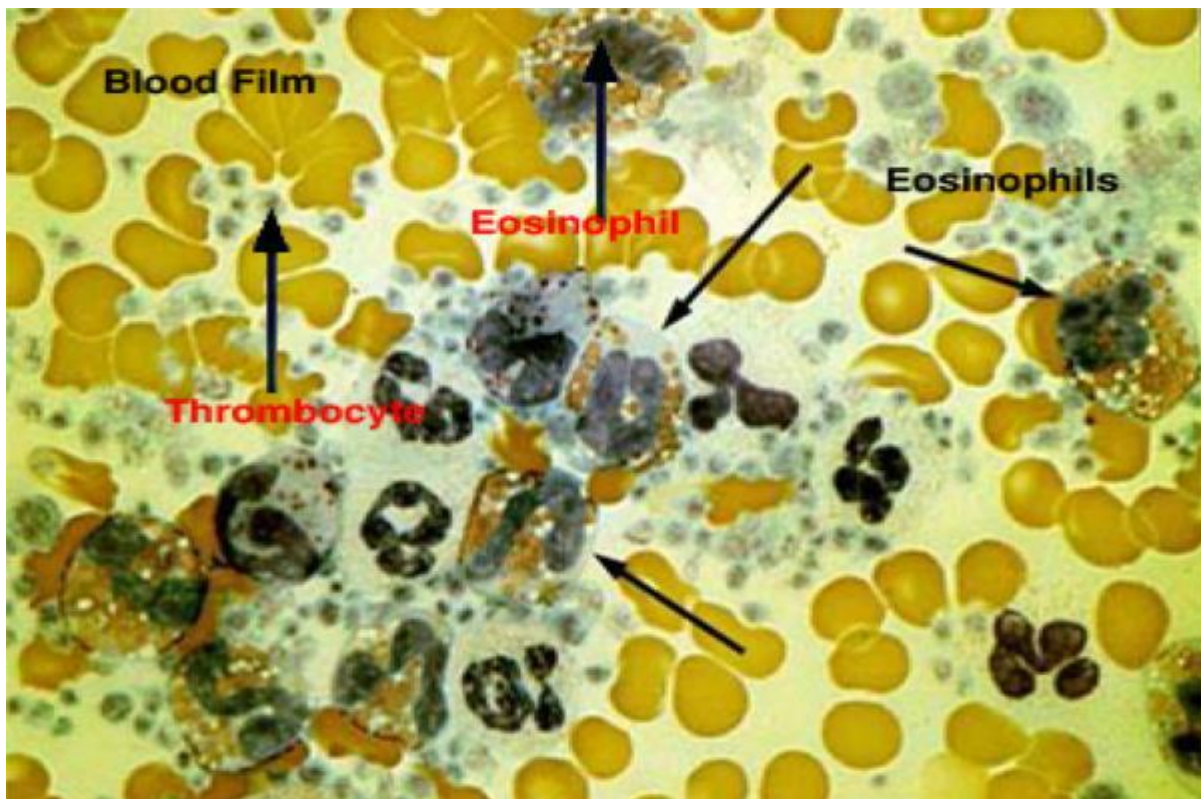
Blood clot formation.

Release serotonin that reduces the blood flow by constricting the damaged vessels.

## Function

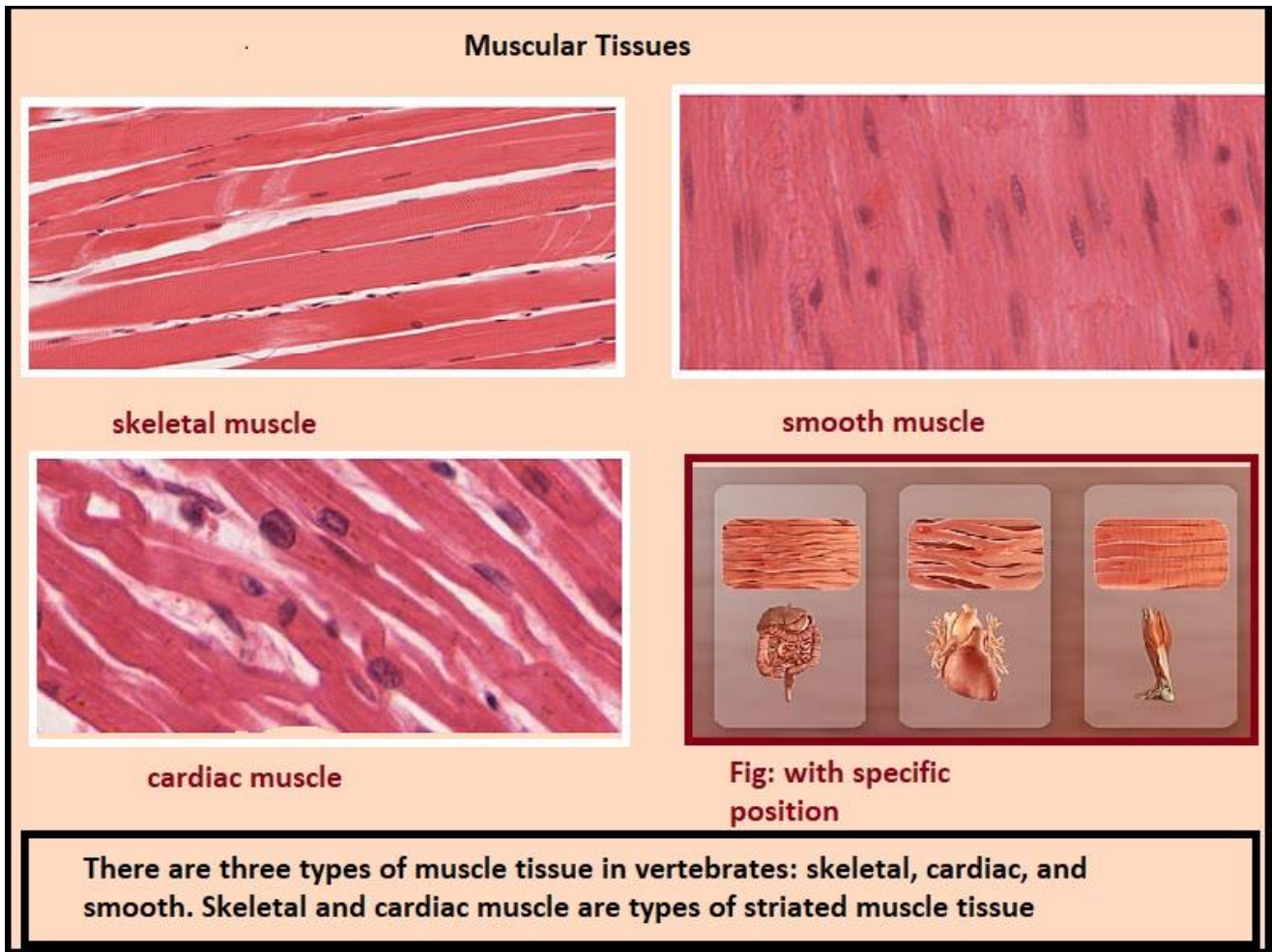
The principal function of the macrophage is phagocytosis and destruction of the cellular debris.

Antigen presentation and antigen processing thus participating in both humoral and cell-mediated immune response.



### 3. Muscular tissue

It is one of the four basic types of tissues primarily responsible for locomotion and movement of the various body parts.



#### General features

Muscle cells are long and narrow; therefore they are called muscle fibers or myofibers.

Muscle fibers are highly specialized for contractility, which occurs due to the presence of contractile proteins within their cytoplasm.

Muscle fibers originate primarily from the mesoderm, except the muscle of the iris, and myoepithelial cells that are ectoderm.

Special terms are used for muscle fibers: plasmalemma = sarcolemma; cytoplasm = sarcoplasm; endoplasmic reticulum = sarcoplasmic reticulum; mitochondria = sarcosomes.

Muscle tissue is a composite tissue where it contains a minimal amount of connective tissue beside its principal cells.

There are three types of muscle tissue: skeletal, cardiac and smooth muscles.

### **Skeletal muscle (Striated and voluntary myofibers)**

They are found in all skeletal muscles, tongue larynx, pharynx and eye. It is called skeletal because its contraction moves some parts of the skeleton; voluntary because its contraction is under conscious control, and striated because under microscope, its fiber shows alternating dark and light bands called cross-striation.

A skeletal muscle is composed of skeletal myofibers and connective tissue. A sheath of dense connective tissue called epimysium encloses the entire muscle. From the epimysium, thin collagenous septa extend inward to divide the muscle into a number of bundles or fascicles. These septa are called the perimysium. The perimysium is continuous with the endomysium that is a delicate connective tissue layer surrounds each individual myofibers.

At least five cell types are found within the bundle of the skeletal muscle: myofibers, endothelial cells, fibroblasts and myosatellite cells.

The connective tissue in between the myofibers is needed for two reasons: 1) through which blood vessels, lymphatics and nerve enter or leave the interior of the muscle. 2) At the ends of the muscle, the connective tissue elements merge to form tendons that anchor the muscle to other structures such as bone or cartilage.

## **Cardiac muscle (Striated and involuntary)**

It is called cardiac because it constitutes most of the heart although some cardiac muscle can also be found in the wall of pulmonary vein and vena cava.

Cardiac myofibers are striated, however, the striation is less distinct than that of the skeletal myofibers due to: irregular branching shape of the fiber, the less myofibrils content and the abundance of non-contractile sarcoplasm. They are involuntary, they contract spontaneously without any nerve supply. The rate this inherent rhythm can be modulated by autonomic and hormonal stimuli.

### Structure of cardiac muscle

At the LM level, the cardiac myofibers are long (50-100 mm), cylindrical cells that are branched and anastomosed forming a network. They are traversed at intervals by dark-staining structures called intercalated discs that extend across the fiber in a stepwise manner.

Most of the cells have one nucleus and at most two nuclei. The nuclei are oval and centrally located within the cell. Like the skeletal muscles, the cytoplasm is acidophilic and striated consisting of an alternated dark and light bands.

The cells are surrounded by delicate connective tissue containing fibroblasts, pericytes and dense capillary network necessary to meet their high metabolic demands. Myosatellite cells are absent.

In TS, the cardiac muscle fibers are spherical or oval with aregular diameter of about 20 mm containing single central nuclei.

At the EM level, the fine structure of the cardiac muscle is similar to that of the skeletal muscle except:

Cardiac myocytes has a less extensive sarcoplasmic reticulum and does not form dilated terminal cisternae.

### ***Purkinje fibers***

They are modified cardiac muscle fibers designed for rapid conduction of nerve impulses. They differ from the ordinary cardiac muscle fibers in the following aspects:

They are larger in size.

The nucleus is smaller and eccentricity situated.

The cytoplasm is paler, vacuolated because it is rich in glycogen.

The myofibrils are fewer and concentrated at the periphery.

The T tubules are absent.

### **Smooth muscle (Visceral muscle)**

Smooth muscles are found in the walls of hollow viscera and blood vessels. It is called smooth because it has no cross striations, involuntary because its contraction can not be elicited at will and visceral because they are found in visceral organs.

#### Structure of smooth myofibers

At the LM level, the smooth muscle cell is elongated, spindle-shaped with pointed ends. It has a diameter of 3-10 mm with length ranges between 30-500 mm.

The cytoplasm is acidophilic and contains only one nucleus. The nucleus is elongated and centrally located in the cytoplasm at the widest part of the cell. During contraction, the nuclei may appear spiral in shape .

The smooth muscle fibers are bound together into irregular branching bundles. Within the bundles, individual muscle fibers are arranged parallel to each other with

the thick part of the cell lying against the thin parts of adjacent cells. A sheath of delicate connective tissue containing capillaries and few nerve fibers invests each muscle bundle.

The cytoplasm is filled with parallel thin (actin) and thick (myosin) filaments. The filaments do not have the arrangement seen in the sarcomeres.

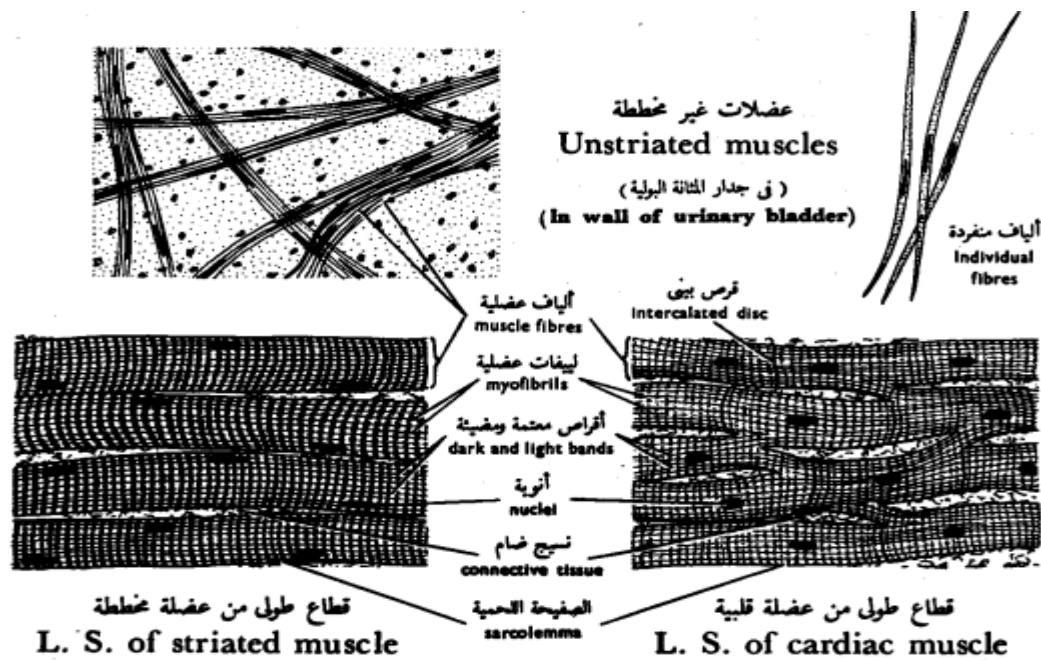
Intermediate filaments (desmin, vimentin and synemin) are also located within the cytoplasm.

## Functions

Contraction of the smooth muscle is an inherent property however, it can be modulated by the autonomic nervous system.

The smooth muscle maintains prolonged partial contraction (tonus) in the wall of arterioles that is necessary to keep normal blood pressure in the blood capillaries.

In the small intestine, the smooth muscle cell undergoes continuous rhythmic constrictions passing along the tract propelling the luminal contents distally.



شكل ٤٢ - الأنسجة العضلية  
**FIG. 42 - MUSCULAR TISSUES**

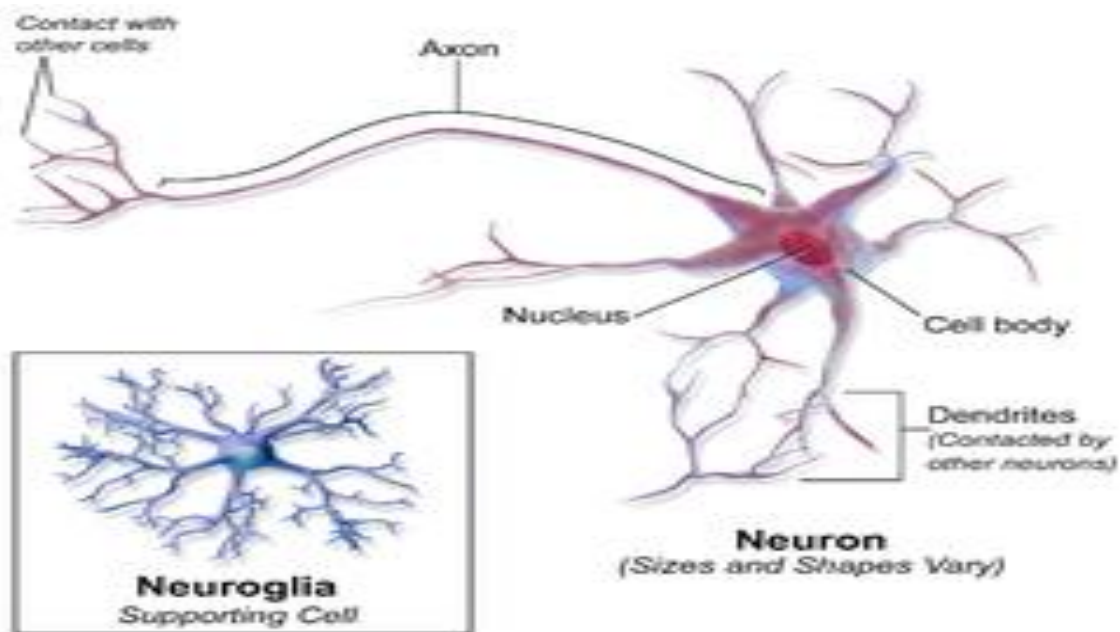


## 4. Nervous tissue

It is one of the four primary basic tissues.

It consists of two types of cells:

- 1- Neurons (nerve cells)
- 2- Neuroglia (supporting cells).



### Neural Tissue

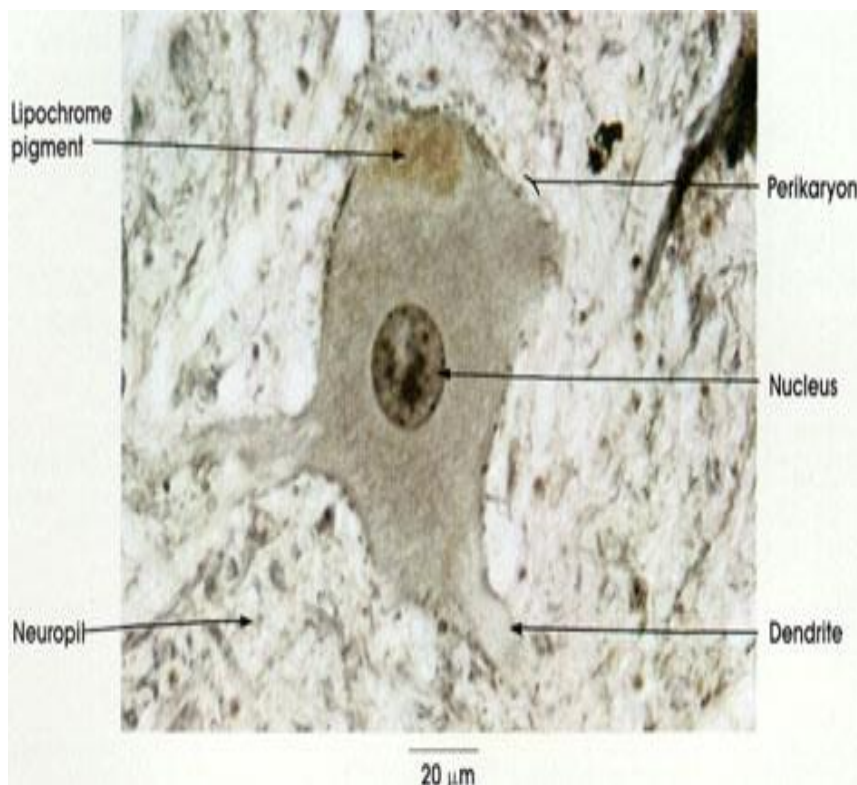
Neuron=Nerve cell

- It is *the structural and functional unit* of the nervous tissue.
- It is characterized by:
  - 1- Excitability: they respond to environmental changes by generation of action potential or nerve impulse.
  - 1- Conductivity: they are capable of propagation of nerve impulse to other neurons, muscles& glands.

## Histological structure of the neuron

### I- Cell body (perikaryon, soma)

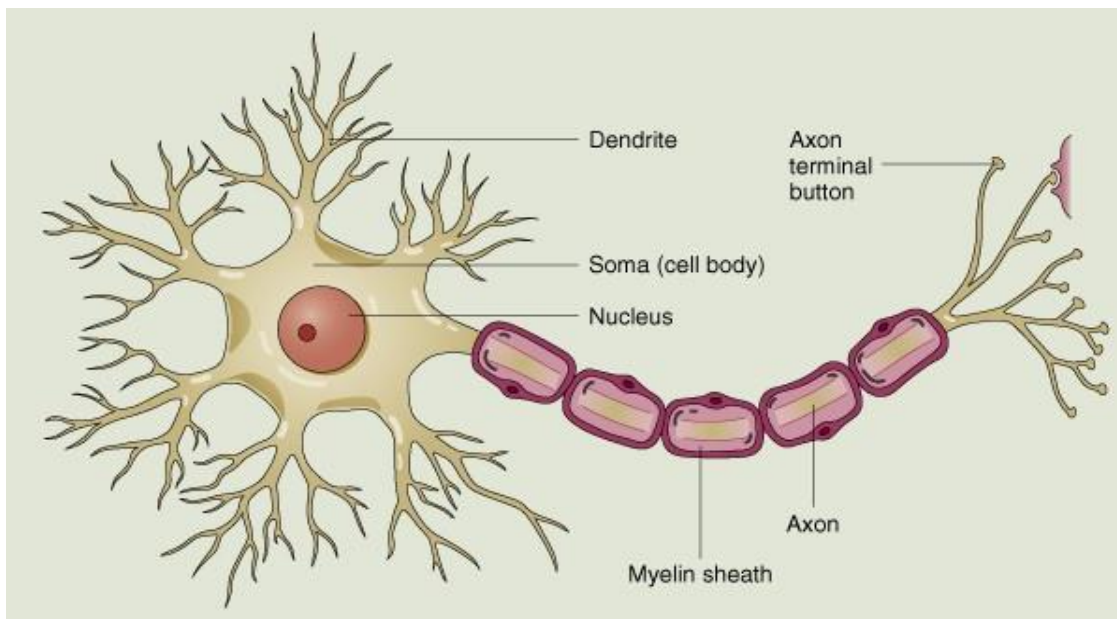
- It is composed of:
  - 1- Nucleus: euchromatic.
  - 2- Cytoplasm: contains:
    - Nissl bodies
      - LM: basophilic granules.
      - EM: aggregates of ribosomes and rER.
      - Function: protein synthesis.
      - Distribution: in the cell body *except* in the region of axon hillock.
    - Large perinuclear Golgi apparatus: for packaging of neurotransmitters into synaptic vesicles.
    - Cytoskeleton: formed of neurofibrils that include neurofilaments and microtubules playing a role in the transmission of nerve impulses.
    - Inclusions: lipofuscin pigments and lipids.



## II- Cell processes

### 1- Axon:

- Origin: from the axon hillock.
- Number: always single.
- Direction of impulses: conducts nerve impulses away from the cell body.
- Shape: long, with a regular cylindrical shape.
- Branching: no branches except at axon termination forming terminal arborizations. It may give off collaterals arising at right angles.
- Structure: the axoplasm contains few organelles (neurofibrils, synaptic vesicles and mitochondria). Nissl bodies are *absent*.
- Surrounding sheath: axolemma may be surrounded by sheaths according to the type of nerve fiber.

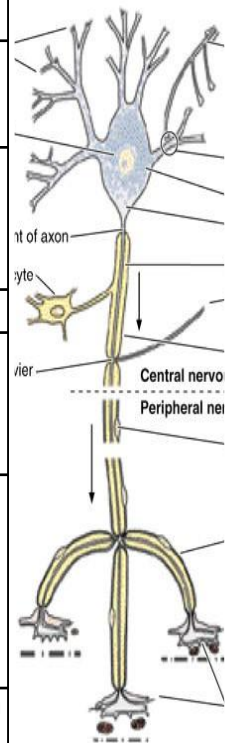


### 2- Dendrite:

- Origin: from any part of the cell body.
- Number: usually multiple (in multipolar neurons). It may be single (in bipolar neurons).
- Direction of impulses: conducts nerve impulses towards the cell body

- Shape: short, thick near its origin and tapers towards its end.
- Branching: many branches arising at acute angles, having short spines for synapses.
- Structure: contains most of the organelles as in the perikaryon *except* the Golgi apparatus. Nissl bodies are present.
- Surrounding sheath: not surrounded by sheaths.

	The axon	The dendrite
<b>1- Origin</b>	Arises from axon hillock	Arises from any part of the cell
<b>2- Direction of the impulse.</b>	conducts nerve impulse away from the cell body	conducts nerve impulse toward the cell body
<b>3- Number</b>	Always single	Usually multiple (in multipolar neurons). It may be single (in bipolar neurons)
<b>4- Length</b>	Long	Short
<b>5- Thickness</b>	Thin with a constant diameter.	Thick near its origin and tapers as it goes toward its end.
<b>6- Branching</b>	Does not branch except at its termination (terminal arborization). It may give off collaterals arising at right angles.	Many branches arising at acute angles, having short spines.
<b>7- Organelles present</b>	Contains few organelles (neurofibrils vesicles and mitochondria. <b>Nissl granules are absent.</b>	Contains most of the organelles as in the perikaryon except Golgi. <b>Nissl granules are present</b>
<b>8- Surrounding structures</b>	It may be surrounded by sheaths.	It is not surrounded by sheaths

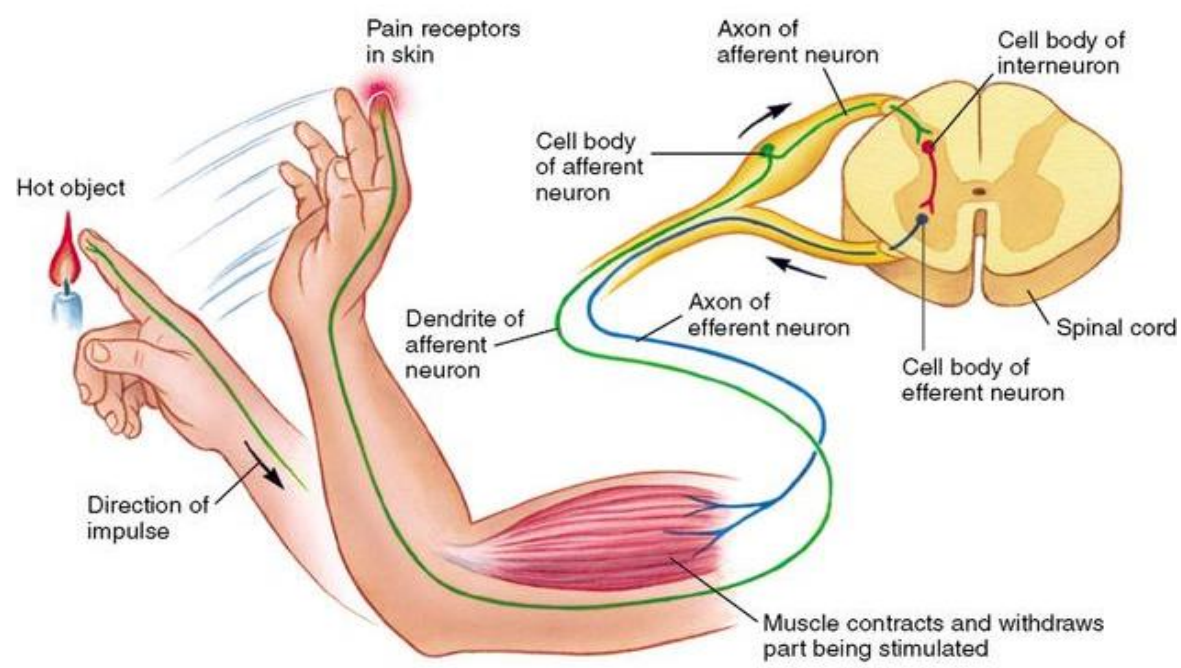
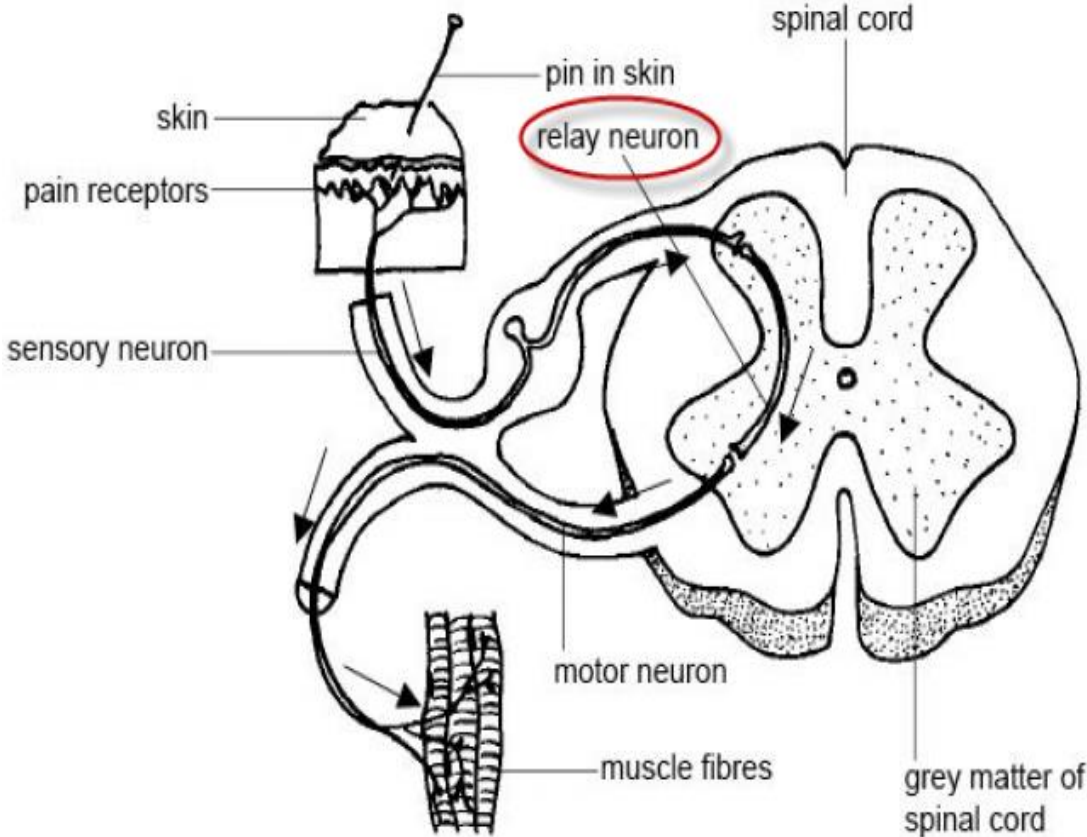


## Classification of the neurons

### I- Functionally

- 1- Sensory neurons: they carry impulses from receptors to the CNS.
- 2- Motor neurons: they carry impulses from CNS to the effector organs.

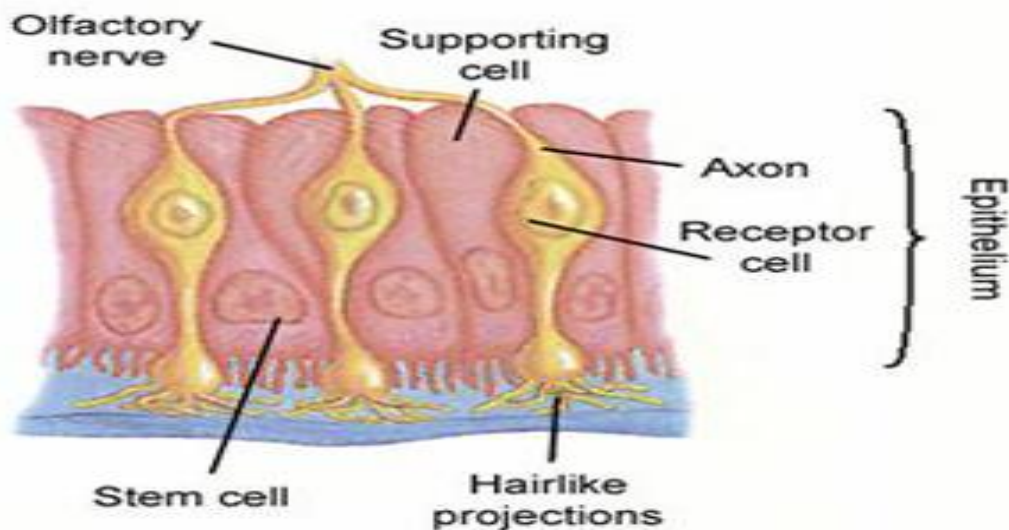
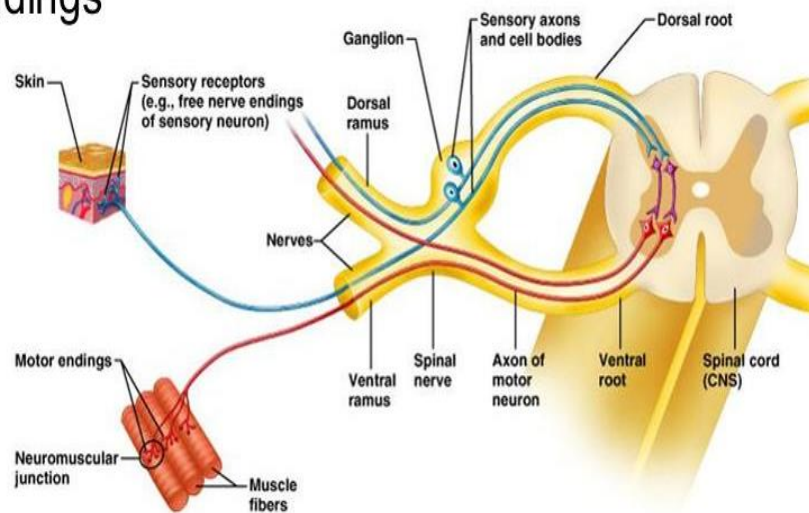
3- Interneurons (association neurons): act as a link between sensory and motor neurons in CNS only.



## II-Morphologically

- Neurons are classified according to the number of their processes into:
  - 1- Unipolar: have only one cell process.
    - Site: present in the embryonic stage.
  - 2- Pseudounipolar: have a single process that divides like the letter T into two branches (both are axons).
    - Site: in the cranio spinal ganglia.
  - 3- Bipolar: have two processes, one is an axon and the other is a dendrite.
    - Site: the olfactory neurons present in the olfactory mucosa of the nose.

- sensory receptors
- motor endings
- nerves
- ganglia



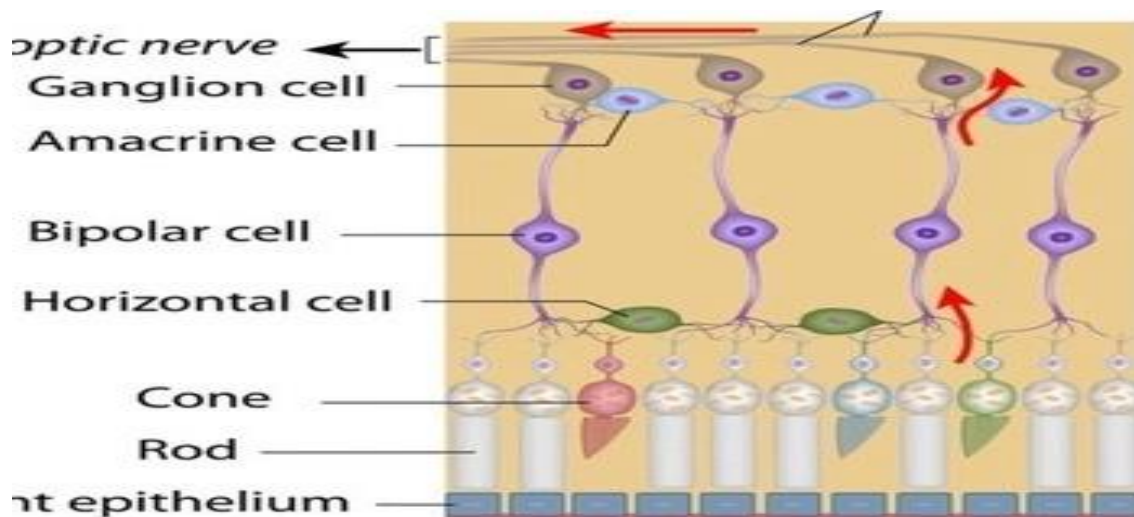
4- Multipolar: have more than two processes. These are classified according to the shape of their perikaryon into:

A-Stellate neurons: they are the anterior horn cells of the spinal cord and the autonomic ganglion cells.

B- Pyramidal neurons: in the cerebral cortex.

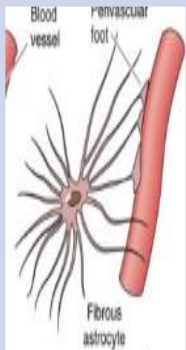
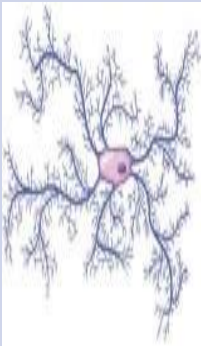
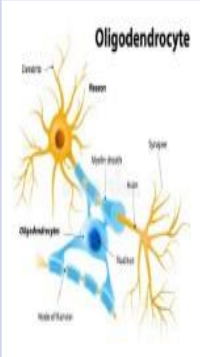
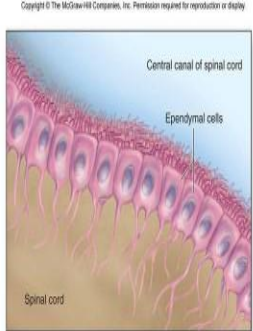
C- Pyriform neurons: in the cerebellar cortex (Purkinje cells)& the retina (ganglion cells).

D- Granule cells: in the cerebellar cortex.

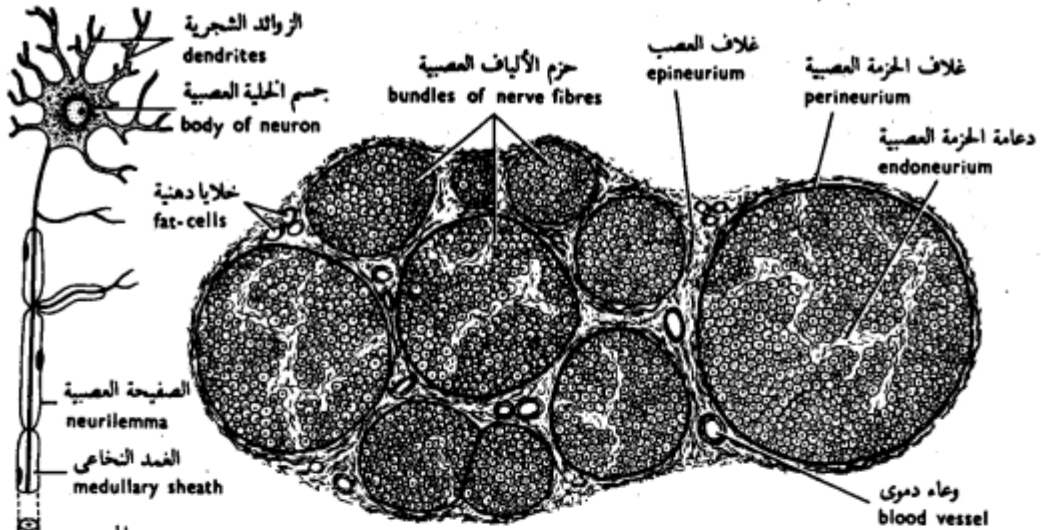


Nerve fiber

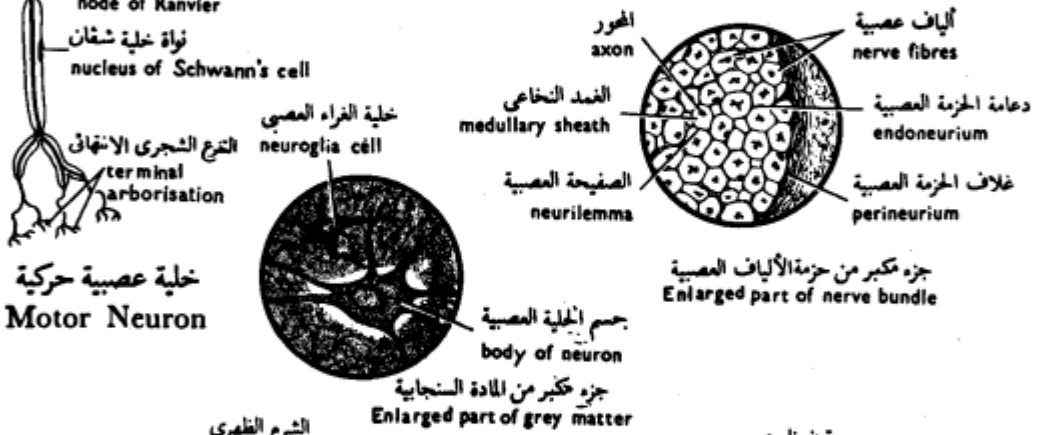
- Definition: It is an axon enveloped by a special sheath.
- It differs in the enveloping sheaths according to whether the fibers are part of the central or peripheral nervous system.

	Astrocyte =Macroglia	Microglia	Oligodendrocyte	Ependymal cell
<b>LM:</b> <b>Shape</b>	<ul style="list-style-type: none"> <li>•Large stellate</li> <li>•Multiple processes,end by foot like expansion on the blood vessels.</li> </ul>	<ul style="list-style-type: none"> <li>•Small, oval.</li> <li>•Processes arising from the two poles. The cell body and the processes have minute spines.</li> </ul>	<ul style="list-style-type: none"> <li>•Small cells.</li> <li>•Few short processes.</li> <li>• They are aligned in rows between the axons in the white matter.</li> </ul>	<ul style="list-style-type: none"> <li>•Epithelial-like cuboidal cells, lining the brain ventricles and the central canal of the spinal cord.</li> <li>•Apically have microvilli and few cilia, while basally have numerous infoldings without a basement membrane.</li> </ul>
<b>Function</b>	<ul style="list-style-type: none"> <li>•Supportive</li> <li>•nutritive</li> <li>•Metabolic</li> <li>•Formation of blood brain barrier.</li> </ul>	Phagocytosis of bacteria,apoptotic and malignant cells.	Formation the myelin sheath in the white matter of CNS	Formation of cerebro-spinal fluid.
	 <p>Blood vessel perivascular foot Fibrous astrocyte</p>		 <p>Oligodendrocyte</p> <p>Labels: Dendrite, Process, Myelin sheath, Soma, Node, Oligodendrocyte, Node of Ranvier, Axon</p>	 <p>Copyright © The McGraw-Hill Companies, Inc. Permission required for reproduction or display.</p> <p>Central canal of spinal cord Ependymal cells Spinal cord</p> <p>(b) Ependymal cells</p>

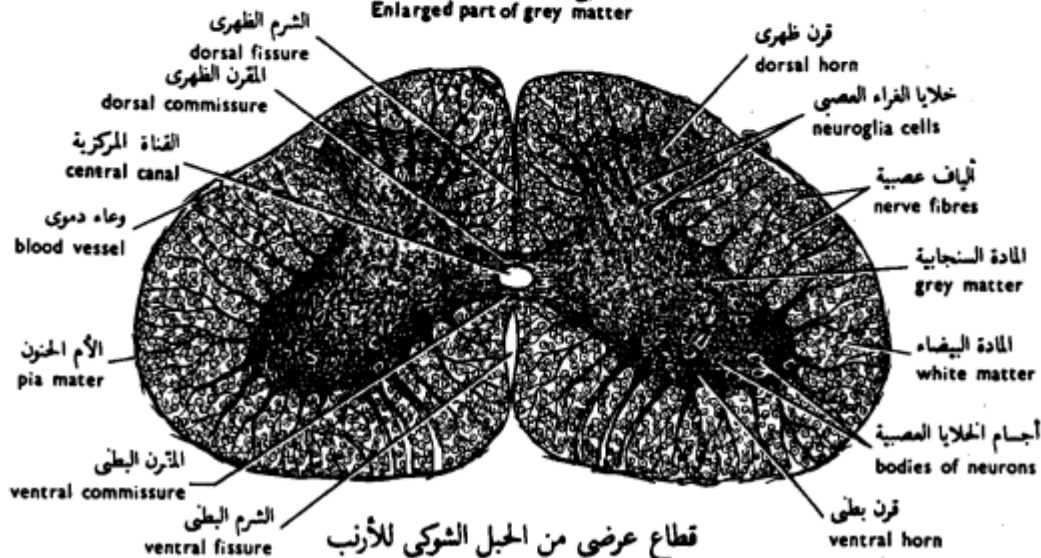




قطاع عرضي من العصب الوركي للقط  
T.S. of the Sciatic Nerve of the Cat



خلية عصبية حركية  
Motor Neuron



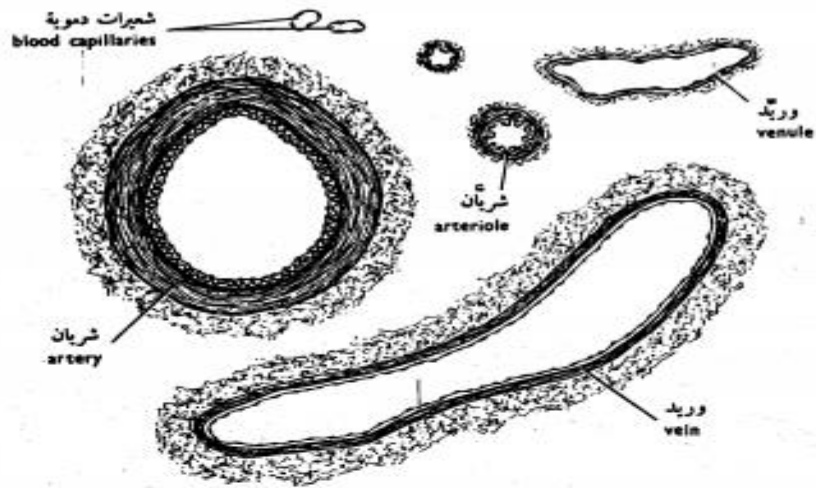
قطاع عرضي من الحبل الشوكي للارنب  
T.S. of the Spinal Cord of the Rabbit

شكل ٤٣ - الأنسجة العصبية

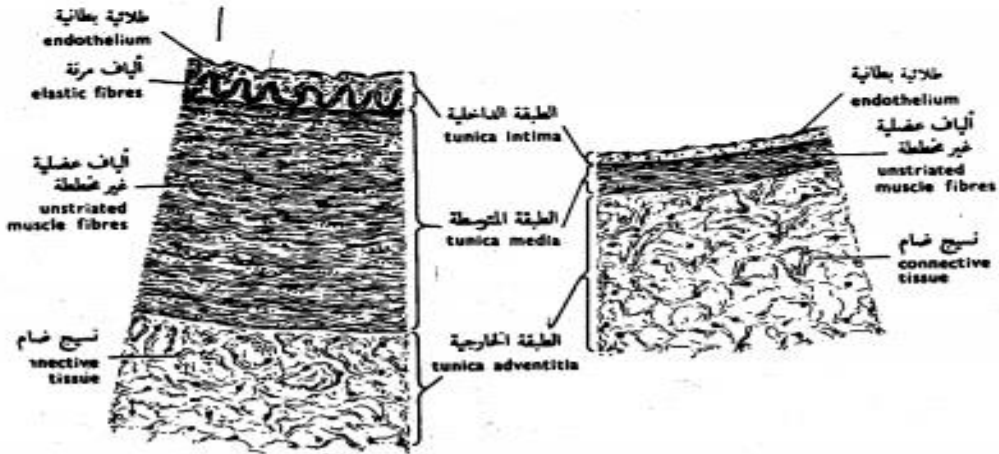
FIG. 43 - NERVOUS TISSUES

# The Organs

## Blood vessels



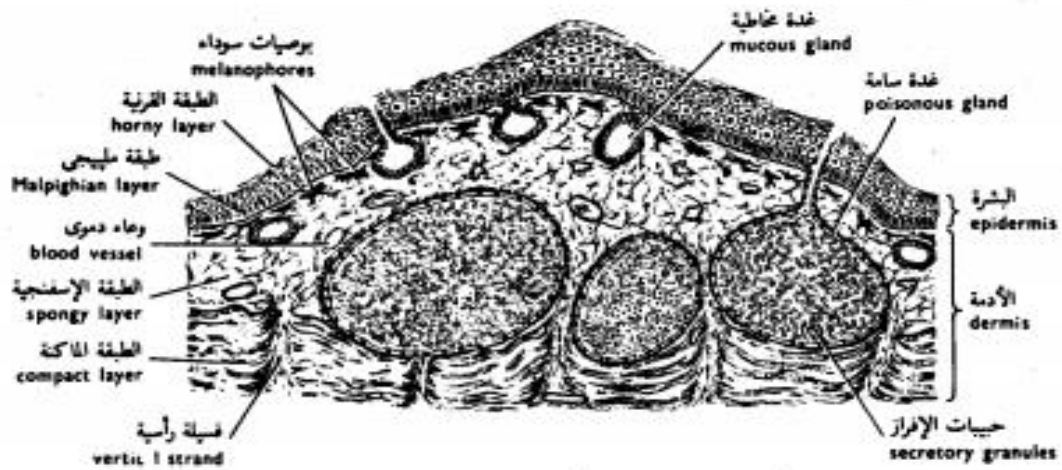
قطاعات عرضية من أوعية دموية مختلفة  
T.S. of different Blood Vessels



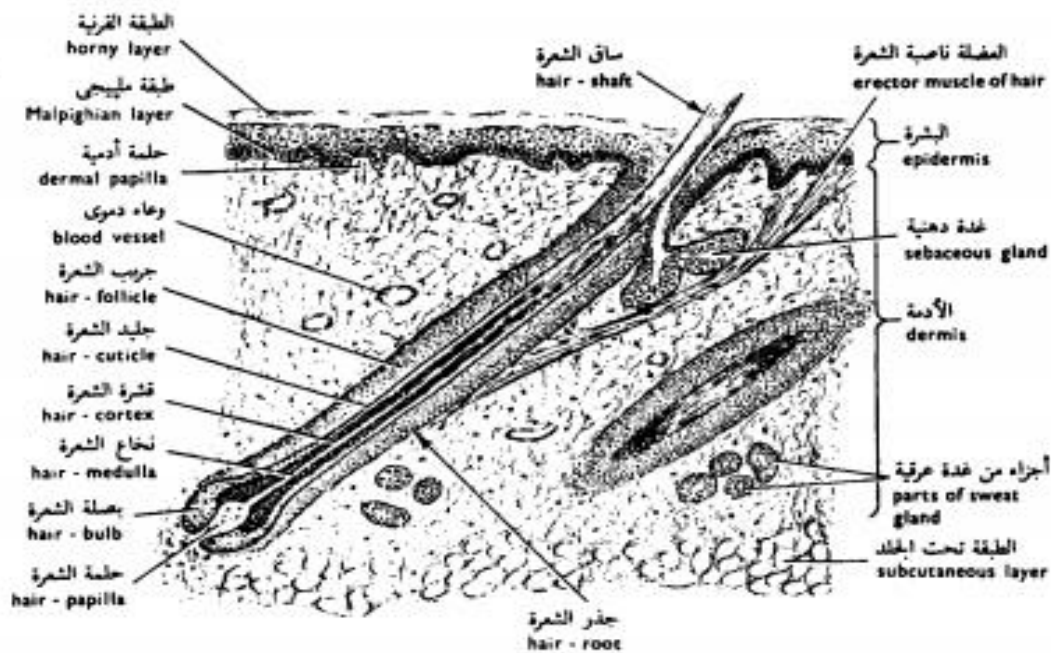
جزء من قطاع عرضي من جدار شريان  
Sector of the wall of an Artery

جزء من قطاع عرضي من جدار وريد  
Sector of the wall of a Vein

شكل ٤٤ - الأوعية الدموية  
FIG. 44 - BLOOD VESSELS

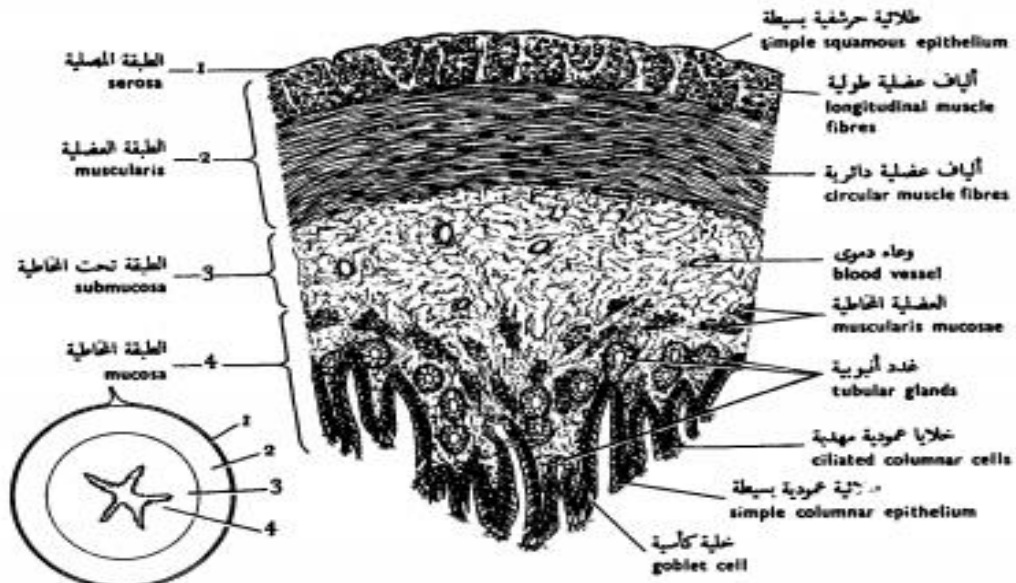


شكل ٤٥ - قطاع رأسي من جلد الضفدعة  
 FIG. 45 - V. S. OF THE SKIN OF THE TOAD

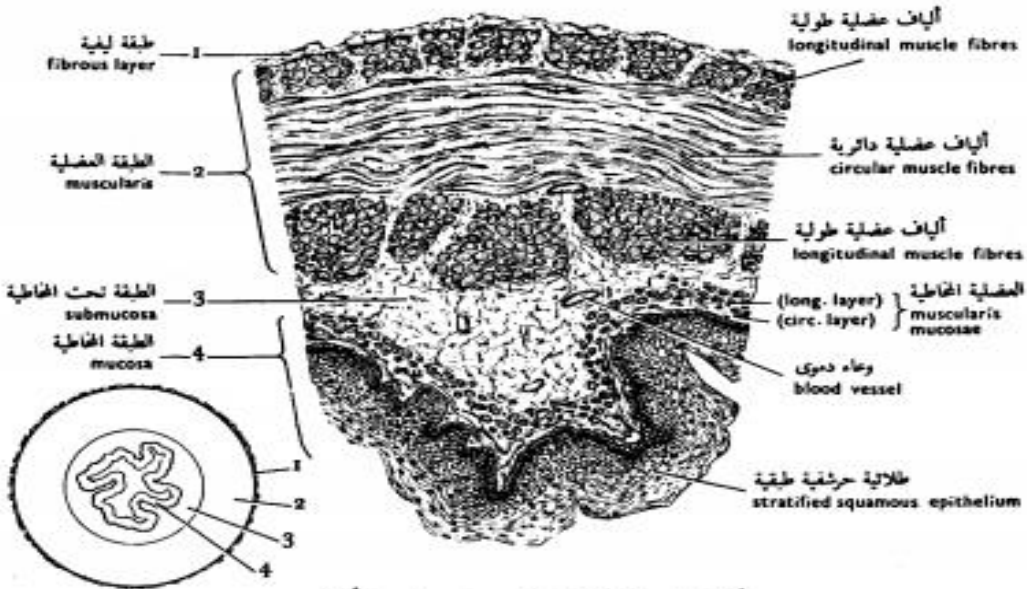


شكل ٤٦ - قطاع رأسي من جلد الخنزير  
 FIG. 46 - V. S. OF THE SKIN OF THE PIG

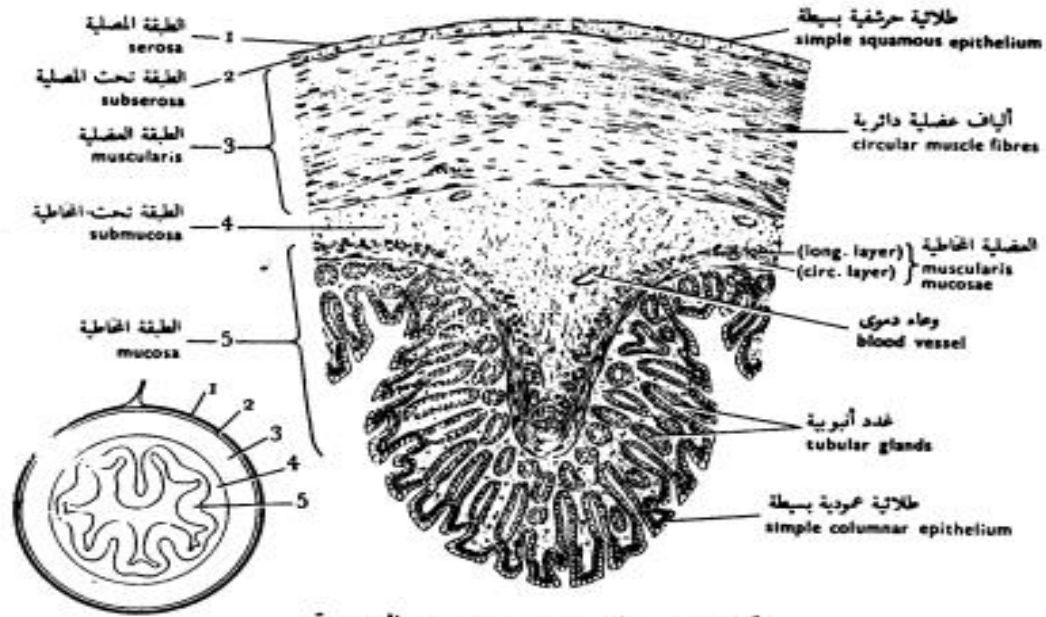
# Digestive tract



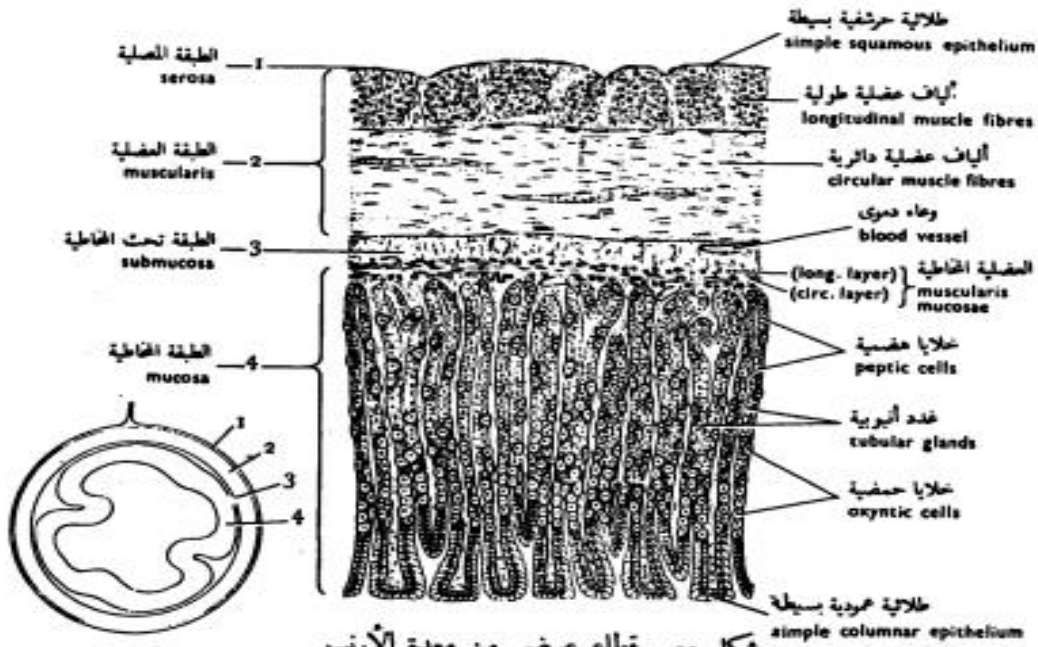
شكل ٥٢ - قطاع عرضي من مريء الضفدعة  
 FIG. 52 - T.S. OF THE OESOPHAGUS OF THE TOAD



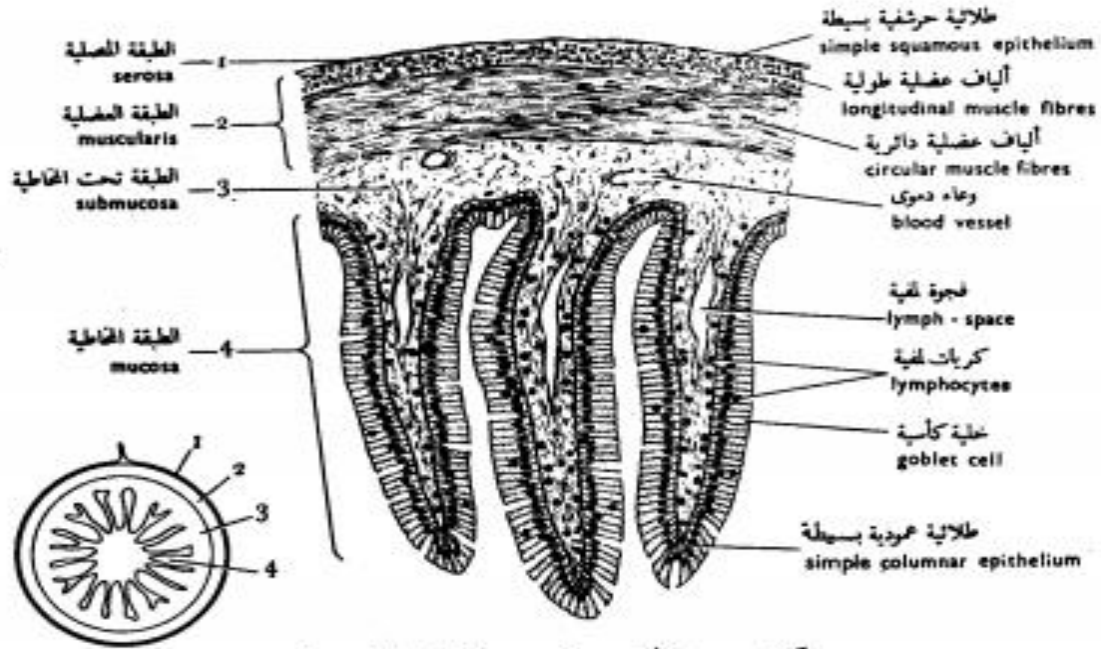
شكل ٥٣ - قطاع عرضي من مريء الأرنب  
 FIG. 53 - T.S. OF THE OESOPHAGUS OF THE RABBIT



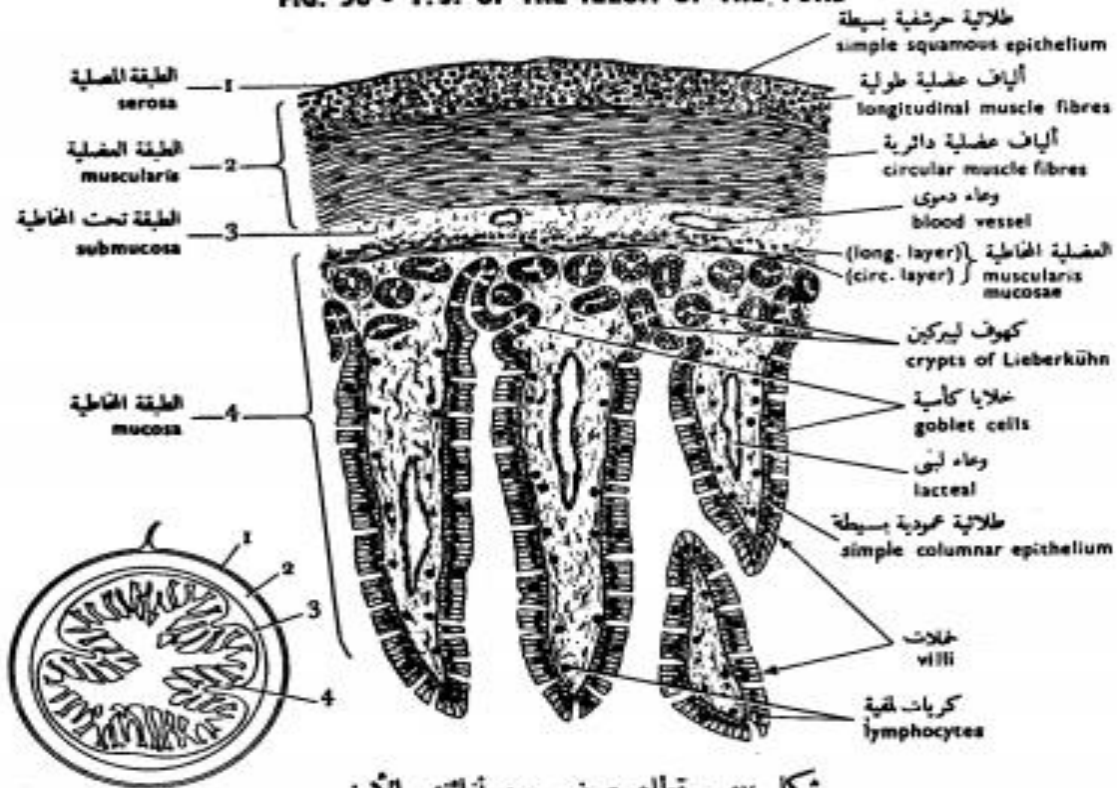
شكل ٥٤ - قطاع عرضي من معدة الضفدعة  
 FIG. 54 - T.S. OF THE STOMACH OF THE TOAD



شكل ٥٥ - قطاع عرضي من معدة الأرنب  
 FIG. 55 - T.S. OF THE STOMACH OF THE RABBIT

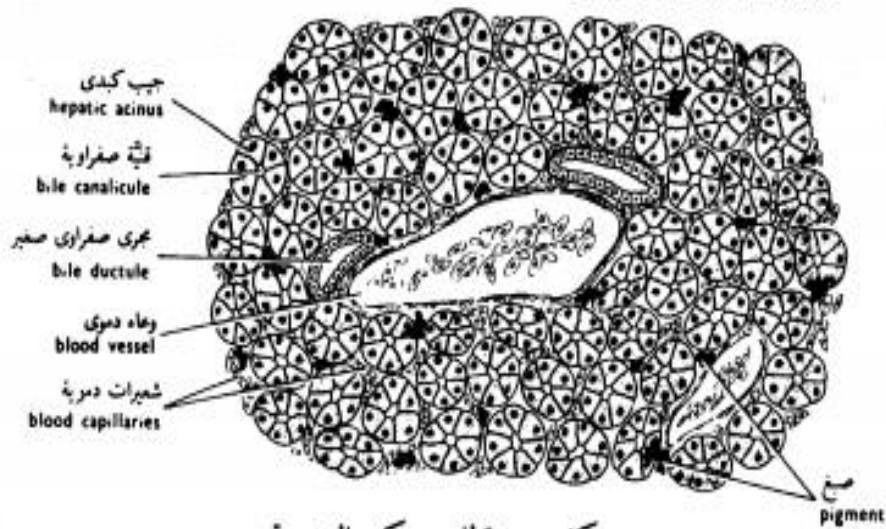


شكل ٥٦ - قطاع عرضي من لفائف الضفدعة  
 FIG. 56 - T.S. OF THE ILEUM OF THE TOAD

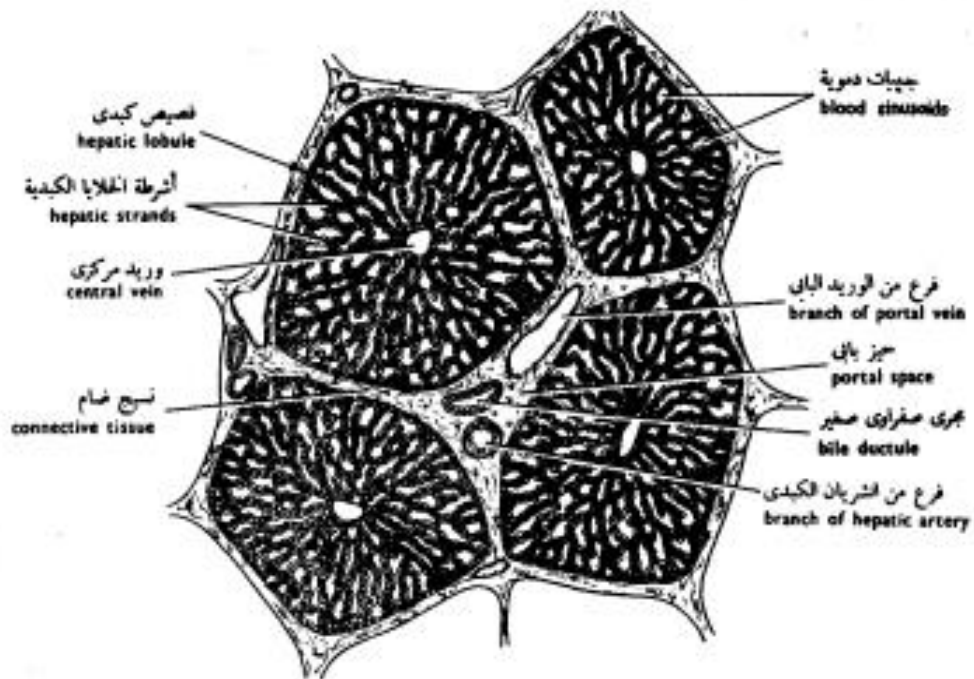


شكل ٥٧ - قطاع عرضي من لفائف الأرنب  
 FIG. 57 - T.S. OF THE ILEUM OF THE RABBIT

of the Toad's Liver



شكل ٥٩ - قطاع من كبد الضفدعة  
 FIG. 59 - S. OF THE LIVER OF OF THE TOAD

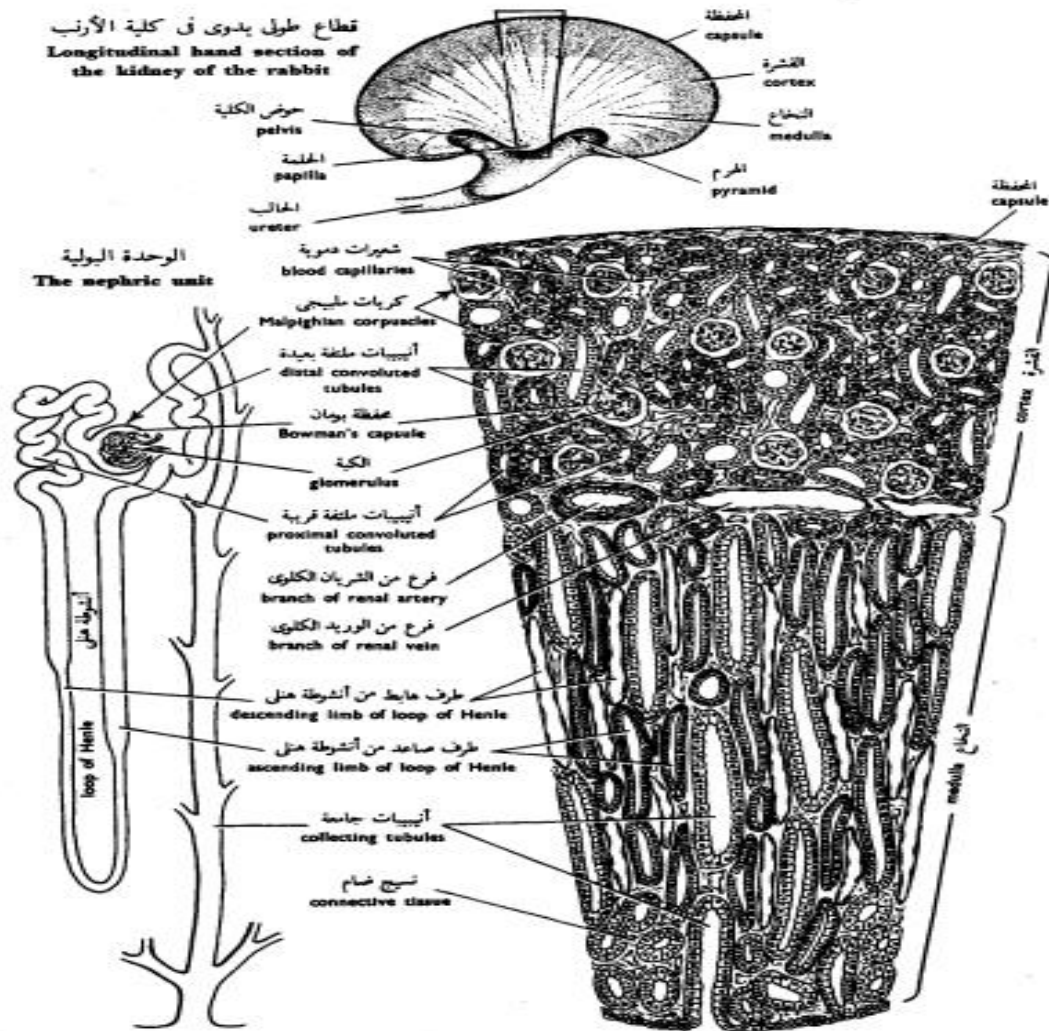


شكل ٦٠ - قطاع من كبد الخنزير  
 FIG. 60 - S. OF THE LIVER OF THE PIG

# Kidney

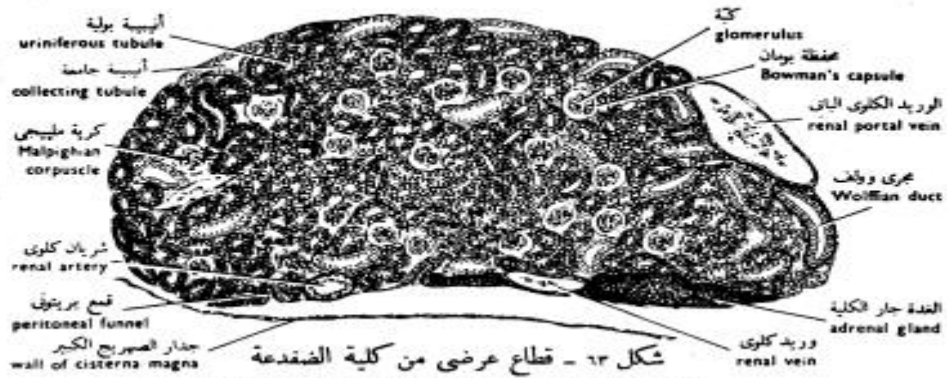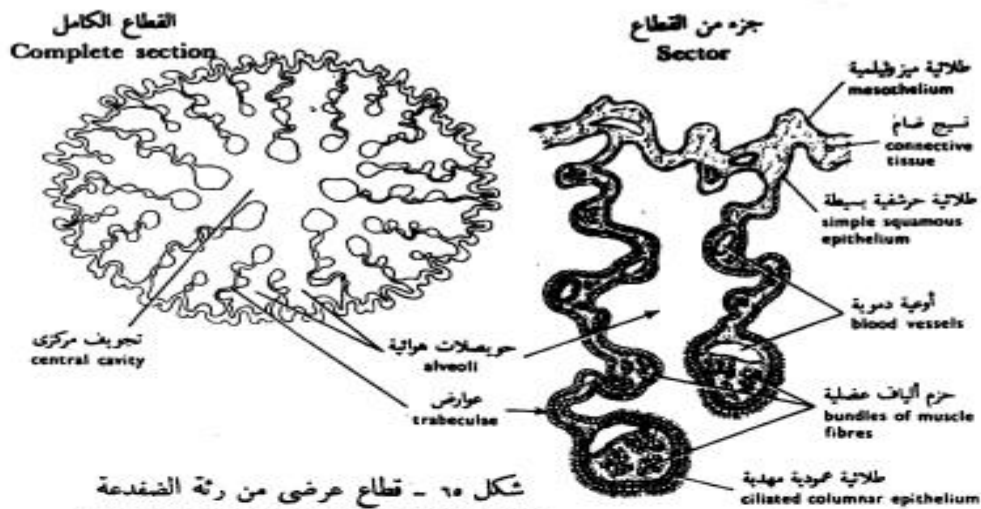


FIG. 63 - T.S. OF THE KIDNEY OF THE TOAD

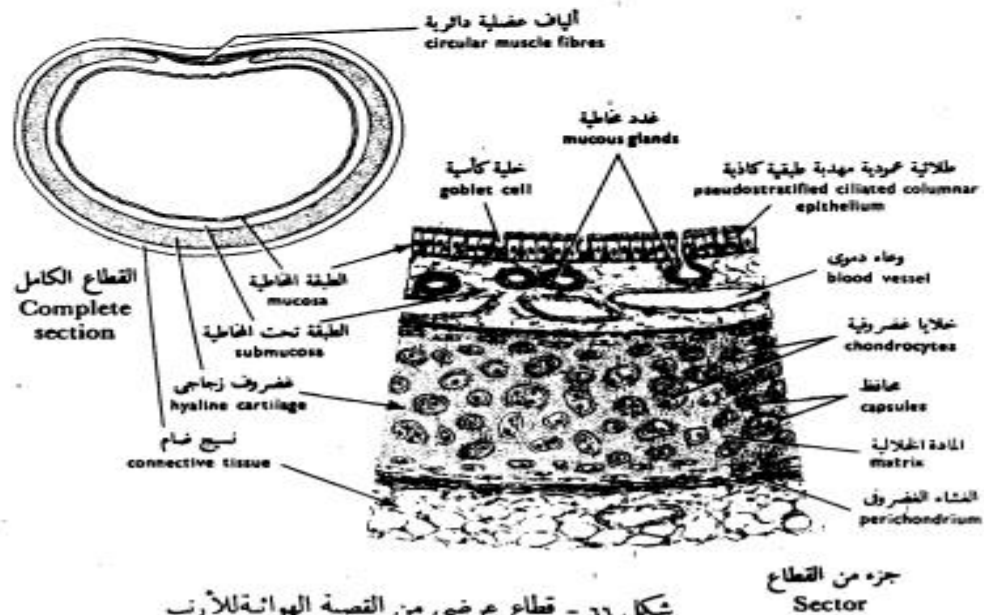


شكل ٦٤ - قطاع عرضي من كلية الأرنب



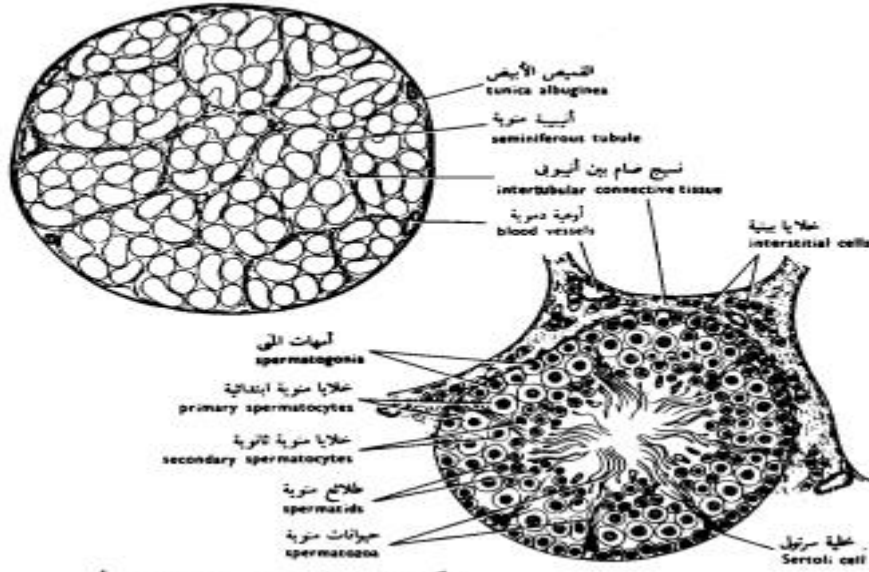


شكل ٦٥ - قطاع عرضي من رئة الضفدعة  
FIG. 65 - T.S. OF THE LUNG OF THE TOAD

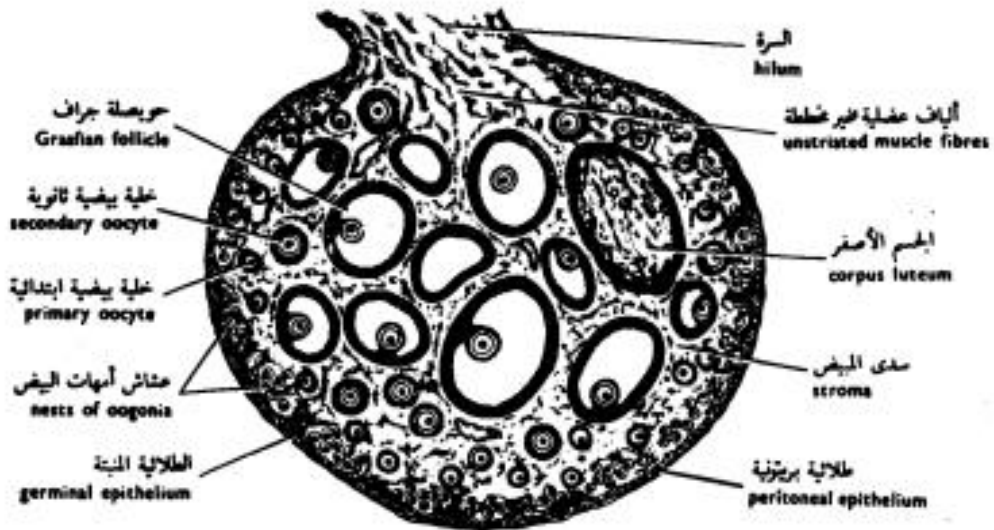


شكل ٦٦ - قطاع عرضي من القصبة الهوائية للآرنب  
FIG. 66 - T.S. OF THE TRACHEA OF THE RABBIT

# Testis and Ovary



شكل ٦٧ - قطاع عرضي من خصية الفأر  
 FIG. 67 - T.S. OF THE TESTIS OF THE RAT



شكل ٧١ - قطاع عرضي من مبيض القطاة  
 FIG. 71 - T.S. OF THE OVARY OF THE CAT

## References

- 1- <https://byjus.com/>
- 2- <https://www.biologyonline.com/>
- 3- <https://microbenotes.com/>
- 4- <https://www.khanacademy.org/>
- 5- Junqueira's Basic Histology (Atlas And Textbook)
- 6- Histology: A Text And Atlas (Ross)
- 7- Color Atlas And Text For Histology (Gartner's)
- 8- Wheater's Functional Histology
- 9- BRS Cell Biology And Histology (Review Book)
- 10- Lange Histology And Cell Biology

## Animal Classification

Despite the fact that a bewildering variety of species with different structures and forms exist out there, organisms share some common features among themselves. These similarities are the basis of classification. Classification is the systematic arrangement of things around us for easy identification and study. The basis of classification can vary according to the purpose of the classification. A biological classification generally pins out the morphological and evolutionary similarities as its basis. Let's go on the basis of classification of the animal kingdom in detail.

### Animal Kingdom: Basis of Classification

The animal kingdom is the largest kingdom amongst the five kingdoms consisting of all animals. Animals are multicellular eukaryotes; do not possess a cell wall or chlorophyll like plants, and share the same mode of nutrition, that is, the heterotrophic mode. Besides these similarities, they are also related to their cell arrangement, body symmetry, level of organization, coelom, presence/absence of notochord, etc. Based on these features, the animal kingdom has been classified into 11 different phyla. The different criteria for animal classification are explained below.

### Levels of Organisation

Though animals are multicellular, the level of organization of cells varies from one animal to another. Certain animals have a loose mass of cells and show the cellular level of organization. Such animals have been categorized into the phylum Porifera. As we move on, the complexity of body design amplifies and the division of labour occurs among the tissues. These animals exhibit tissue level of organisation and are classified as coelenterate. Phylum Platyhelminthes and Aschelminthes have an organ level of organization. Non-chordates such as Annelids, Arthropods, Molluscs, Echinoderms, and Chordates have a specialised organ system for their physiological activities. They have the organ-system level of organisation. Although these animals have organ systems level of organisation. The complexities of organ systems vary and are categorised into different phyla.

### Symmetry

Symmetry is another basis for the classification of animals. Generally, animals show two types of symmetry-

**Radial symmetry:** A symmetry where any plane passing through the central axis divides the body into two equal halves is called the radial symmetry. Examples are Coelenterates, ctenophores and echinoderms.



**Bilateral symmetry:** In bilateral symmetry, only a single plane divides the body into two equal halves, e.g. Annelids, Arthropods, Molluscs, etc.



However, some animals do not show any symmetry i.e. their body can't be divided into two halves in any plane passing through the centre. Such animals are said to be asymmetrical, e.g. Poriferan.

### **Diploblastic and Triploblastic Organisation**

All animals develop their tissues, organs and organ system from the cells that form the embryonic layers. Based on the number of embryonic layers, animals are classified into two- diploblastic and triploblastic animals.

**Diploblastic animals:** In diploblastic animals, the cells form two embryonic layers, i.e., an outer layer- ectoderm and an inner layer – endoderm, e.g. Phylum Coelenterata.

**Triploblastic animals:** In triploblastic animals, cells are arranged in three embryonic layers- ectoderm, endoderm and a middle layer – mesoderm. Animals belonging to Phyla Platyhelminthes to Chordata have a triploblastic organisation.

The coelom is a key feature for classification. The coelom is a cavity between the body wall and gut wall, lined by mesoderm. Depending on the presence/absence of coelom, animals have been classified into three:

**Coelomate:** Coelom is present in a coelomate. Animals belonging to phyla Annelida, Mollusca, Arthropoda, Echinodermata, Hemichordata and Chordata are examples of coelomates.

**Pseudocoelomate:** In pseudocoelomates, mesoderm appears as pouches between the endoderm and ectoderm. But the cavity formed is not lined by mesoderm, e.g. Aschelminthes.

**Acoelomate:** Coelom is absent in an acoelomate, e.g. Platyhelminthes.

### ***Notochord***

The notochord is a longitudinal, cartilaginous supporting rod running beneath the nerve cord. The animal kingdom has been broadly classified into two, based on the presence or absence of notochord- Non-Chordata and Chordata. Chordates possess notochord while non-chordates lack it. Animals belonging to the Phylum Porifera to Phylum Echinoderms are non-chordates.

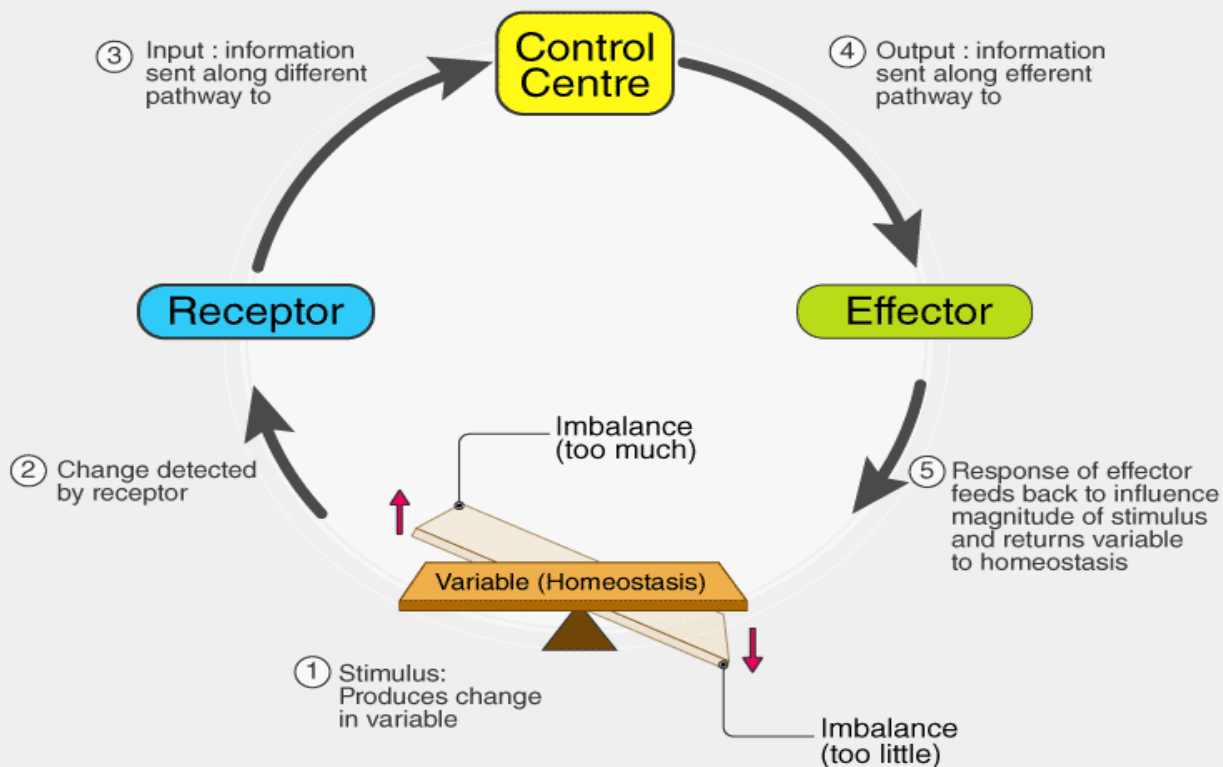
## Homeostasis

### **Homeostasis Definition**

***“Homeostasis is the state of steady internal chemical and physical conditions maintained by living systems.”***

### **Homeostasis Meaning and Etymology**

The theory of homeostasis was first introduced by Claude Bernard, a French Physiologist in the year 1865, and the term was first used in 1926 by Walter Bradford Cannon. Bradford derived Homeostasis from the ancient Greek words ὁμοιος (pronounced: hómoios) and ἵστημι (pronounced: hístēmi). The combination of these words translates to “similar” and “standing still” respectively.



**Homeostasis** is a property of a human biological system where the self-regulating process tends to maintain the balance for the survival. The regulation takes place in a defined internal environment

Read on to explore what is homeostasis and its role in regulating internal body environment.

### What is Homeostasis?

Homeostasis is quite crucial for the survival of organisms. It is often seen as a resistance to changes in the external environment. Furthermore, homeostasis is a self-regulating process that regulates internal variables necessary to sustain life.

In other words, homeostasis is a mechanism that maintains a stable internal environment despite the changes present in the external environment.

The body maintains homeostasis by controlling a host of variables ranging from body temperature, blood pH, blood glucose levels to fluid balance, sodium, potassium and calcium ion concentrations.

The regulation of homeostasis depends on three mechanisms:

1. Effector.
2. Receptor.
3. Control Center.

The entire process continuously works to maintain homeostasis regulation.

### ***Receptor***

As the name suggests, the receptor is the sensing component responsible for monitoring and responding to changes in the external or internal environment.

### ***Control Center***

The control centre is also known as the integration centre. It receives and processes information from the receptor.

### ***Effector***

The effector responds to the commands of the control centre. It could either oppose or enhance the stimulus.

## **Homeostasis Breakdown**

The failure of homeostasis function in an internal environment will result in illnesses or diseases. In severe cases, it can even lead to death and disability.

Many factors can affect homeostasis. The most common are:

- Genetics.
- Physical condition.
- Diet and nutrition.
- Venoms and toxins.
- Psychological health.
- Side effects of medicines and medical procedures.

## **Body Systems and Homeostasis**

The body system participates in maintaining homeostasis regulations. The purpose of the body system is to describe several controlling mechanisms where every system contributes to homeostasis.



listed below. Some tissues which absorb raw materials perform different functions to maintain the internal body environment.

### **Other Examples of Homeostasis**

1. Blood glucose homeostasis.
2. Blood oxygen content homeostasis.
3. Extracellular fluid pH homeostasis.
4. Plasma ionized calcium homeostasis.
5. Arterial blood pressure homeostasis.
6. Core body temperature homeostasis.
7. The volume of body water homeostasis.
8. Extracellular sodium concentration homeostasis.
9. Extracellular potassium concentration homeostasis.
10. Blood partial pressure of oxygen and carbon dioxide homeostasis.

## **Chemistry of Nutrition**

**Nutrition** is the process of providing the body with the raw materials it needs to function and grow. There are three major macronutrients (carbohydrates, proteins, and fats) that function as the major building blocks and fuel for physiological processes. Additionally, a balanced diet must contain sufficient micronutrients like vitamins and minerals.

Humans receive their micronutrients and macronutrients from plant and animal sources. The whole structures (leaves of plants, muscles of animals, etc.) are broken down into their chemical components through digestion, then those individual molecules are reassembled to make new cells or are broken down further to provide energy for cellular function.

Improper nutrition (whether it is *overnutrition* or *undernutrition*) is associated with chronic diseases and birth defects.

### **Carbohydrates**

**Carbohydrates** are neutral compounds made of carbon, hydrogen, and oxygen. Carbohydrates form chains of repeating units, or polymers, and can be classified based on the number of units they contain.

Monosaccharides are the basic units of carbohydrates. Glucose is the most important monosaccharide in human nutrition, because it is the body's primary source of fuel and the only way the brain can obtain energy. If glucose is not obtained from the diet in sufficient quantities, the body must produce it through gluconeogenesis in order to maintain brain function.

**Fructose** and **galactose** are other examples of nutritionally important monosaccharides. The ribose and deoxyribose found in DNA are also examples of monosaccharides.

**Disaccharides:** two monosaccharides linked together form a disaccharide.

**Lactose** (galactose + glucose) and **sucrose** (fructose + glucose) are examples.

**Oligosaccharides** (3-9 sugar molecules): maltodextrin, for example, is a glucose oligosaccharide produced by corn.

**Polysaccharides** (many sugar molecules): Both **starch** and **cellulose** are long chains of glucose molecules. In starch, every glucose molecule is oriented the same way in space (this is called alpha linkage). Cellulose, on the other hand, is a repeating pattern where every other glucose molecule is rotated by 180 degrees (beta linkage). This may seem like a minor difference, but the result is that starch is digestible to humans and a useful source of energy, while cellulose is indigestible for humans, and is an example of dietary fiber. Human bodies have the necessary enzymes to break down starch into glucose, but not cellulose. Some other creatures do, like termites, but cellulose is generally **stronger** than starch, for instance, it's not dissolvable in water.

Functions of carbohydrates:

1. Energy homeostasis: sugar (in the form of glucose) is the main energy source for the body and the only energy source the brain can utilize. Problems with carbohydrate homeostasis can result in diabetes mellitus or hypoglycemia.
2. Nucleotide formation: DNA and RNA are made of up nucleic acids, which consist of a sugar (deoxyribose or ribose) bound to phosphate and a nitrogenous base.
3. Glycoprotein formation: Glycoproteins result from a carbohydrate attaching to a amino-acid or polypeptide chain. Mucin (a component of mucus), hemoglobin A1c, antibodies in the immune system, and clotting factors are examples.

**Proteins** are made of *amino acids* and account for about 15% of body mass (the second largest component after water). About 50% of the protein mass in a human body falls into one of the following categories:

1. Collagen, which is found in skin.
2. Myosin and actin, which are found in muscles.
3. Hemoglobin, which is a component of the blood.

Amino acids are utilized extensively during DNA translation to make new proteins for use throughout the body. Some individual amino acids can be synthesized by the body, as long as the overall quantity of protein is sufficient. **Essential amino acids** cannot be synthesized endogenously (within the body) and must be obtained directly from the diet. These are also referred to as *indispensable amino acids*. There are eight:

1. Isoleucine
2. Leucine
3. Phenylalanine
4. Valine
5. Threonine
6. Methionine
7. Tryptophan
8. Lysine

Proteins are classified based on how well they supply essential amino acids. **Incomplete proteins** are missing one or more of the essential amino acids, while **complete proteins** contain them all. Generally, animal proteins are the best source of indispensable amino acids, followed by legumes, cereals, and tubers, respectively.

## Lipids

Lipids (fats) have the highest energy content per gram of the macronutrients. They are an excellent way to store energy long term. Lipids are water-insoluble (they do not dissolve in water and, in this case, float in water), so they are transported through the bloodstream by lipoproteins.

**Triglycerides** are an ester found in natural fats and oils. Lipids can be **unsaturated**, meaning they contain one or more double bonds (olive oil is an example), or **saturated** (like butter). Naturally occurring unsaturated fats are cis isomers. Trans fats are a manufactured unsaturated fat that behaves like a saturated fat. The inclusion of trans fats in processed foods has been controversial, and their use has been banned in many countries after data showed that eating trans fats increased the risk of coronary heart disease, even compared to saturated fats.

Essential fatty acids cannot be synthesized by the body. Humans must obtain omega-6 (linoleic acid, found in vegetable oils) and omega-3 (alpha-linolenic acid, found in foods like salmon and flax seeds) from their diets. Most other lipids can be manufactured by the liver in a process called **lipogenesis**. **Phospholipids** are a major structural component of cell membranes and help determine how flexible the membrane is. Saturated fatty acids pack more densely, making the overall structure of the membrane more rigid, while the kinks in unsaturated fatty acids take up extra space, making the membrane more fluid.

**Sterol**, the backbone of cholesterol, is the starting material for many hormones synthesized by the body, including aldosterone, cortisol, and the sex hormones estrogen, progesterone, and testosterone.

Energy Balance.

## Micronutrients

**Vitamins** and **minerals** are also necessary for biochemical reactions. They are organic molecules that cannot be synthesized by the human body in sufficient quantities to meet its basic metabolic needs. They are either water soluble (vitamins B and C) or fat soluble (vitamins A, D, E, and K).

Minerals of Dietary Importance:

1. **Calcium** regulates cellular processes.
2. **Potassium, sodium,** and **chloride** regulate membrane potentials in nerve and muscle cells.
3. **Magnesium** acts as a cofactor in hundreds of reactions, also involved in metabolism, protein synthesis, and nucleic acid synthesis.
4. **Copper** is involved in oxidation reactions.
5. **Zinc** regulates gene expression.

## Overnutrition

For most of human history, nutritionally important foods like sugars, salts, and fats have been scarce at least part of the year. As a result, humans developed a taste for foods high in sugar and fat, the ability to store excess calories, and the ability to eat large quantities in a single sitting. (It's pretty nonsensical to fell a woolly mammoth with spears, take three bites of it, and then be full.)

Over the past two centuries, innovations like nitrogen fertilizers and refrigeration have dramatically increased the food supply, transforming the landscape into a land of constant plenty and saving large numbers of people from starvation every year. However, evolution is a relatively slow process, and the human body is still programmed the same way it was when food was scarce. Ancestrally adaptive

behaviors sometimes common in the 21st century, leading to high rates of obesity, diabetes, hypertension and other chronic diseases.

## Undernutrition

Undernutrition is a major concern for many communities around the world.

Some undernourished individuals suffer from an **absolute deficiency** of macronutrients, like marasmus, a condition where lack of protein leads to low energy, emaciation, and muscle wasting. Marasmus is caused by inadequate intake, absorption, or utilization of protein. Lack of food is a common cause, but anorexia nervosa, major depression, and malabsorption syndromes can also lead to marasmus.

People suffering from kwashiorkor also have a protein deficiency, even though they have a relatively high energy diet. This condition is common when a diet is based on a low quality diet that lacks some of the essential amino acids, and is referred to as a **relative deficiency**. People suffering from kwashiorkor are emaciated, but also have a bloated abdomen due to edema.

## Digestion

The human digestive system refers to the organs that take in food and break them down. Digestion describes the complex process that enables the nutrients in food to enter the body and its cells.

Food contains all of the nutrients a person's body needs for health, but large, complex compounds bind them. During digestion, the body breaks these compounds down into smaller parts. This enables them to enter cells, providing energy and other benefits.

This article explains how the body digests food from when it enters the mouth to when it exits the body. It also suggests some tips for healthy digestion and how to identify problems.

### What is digestion?

The human gastrointestinal tract, also called the alimentary canal, is around 30 feet (9 meters) long in adults.

- the mouth, or oral cavity
- the esophagus
- the stomach
- the small intestine
- the large intestine, or colon
- the rectum

In addition, the following organs support digestion, for example, by chewing or adding enzymes and other secretions that enable the body to absorb nutrients:

- the teeth
- the tongue
- the salivary glands
- the liver
- the pancreas
- the gallbladder

Together, these organs provide mechanical processing, the secretion of enzymes and bile to help break down compounds, and the excretion of waste.

Some terms to describe these functions include:

- ingestion, which includes chewing and swallowing
- the secretion of substances that enable food and nutrients to move through the body effectively
- propulsion, where muscles move the contents of the canal forward
- digestion, the breakdown of food, for example, through chewing and secretions
- the absorption of nutrients, which mainly occurs in the small intestine
- defecation and urination, the removal of waste products through the rectum and the bladder, respectively

Digestion begins even before the food enters the mouth.

When a person smells or thinks of food or eating, the salivary glands begin producing saliva.

Once the food is inside of the mouth:

- saliva moistens it.
- the teeth and tongue break it down mechanically.
- an enzyme in the saliva, salivary amylase, breaks it down into starch.

Chewing and amylase digestion will convert the food into a small, round blob, or bolus. This enables a person to swallow it easily.

## **The esophagus**

After swallowing, the bolus enters the esophagus, where gravity and muscle contractions help move it down to the stomach through a process called peristalsis.

Peristalsis is the slow contraction of smooth muscles along and around the digestive system.

As the bolus moves through the esophagus, these contractions push it toward the stomach.

## **The stomach**

The bolus enters the stomach through a ring-like muscle Trusted Source called the lower esophageal sphincter. This sphincter relaxes, allowing the bolus to enter the stomach.

In the stomach, the following processes occur:

- The stomach stores the food temporarily.
- Cells in the stomach secrete gastric juices. These include hydrochloric acid, which maintains the pH of the stomach between 1.5–2.0 Trusted Source.

The stomach has three muscular layers that churn and mix its contents.

These processes turn the food into a thick paste, known as chyme.

Hydrochloric acid is essential for:

- destroying microorganisms, such as bacteria
- breaking down proteins and plant fibers
- activating pepsin, an enzyme that helps digest proteins

The acid, however, can harm the stomach lining, so some cells produce mucus to protect the lining from damage.

The stomach does not absorb many nutrients from the chyme into the bloodstream, so the chyme enters the small intestine through the pyloric sphincter.

### **The small intestine**

The small intestine is around 20 ft (6 m) long and absorbs around 90% Trusted Source of the nutrients from food into the bloodstream.

There are three sections:

- **The duodenum:** This receives chyme from the stomach and digestive enzymes from the liver and pancreas.
- **The jejunum:** Most of the chemical digestion and absorption occur here.
- **The ileum:** This contains the ileocecal valve, a sphincter through which food passes to the large intestine.

Once the food is fully broken down, the villi absorb the nutrients, which enter the bloodstream.

Villi are tiny, finger-like projections that line the walls of the small intestine. Within the villi are tiny capillaries called lacteals. By increasing their surface area, the villi maximize their absorption of nutrients.



The large intestine

Any unabsorbed food and nutrients now pass to the large intestine, or colon. The material is now feces.

The large intestine is around 6 ft (2 m)Trusted Source long and consists of the:

- cecum, a pouch through which food enters from the small intestine
- ascending colon
- transverse colon
- descending colon
- sigmoid colon

From the large intestine, the body absorbs water and electrolytes.

Food travels slowly through the colon to allow the body to absorb water, and trillionsTrusted Source of gut bacteria break down any undigested food.

Next, peristalsis moves the feces toward the rectum.

### **The rectum**

As the digested food moves into the rectum, nerves in the wall of the rectum known as stretch receptors detect when the chamber is full and stimulate the desire to defecate.

Defecation involves two types of muscle movement.

The first happens automatically, and a person cannot control it. This is a relaxation of the smooth muscles in the internal anal sphincter.

The second, a person can control and is a conscious relaxation of the skeletal muscles in the external anal sphincter. If a person wishes to delay defecation, they can avoid relaxing their muscles to move the feces back into the colon.

The longer feces stay in the colon, the more water the body will absorb. This can lead to dry, hard feces, constipation, and possibly impaction. For this reason, a person should defecate as soon as is convenient.

If person should seek medical advice if they are unable to urinate for about    days or if they have abdominal or rectal pain or bleeding

**Cellular metabolism** is the set of chemical reactions that occur in living organisms in order to maintain life. Cellular metabolism involves complex sequences of controlled biochemical reactions, better known as metabolic pathways. These processes allow organisms to grow and reproduce, maintain their structures, and respond to environmental changes.

### Regulation

The chemical reactions of metabolism are organized into metabolic pathways, in which one chemical is transformed into another by a sequence of enzymes. Enzymes are crucial to metabolism and allow the fine regulation of metabolic pathways to maintain a constant set of conditions in response to changes in the cell's environment, a process known as homeostasis.

### Classification

Cellular metabolism has two distinct divisions: anabolism and catabolism. Anabolism is a constructive metabolic process in which a cell uses energy to construct molecules such as enzymes and nucleic acids and perform other essential life functions. Anabolism involves three basic stages: firstly, the production of precursors such as amino acids, monosaccharides, isoprenoids and nucleotides; secondly, their activation into reactive forms; and thirdly, the assembly of these precursors into complex molecules.

Catabolism is the metabolic process by which the cell breaks down complex molecules. The purpose of catabolic reactions is to provide the energy and components needed by anabolic reactions. Catabolic reactions are normally exothermic and are further subdivided according to their substrate into carbohydrate, fat, and protein catabolism.

Evolution of life on earth has not been a simple process. Some explain it as a process while some interpret it as a result of various natural occurrences. The evolutionary theory tries to convey the message of the origin of the earth and how lives on earth evolved. Evolution as a process, explains how the world came into existence. It has resulted in biodiversity.

### **What is Evolution?**

The process by which modern organisms have descended from their ancestors, with changes in their allele frequencies, is called evolution.

The Big Bang Theory is the most accepted theory regarding the origin of life on earth and different forms of life in it. According to the theory, the universe is a result of a huge explosion, which occurred 20 billion years ago. It took another 10 billion years for the origin of the earth. Once earth originated, it grew, and the living conditions like the temperature and atmosphere stabilized. It is believed that the first life form came into existence on earth around 2000 million years ago (mya).

Even though there is no clear picture of the evolution of the first living cell, it is assumed that the first cell originated from non-cellular molecules. This cell is divided to form more of them. The evolving cells had few characteristic features which helped them to survive. These features include the ability to trap light energy and derive energy from it and the oxygen releasing capacity of the cells. Finally, single unicellular organisms evolved to form much more complex multicellular organisms.

Once the multicellular organisms evolved, evolution happened at a much faster pace. The further series of development and evolution of new organisms like invertebrates, plants, animals such as reptiles, fish, amphibians, mammals, etc., took place within a time range of 500-300 million years ago (mya). Later these organisms started to evolve in their own way. This commenced the branching of lineages. Environmental conditions like climatic changes, limited resources, predators, etc. played an enormous role in that. During each phase of evolution, one life form dominated over the other. Nature selected one over the other, which was called the fittest of all.

The flow of evolution of animals began with jawless fish (350 mya) before plants (320 mya) invaded the lands. Later, fish which could live on both land and water replaced plants, they fed on them. Amphibians, which were derived from these lobefin animals later evolved into reptiles. Reptiles of different shapes, sizes, and life patterns flourished during that many mya. Certain ones lived in water, e.g., Ichthyosaurs (200 mya), others lived on land. Dinosaurs were a known land reptiles which existed at that time. Due to some unknown reasons, they became extinct. Followed by reptiles, there was an era of mammals which dominated all other species.

Various processes such as natural selection, genetic drift, gene flow, etc. had contributed a lot in developing the living conditions and organisms as we know them today.

The evolution occurs due to the changes in the gene pool- the collection of **genes**. There are four key mechanisms that cause changes in gene pool of a population. These include:

1. Mutation
2. Gene Flow
3. Genetic Drift
4. Natural Selection

### **Mutations**

Mutations are defined as the changes in the DNA sequence of a living organism. The mutations occurring in the germ cells, i.e., the egg or sperm cells only are passed on to future generations. These mutations are inherited from the parents and are present in every cell throughout a person's life. These are the mutations that lead to evolution. The acquired mutations occur during a person's life and are present only in some cells. These are caused due to environmental factors such as ultraviolet radiation and do not pass on to future generations. They are not a part of evolution.

### **Gene Flow**

The transfer of genes from one population to another is called gene flow.

For eg., pollen moving from one place to another by the action of wind or people moving to different cities or countries. When a person from one country moves to the other and mates with a person there, a transfer of genes occurs between the individuals. This is how the gene flows between different populations. Gene transfer can be horizontal, i.e., the transfer of genetic material from one population to another by asexual means. This phenomenon is prevalent in prokaryotes.

### **Genetic Drift**

It refers to the change in the allele frequency of a population as a matter of chance. It is a random event whose effect is larger in smaller populations and smaller in larger populations. The two examples of genetic drift are the bottleneck effect and the founder effect.

- **Founder Effect:** When a small number of individuals separated from a larger population make up a new population, there is a loss of genetic diversity. They do not carry the genetic diversity of the previous population.

Due to this, some genetic traits become more prevalent than others, which results in genetic diseases in future generations.

## **Natural Selection**

Some individuals with certain traits have higher survival and reproductive rate than others. They pass on these genetic features to their offspring which brings an evolutionary change into the future generations. This selection of the genetic qualities that prove beneficial for survival in future generations is known as natural selection.

Darwin's Finches is one classic example of natural selection. Darwin's finches have evolved into 15 different species depending upon their adaptation and feeding habits.



**Zoo 101– Zoology I( حيوان عام 1) مقرر**  
**لطلاب الفرقة الأولى بكلية العلوم شعبة البيوتكنولوجي**  
**للعام الدراسي 2024-2025 الترم الاول**

**الجزء العملي**

**إعداد**

**دكتوراه سهام علي مبارك**

**القائم بالتدريس**

**دكتوراه مريم ابوبكر فاوي**

# Microscopes

## Types of microscopes

### 1- Light microscope

#### I- Illuminating system (source of light):

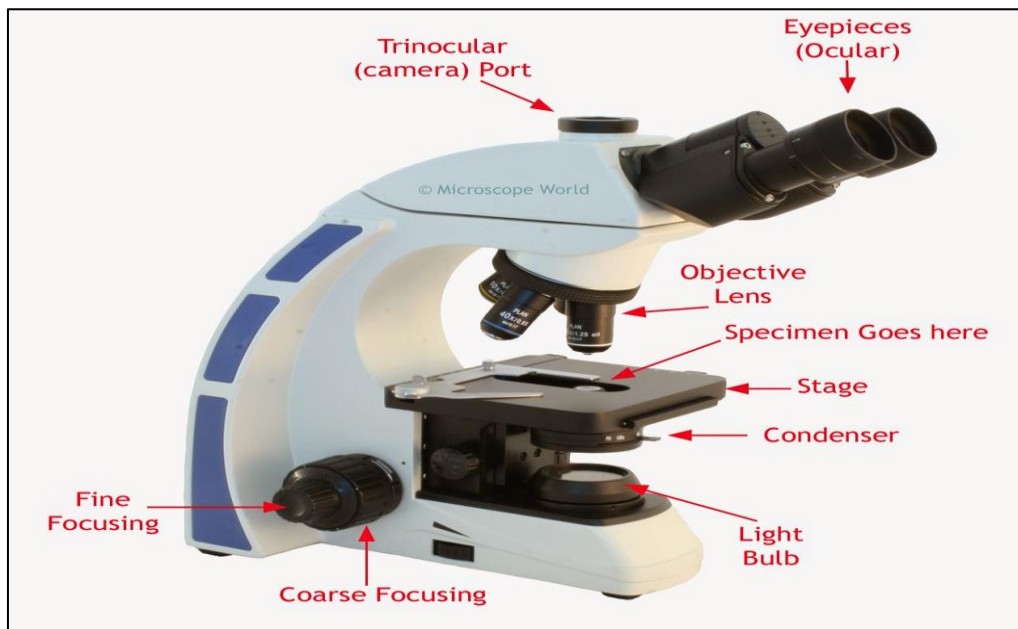
- Day light.
- Electric light.

#### II- Optical system:

- *Condenser lens*: collect and focus light on the specimen.
- *Objective lenses*: provide initial magnification (x4, x10, x40, x100).
- *An ocular lens (eyepiece)*: magnifies the primary

image a second time (x5, x10, x15).

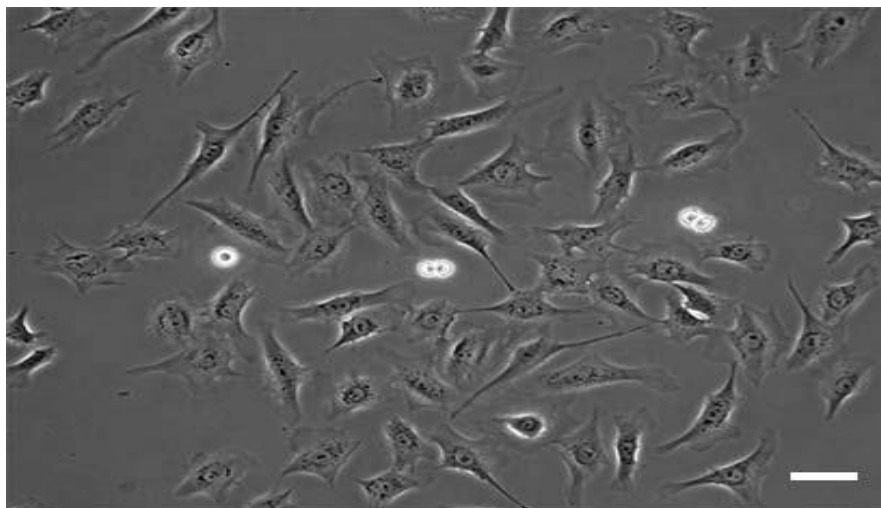
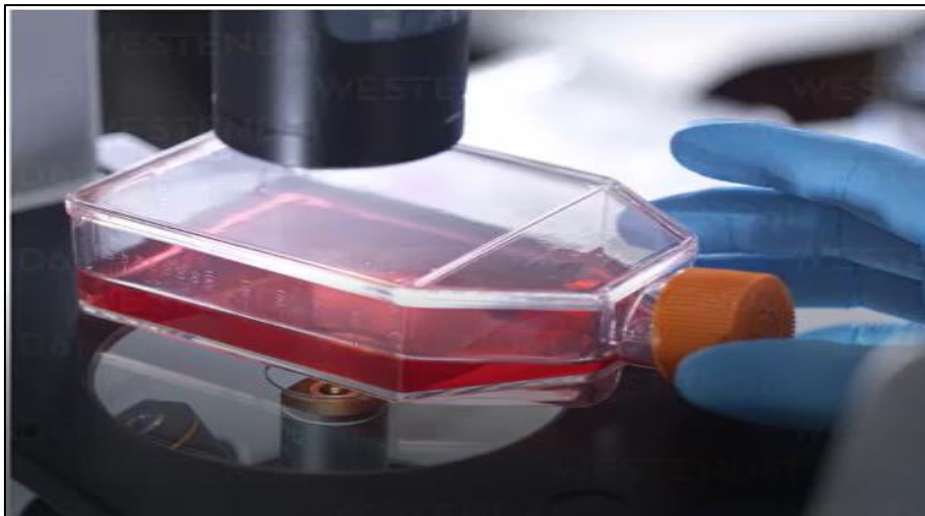
**III- Focus adjustment knobs:** focus the image by moving the stage up and down.



Total magnification= Magnifying power of the objective lens x magnifying power of ocular lens

## 2- Phase contrast microscope


- Use: for unstained living histological specimen.





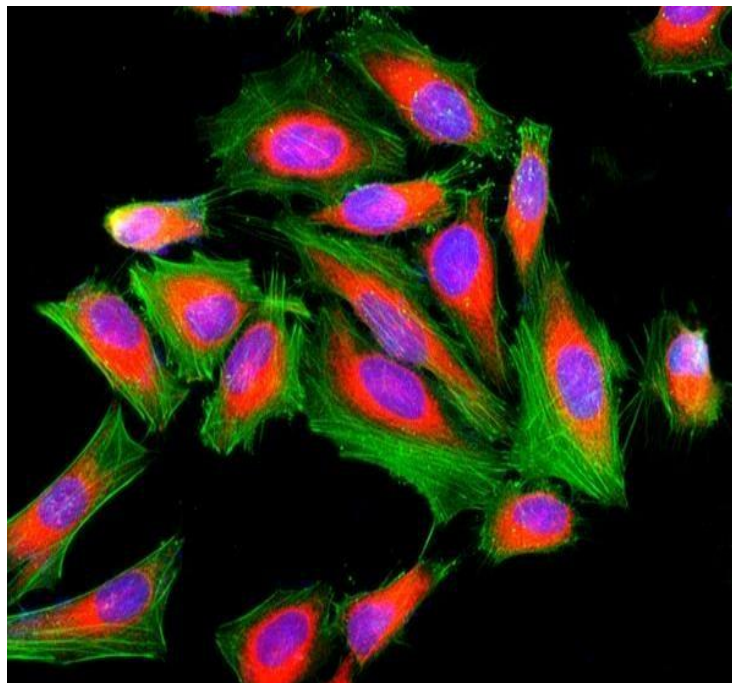
### 3- Polarizing microscope

- Use:
  - Regularly oriented structures (bone).
  - Structures with linear symmetry (collagen, muscle, microtubules, cilia& flagella).



#### 4- Fluorescence microscope

- **Light source:** ultraviolet light source.
- **Stain:** fluorescent stain.
- **Idea:** the specimen absorbs the UV light and emits light of a longer wavelength.
- **Use:** immunohistochemistry.



## 5- Electron microscope

- **Illuminating system:** electron beam.
- **Types:**

### 1- Transmission EM:


- It gives details about the cellular and intercellular structures.
- An electron gun at the top of a TEM emits electrons.
- An electromagnetic lens focuses the electrons into a very fine

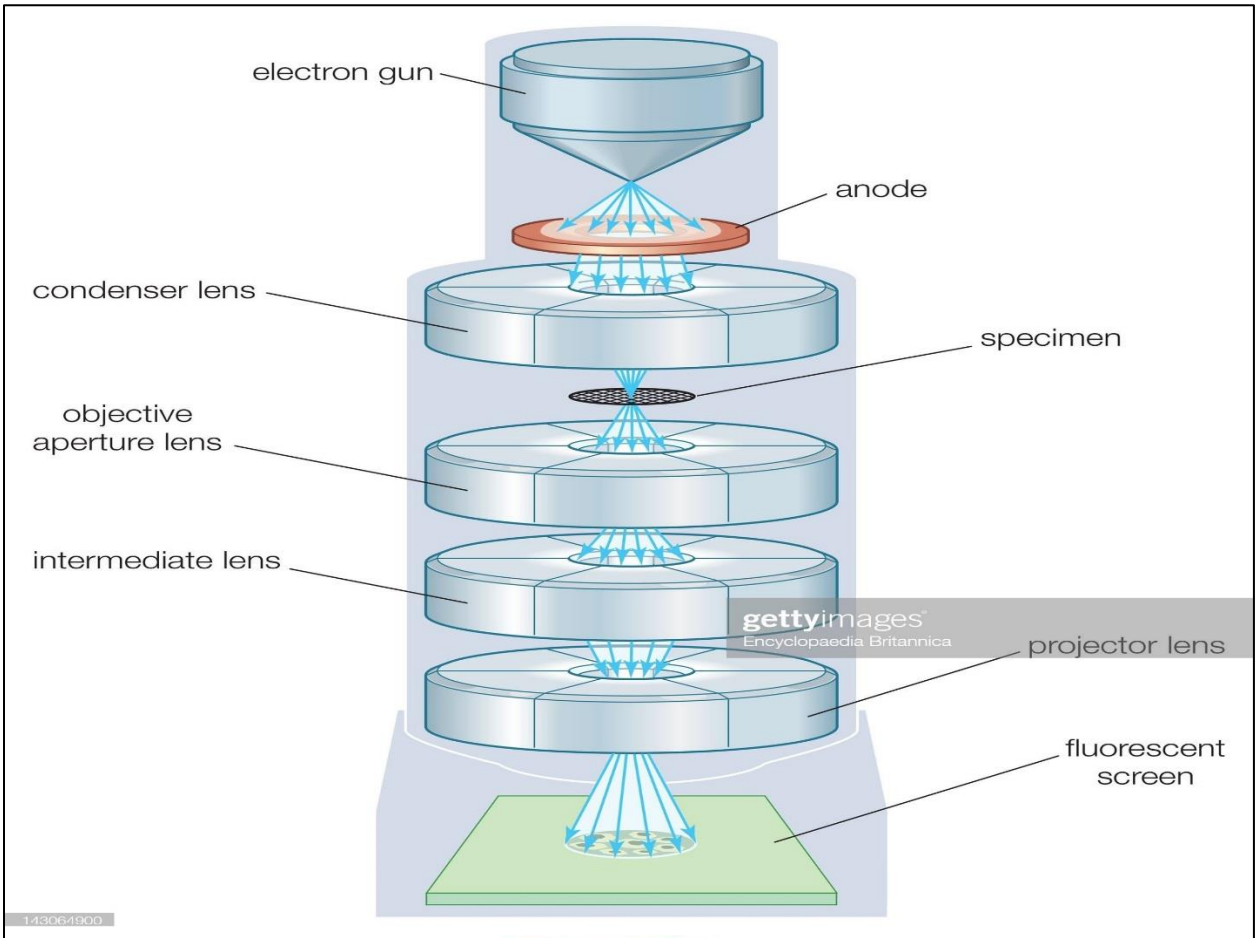
beam.

- This beam then passes through a very thin specimen.
- Another electromagnetic lenses form and magnify the image.
- The final image is viewed on a fluorescent screen.

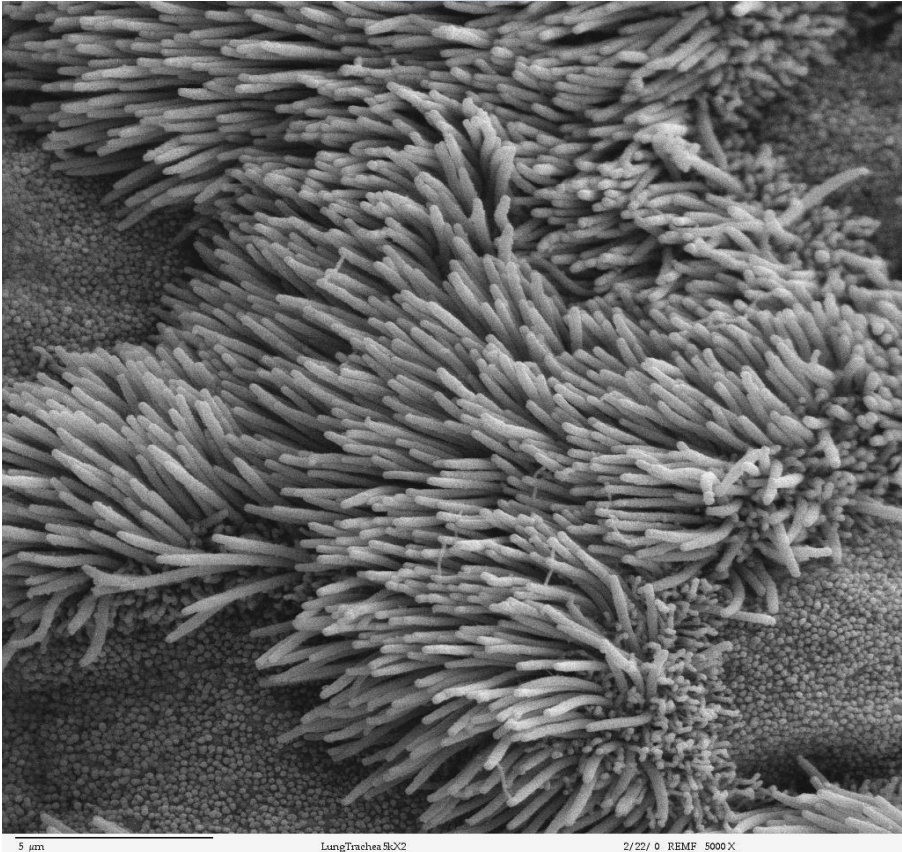
### 2- Scanning EM:

- Gets 3-D image of the surface of the specimen.





**SEM**



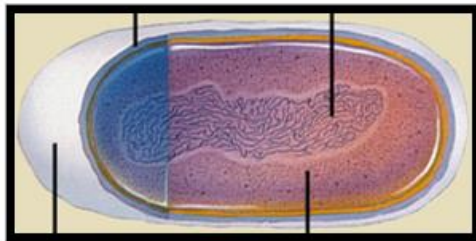
Type of microscope	LM	EM
<b>1- Source of light</b>	Day or electric light.	Beam of electrons.
<b>2- Lenses</b>	Glass lenses.	Magnetic fields.
<b>3- Magnification</b>	Up to 1500.	Up to 1000.000.
<b>4- Embedding</b>	Paraffin.	Plastic.
<b>5- Sectioning knife</b>	Rotatory microtome: steel knife.	Ultra microtome: glass or diamond knife.
<b>6- Staining</b>	Any stain.	Lead citrate & osmium tetroxide.
<b>7- Thickness of section</b>	5-9 microns.	50-90 nm.
<b>8- Microphotographs</b>	Colored according to stain.	Black & white.

# Cytology

## Different Types of Cells

<b>Definition of a cell</b>	Smallest functional unit within a living organism that can function independently
<b>Components</b>	Plasma membrane, cytoplasm, nucleus, membranous organelles, non-membranous organelles
<b>Membranous organelles</b>	Nucleus, Endoplasmic reticulum, Golgi apparatus, mitochondria, peroxisomes, lysosomes, transport vesicles
<b>Non-membranous organelles</b>	Ribosomes, microtubules, cytoskeleton (actin filaments, intermediate filaments, centrioles)

## Two Fundamentally Different Types of Cells

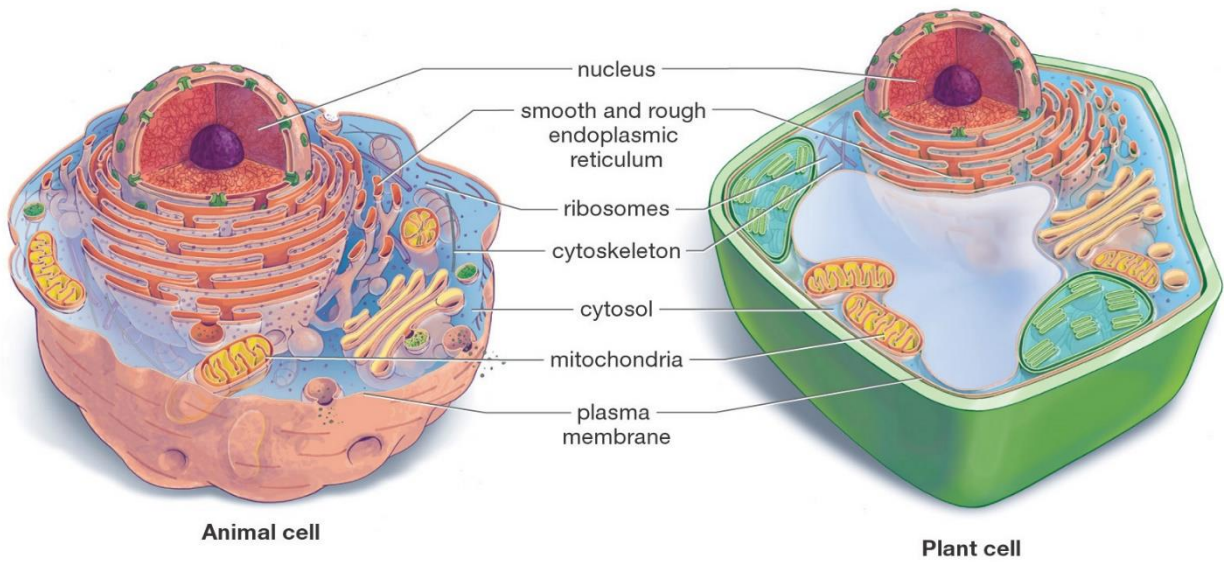


A prokaryotic cell

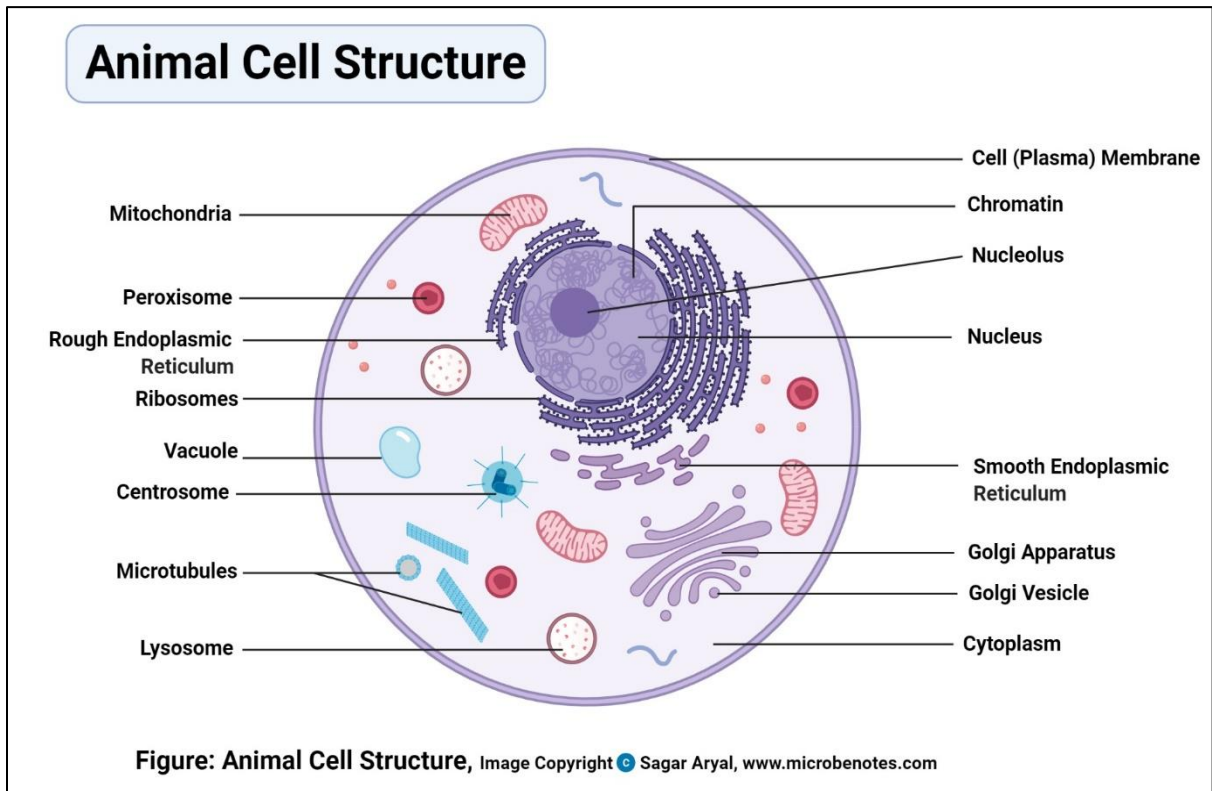


A eukaryotic cell

## Animal and Plant Cells Have More Similarities Than Differences

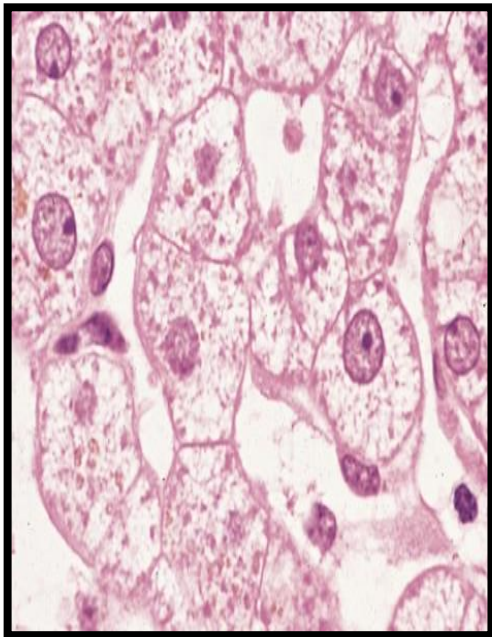
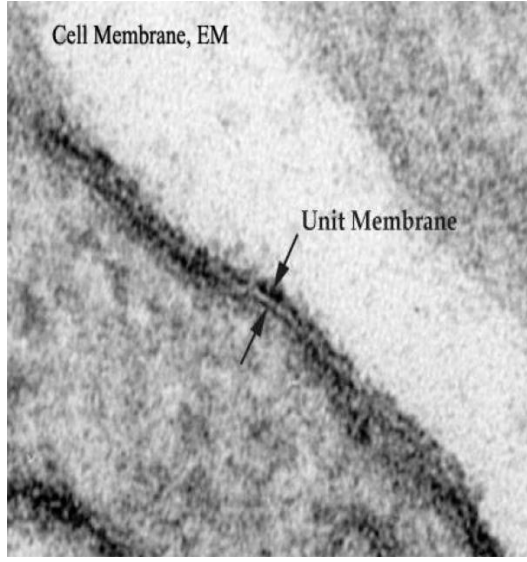


### Draw animal cell



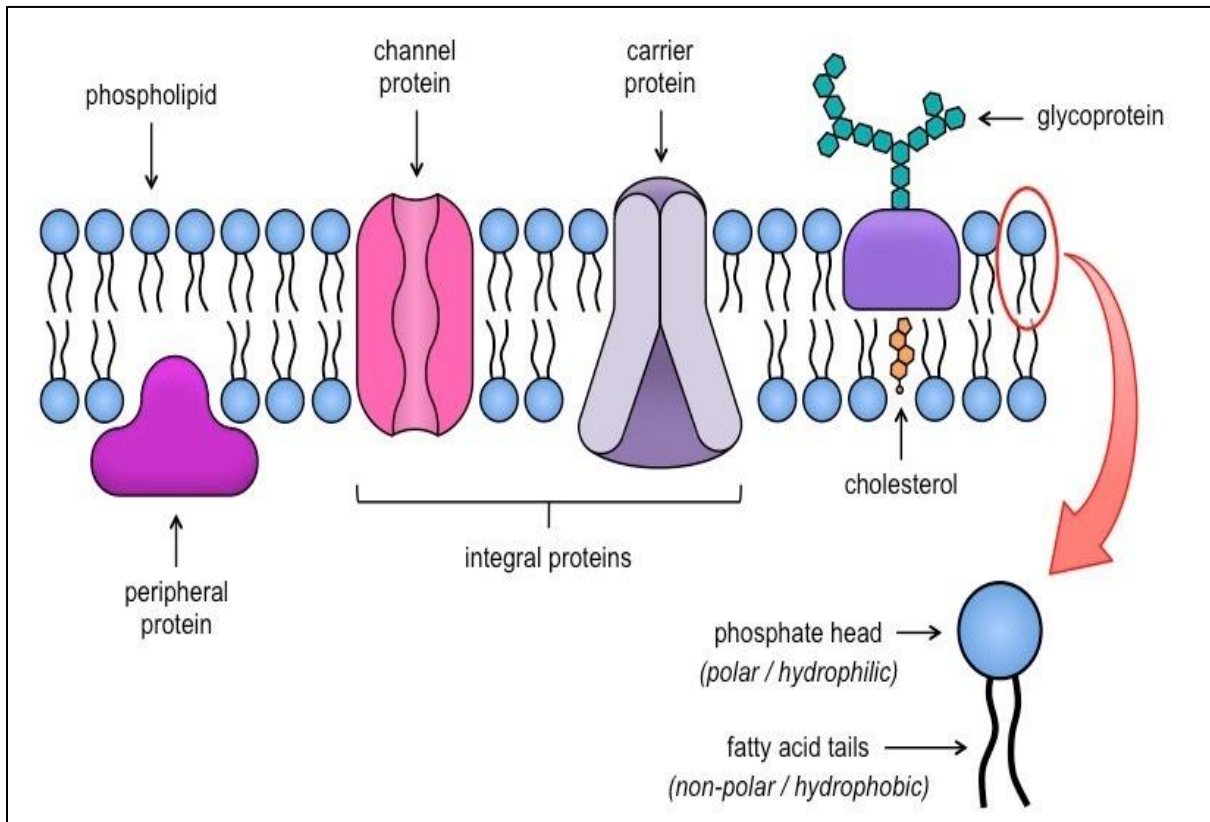
# Cell organelles

## 1- Cell membrane

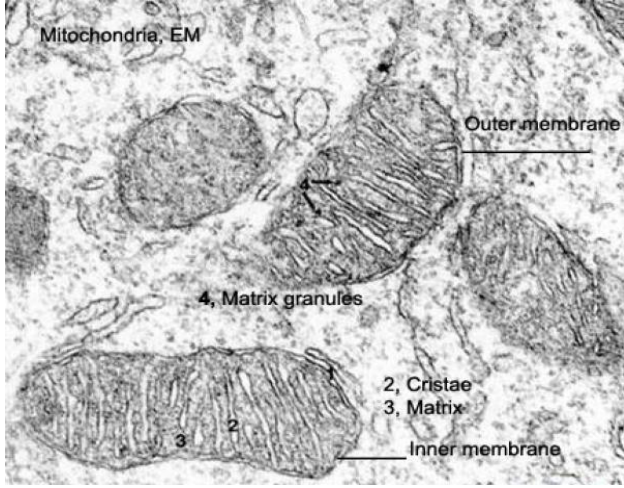
		Structure	Function
		Molecular structure of the Cell membrane 3 components: 1-Lipid molecules: a- phospholipids b- cholesterol 2- Protein molecules: 50% of the membrane mass. 3- Carbohydrate molecules	Its function is to protect the integrity of the interior of the cell by allowing certain substances into the cell while keeping other substances out. It also serves as a base of attachment for the cytoskeleton in some organisms and the cell wall in others. Thus, the cell membrane also serves to help support the cell and help maintain its shape.
		LM	EM
Cell membrane	It can not be seen by light microscope <i>because</i> it is too thin to be seen <i>but</i> the condensation of the stain on the outer surface of the cell membrane marks its.		1- <i>At low magnification:</i> thin dense line 8 - 10 nm in thickness. 2- <i>With higher magnification:</i> a trilaminar structure, with an outer (= extracellular leaflet) and an inner (= cytoplasmic leaflet) electron dense lines and a middle electron lucent zone in between.
			



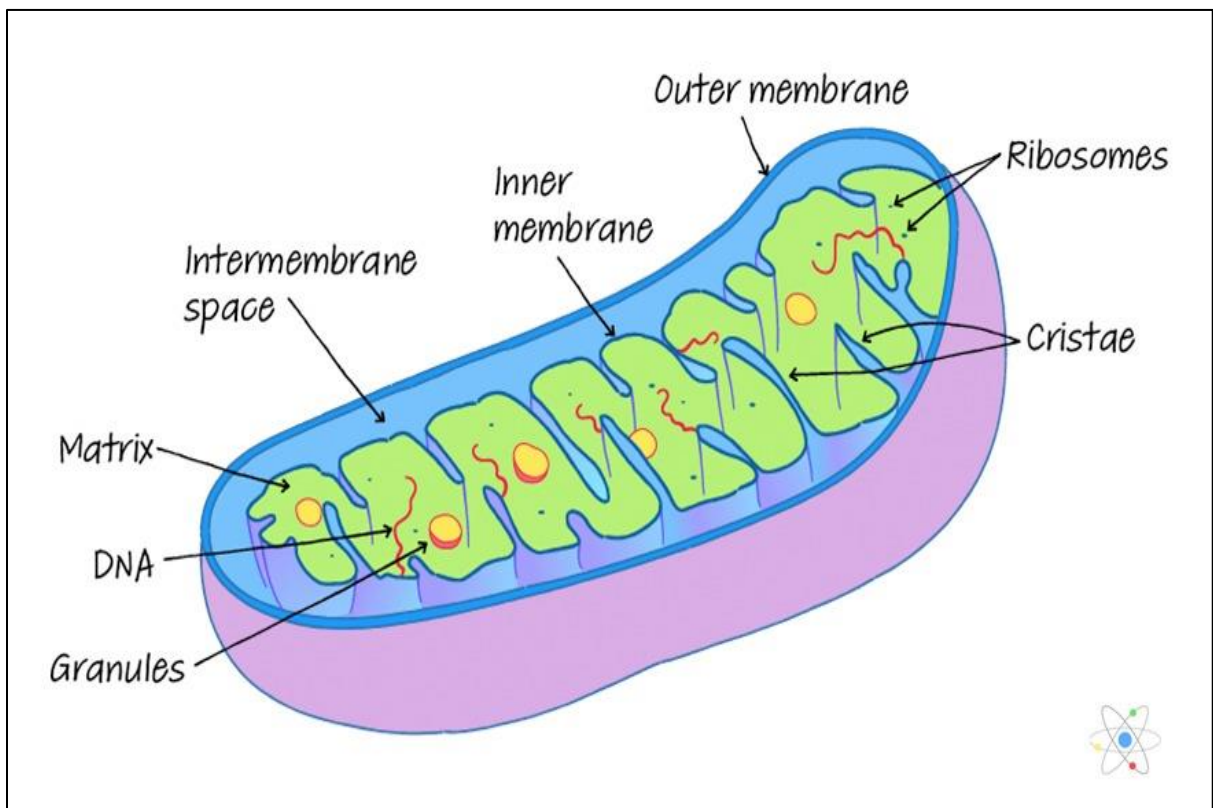
# Draw



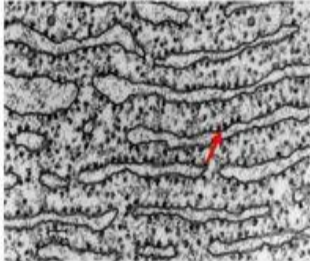
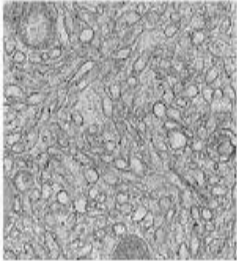
## 2- Mitochondria

<b>Mitochondria</b>	<b>Structure</b>	<b>Function</b>
	<p>The mitochondrion is composed of compartments that carry out specialized functions. These compartments or regions include the outer membrane :</p> <ol style="list-style-type: none"> <li>1. The outer mitochondrial membrane.</li> <li>2. The intermembrane space (the space between the outer and inner membranes).</li> <li>3. The inner mitochondrial membrane .</li> <li>4. The cristae space (formed by infoldings of the inner membrane) .</li> <li>5. The matrix (space within the inner membrane), which is a fluid.</li> </ol>	<ul style="list-style-type: none"> <li>• They house the chains of enzymes that catalyze reactions that provide the cells with most of its ATP (adenosine triphosphate).</li> <li>• On demands, the ATP yields its high-energy phosphate bond to another molecule and become transformed into ADP.</li> <li>• Within the mitochondrial matrix, ADP is transformed again into ATP. These processes take place within the mitochondrial matrix and inner mitochondrial membranes.</li> <li>• The matrix contains enzymes of Krebs cycle and fatty acid oxidation. The inner membrane contains the cytochromes and the enzymes involved in ATP production.</li> <li>• Due to their role in energy production, the mitochondria are likened to powerhouses of the cells.</li> <li>• Participate in regulation of calcium level within the cytosol.</li> </ul>
	<b>LM</b>	<b>EM</b>
	<p>they appear as granules, rod-like or thread-like. Their size range from 5-10 mm length and 0.5-1 mm in diameter. The number is highly variable according to the energy requirements of the cells. Liver cells (active cells) contain as many as 1000 mitochondria. Small lymphocytes (inactive cells) contain very few.</p> <p>They are motile organelles and localize at intracellular sites of high-energy requirements such as basal regions of ion-transporting cells</p>	<p>they appear as ovoid or elongated structures bounded by two membranes. The outer membrane is smooth. The inner membrane is thrown into folds called cristae projecting into the inner cavity that is filled with an amorphous substance called matrix. The number of the cristae seen in mitochondria is directly related to the energy requirement of cell .</p>  <p>The electron micrograph shows several mitochondria with a smooth outer membrane and a highly folded inner membrane forming cristae. Labels include: 'Mitochondria, EM' at the top left; 'Outer membrane' pointing to the smooth surface; '4, Matrix granules' pointing to small dark spots; '2, Cristae' and '3, Matrix' pointing to the internal folds and fluid respectively; and 'Inner membrane' pointing to the folded structure.</p>

**Draw**



### 3- Endoplasmic reticulum

		Structure	Function
		<b>Endoplasmic reticulum</b>	<p><b>The rough endoplasmic reticulum (rER)</b> is a membranous organelle concerned principally with synthesis and secretion of proteins. It is called rough due to the presence of large number of ribosomes attached to its limiting membrane.</p> <p><b>The smooth endoplasmic reticulum (sER)</b></p> <p>is a membranous organelle consists primarily of a network of branching and anastomosing tubules and vesicles.</p> <p>It differs from the rER in that its limiting membrane is smooth and devoid of ribosomes.</p>
<b>LM</b>	<b>EM</b>		
	<p><b>rER</b> it appears as basophilic cytoplasmic areas that are referred to as the ergastoplasm or chromidial substances.</p> <p><b>sER</b> it does not appear. The cytoplasm of the cells contained abundant sER usually appears acidophilic.</p>	<p><b>rER</b>; Much of the surface of the rER is studded with ribosomes giving the reticulum a rough or granular appearance.</p> <p><b>sER</b>; it appears as irregular network of membranous tubules and vesicles devoid of ribosomes in contrast to the flattened ribosome-studded cisternae of rER. The sER tubules may be continuous with those of rER and Golgi apparatus.</p> <div style="display: flex; justify-content: space-around; align-items: center;"> <div style="text-align: center;"> <p>Rough endoplasmic reticulum (RER)</p>  </div> <div style="text-align: center;"> <p>Smooth endoplasmic reticulum (SER)</p>  </div> </div>	

**Draw**

## Endoplasmic Reticulum (ER)

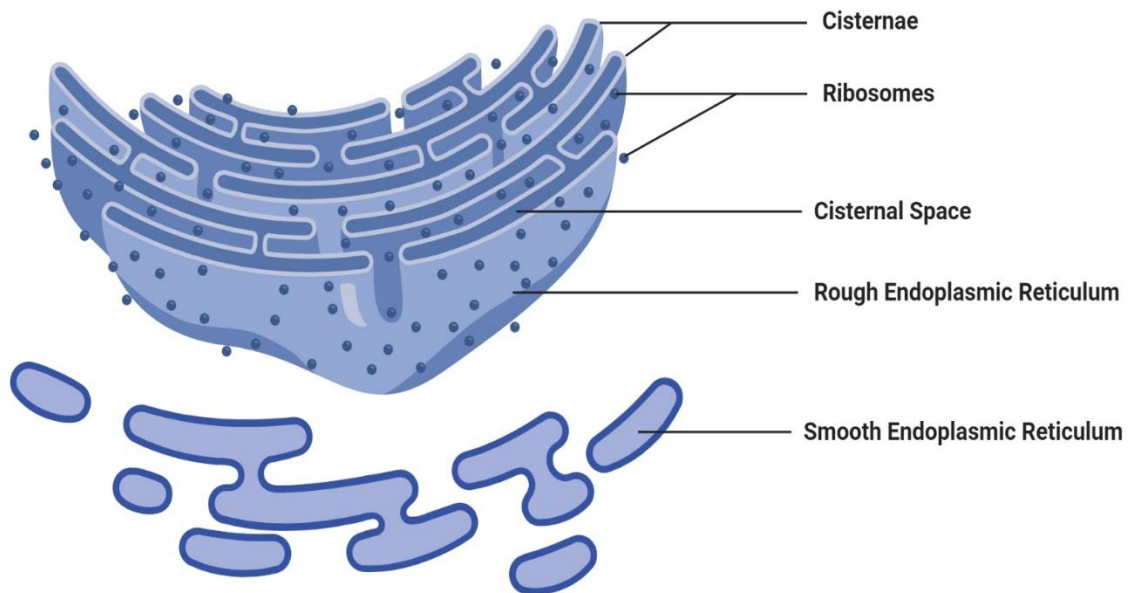
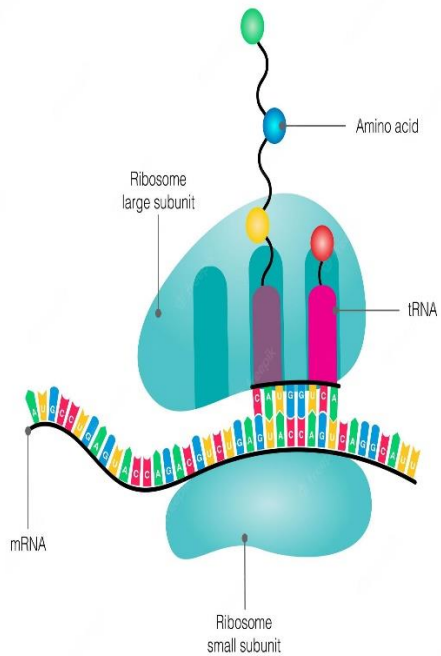
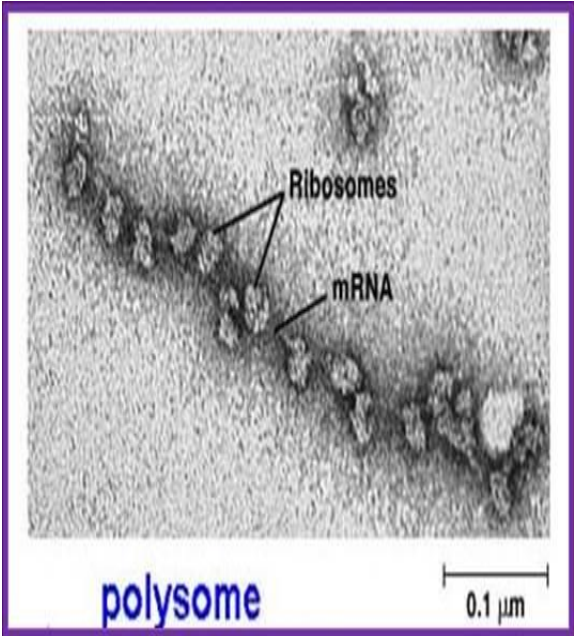
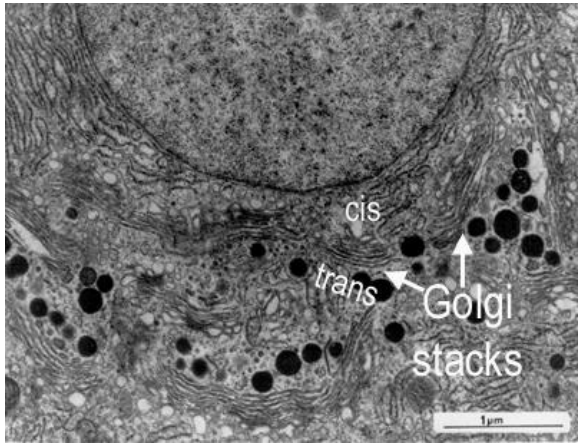


Figure: Endoplasmic Reticulum (ER), Image Copyright © Sagar Aryal, [www.microbenotes.com](http://www.microbenotes.com)

## 4- Ribosomes

		Structure	Function
<b>Ribosomes</b>		<ul style="list-style-type: none"> <li>✓ They are rounded ribonucleoprotein particles, 20-30 nm in diameter that provide the intracellular sites where amino acids are linked together to form polypeptide chains (proteins).</li> <li>✓ Each ribosome composed of a large and a small subunit that are made of rRNA and different types of proteins.</li> </ul>	<ul style="list-style-type: none"> <li>✓ Free ribosomes are responsible for synthesis of proteins for internal use (cytoplasmic proteins and enzymes).</li> <li>✓ Attached ribosomes are responsible for synthesis of proteins for external use (secretory or lysosomal enzymes).</li> </ul>
		<b>LM</b>	<b>EM</b>
		they are too small to be seen. However, cell containing abundant ribosomes usually has basophilic cytoplasm. Such cytoplasmic basophilia is largely due to the strong affinity of rRNA for hematoxylin.	ribosomes are seen free in the cytoplasm either as separate entities or attached to messenger RNA molecules in small aggregation called polyribosomes or polysomes. Polyribosomes may also be attached to the surface of rER.
		<b>Diagram</b>	
		<p style="text-align: center;"><b>Ribosome</b></p>  <p>The diagram illustrates the structure of a ribosome. It consists of a large subunit (top) and a small subunit (bottom). The large subunit contains rRNA and tRNA. The small subunit contains rRNA and mRNA. An amino acid chain is shown being synthesized from the large subunit. Labels include: Amino acid, Ribosome large subunit, tRNA, Ribosome small subunit, and mRNA.</p>	 <p>The electron micrograph shows a polysome, which is a complex of multiple ribosomes attached to a single mRNA molecule. The ribosomes appear as dark, rounded structures, and the mRNA is a thin, wavy line. Labels include: Ribosomes, mRNA, polysome, and a scale bar of 0.1 μm.</p>

## 5- Golgi apparatus

<b>Golgi apparatus</b>	<b>Structure</b>	<b>Function</b>
	<ul style="list-style-type: none"> <li>• a membranous organelle concerned principally with synthesis, concentration, packaging and release of the secretory products.</li> <li>• The Golgi saccules are arranged in Golgi stacks that contain from 3-10 saccules. Most cell types possess several stacks of Golgi saccules forming an elaborate ramifying network termed the Golgi complex.</li> <li>• Each stack of saccules has 1) a forming face or Cis face that is convex in shape. 2) a maturing face or trans face that is concave. The Cis face is usually associated with a number of small transfer vesicles. The trans face characterized by being associated with much larger secretory granules.</li> </ul>	<ul style="list-style-type: none"> <li>• Packaging and concentration of secretions.</li> <li>• Modification of the secretory products such as glycosylation and sulfation of proteins to form glycoproteins and sulfated glycoproteins (mucus).</li> <li>• Production of primary lysosomes.</li> </ul>
	<b>LM</b>	<b>EM</b>
<p>it can be selectively stained with silver salts or osmium where it appears as a black network located near the nucleus. In H&amp;E sections, it may be visible as a lighter-stained region called negative Golgi image. It is seen to great advantage in secretory cells such as osteoblasts.</p>	<p>the main structure unit of the Golgi apparatus is a flattened membranous vesicle called Golgi saccule.</p>  <p>The electron micrograph shows a cross-section of Golgi stacks. The stacks are composed of multiple flattened, parallel membrane-bound sacs (saccules). The top face of the stack is labeled 'cis' and the bottom face is labeled 'trans'. An arrow points to the 'Golgi stacks' with a scale bar of 1 μm.</p>	

## Draw

### Golgi apparatus (Golgi bodies/Golgi complex)

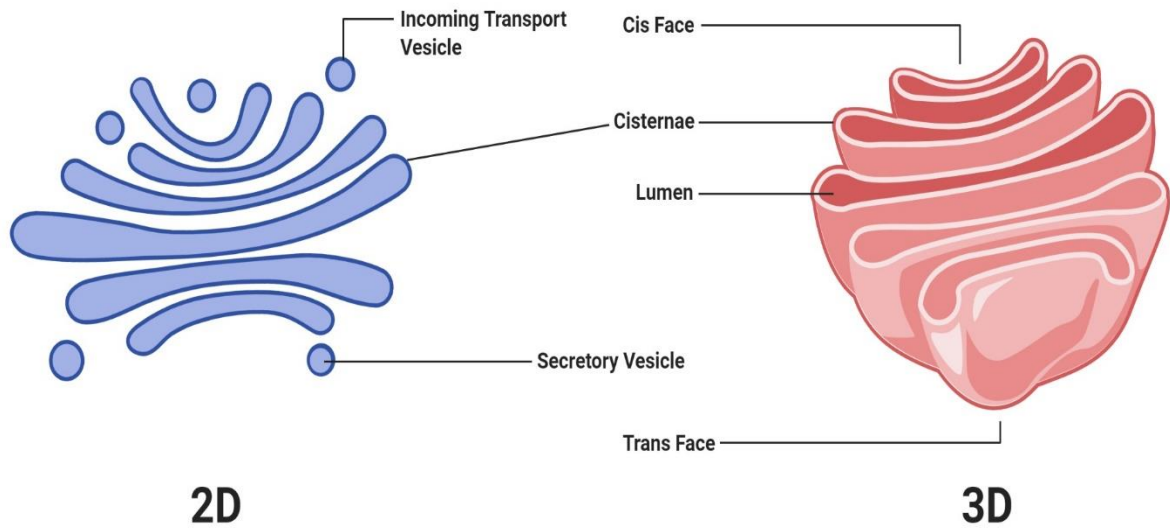
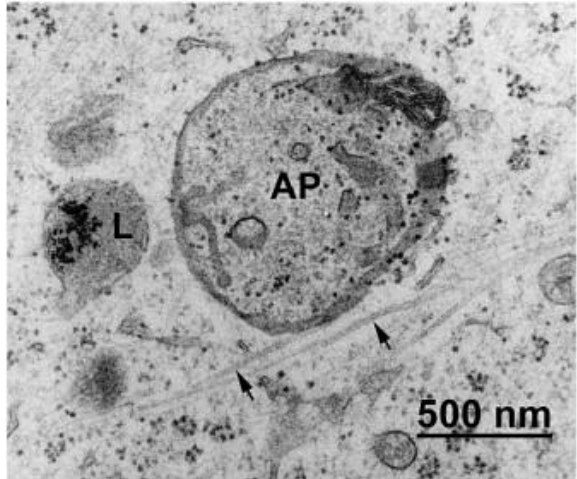
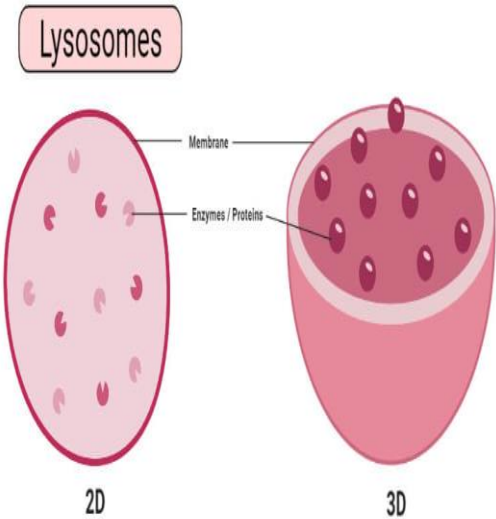


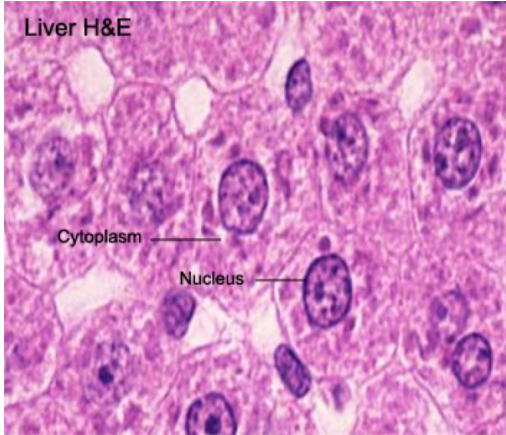
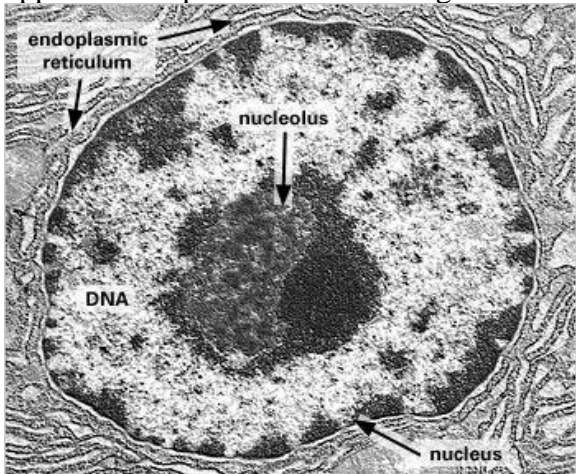
Figure: Golgi apparatus (Golgi bodies/Golgi complex), Image Copyright © Sagar Aryal, www.microbenotes.com



## 6- Lysosomes

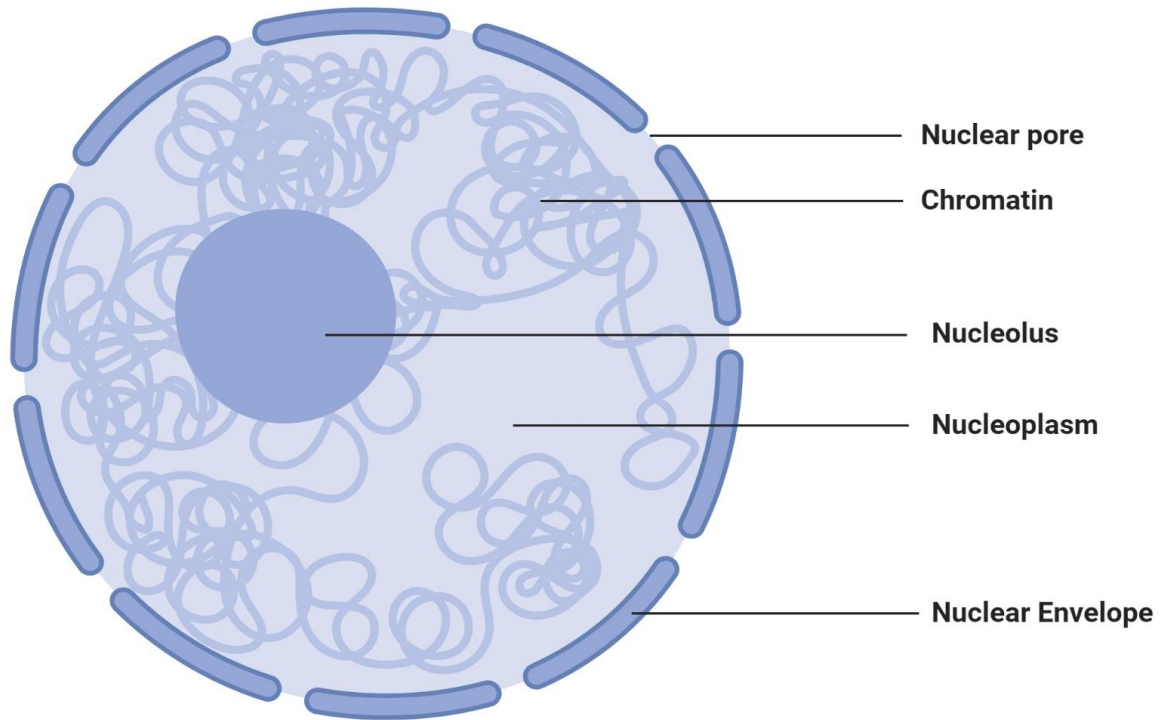
		Structure	Function
		They are membrane-bounded vesicles (0.2-0.4 $\mu$ m) containing a number (more than 40) of hydrolytic enzymes that are active at acid pH (acid hydrolases) maintained within their interior. This group of enzymes is capable of destroying all the major macromolecules (e.g., proteins and lipids) of the cells.	✓ Degradation of any exogenous macromolecules (phagocytosis and pinocytosis). ✓ Disposition of any organelles or cell constituents that are no longer useful to the cell (autophagy).
<b>Lysosomes</b>	LM	EM	
	provides no direct evidence for the existence of lysosomes. The lysosomes are resolved at the LM level when their enzyme contents (e.g., acid phosphatase) are stained by histochemical methods.	The lysosomes appear as spherical membrane-bounded vacuoles with their contents showing varying degree of electron density.	
	Diagram		
			

## 7- Nucleus

		<b>Structure</b>	<b>Function</b>
<b>Nucleus</b>		<p>It is the largest membranous organelle of the cell.</p> <p>The interphase (not engaged in cell division) nucleus consists of nuclear envelope, chromatin, nucleolus, and nuclear sap (karyolymph).</p> <ol style="list-style-type: none"> <li>1. Nuclear envelope</li> <li>2. Chromatin</li> </ol> <p>two types of chromatins are distinguished: heterochromatin and euchromatin.</p> <ol style="list-style-type: none"> <li>3. Nucleolus</li> </ol> <p>a conspicuous, spherical, basophilic structure that is primary concerned with synthesis of ribosomal RNA.</p> <ol style="list-style-type: none"> <li>4. Nuclear sap (karyolymph)</li> </ol> <p>The nuclear sap is a colloidal solution in which chromatins are suspended. It helps in the movement of RNA (rRNA, tRNA, and mRNA) toward the nuclear pores.</p>	<ul style="list-style-type: none"> <li>✓ The nucleus is the archive of the cell that carries the genetic information necessary to regulate the different cell functions. It consists primarily of DNA (20% of its mass), DNA-binding proteins, and some RNA.</li> <li>✓ The DNA-binding proteins are of two major type histones and non-histones. The histones are involved in the folding of DNA strands and regulation of DNA activity. The non-histones are involved in the regulation of gene activity.</li> <li>✓ The nuclear RNA represents newly synthesized transfer and ribosomal RNA that has not yet passed into the cytoplasm.</li> </ul>
	<b>LM</b>	<b>EM</b>	
	appears as lightly-stained basophilic areas.	appears as dispersed filaments or granules.	
	<p>Liver H&amp;E</p> 		

**Draw**

# Nucleus

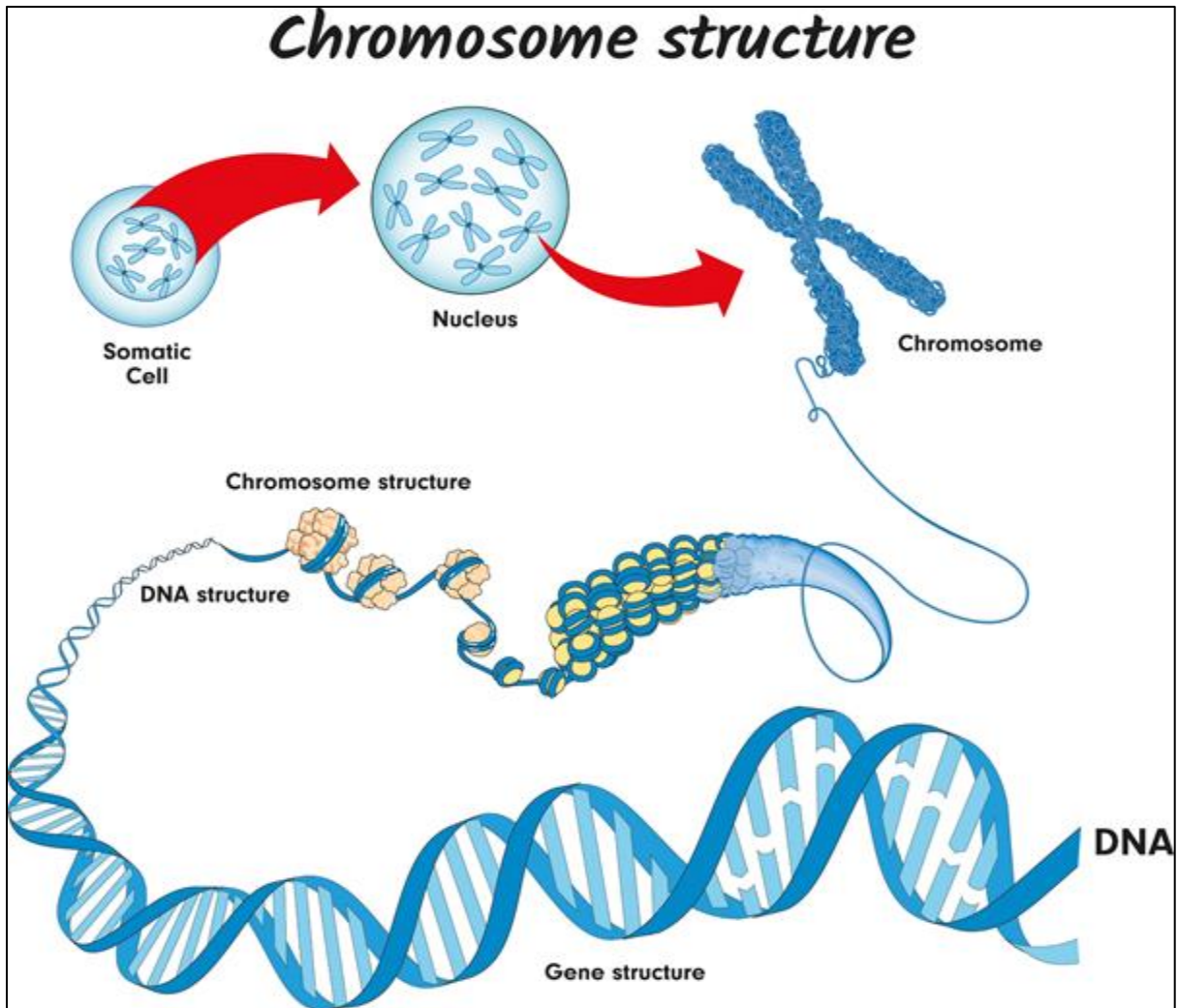


**Figure: Nucleus**, Image Copyright © Sagar Aryal, [www.microbenotes.com](http://www.microbenotes.com)

## 8- DNA and chromosomes

Inside the nucleus of a cell, there are thread-like structures called chromosomes. Each chromosome is made out of a long, coiled up strand of DNA (genetic material), which means that each chromosome contains many genes.

Normally, there are 46 chromosomes inside the nucleus of each human body cell. Chromosomes are usually found in pairs.



A **diploid** cell contains two complete sets of chromosomes in its nucleus, one from each parent. In humans, all body cells are diploid cells. Human diploid cells have 23 pairs of chromosomes (46 in total). The diploid number is often represented as  $2n$ , with  $n$  being the number of chromosomes. In humans,  $2n = 46$ .

The word **haploid** means half. It describes a cell that contains a single set of chromosomes. The symbol  $n$  is often used to show the haploid number. In humans,  $n = 23$ . Human sex cells (egg and sperm cells) contain a single set of chromosomes, so they are haploid cells.

- Sex cells are also called **gametes**

# Histology

## Tissue Preparation for Light Microscopy

- ✓ Stabilize cellular structures by chemical fixation.
- ✓ Dehydrate and infiltrate tissues with paraffin or plastic.
- ✓ Embed fixed tissues in paraffin or plastic blocks.
- ✓ Cut into thin slices of 3-10 micrometer thick; collect sections on slides.
- ✓ Re-hydrate and stain with Hematoxylin (a basic dye): Stains basophilic structures (e.g. nucleic acids) blue/purple.
- ✓ Counterstain with Eosin (an acidic dye): Stains acidophilic or “eosinophilic” structures (e.g. proteins, membranes) red/pink.
- ✓ “H & E” staining is routine, but other dyes and staining techniques may be used to visualize other structures.

## **Types of tissues**

(A group of cells that all perform the same specific function)

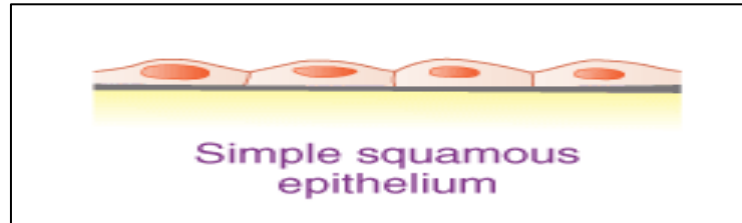
1. Epithelial Tissue – covers body surfaces and organs, lines body cavities
2. Connective Tissue – binds and supports body parts
3. Muscular Tissue – contracts producing movement
4. Nervous Tissue – responds to stimuli and transmits nerve impulses

# 1. Epithelial Tissue

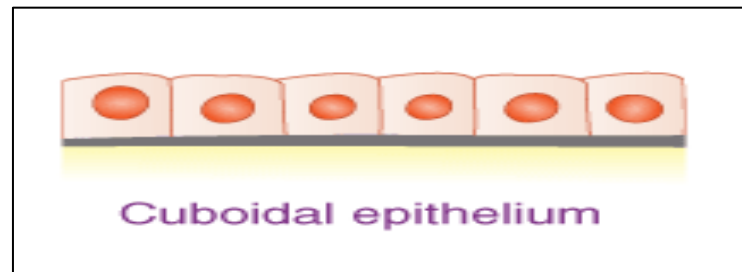
## Simple epithelium

It consists of single layer of epithelial cells resting on basement membrane.

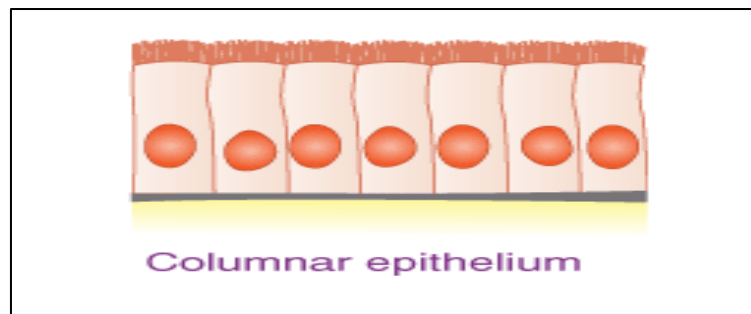
### i. Simple squamous epithelium



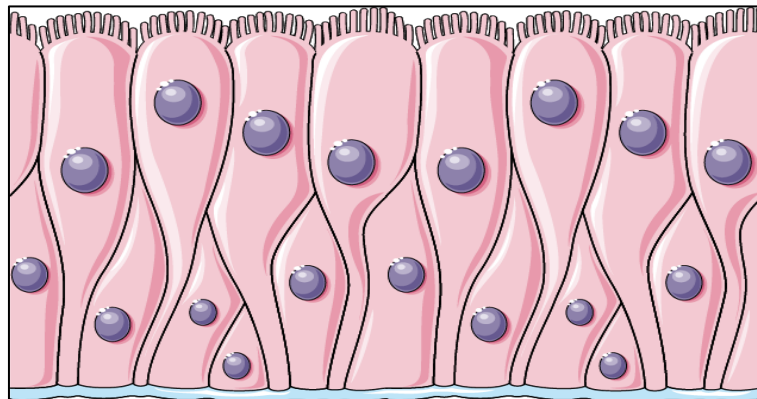
### ii. Simple cuboidal epithelium



### iii. Simple columnar epithelium



### iv. Pseudostratified columnar epithelium



# الأنسجة الطلائية

## Simple بسيطة

(تنظم خلاياها أساساً في طبقة واحدة)

(Cells arranged principally in one layer)

مهدبة  
طبقة كاذبة

Pseudo-stratified ciliated



بطانة القصبة  
الهوائية  
Inner lining  
of trachea

طبقة كاذبة

Pseudo-stratified



الجدار المبطن  
لقنوات بعض  
الغدد الكبيرة  
Inner wall  
lining ducts  
of some large  
glands

عمودية  
مهدبة

Ciliated Columnar



الفشاء المخاطي  
المبطن لتجويف  
المنطقة الأمامية  
لقناة البيض في  
الصفدة  
Mucous mem-  
brane lining  
the anterior  
region of the  
oviduct of  
the toad

عمودية

Columnar



الفشاء المخاطي  
للقناة الهضمية  
في الصفدة،  
من المريء  
حتى المستقيم  
Mucous  
membrane of  
alimentary  
canal of the  
toad, from  
oesophagus  
to rectum

مكعبانية  
(مكعبة)

Cuboidal



جدار الغدة  
العرقية  
Wall of  
sweat gland

حرفشية

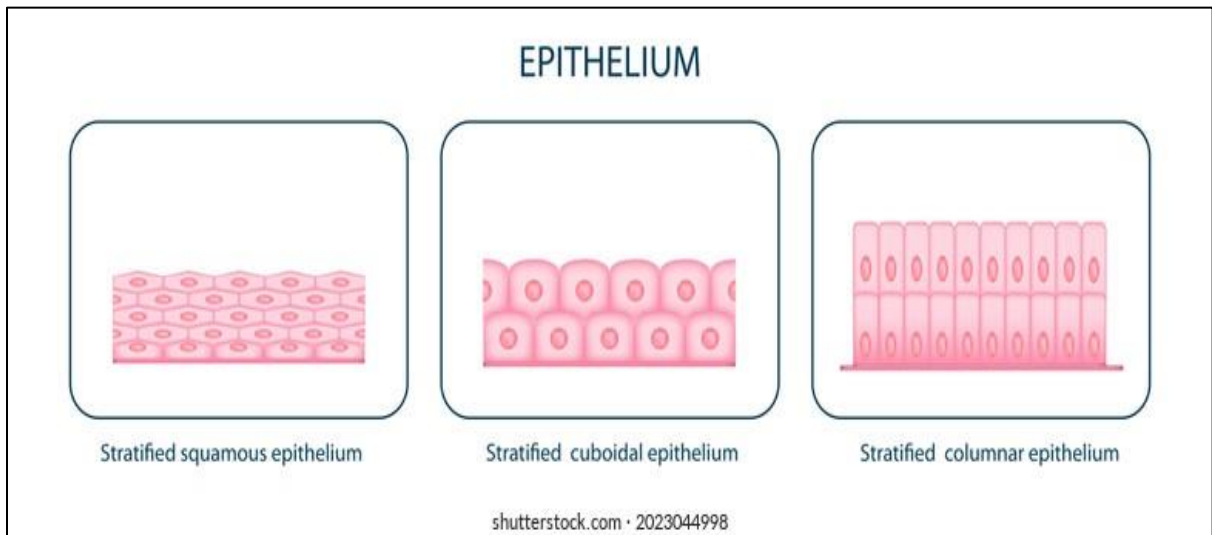
Squamous



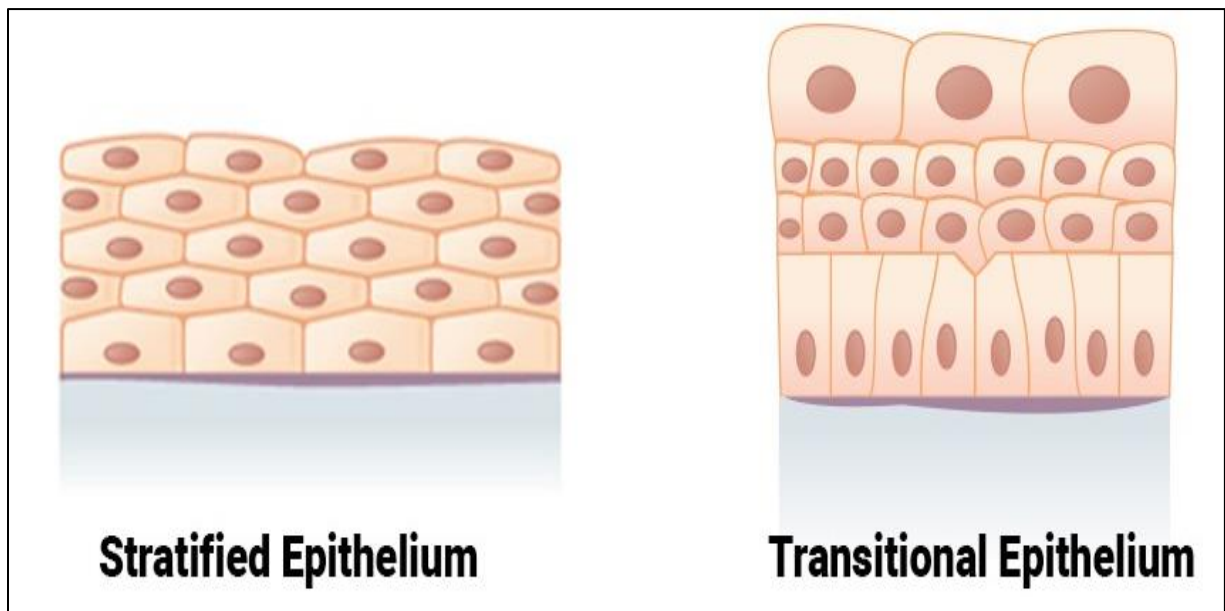
البطانية ، في  
جدار محفظة  
بومان  
Endothelium;  
wall of Bow-  
man's capsule

## Stratified epithelium

- It consists of two or more than two layers of cells.
  1. Stratified squamous epithelium
  2. Stratified cuboidal epithelium
  3. Stratified columnnar epithelium

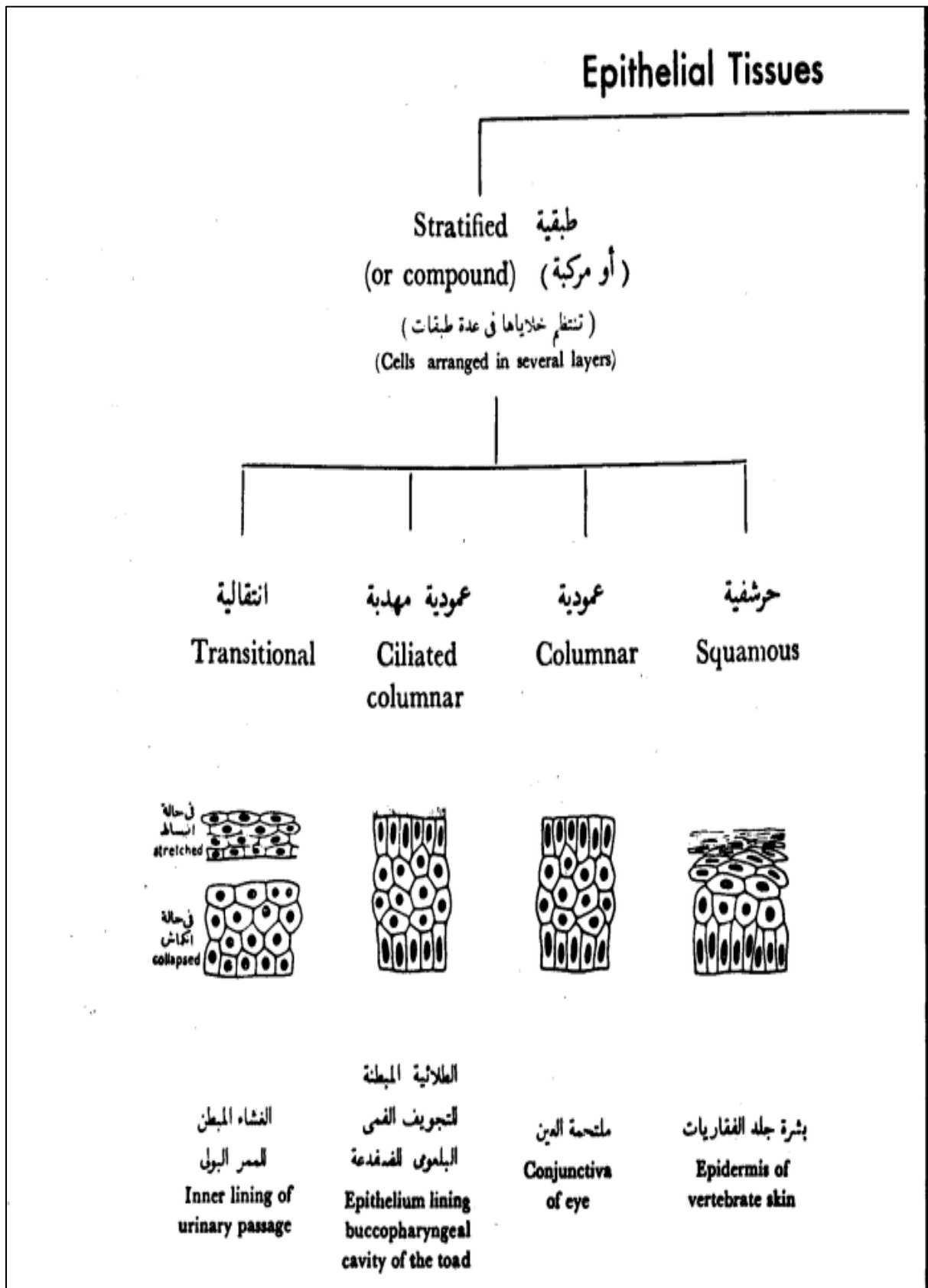


## 4. Transitional epithelium

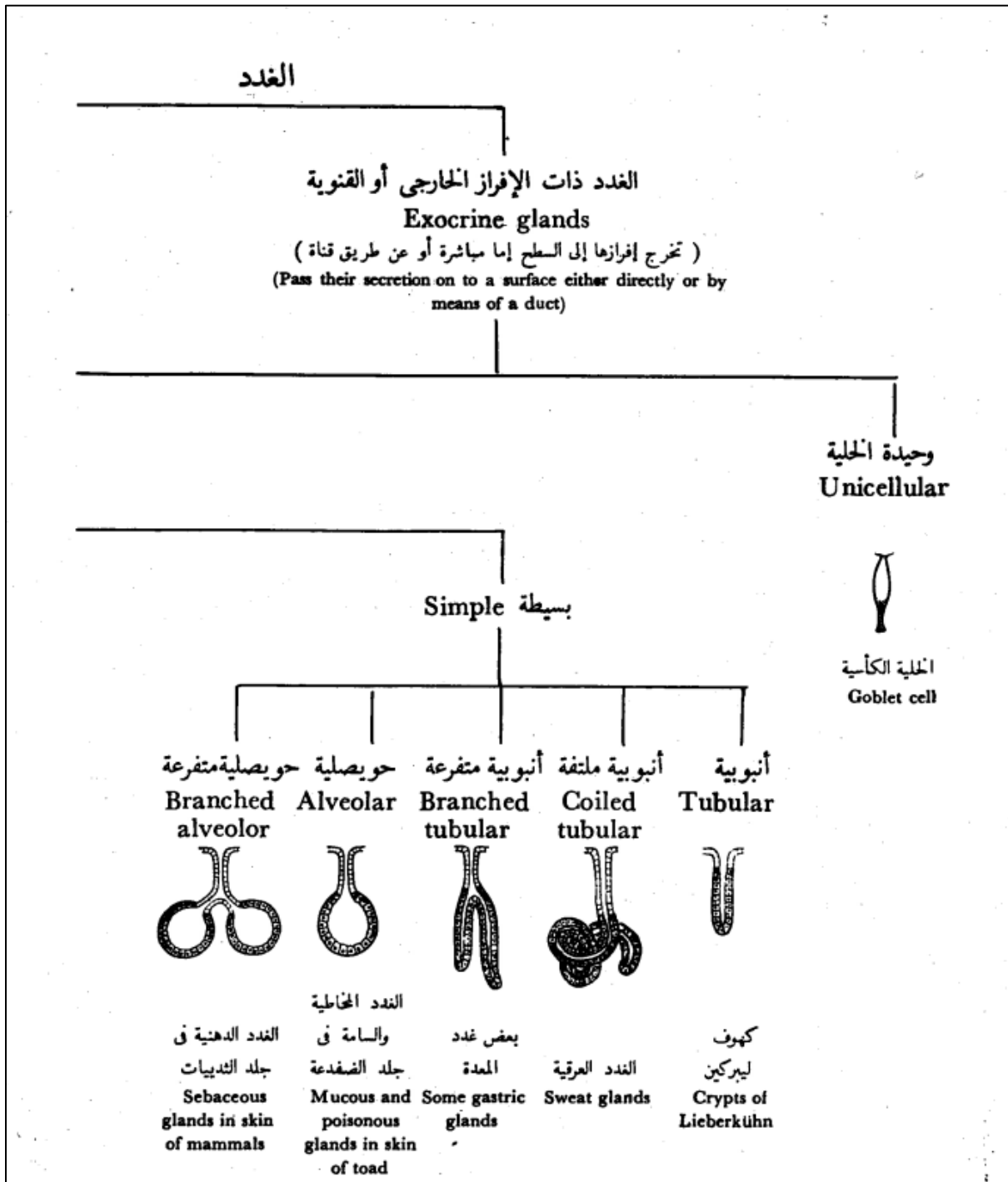




Draw



# Glandular epithelium




# The Glands

الغدد ذات الإفراز الداخلي أو الصم  
**Endocrine or ductless glands**  
 (تخرج إفرازها إلى الدم أو اللمف مباشرة)  
 (Pass their secretion directly into the blood or lymph)  
 مثل الكظر  
 e.g. Adrenal gland

Multicellular عديدة الخلايا

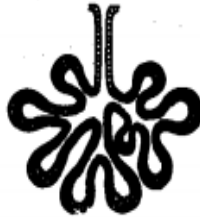Compound مركبة

شبكة  
**Reticular**



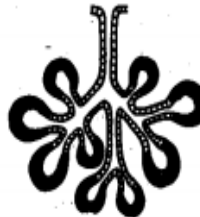كبد الثدييات  
**Liver of mammals**

أنبوبية حويصلية  
**Tubulo-alveolar**



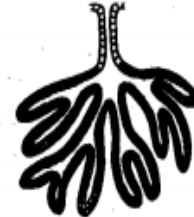البنكرياس والغدد  
 اللبنية  
**Pancreas and  
 mammary glands**

حويصلية  
**Alveolar**



الغدة العابية  
**Parotid salivary  
 gland**

أنبوبية  
**Tubular**



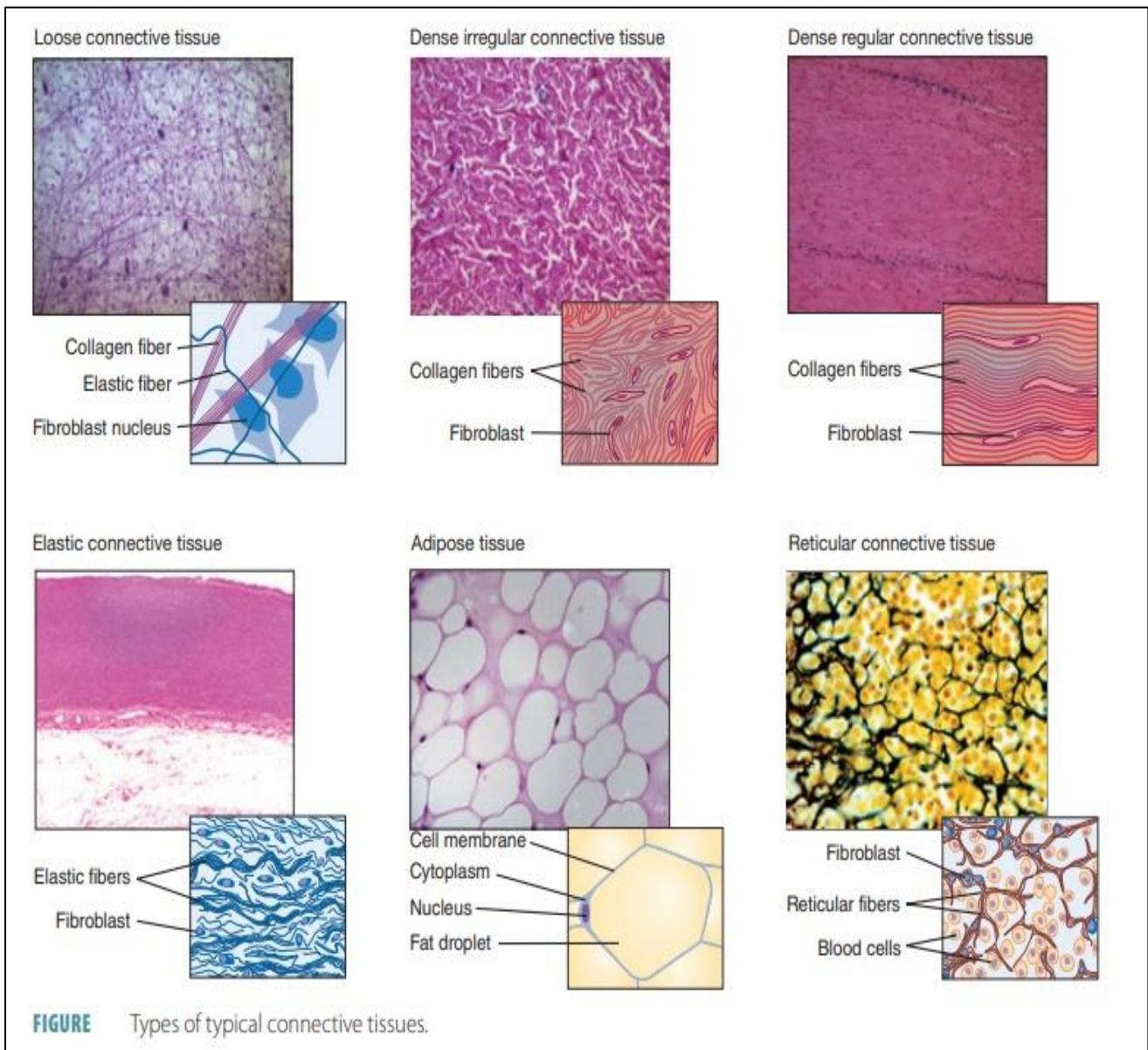
الغدة النعمية  
**Lacrymal gland**

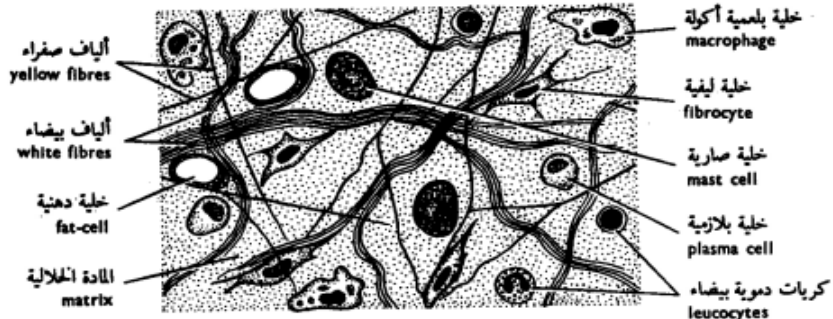
## 2. Connective Tissue

### Types of Connective tissue

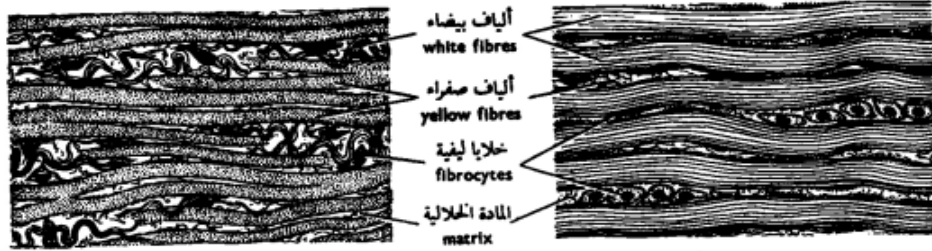
#### A-Loose (ordinary or areolar) connective tissue

1. Dense irregular connective tissue
2. Dense regular connective tissue
3. Dense regular elastic (Elastic ligaments)
4. Reticular connective tissue
5. Adipose tissue



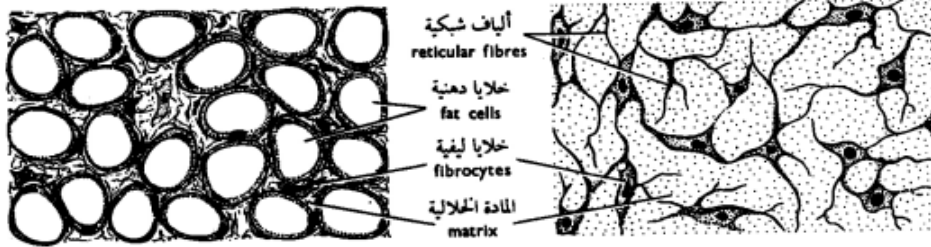


نسيج ضام فجوى  
 Areolar connective tissue  
 (من الطبقة تحت الجلد From subcutaneous layer)



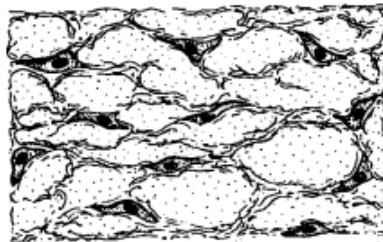
نسيج ضام مرن  
 Elastic connective tissue  
 (ق . ط . من الرباط القفوي L.S. of ligamentum nuchae)

نسيج ضام ليفي  
 Fibrous connective tissue  
 (قطع طول من وتر L.S. of tendon)



نسيج ضام دهني  
 Adipose connective tissue  
 (قطع من الجسم الدهني S. of Fat-body)

نسيج ضام شبكي  
 Reticular connective tissue  
 (قطع من غدة لمفية S. of lymph gland)



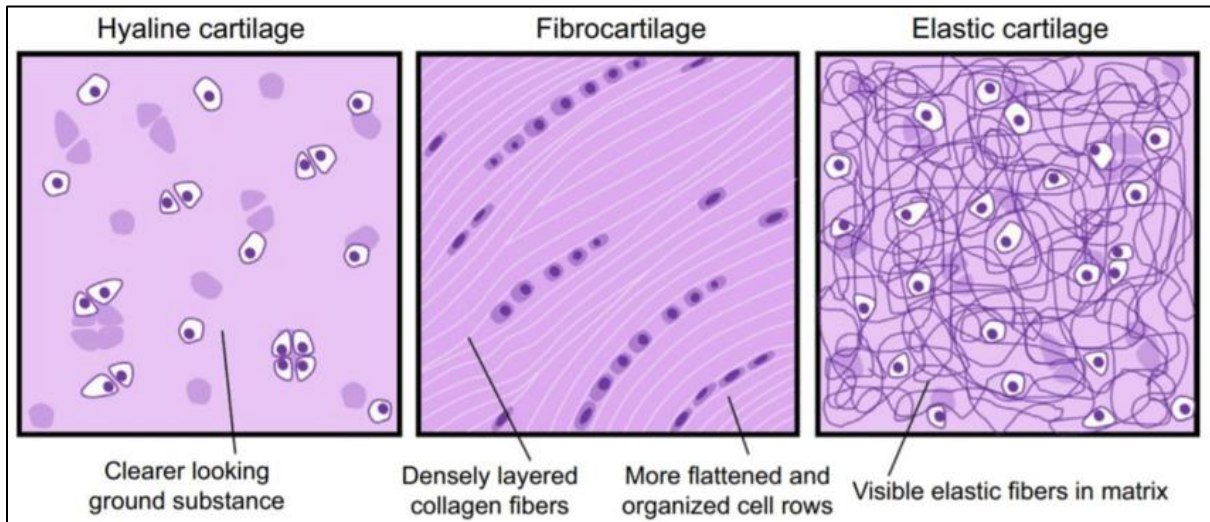
نسيج ضام مخاطي  
 Mucous connective tissue  
 (ق . ع . من الحبل السري T.S. of umbilical cord)

شكل ٣٩ - الأنسجة الضامة الأصيلة  
 FIG. 39 - CONNECTIVE TISSUES PROPER

## B-Skeletal Connective tissue (Cartilage& Bone)

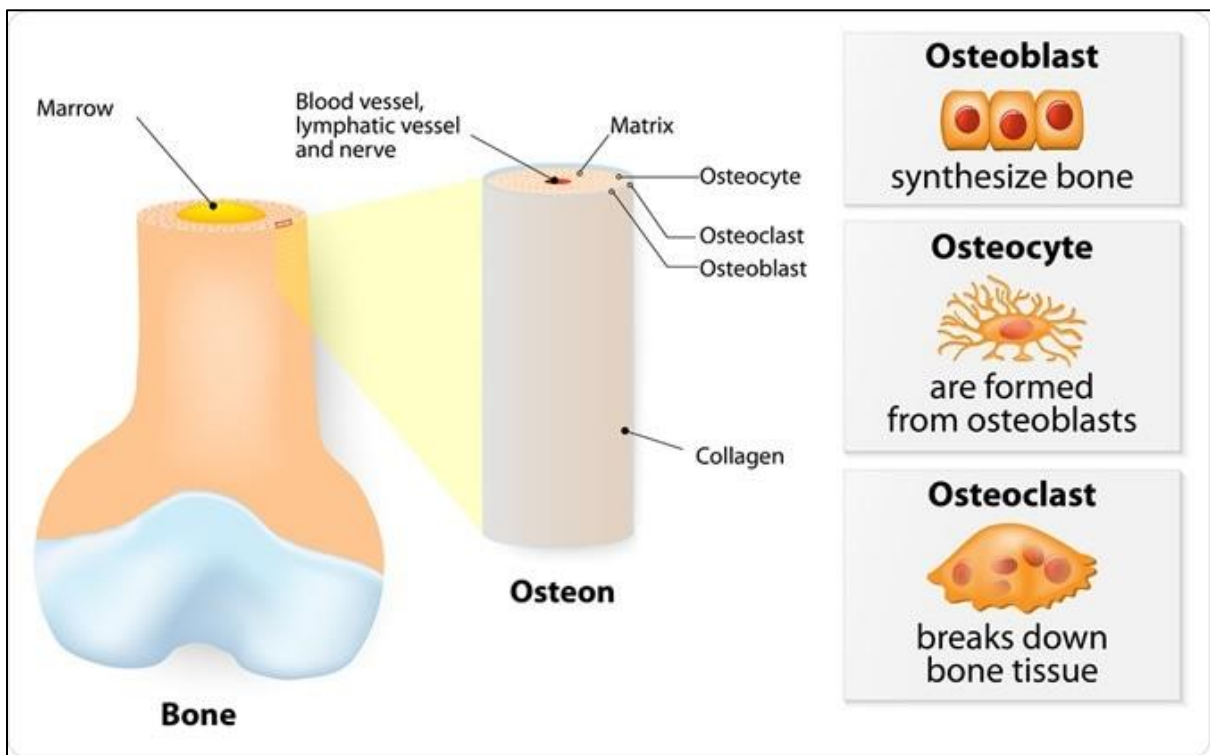
### 1- Cartilage

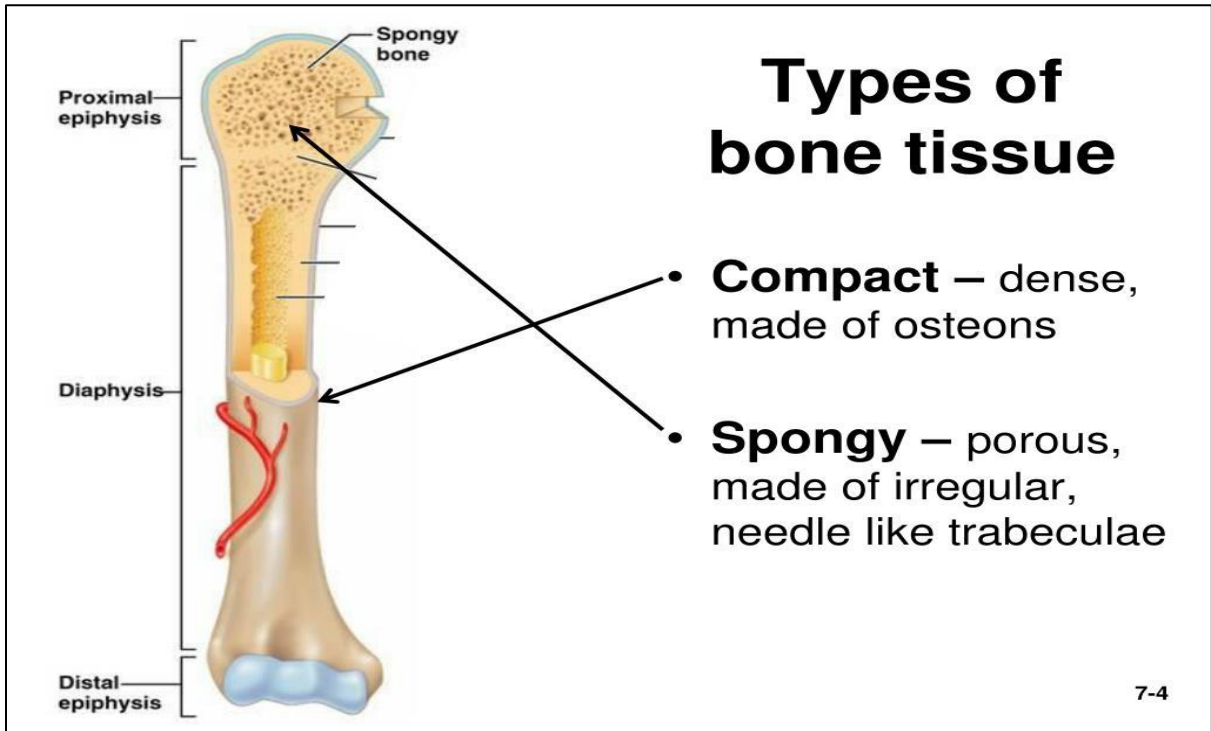
- ✓ Hyaline cartilage
- ✓ Elastic cartilage
- ✓ Fibrocartilage



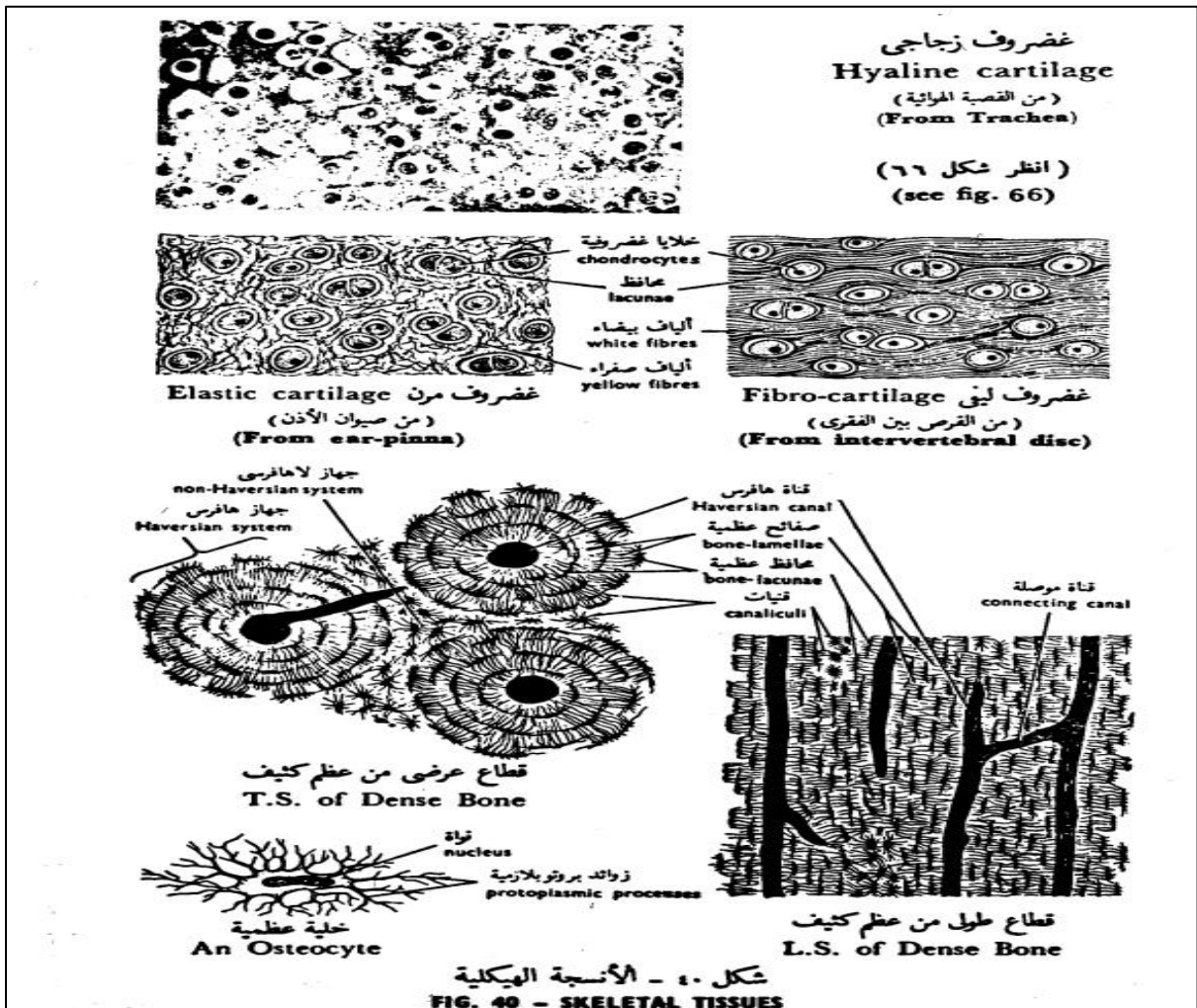
### 2- Bone

- ✓ Compact bone
- ✓ Cancellous or spongy bone



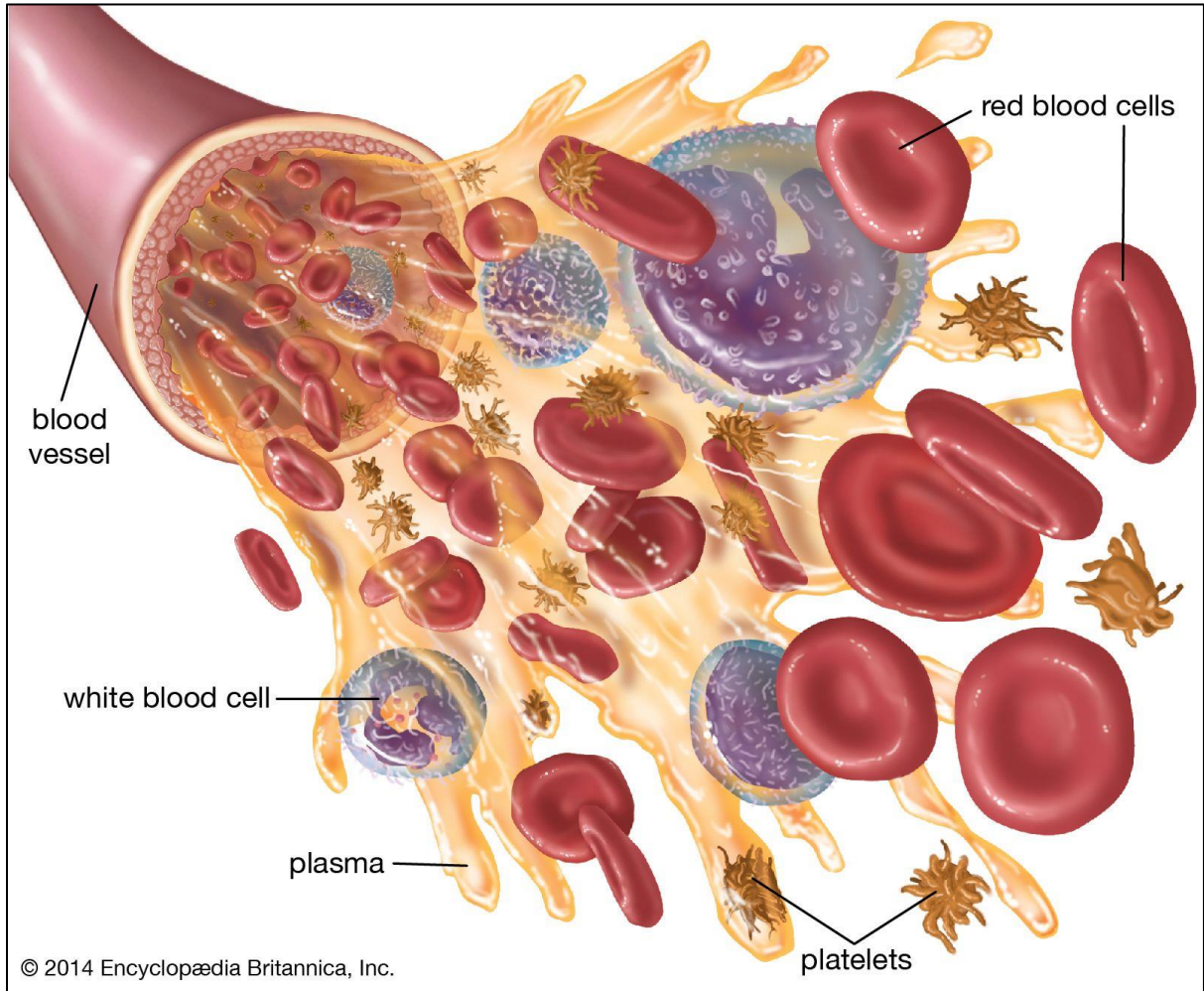


Draw

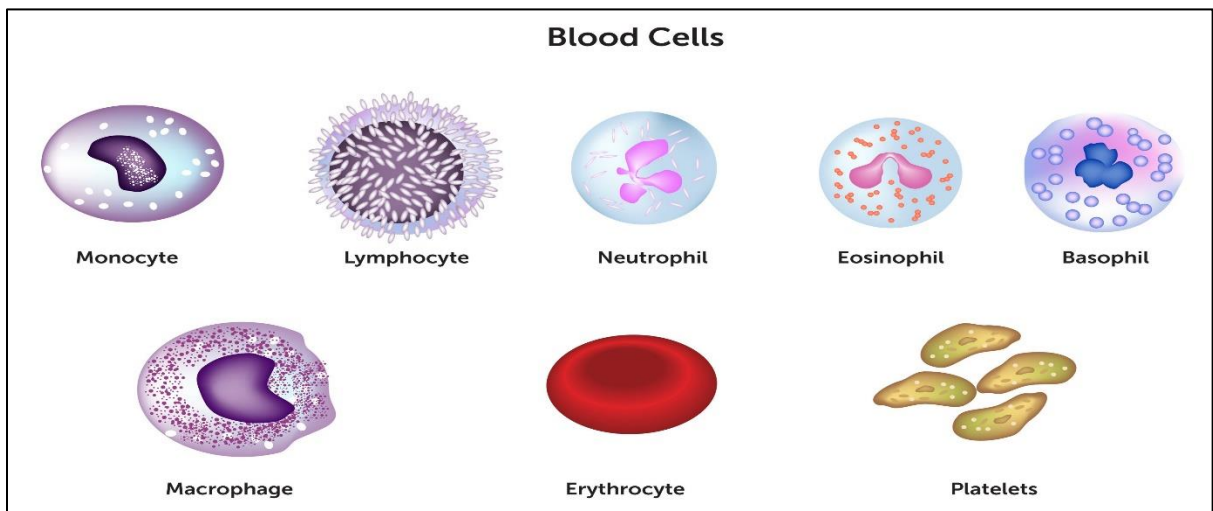


# C-Vascular connective tissue (Blood& Lymph)

## Blood

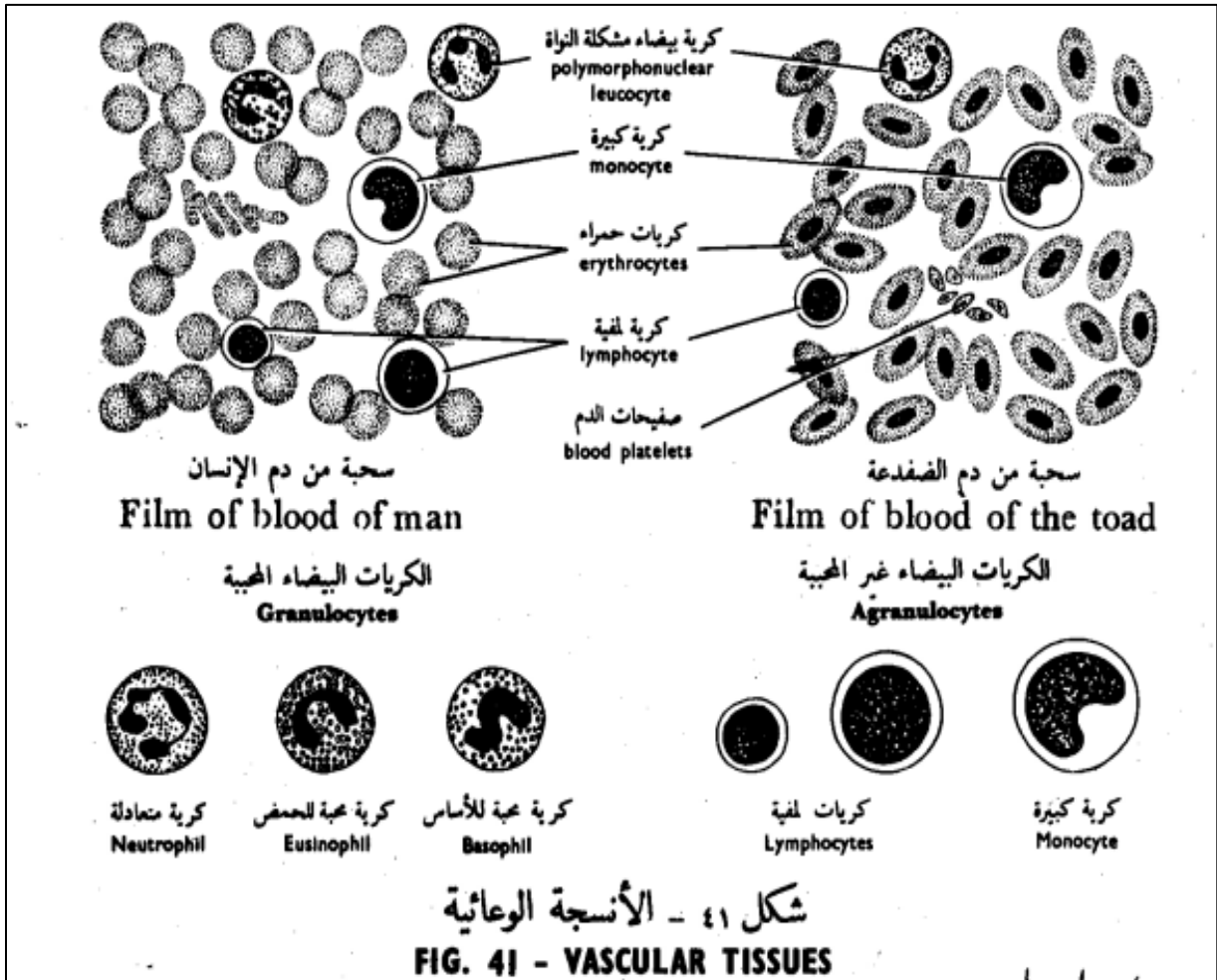


The blood cells are grouped into three main categories: red blood cells (erythrocytes), white blood cells (leukocytes) and blood platelets (thrombocytes).





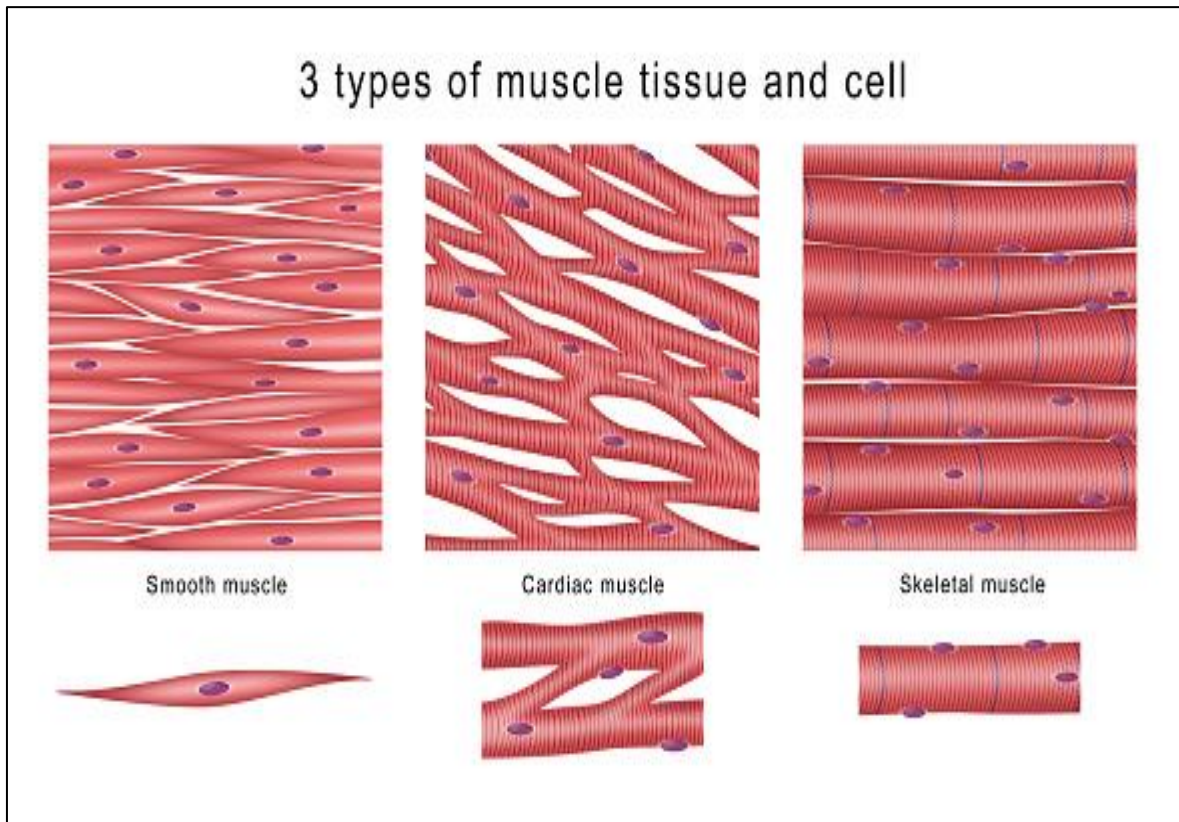
Draw



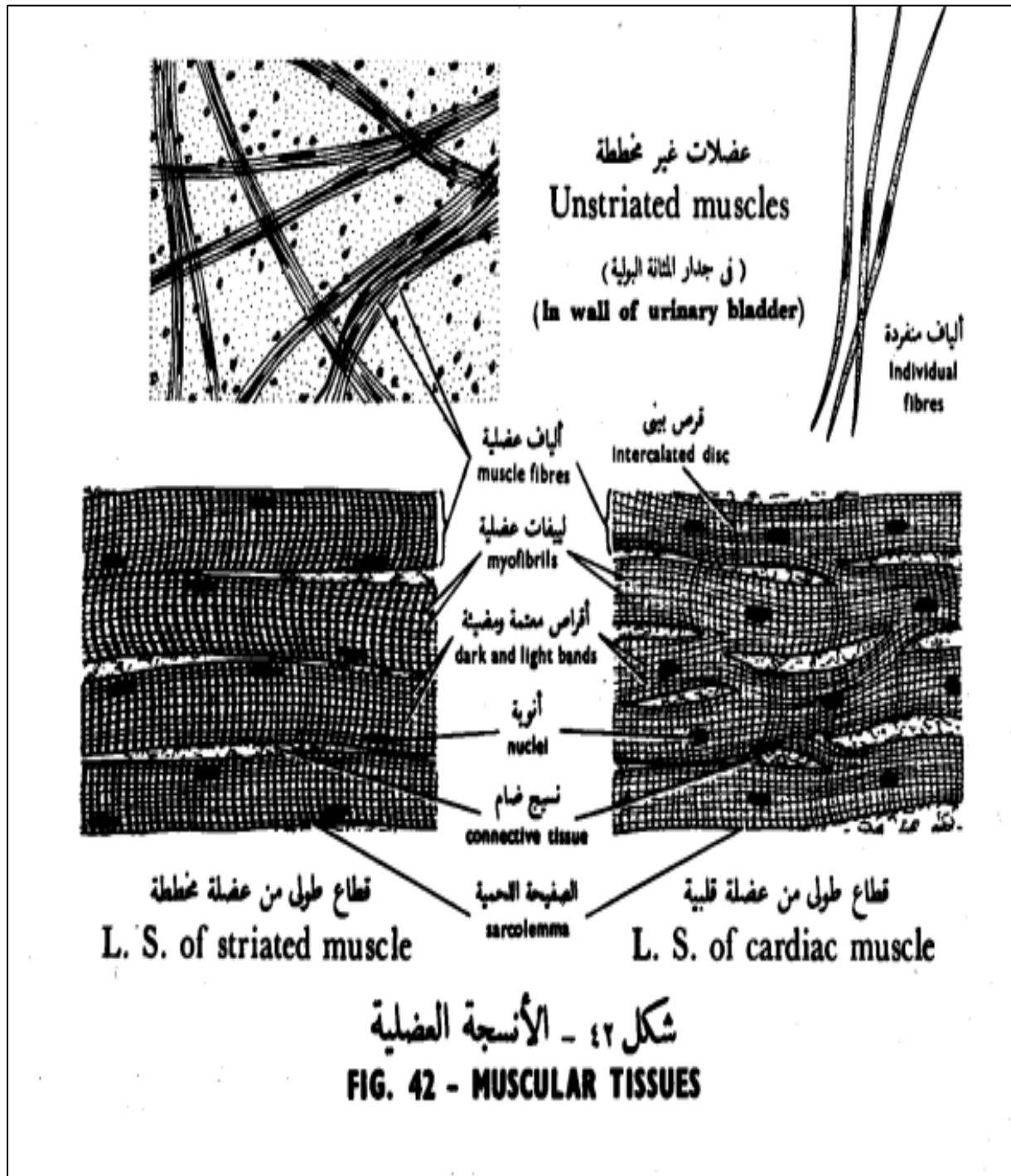
### 3- Muscular tissue

It is one of the four basic types of tissues primarily responsible for locomotion and movement of the various body parts.

- ✓ Skeletal muscle (Striated and voluntary myofibers)
- ✓ Cardiac muscle (Striated and involuntary)
- ✓ Smooth muscle (Visceral muscle)



Draw

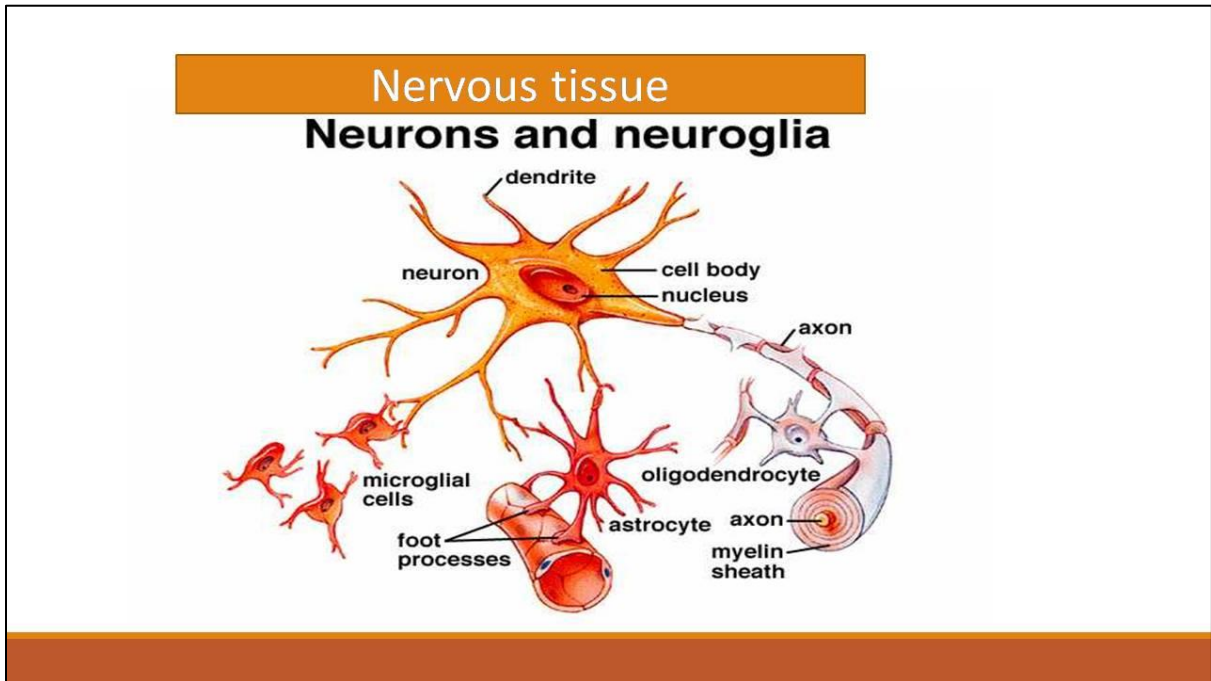


## 4- Nervous tissue

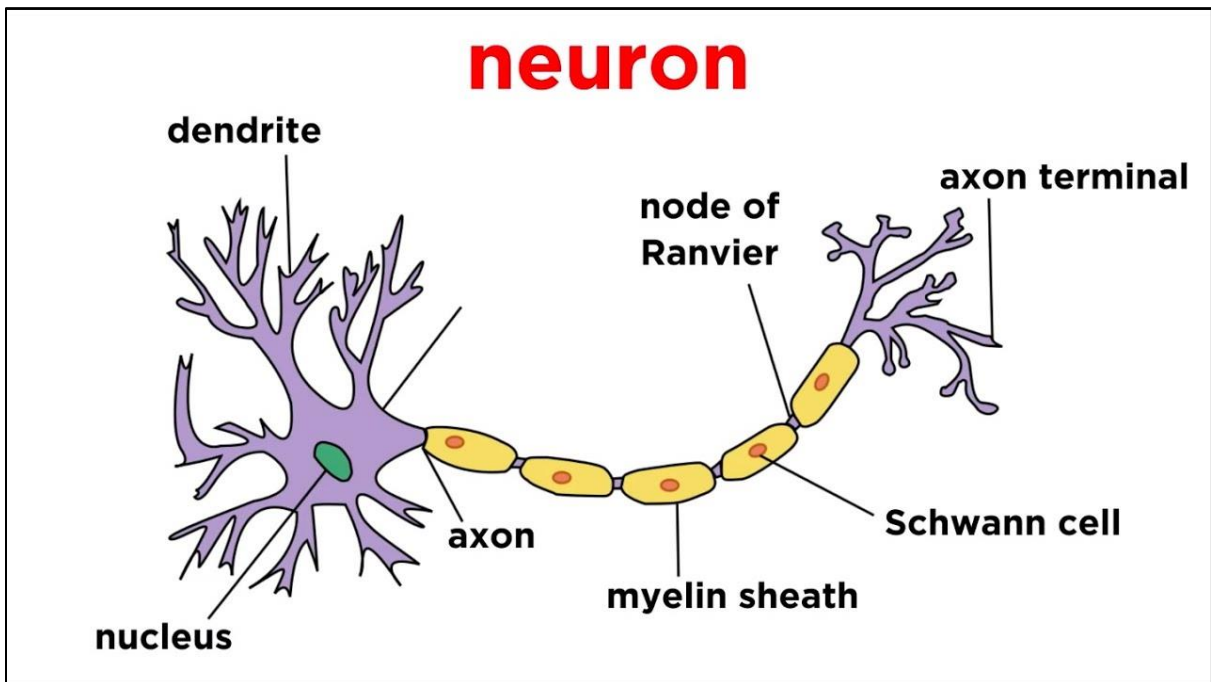
It is one of the four primary basic tissues.

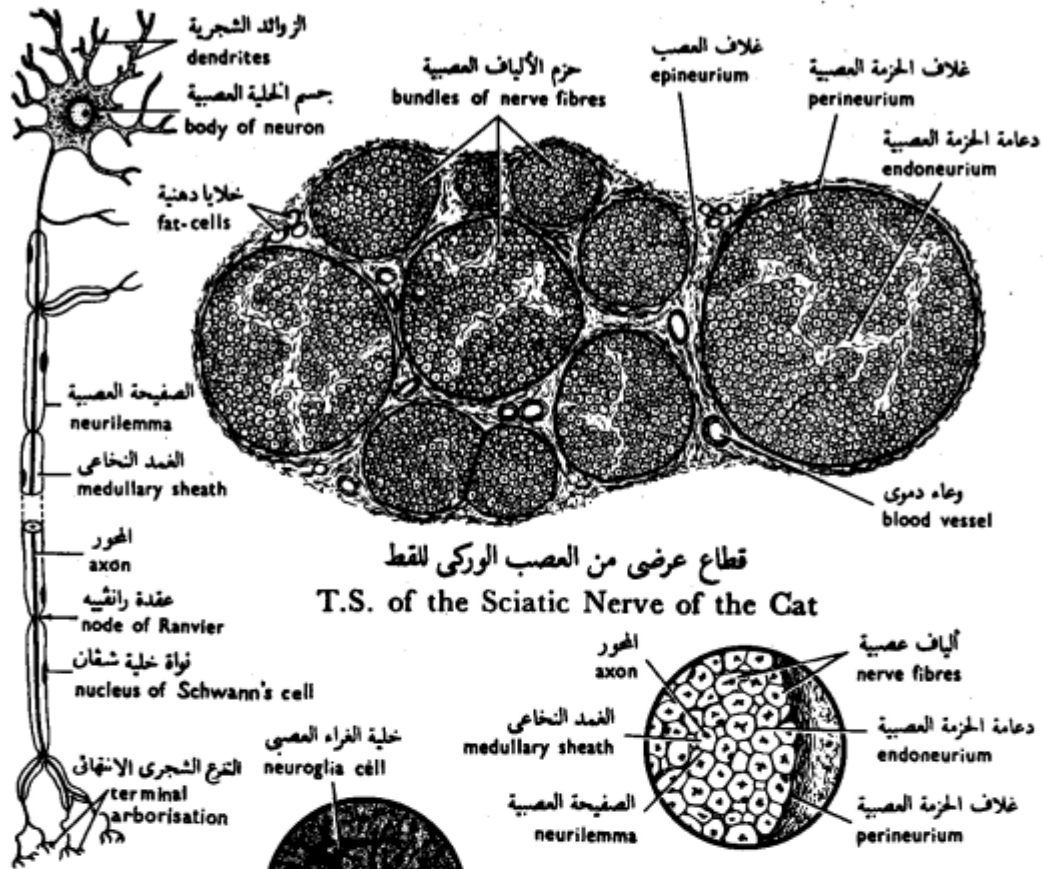
It consists of two types of cells:

- ✓ Neurons (nerve cells)
- ✓ Neuroglia (supporting cells).



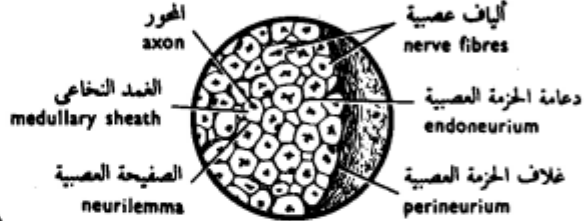
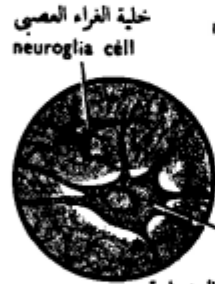
**Draw**





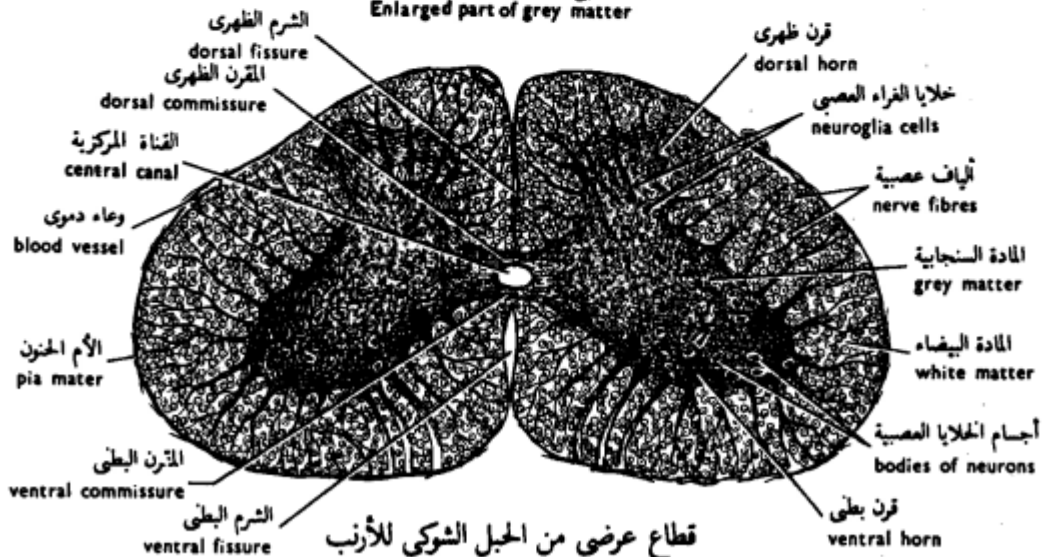
قطاع عرضي من العصب الوركي للقط  
 T.S. of the Sciatic Nerve of the Cat

خلية عصبية حركية  
 Motor Neuron



جزء مكبر من حزمة الألياف العصبية  
 Enlarged part of nerve bundle

جسم الخلية العصبية  
 body of neuron  
 جزء مكبر من المادة السنجابية  
 Enlarged part of grey matter



قطاع عرضي من الحبل الشوكي للأرنب  
 T.S. of the Spinal Cord of the Rabbit

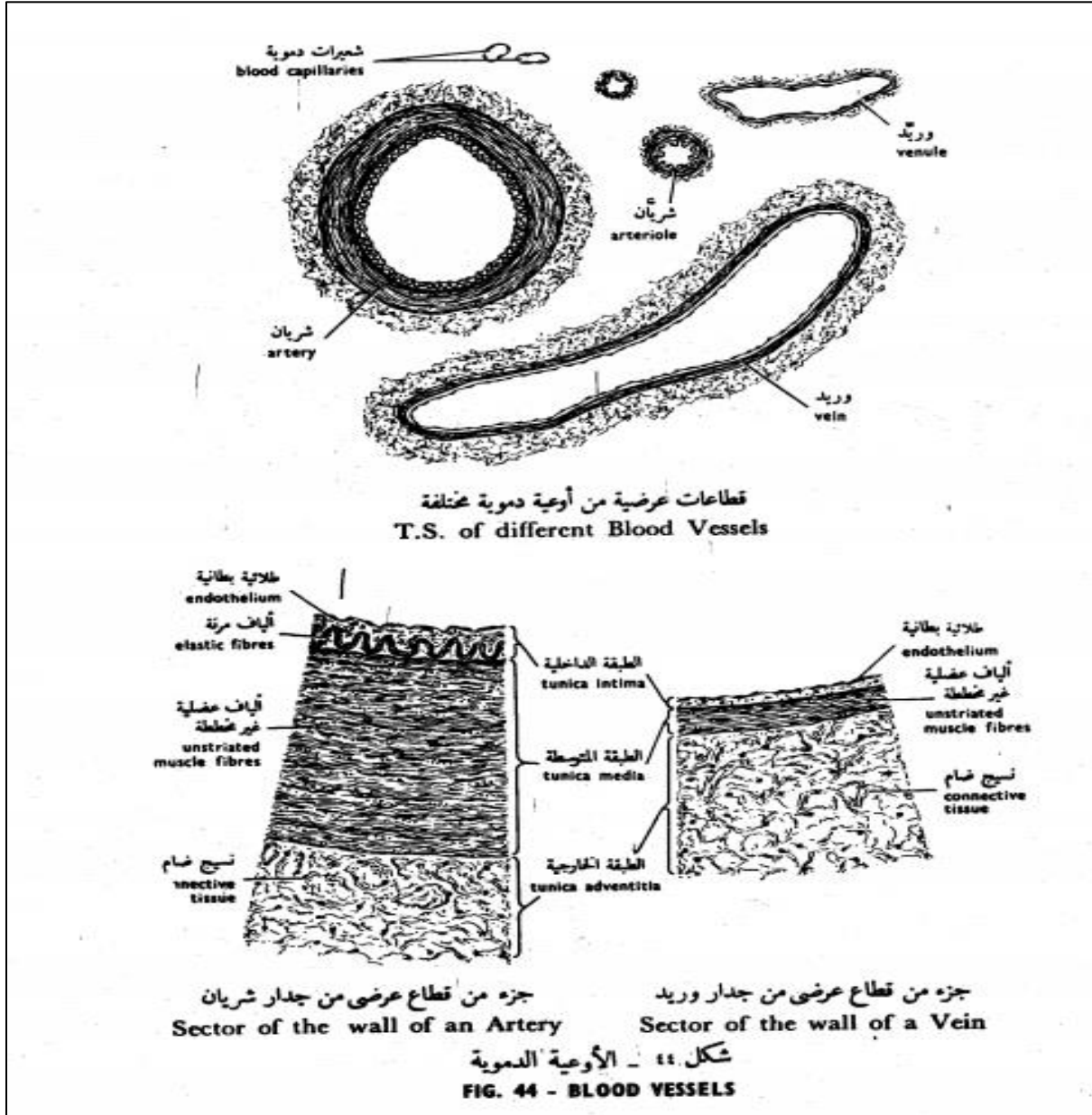
شكل ٤٣ - الأنسجة العصبية

FIG. 43 - NERVOUS TISSUES

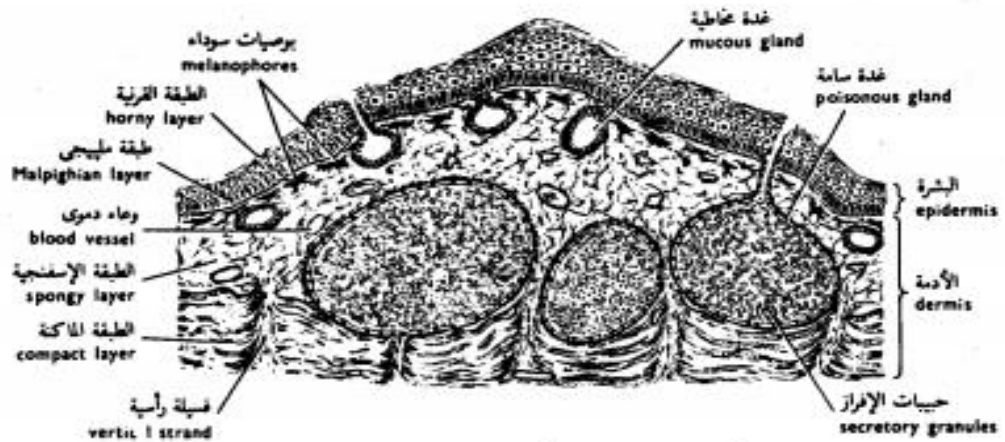
# The Organs

Write the types of tissues in the following organs?

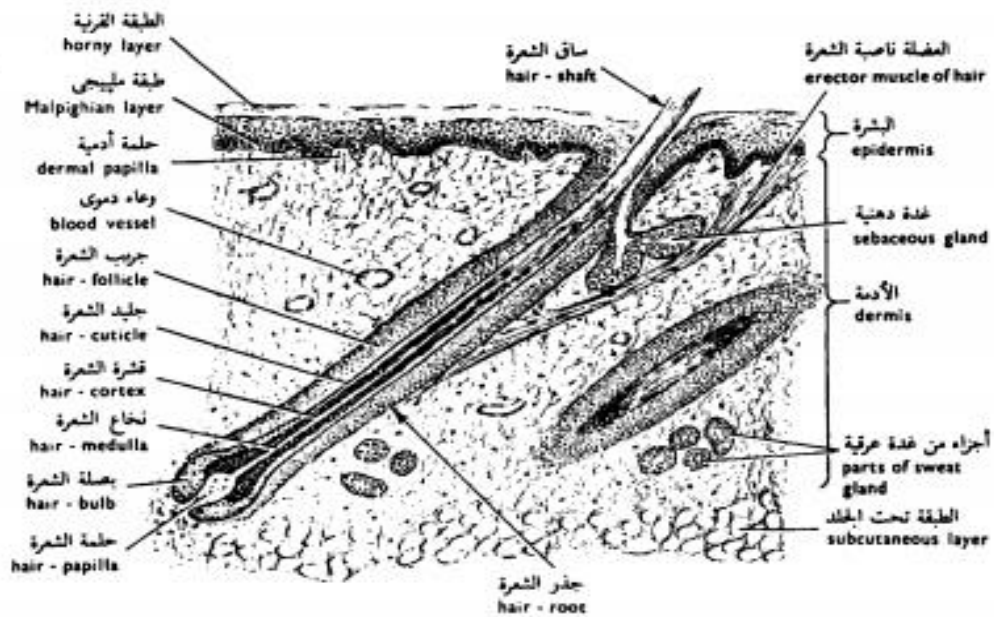
Blood vessels



# Skin

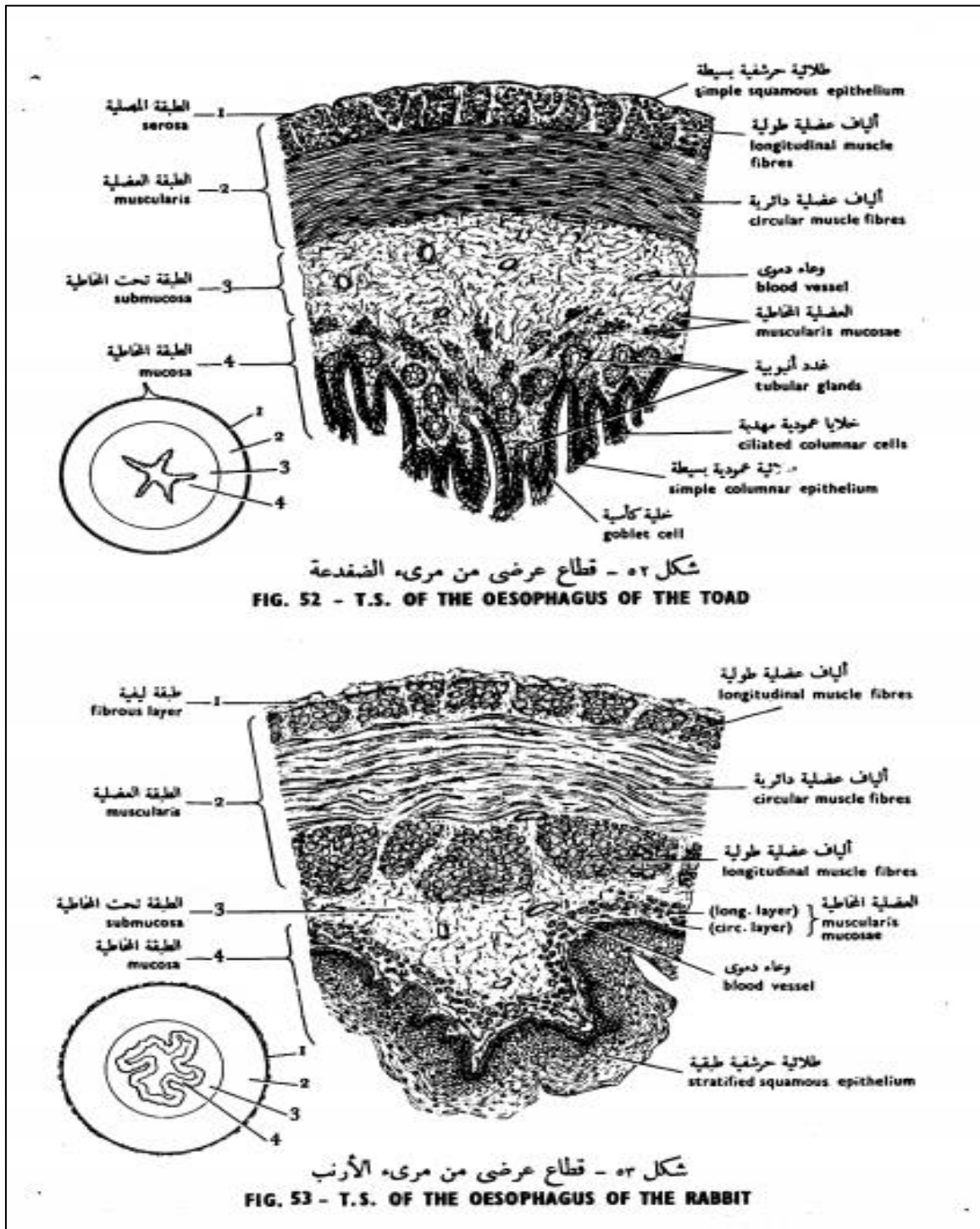


شكل ٤٥ - قطاع رأسي من جلد الضفدعة  
 FIG. 45 - V.S. OF THE SKIN OF THE TOAD

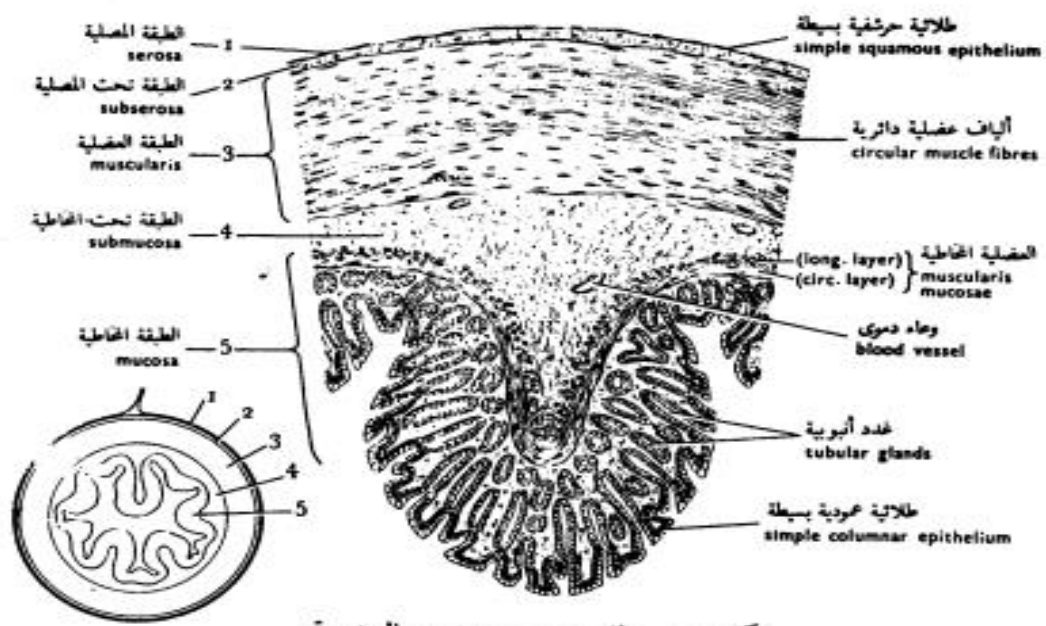


شكل ٤٦ - قطاع رأسي من جلد الخنزير  
 FIG. 46 - V.S. OF THE SKIN OF THE PIG

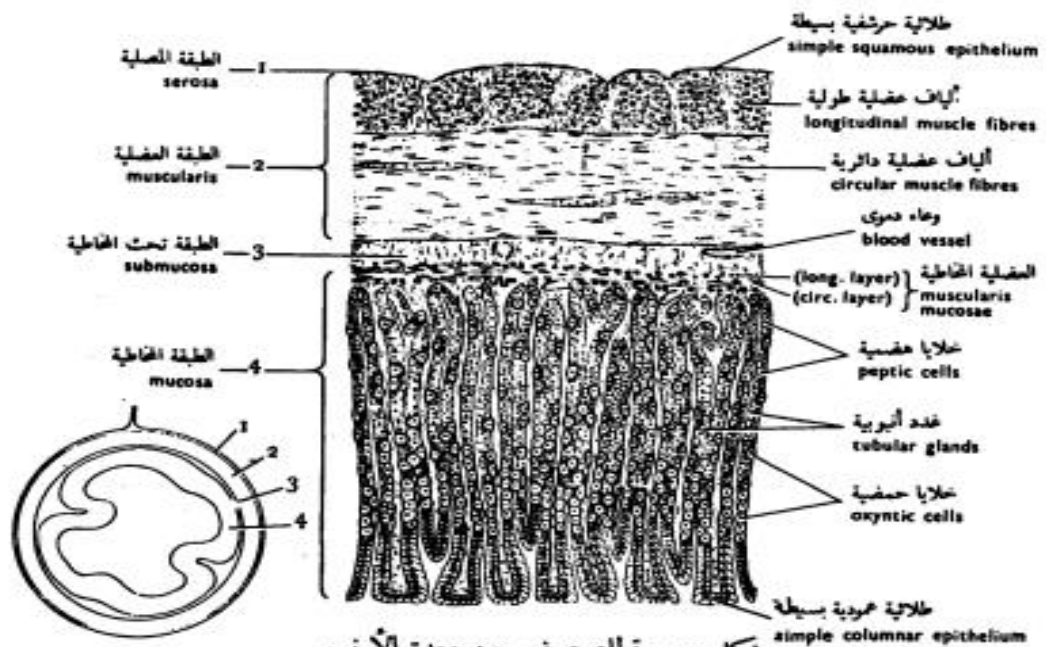
# Digestive tract



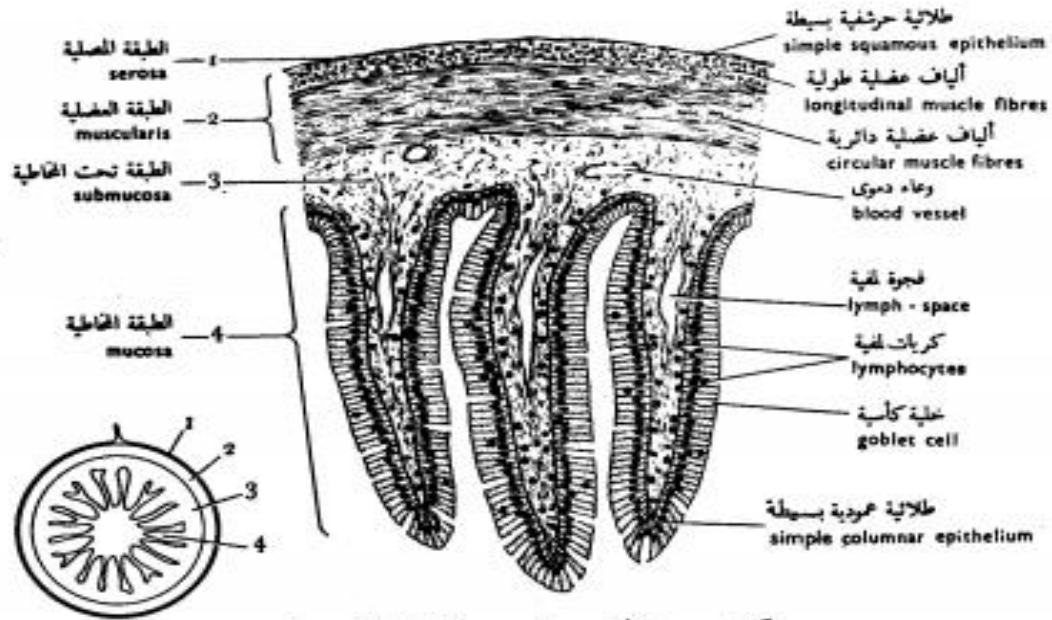




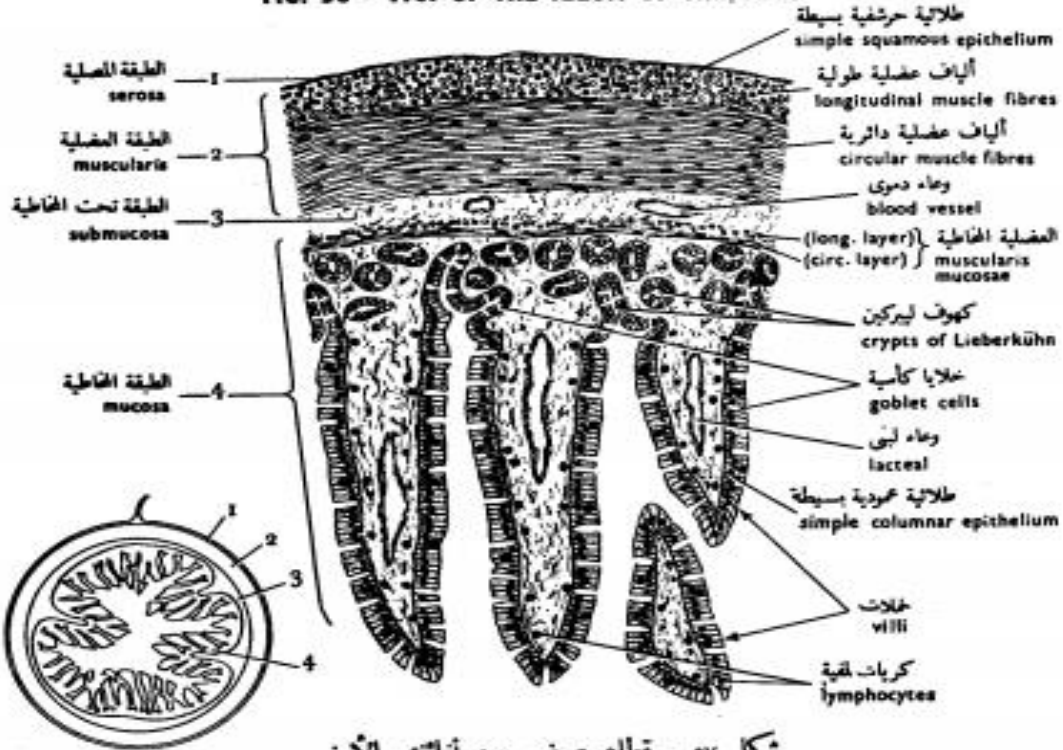
شكل ٥٤ - قطاع عرضي من معدة الضفدعة  
 FIG. 54 - T.S. OF THE STOMACH OF THE TOAD



شكل ٥٥ - قطاع عرضي من معدة الأرنب  
 FIG. 55 - T.S. OF THE STOMACH OF THE RABBIT



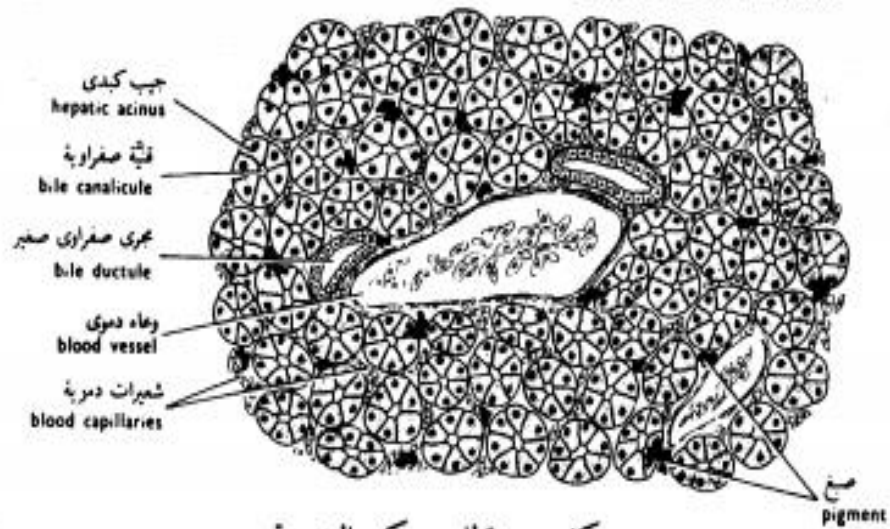
شكل ٥٦ - قطاع عرضي من لفائف الضفدعة  
 FIG. 56 - T.S. OF THE ILEUM OF THE TOAD



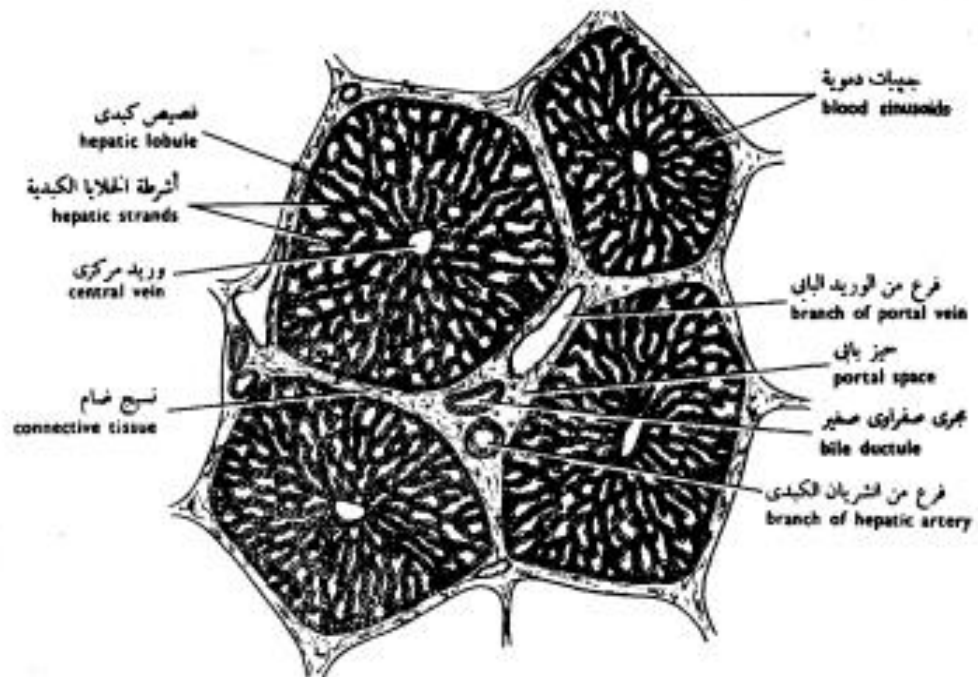
شكل ٥٧ - قطاع عرضي من لفائف الأرنب  
 FIG. 57 - T.S. OF THE ILEUM OF THE RABBIT

# Liver

## of the Toad's Liver

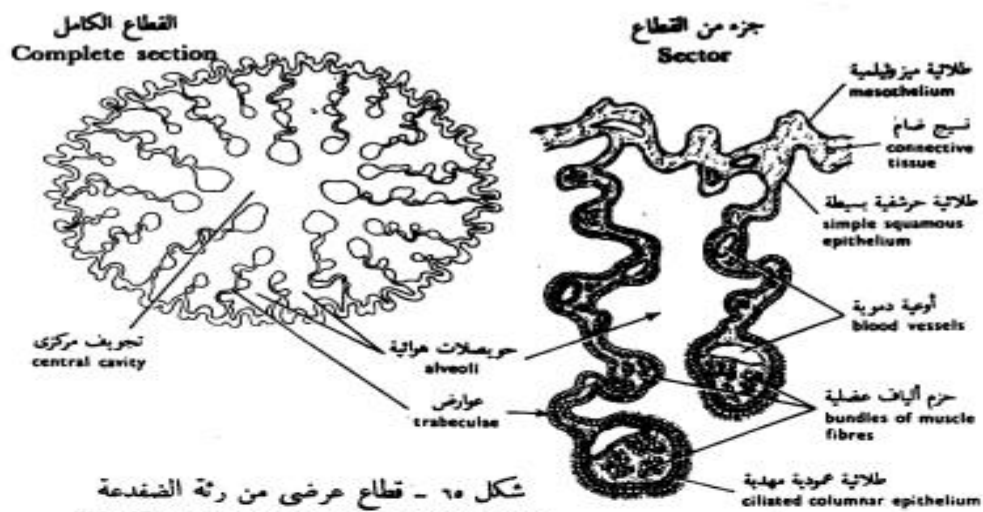


شكل ٥٩ - قطاع من كبد الضفدعة  
 FIG. 59 - S. OF THE LIVER OF OF THE TOAD

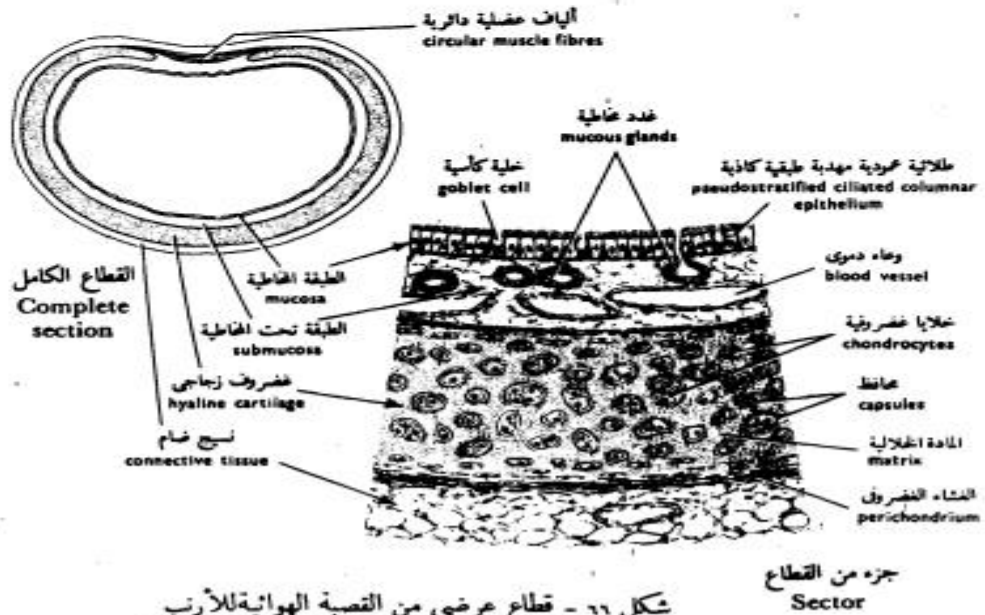


شكل ٦٠ - قطاع من كبد الخنزير  
 FIG. 60 - S. OF THE LIVER OF THE PIG



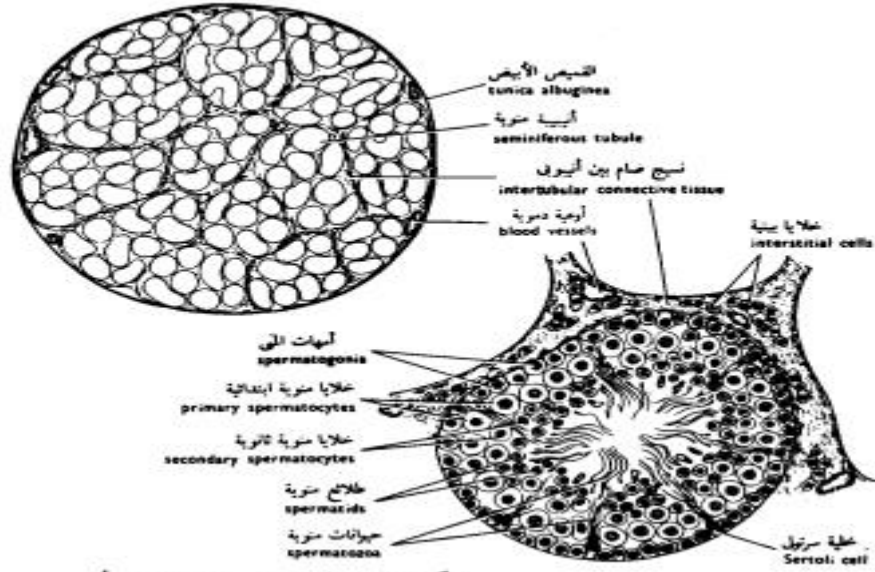


شكل ٦٥ - قِطَاعُ عَرْضِيٍّ مِنْ رِئَةِ الضَّفَدَةِ  
FIG. 65 - T.S. OF THE LUNG OF THE TOAD

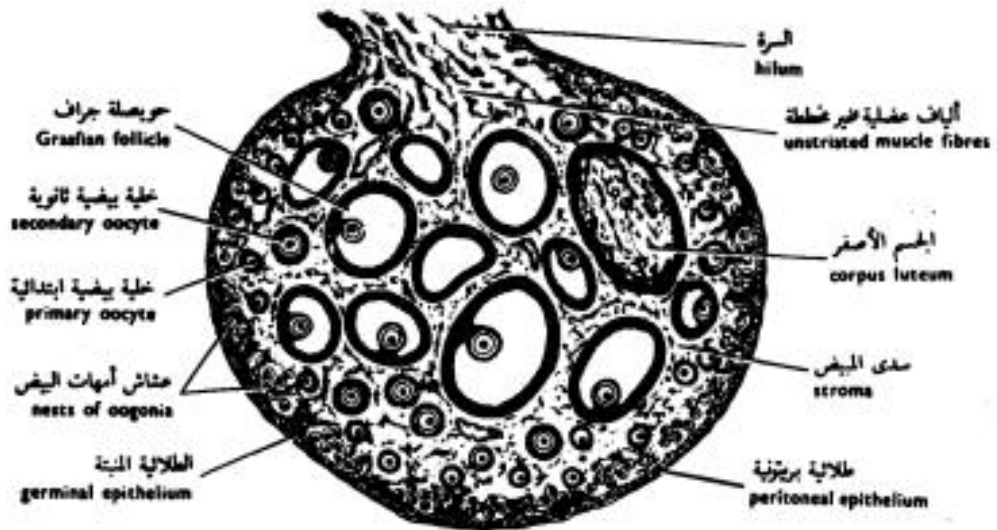


شكل ٦٦ - قِطَاعُ عَرْضِيٍّ مِنْ التَّصْبَةِ الهوائية لِلرَّابِطِ  
FIG. 66 - T.S. OF THE TRACHEA OF THE RABBIT

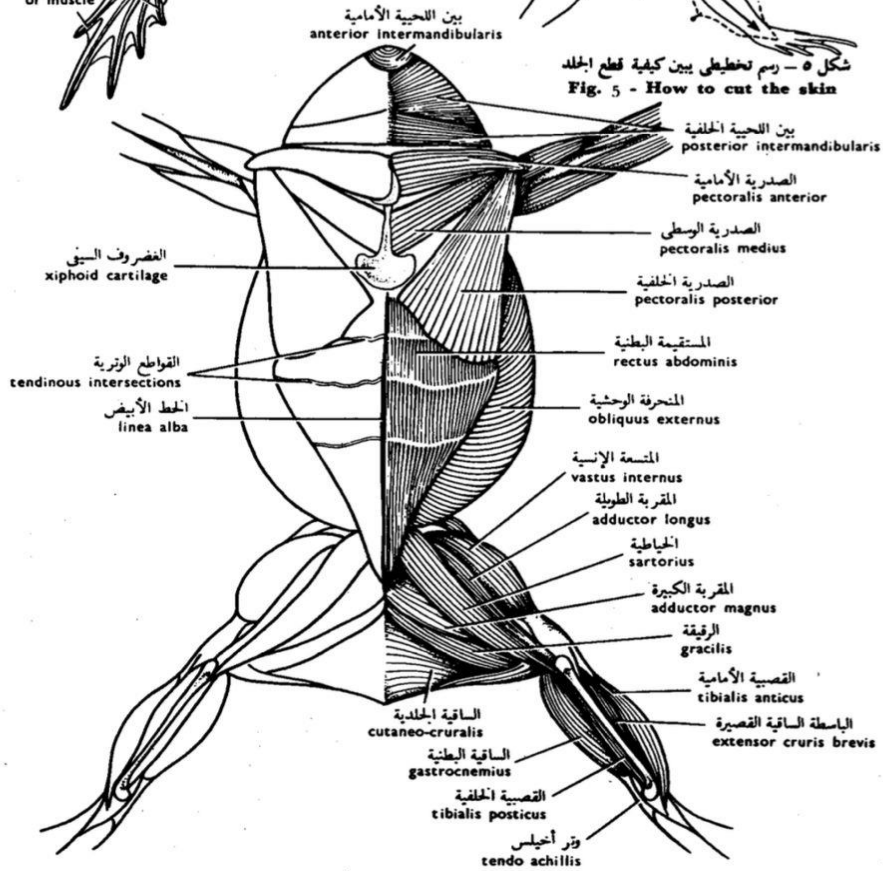
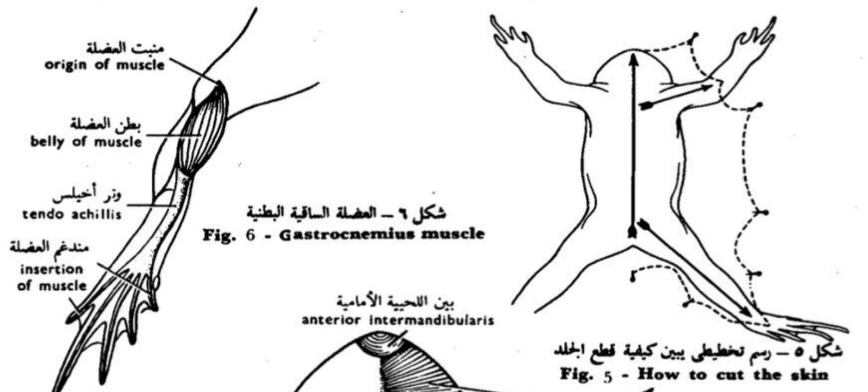# Testis and Ovary



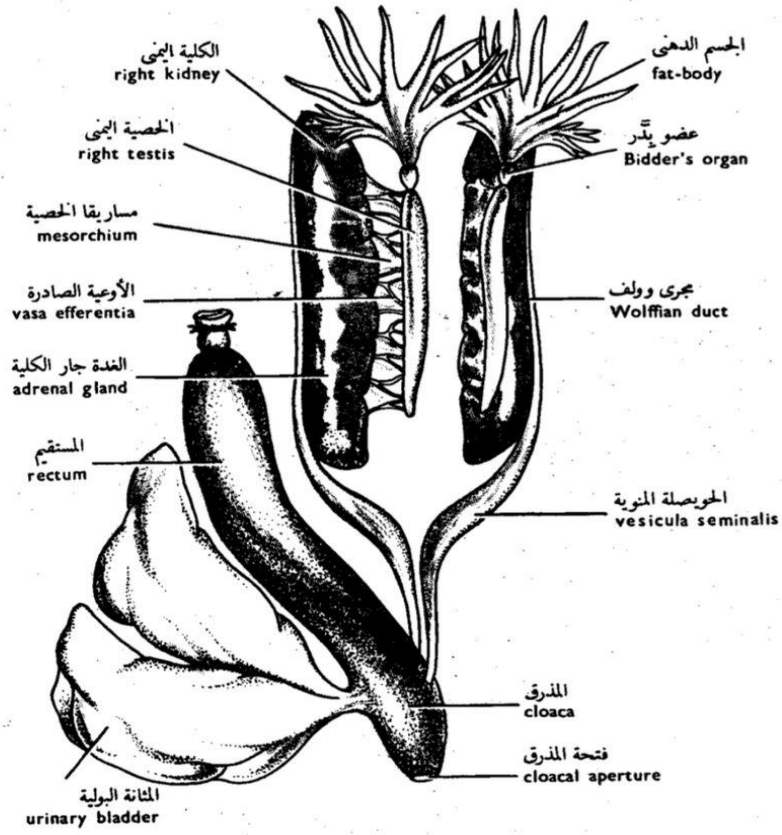
شكل ٦٧ - قطاع عرضي من خصية الفأر  
FIG. 67 - T.S. OF THE TESTIS OF THE RAT



شكل ٧١ - قطاع عرضي من مبيض القطاة  
FIG. 71 - T.S. OF THE OVARY OF THE CAT

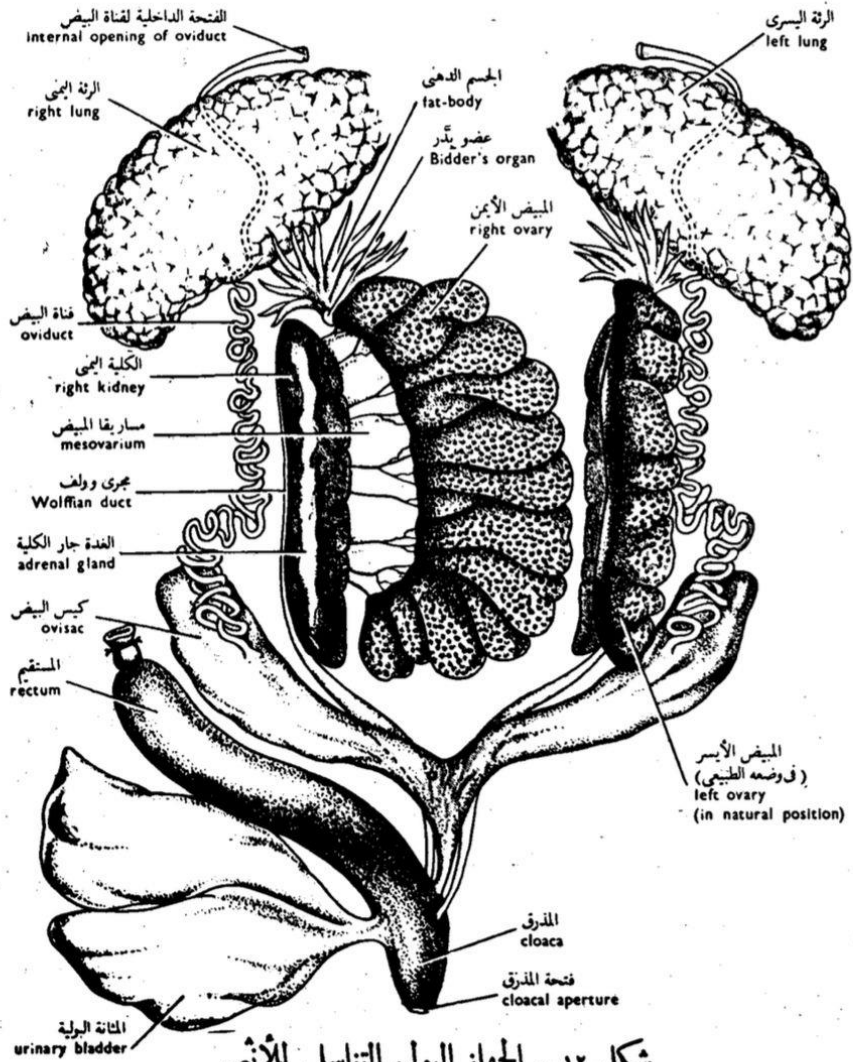


شكل ٧ - العضلات البطنية السطحية  
 FIG. 7 - VENTRAL SUPERFICIAL MUSCLES



شكل ١١ - الجهاز البولي التناسلي للذكر  
**FIG. II - MALE URINOGENITAL SYSTEM**





شكل ١٢ - الجهاز البولي التناسلي للإنثى  
**FIG. 12 - FEMALE URINOGENITAL SYSTEM**  
 (وقد أبعده الجانبان ككل عن الآخر)  
 (the two sides have been separated)

