



Zoology I

(Code: Zoo 101)

Theoretical

Prepared by

Dr/ Rana Abdelstar

Dr/ Zienab Kamal

Dr/ Gihan Hassan

First semester


2024-2025

رؤية كلية العلوم



التميز في تعليم العلوم الأساسية والبحث العلمي للمساهمة في التنمية المستدامة.

رسالة كلية العلوم



تقديم تعليم مميز في مجالات العلوم الأساسية وإنتاج بحوث علمية تطبيقية للمساهمة في التنمية المستدامة من خلال إعداد خريجين متميزين طبقا للمعايير الأكاديمية القومية، وتطوير مهارات وقدرات الموارد البشرية، وتوفير خدمات مجتمعية وبيئية تلبي طموحات مجتمع جنوب الوادي، وبناء الشراكات المجتمعية الفاعلة.

رؤية قسم علم الحيوان

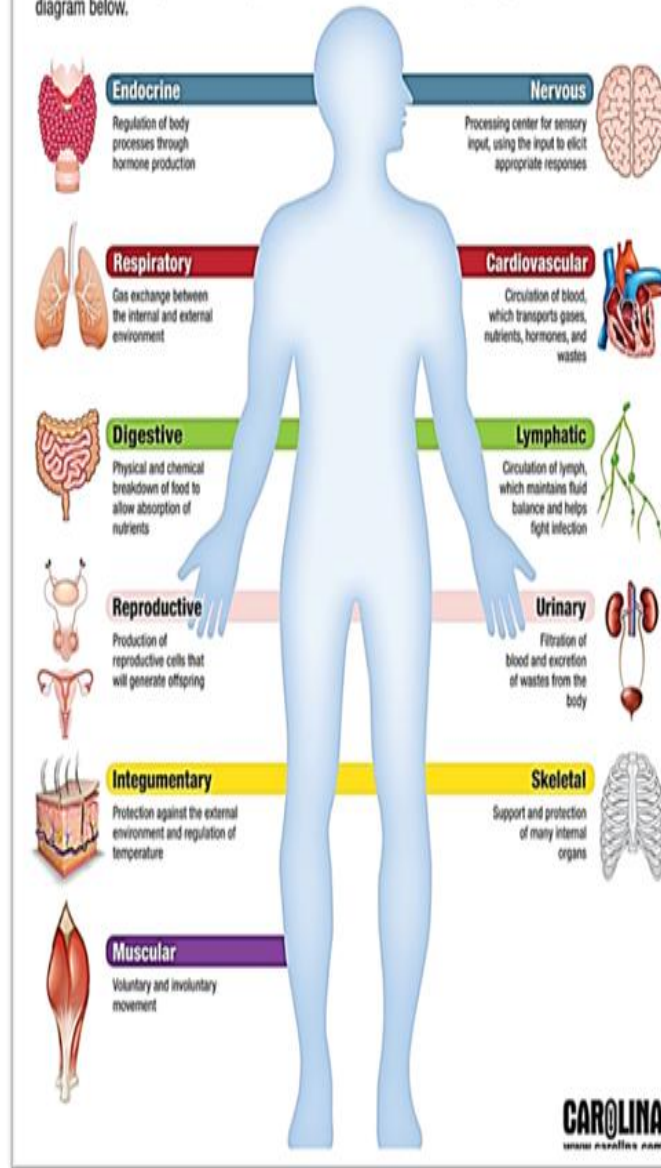
خريجون متميزون علميا وبحثيا محليا ودوليا خدمة للمجتمع وتنمية للبيئة.

رسالة قسم علم الحيوان

يسعى قسم علم الحيوان بكلية العلوم من خلال ما يقدمه من برامج تعليمية متطورة وبحث علمي تطبيقي عالمي وبنية اساسية مناسبة الى خريجين متميزين محليا ودوليا في مجالات علوم البيولوجيا ينتفع بهم المجتمع وسوق العمل.

Human Body Systems

There are 11 main systems that keep our bodies functioning. Learn the primary roles of each in the diagram below.



Physiology part

Physiology content:

- An introduction of general physiology.
- Nutrition and Digestion.
- Absorption.
- Metabolism.
- Excretion.
- Respiration.
- Circulation system, Blood and Lymph.
- Reproductive system.
- Nervous System.
- Endocrine System and hormone's function.

Physiology and life processes

Physiology tells us how our bodies work structurally and functionally.

The most important life processes of human:

Metabolism: includes catabolism and anabolism that provides energy and body components.

Excitability: ability to sense changes in and around us.

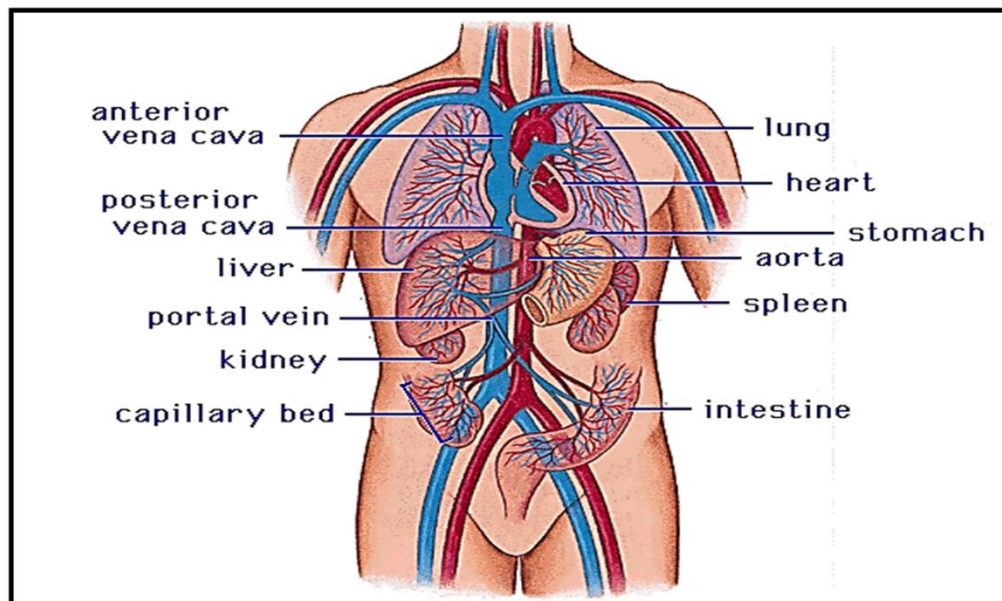
Conductivity: ability to carry the effects of stimulus from part of a cell to another.

Contractility: ability to contract in response to stimulus.

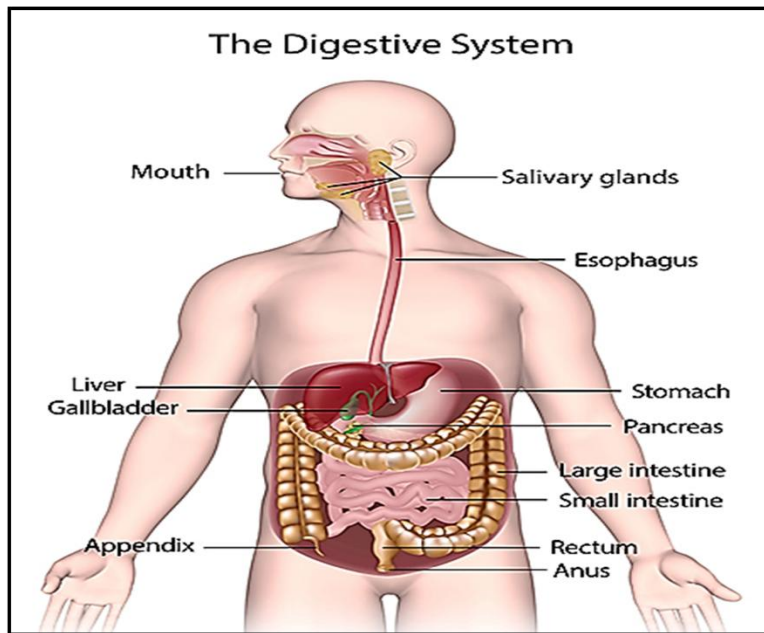
Growth

Reproduction

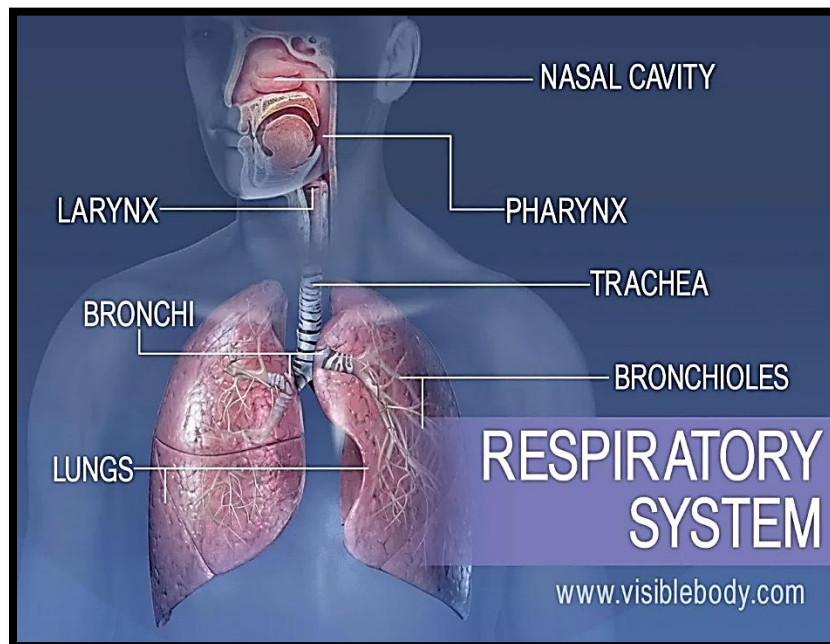
Components of body system



Circulatory system

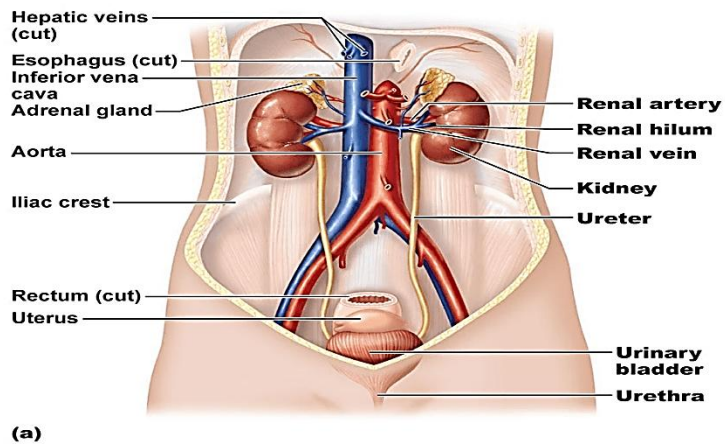


Digestive System



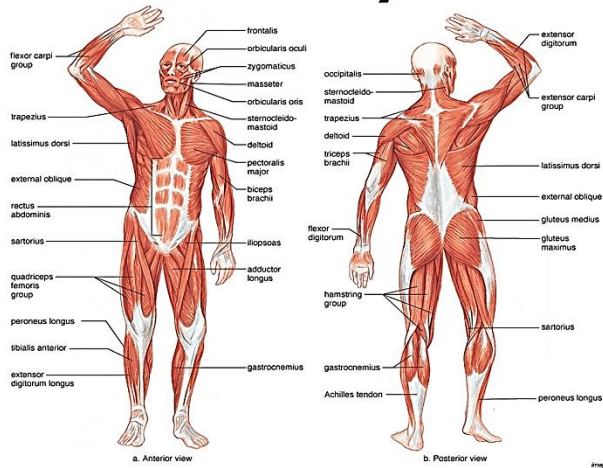
Respiratory system

Urinary System

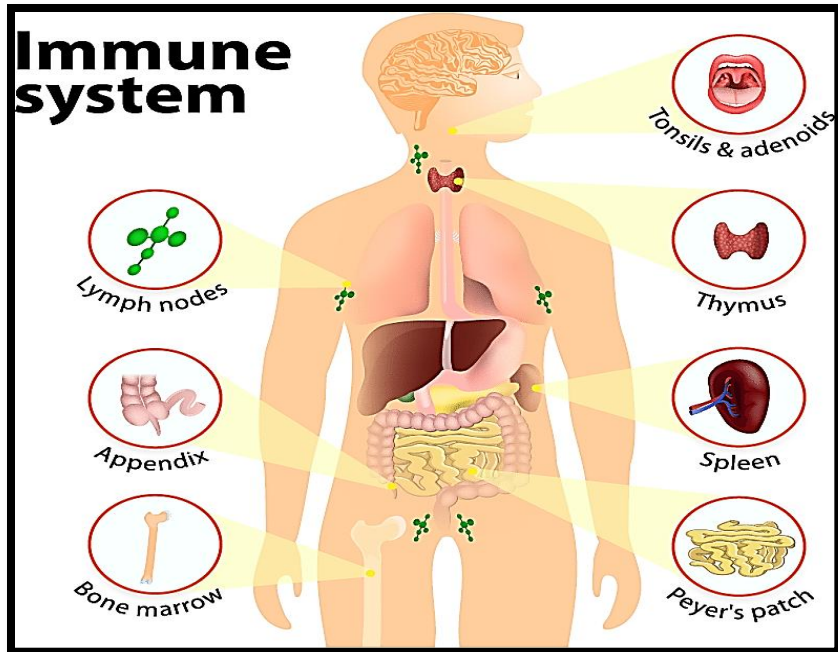


Urinary system

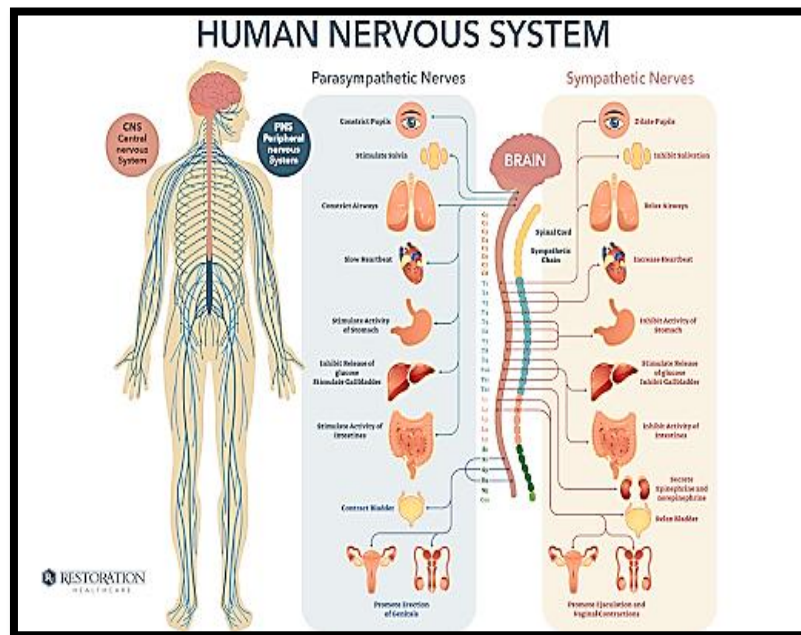
Muscular System



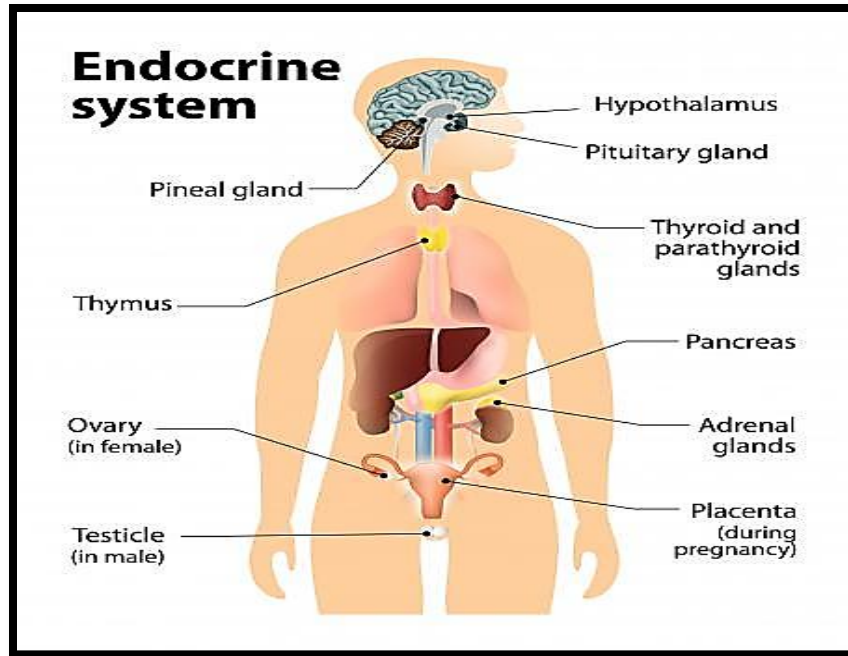
Muscular system



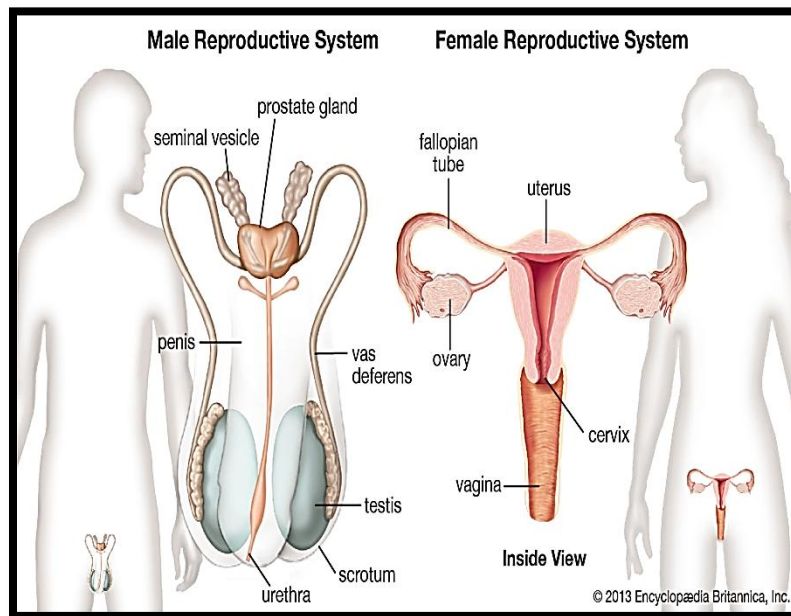
Immune system



Nervous system

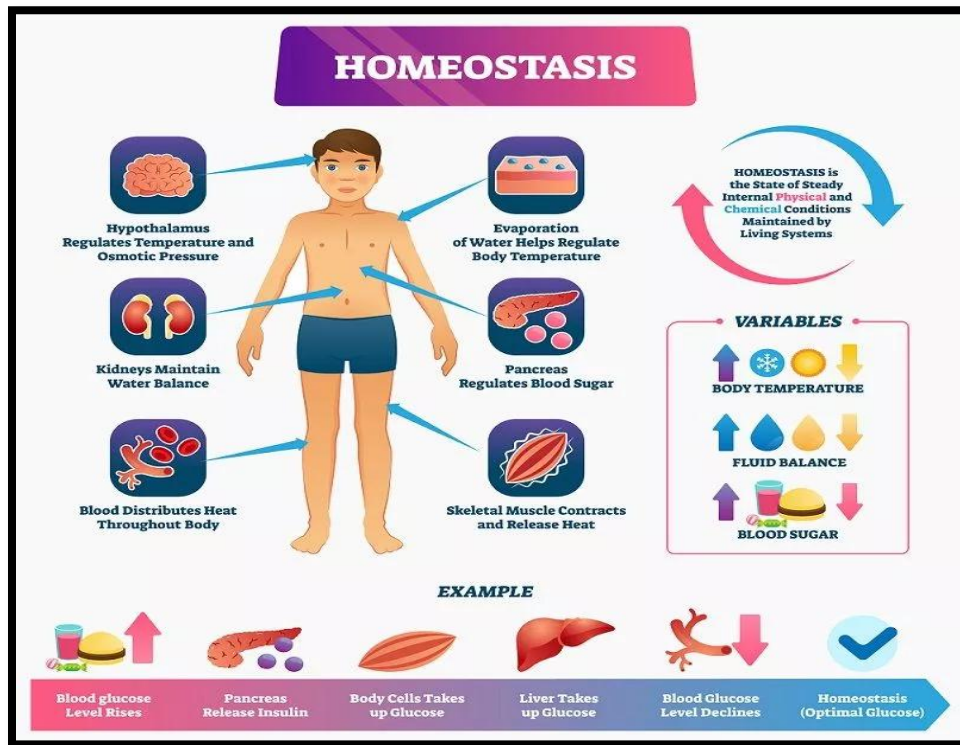


Endocrine system



Reproductive system

Homeostasis



Role of body system in maintaining homeostasis:

Nervous system:

Information from the external environment, also acts through electrical signals to control rapid responses for higher functions such as concentration, memory, and creativity.

Endocrine system:

Acts by hormones secreted into the blood to control processes that require duration rather than speed, such as metabolic activity, water and electrolytes balances.

Circulatory system:

Transports nutrients, oxygen, CO₂, wastes, electrolytes and hormones through the body.

Respiratory system:

Obtains oxygen and eliminates CO₂ to the external environment; helps regulate pH by adjusting the rate of removal of acid-forming carbon dioxide.

Urinary system:

Important in regulating the volume, electrolyte composition, and pH of the internal environment; removes waste and excess water, salt, acid and other electrolytes from the plasma and eliminate them into the urine.

Digestive system:

Obtains nutrients, water and electrolytes from the external environment and transfers them into the plasma; eliminates undigested food residues to the external environment.

Muscular and skeletal system:

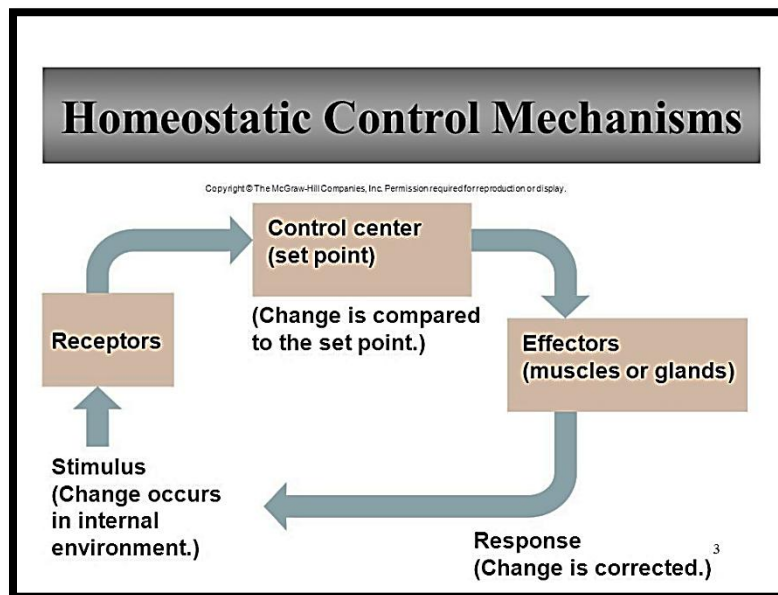
Supports and protects body parts and allows body movements, heat generated by muscular contraction are important in temperature regulation, calcium stored in the bones.

Immune system:

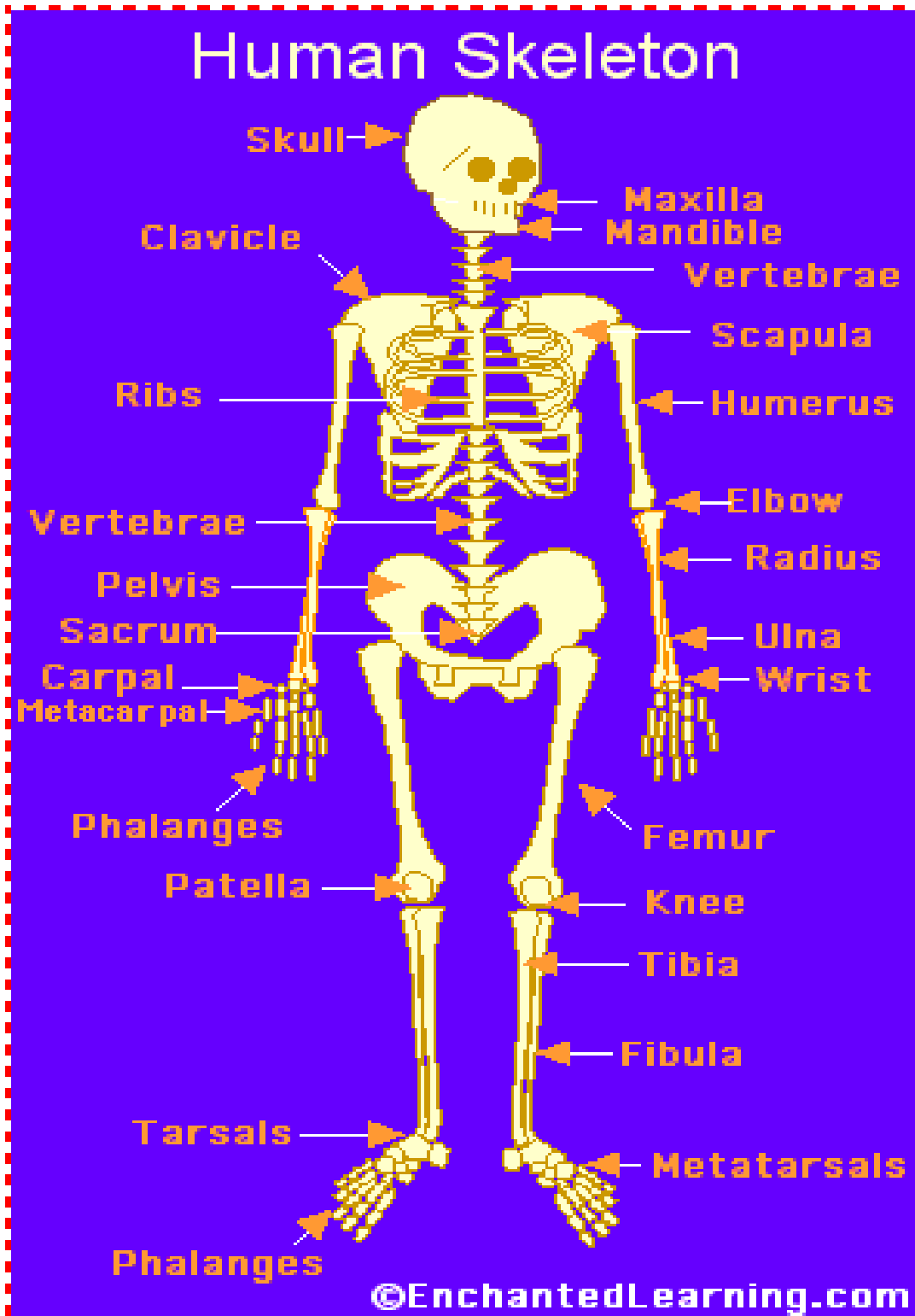
Defense against foreign invaders and cancer cells; tissue repair.

Integumentary system:

Keeps internal fluids in and foreign materials out serves as a protective barrier between the external environment and the remainder of the body; temperature regulation.



The skeletal system



The skeletal system is composed of bones and cartilage connected by ligaments to form a framework for the rest of the body tissues. There are two parts to the skeleton:

- **Axial skeleton** – bones along the axis of the body, including the skull, vertebral column and ribcage;
- **Appendicular skeleton** – appendages, such as the upper and lower limbs, pelvic girdle and shoulder girdle.

Function

As well as contributing to the body's overall shape, the skeletal system has several key functions, including:

- Support and movement;
- Protection;
- Mineral homeostasis;
- Blood-cell formation;
- Triglyceride storage.

Support and movement

Bones are a site of attachment for ligaments and tendons, providing a skeletal framework that can produce movement through the coordinated use of levers, muscles, tendons and ligaments. The bones act as levers, while the muscles generate the forces responsible for moving the bones.

Protection

Bones provide protective boundaries for soft organs: the cranium around the brain, the vertebral column surrounding the spinal cord, the ribcage containing the heart and lungs, and the pelvis protecting the urogenital organs.

Mineral homeostasis

As the main reservoirs for minerals in the body, bones contain approximately 99% of the body's calcium, 85% of its phosphate and 50% of its magnesium (Bartl and Bartl, 2017). They are essential in maintaining homeostasis of minerals in the blood with minerals stored in the bone are released in response to the body's demands, with levels maintained and regulated by hormones, such as parathyroid hormone.

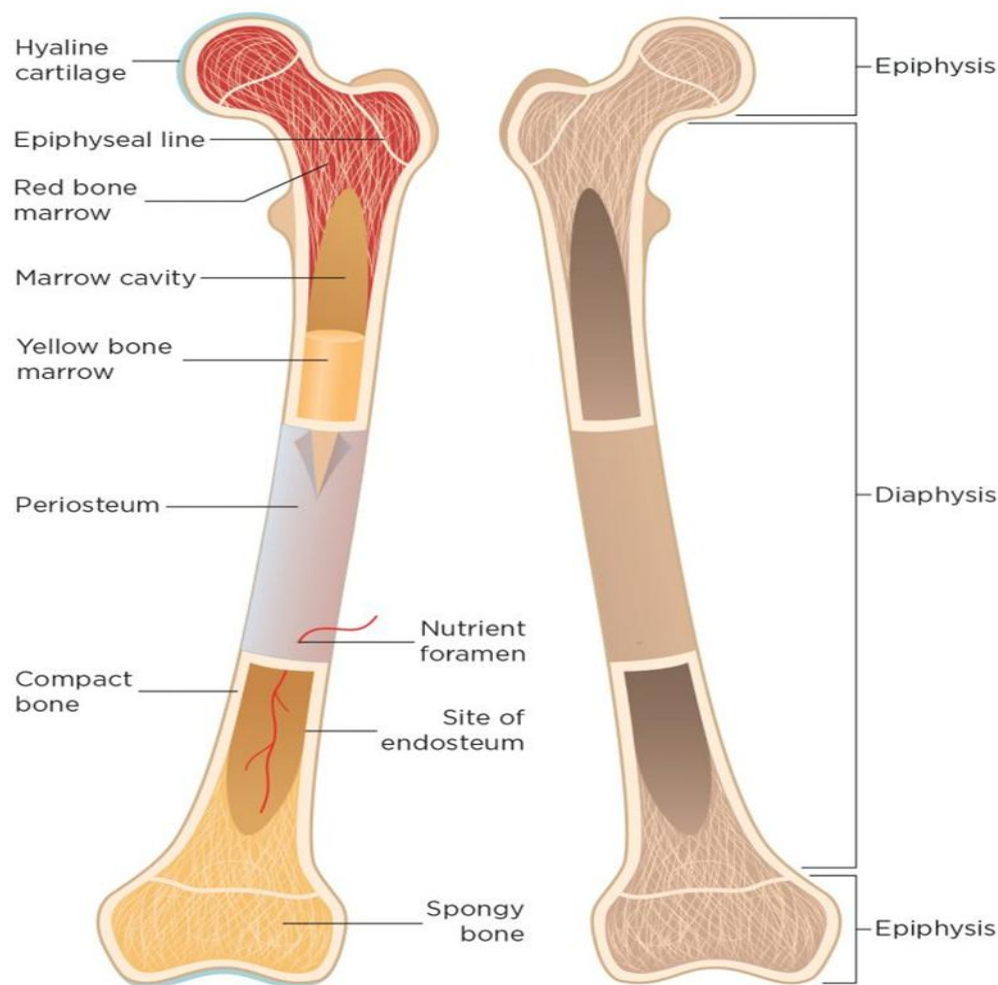
Blood-cell formation (haemopoiesis)

Blood cells are formed from haemopoietic stem cells present in red bone marrow. Babies are born with only red bone marrow; over time this is replaced by yellow marrow due to a decrease in erythropoietin, the hormone responsible for stimulating the production of erythrocytes (red blood cells) in the bone marrow. By adulthood, the amount of red marrow has halved, and this reduces further to around 30% in older age (Robson and Syndercombe Court, 2018).

Triglyceride storage

Yellow bone marrow (Fig 1) acts as a potential energy reserve for the body; it consists largely of adipose cells, which store triglycerides (a type of lipid that occurs naturally in the blood) (Tortora and Derrickson, 2009).

Fig 1. **Bone structure**



Development and structure of the skeleton

Infants are born with about 300 separate bones, a nonprofit children's health provider. As a child grows, some of those bones fuse together until growth stops, typically by the age of 25, leaving the skeleton with 206 bones.

Our bones are separated into two categories based on the purpose and location of the bones: The axial skeleton and the appendicular skeleton, according to "Anatomy & Physiology."

The axial skeleton contains 80 bones, including the skull, spine and rib cage. It forms the central structure of the skeleton, with the function of protecting the brain, spinal cord, heart and lungs.

The remaining 126 bones make up the appendicular skeleton; they include the arms, legs, shoulder girdle and pelvic girdle. The lower portion of the appendicular skeleton protects the major organs associated with digestion and reproduction and provides

stability when a person is walking or running. The upper portion allows for a greater range of motion when lifting and carrying objects.

Bones are further classified by their shape: long, short, flat, irregular or sesamoid, according to "Anatomy & Physiology".

- Long bones are found in the arms, legs, fingers and toes. These bones are longer than they are wide and are cylindrical. They move when the muscles around them contract, and they are the most mobile parts of the skeleton.
- Short bones are found in the wrists and ankles and are about equal in their length, width and thickness.
- Flat bones make up the skull, shoulder blades, sternum and ribs. These curved, thin bones protect internal organs and provide an anchor for muscles.
- Irregular bones are those in the spinal cord and face, which, because of their unique dimension, don't fit in any of the other shape categories.
- Sesamoid bones are found in the hands, wrists, feet, ears and knees. These small, round bones are embedded in tendons and protect them from the great pressure and force they encounter.

There are some variations between male and female skeletons. For example, the female pelvis is typically more broad, thin, and round than the male pelvis, according to "Anatomy & Physiology."

What's inside your bones?

All about your body's skeleton, the framework of bones that keeps you together.

Three main types of material make up every bone in your body: compact bone, spongy bone and bone marrow.

Approximately 80% of every bone is compact bone, which is the hardest and strongest type of bone and is what allows the body to support its weight. Compact bone makes up the outer layers of the bone and protects the inner parts of the bones where many vital functions occur, such as bone marrow production. Compact bone consists primarily of cells called osteocytes. Microscopic passages in between the cells to allow nerves and blood vessels to pass through.

About 20% of each bone is spongy bone, which is filled with large holes and passages. Most often found toward the ends of individual bones, the spongy bone material is filled with bone marrow, nerves and blood vessels.

Two types of bone marrow fill the pores in spongy bone. Approximately half is red bone marrow, which is found mainly within flat bones such as shoulder blades and ribs. This is where all red and white blood cells and platelets (cells that help a cut stop bleeding) are made. Infant's bones contain all red bone marrow to produce enough blood cells to keep up with the youngsters' growth.

The other half of marrow is yellow bone marrow, which is found in long bones, such as thigh bones, and consists primarily of fat. Blood vessels run through both types of bone marrow to deliver nutrients and remove waste from the bones.

There are four main types of cells within bones: Osteoblasts, osteocytes, osteoclasts and lining cells.

Osteoblasts are cells that create new or repair existing bone material as the bones grow or break. The cells create a flexible material called osteoid and then fortify it with minerals to harden and strengthen it. When osteoblasts successfully finish their job, they retire to become osteocytes or lining cells.

Osteocytes, found in the compact bone, are responsible for exchanging minerals and communicating with other cells in the vicinity. They are formed from old osteoblasts that have gotten stuck in the center of bones.

Osteoclasts break down existing bone material and reabsorb it. These cells often work with osteoblasts to heal and reshape bone after a break (the osteoclasts break down the extra callus formed by the healing process) to make room for new blood vessels and nerves and to make bones thicker and stronger.

Lining cells are flat bone cells that completely cover the outside surface of bones. Their primary function is controlling the movement of minerals, cells and other materials into and out of the bones.

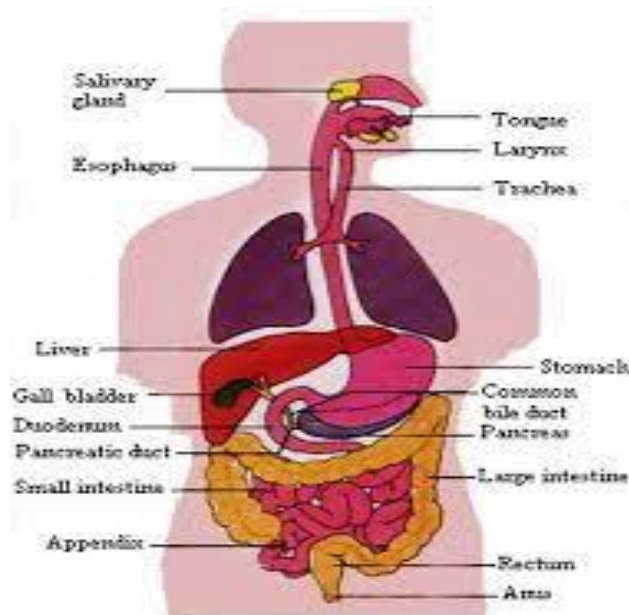
Diseases of the skeletal system

As with any part of the human body, bones are susceptible to injury and disease.

Some of the most common diseases that can affect the skeletal system include:

- **Osteoporosis** is a disease that causes the density and strength of bones to decrease because bone loss occurs faster than bone growth. It can be caused by genetics or unhealthy lifestyle habits (such as lack of calcium or vitamin D, and heavy smoking or drinking with little exercise).
- **Leukemia** is a type of cancer that starts in the bone marrow and the **lymphatic system**. Several types of leukemia affect various blood cells and other systems of the body.
- **Osteoarthritis** is a disease that causes the breakdown of the cartilage that protects the ends of bones in joints. This lack of cartilage leads to bone-on-bone rubbing, which can cause significant pain, damage to the bones and connective tissues, inflammation of the surrounding tissue and restricted motion.

The Digestive System



the digestive system uses mechanical and chemical activities to break food down into absorbable substances during its journey through the digestive system. Table 1 provides an overview of the basic functions of the digestive organs.

Main function of digestive system: The main function of the digestive system is to turn the food into simple sugars, amino acids, and carbohydrates. This is fuel for the human body.

Table 1: Functions of the Digestive Organs

Organ	Major functions	Other functions
Mouth	<ul style="list-style-type: none"> • Ingests food • Chews and mixes food • Begins chemical breakdown of carbohydrates • Moves food into the pharynx • Begins breakdown of lipids via lingual lipase 	<ul style="list-style-type: none"> • Moistens and dissolves food, allowing you to taste it • Cleans and lubricates the teeth and oral cavity • Has some antimicrobial activity
Pharynx	<ul style="list-style-type: none"> • Propels food from the oral cavity to the esophagus 	<ul style="list-style-type: none"> • Lubricates food and passageways
Esophagus	<ul style="list-style-type: none"> • Propels food to the stomach 	<ul style="list-style-type: none"> • Lubricates food and passageways
Stomach	<ul style="list-style-type: none"> • Mixes and churns food with gastric juices to form chyme • Begins chemical breakdown of proteins • Releases food into the duodenum as 	<ul style="list-style-type: none"> • Stimulates protein-digesting enzymes • Secretes intrinsic factor required for vitamin B₁₂ absorption in small intestine

Organ	Major functions	Other functions
	chyme <ul style="list-style-type: none"> • Absorbs some fat-soluble substances (for example, alcohol, aspirin) • Possesses antimicrobial functions 	
Small intestine	<ul style="list-style-type: none"> • Mixes chyme with digestive juices • Propels food at a rate slow enough for digestion and absorption • Absorbs breakdown products of carbohydrates, proteins, lipids, and nucleic acids, along with vitamins, minerals, and water • Performs physical digestion via segmentation 	<ul style="list-style-type: none"> • Provides optimal medium for enzymatic activity
Accessory organs	<ul style="list-style-type: none"> • Liver: produces bile salts, which emulsify lipids, aiding their digestion and absorption • Gallbladder: stores, concentrates, and releases bile • Pancreas: produces digestive enzymes and bicarbonate 	<ul style="list-style-type: none"> • Bicarbonate-rich pancreatic juices help neutralize acidic chyme and provide optimal environment for enzymatic activity
Large intestine	<ul style="list-style-type: none"> • Further breaks down food residues • Absorbs most residual water, electrolytes, and vitamins produced by enteric bacteria • Propels feces toward rectum • Eliminates feces 	<ul style="list-style-type: none"> • Food residue is concentrated and temporarily stored prior to defecation • Mucus eases passage of feces through colon

Functions of the Digestive System

1- ingestion – the oral cavity allows food to enter the digestive tract and have mastication (chewing) occurs, and the resulting food bolus is swallowed.

2- Digestion:

♣ Mechanical digestion – muscular movement of the digestive tract (mainly in the oral cavity and stomach) physically break down food into smaller particles.

♣ chemical digestion – hydrolysis reactions aided by enzymes (mainly in the stomach and small intestine) chemically break down food particles into nutrient molecules, small enough to be absorbed.

♣ Secretion – enzymes and digestive fluids secreted by the digestive tract and its accessory organs facilitate chemical digestion.

♣ Absorption – passage of the end – products (nutrients) of chemical digestion from the digestive tract into blood or lymph for distribution to tissue cells.

♣ Elimination (defecation) – undigested material will be released through the rectum and anus by defecation. Copyright © 2006 Pearson Education, Inc., publishing as Benjamin Cummings

Digestive Processes

The processes of digestion include six activities: ingestion, propulsion, mechanical or physical digestion, chemical digestion, absorption, and defecation.

The first of these processes, **ingestion**, refers to the entry of food into the alimentary canal through the mouth. There, the food is chewed and mixed with saliva, which contains enzymes that begin breaking down the carbohydrates in the food plus some lipid digestion via lingual lipase. Chewing increases the surface area of the food and allows an appropriately sized bolus to be produced.

Food leaves the mouth when the tongue and pharyngeal muscles propel it into the esophagus. This act of swallowing, the last voluntary act until defecation, is an example of propulsion, which refers to the movement of food through the digestive tract. It includes both the voluntary process of swallowing and the involuntary process of peristalsis. Peristalsis consists of sequential, alternating waves of contraction and relaxation of alimentary wall smooth muscles, which act to propel food along (Figure 1). These waves also play a role in mixing food with digestive juices. Peristalsis is so powerful that foods and liquids you swallow enter your stomach even if you are standing on your head.

Peristalsis

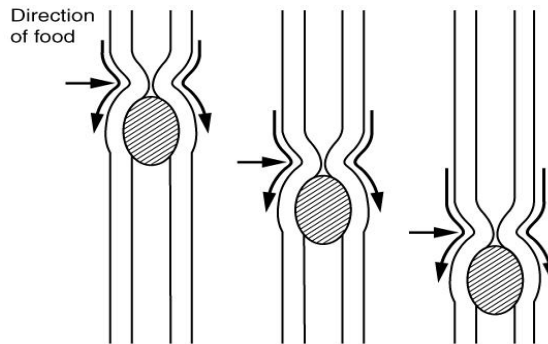


Figure 1: Peristalsis moves food through the digestive tract with alternating waves of muscle contraction and relaxation.

Digestion includes both mechanical and chemical processes.

Mechanical digestion is a purely physical process that does not change the chemical nature of the food. Instead, it makes the food smaller to increase both surface area and mobility. It includes mastication, or chewing, as well as tongue movements that help break food into smaller bits and mix food with saliva. Although there may be a tendency to think that mechanical digestion is limited to the first steps of the digestive process, it occurs after the food leaves the mouth, as well. The mechanical churning of food in the stomach serves to further break it apart and expose more of its surface area to digestive juices, creating an acidic “soup”

called chyme. Segmentation, which occurs mainly in the small intestine, consists of localized contractions of circular muscle of the muscularis layer of the alimentary canal. These contractions isolate small sections of the intestine, moving their contents back and forth while continuously subdividing, breaking up, and mixing the contents. By moving food back and forth in the intestinal lumen, segmentation mixes food with digestive juices and facilitates absorption.

chemical digestion, starting in the mouth, digestive secretions break down complex food molecules into their chemical building blocks (for example, proteins into separate amino acids). These secretions vary in composition, but typically contain water, various enzymes, acids, and salts. The process is completed in the small intestine.

Food that has been broken down is of no value to the body unless it enters the bloodstream and its nutrients are put to work. This occurs through the process of absorption, which takes place primarily within the small intestine. There, most nutrients are absorbed from the lumen of the alimentary canal into the bloodstream through the epithelial cells that make up the mucosa. Lipids are absorbed into lacteals and are transported via the lymphatic vessels to the bloodstream (the subclavian veins near the heart). The details of these processes will be discussed later.

defecation, the final step in digestion, undigested materials are removed from the body as feces.

in some cases, a single organ is in charge of a digestive process. For example, ingestion occurs only in the mouth and defecation only in the anus. However, most digestive processes involve the interaction of several organs and occur gradually as food moves through the alimentary canal (Figure 2).

Digestive Processes

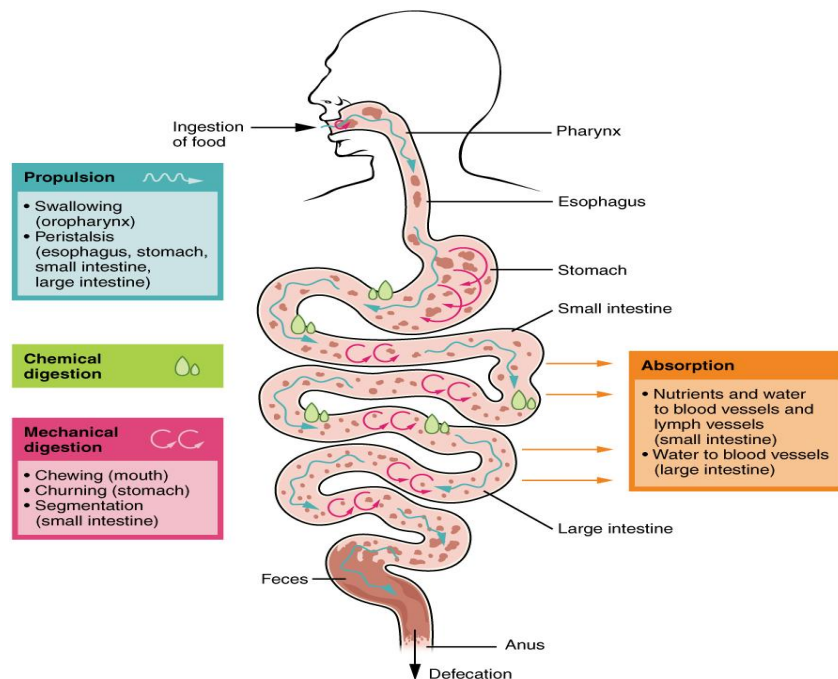


Figure 2: The digestive processes are ingestion, propulsion, mechanical digestion, chemical digestion, absorption, and defecation.

Some chemical digestion occurs in the mouth. Some absorption can occur in the mouth and stomach, for example, alcohol and aspirin.

Regulatory Mechanisms

Neural and endocrine regulatory mechanisms work to maintain the optimal conditions in the lumen needed for digestion and absorption. These regulatory mechanisms, which stimulate digestive activity through mechanical and chemical activity, are controlled both extrinsically and intrinsically.

Neural Controls

The walls of the alimentary canal contain a variety of sensors that help regulate digestive functions. These include mechanoreceptors, chemoreceptors, and osmoreceptors, which are capable of detecting mechanical, chemical, and osmotic stimuli, respectively. For example, these receptors can sense when the presence of food has caused the stomach to expand, whether food particles have been sufficiently broken down, how much liquid is present, and the type of nutrients in the food (lipids, carbohydrates, and/or proteins). Stimulation of these receptors provokes an appropriate reflex that furthers the process of digestion. This may entail sending a message that activates the glands that secrete digestive juices into the lumen, or it may mean the stimulation of muscles within the alimentary canal, thereby activating peristalsis and segmentation that move food along the intestinal tract.

The walls of the entire alimentary canal are embedded with nerve plexuses that interact with the central nervous system and other nerve plexuses—either within the same digestive organ or in different ones. These interactions prompt several types of reflexes. Extrinsic nerve plexuses orchestrate long reflexes, which involve the central and autonomic nervous systems and work in response to stimuli from outside the digestive system. Short reflexes, on the other hand, are orchestrated by intrinsic nerve plexuses within the alimentary canal wall. These two plexuses and their connections were introduced earlier as the enteric nervous system. Short reflexes regulate activities in one area of the digestive tract and may coordinate local peristaltic movements and stimulate digestive secretions. For example, the sight, smell, and taste of food initiate long reflexes that begin with a sensory neuron delivering a signal to the medulla oblongata. The response to the signal is to stimulate cells in the stomach to begin secreting digestive juices in preparation for incoming food. In contrast, food that distends the stomach initiates short reflexes that cause cells in the stomach wall to increase their secretion of digestive juices.

Hormonal Controls

A variety of hormones are involved in the digestive process. The main digestive hormone of the stomach is gastrin, which is secreted in response to the presence of food. Gastrin stimulates the secretion of gastric acid by the parietal cells of the stomach mucosa. Other GI hormones are produced and act upon the gut and its accessory organs. Hormones produced by the duodenum

include secretin, which stimulates a watery secretion of bicarbonate by the pancreas; cholecystokinin (CCK), which stimulates the secretion of pancreatic enzymes and bile from the liver and release of bile from the gallbladder; and gastric inhibitory peptide, which inhibits gastric secretion and slows gastric emptying and motility. These GI hormones are secreted by specialized epithelial cells, called endocrinocytes, located in the mucosal epithelium of the stomach and small intestine. These hormones then enter the bloodstream, through which they can reach their target organs.

The Circulatory System

(The Heart, Blood Vessels, Blood Types)

Circulatory systems generally have three main features:

- Fluid (blood or lymph) that transports materials.
- System of blood vessels.
- A heart to pump the fluid through the vessels.

Types of circulatory systems:

- Animals that have a circulatory system have one of two kinds:
Open: fluid is circulated through an open body chamber.
Closed: fluid is circulated through blood vessels.

Function

- Transport materials needed by cells (Oxygen- Glucose).
- Remove waste materials from cells (Carbon dioxide- Urea)

Major Components

Blood: Fluid that fills the circulatory system

Pump (heart): Continuously circulates blood

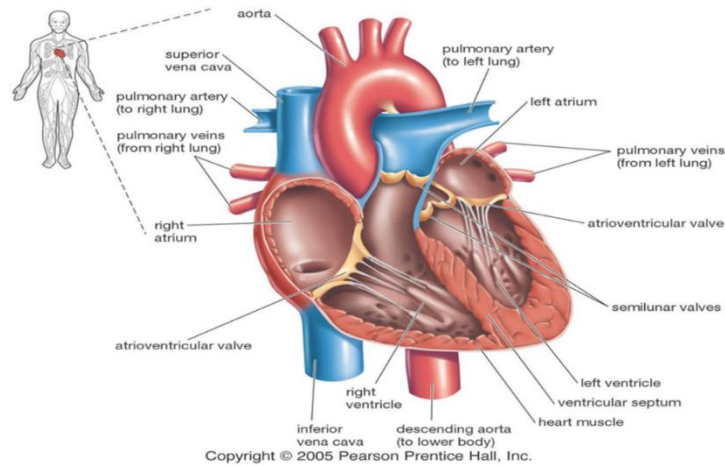
Network of tubes (blood vessels)

- Arteries- blood away from heart
- Veins- blood back to the heart
- Capillaries- link Arteries with Veins

1-The Heart

The human heart has four chambers (Left and right ventricle - Left and right atrium).

The left side of the heart pumps oxygenated blood to the body while the right side of the heart pumps deoxygenated blood to the lungs where oxygen can be absorbed by the hemoglobin carrying red blood cells.



Functions of the Heart

- Generating blood pressure.
- Routing blood.
- Heart separates pulmonary and systemic circulations.
- Ensuring one-way blood flow.
- Heart valves ensure one-way flow.
- Regulating blood supply.

Size, Shape, Location of the Heart

Shape:

Apex: Blunt rounded point of cone.

Base: Flat part at opposite of end of cone.

- Size of a closed fist
- Located in thoracic cavity between two lungs

External Anatomy

- **Four chambers**

2 atria

2 ventricles

- **Major veins**

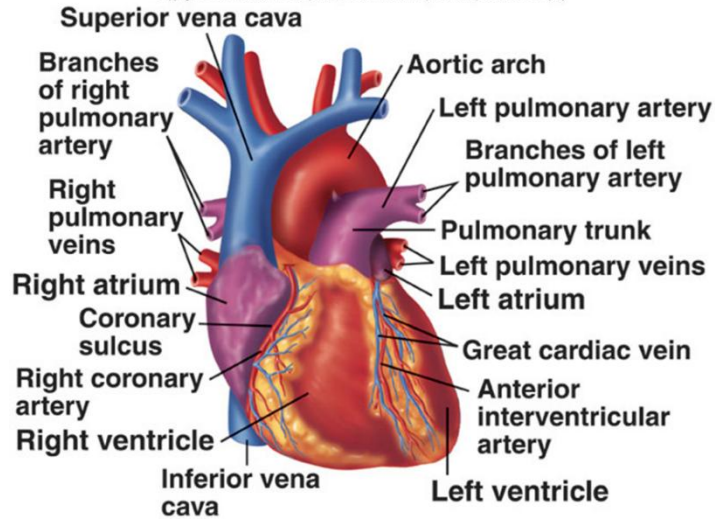
Superior and inferior vena cava

Pulmonary veins

- **Major arteries**

Aorta

Pulmonary trunk



Heart Valves

- Atrioventricular valves

Tricuspid

Bicuspid or mitral

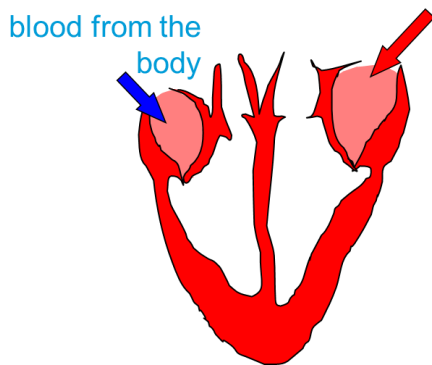
- Semilunar valves

Aortic

Pulmonary

Prevent blood from flowing back

How does the Heart work? Step one

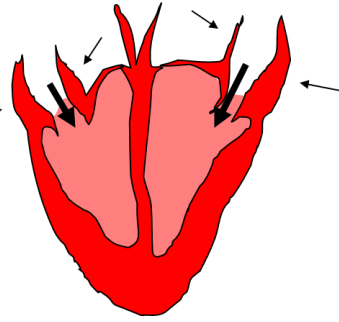


blood from the lungs

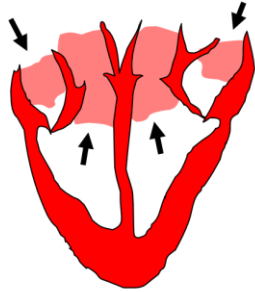
The heart beat begins when the heart muscles **relax** and blood flows into the atria.

STEP TWO

The atria then **contract** and the valves **open** to allow blood into the ventricles.



STEP THREE



The valves **close** to stop blood flowing backwards.

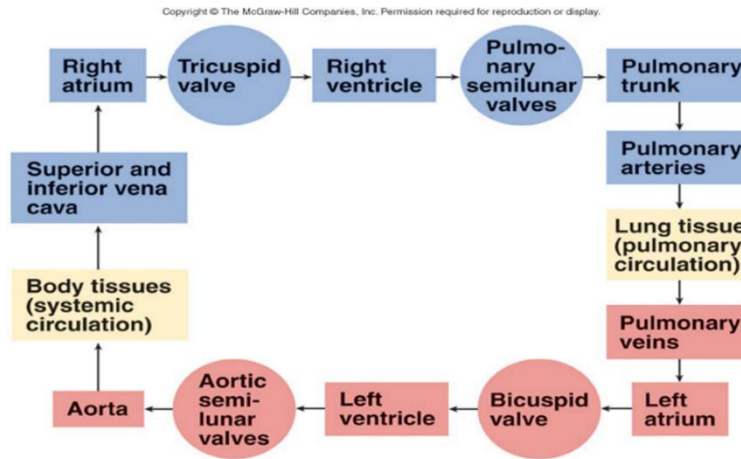
The ventricles **contract** forcing the blood to leave the heart.

At the same time, the atria are **relaxing** and once again filling with blood

The cycle then repeats itself.

Circulation

After passing through the capillaries of the lungs, the blood which is now oxygenated returns to the heart in the pulmonary veins. The left atrium receives blood from the pulmonary vein. Blood passes through the mitral valve into the left ventricle. Contraction of the left ventricle pushes blood through the aortic semilunar valve into the aorta. Blood travels to all regions of the body where it feeds cells with oxygen picked up from the lungs and nutrients from the digestive tract. Deoxygenated blood returns from the rest of the body through the superior and inferior vena cava. Contraction of the right ventricle pushes blood through the pulmonary semilunar valve into the pulmonary arteries in which it travels to the lungs.



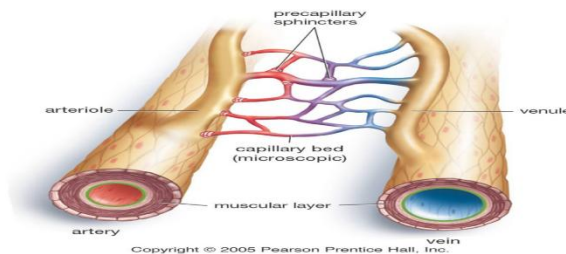
Blood Pressure

Blood pressure is a measure of the force exerted by the blood on the wall of the arteries. An example is 120/80 (systolic pressure/diastolic pressure). Systolic pressure is the result of the contraction of the ventricles (normal 110-140). Diastolic pressure is during the ventricle relaxation (normal 70-90)

2-Blood Vessels:

Blood vessels fall into three major classes:

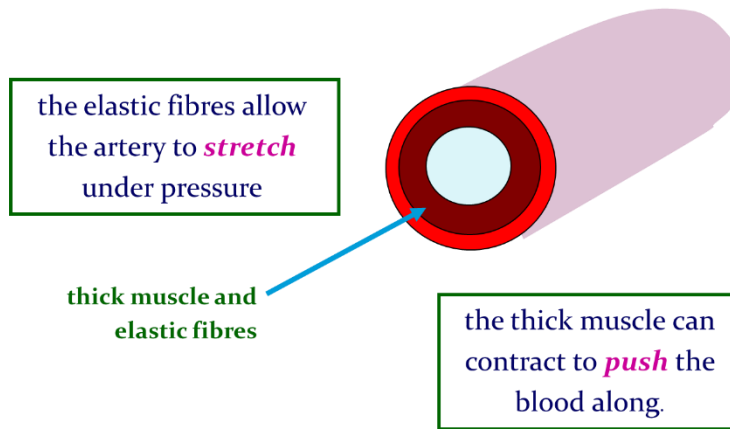
- Arteries and arterioles carry blood away from the heart.
- Veins and venules carry blood to the heart.
- Capillaries allow exchange of nutrients, wastes and gases.



a-The ARTERY

Arteries are thick-walled and lined with smooth muscle. How does the structure of an artery help with its function?

Arteries carry blood away from the heart.

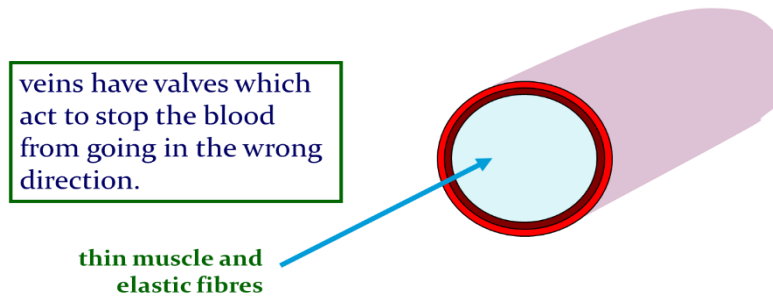


Arteries carry blood away from the heart.

b-The Vein

Veins have thinner walls than arteries. Veins have fewer smooth muscle cells but do have valves. How do valves and the skeletal muscles help vein's function?

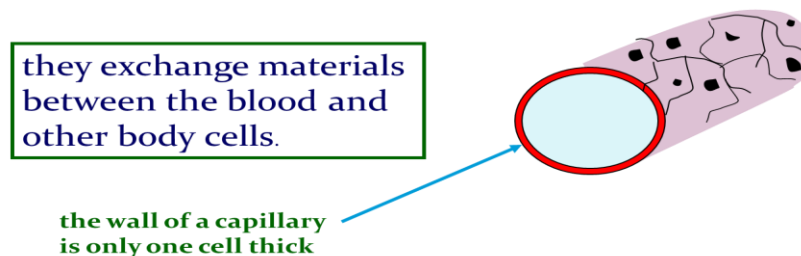
Veins carry blood towards from the heart.



c- The Capillary

Body tissues contain a vast network of thin capillaries. Capillary walls are only one cell thick, allowing exchange of gases, nutrients, and wastes.

Capillaries link Arteries with Veins



3- Blood Components:

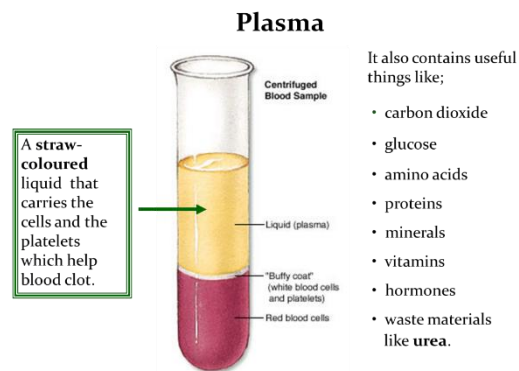
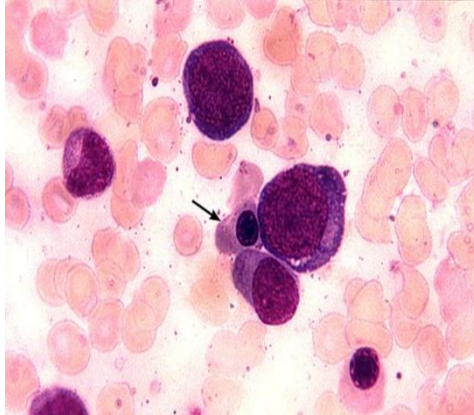
Blood is made up of four major components. What do each of these do?

- Plasma: the liquid portion.

- Red blood cells (RBCs).
- White blood cells (WBCs).
- Platelets (PLT).

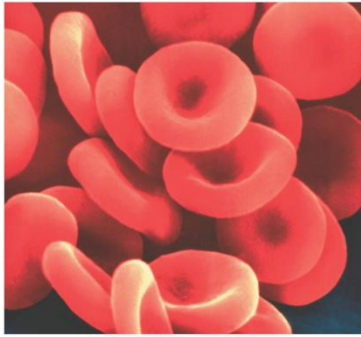
A-) Plasma

Liquid portion of the blood. Contains clotting factors, hormones, antibodies, dissolved gases, nutrients, and waste.



B.) Red Blood Cells

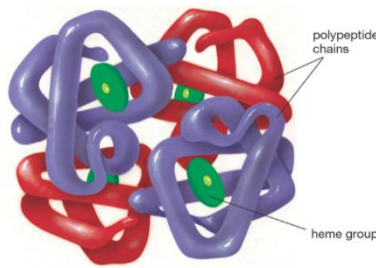
- A biconcave disc that is round and flat.
- Carry hemoglobin and oxygen. Do not have a nucleus and live only about 120 days.
- Can change shape to an amazing extent, without breaking, as it squeezes single file through the capillaries.
- Cannot repair themselves.
- Make up about 99% of the blood's cellular component.
- Red color is due to hemoglobin.



Copyright © 2005 Pearson Prentice Hall, Inc.

Hemoglobin

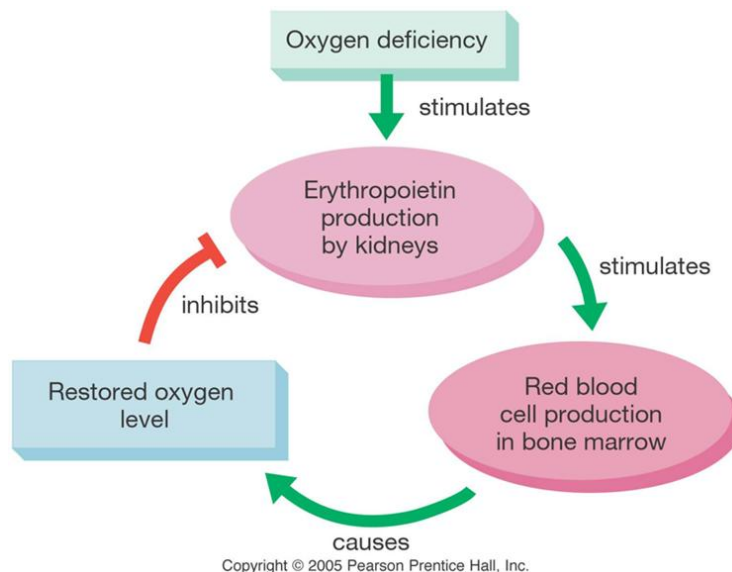
Hemoglobin is a complex protein made up of four protein strands, plus iron-rich heme groups. Each hemoglobin molecule can carry four oxygen atoms. The presence of oxygen turns hemoglobin bright red.



Copyright © 2005 Pearson Prentice Hall, Inc.

RBC lifespan

RBCs live about 4 months. Iron from hemoglobin is recycled in the liver and spleen. The hormone erythropoietin, made by the kidneys, stimulates the production of RBCs in red bone marrow.

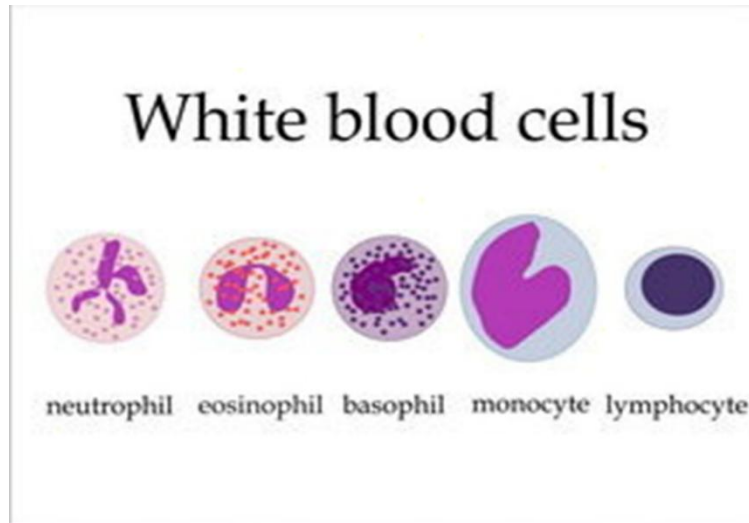


Copyright © 2005 Pearson Prentice Hall, Inc.

C.) White Blood cells

- Fight infection and are formed in the bone marrow.

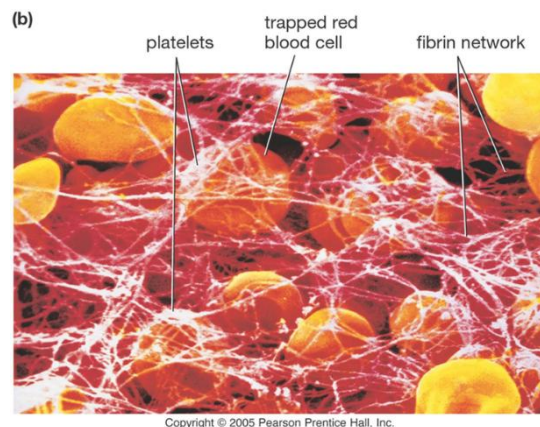
- White blood cells defend against disease by recognizing proteins that do not belong to the body.
- White cells can ooze through the walls of capillaries to patrol the tissues and reach the lymph system
- Have five types (neutrophils, lymphocytes, eosinophils, basophils, and monocytes).



the two main ones are the lymphocytes and the macrophages, macrophages ‘eat’ and digest micro-organisms, some lymphocytes fight disease by making antibodies to destroy invaders by dissolving them. other lymphocytes make antitoxins to break down poisons.

D) Platelets

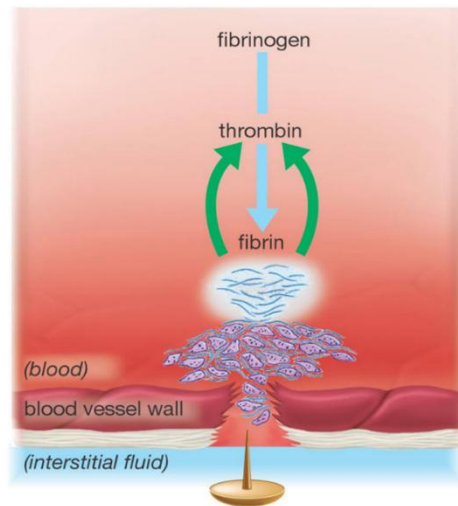
Platelets are cell fragments used in blood clotting. Platelets are derived from megakaryocytes. Because they lack a nucleus, platelets have a short lifespan, usually about 10 days.



Blood clotting

- 1- Platelets aggregate at the site of a wound.
- 2- Broken cells and platelets release chemicals to stimulate thrombin production.
- 3- Thrombin converts the protein fibrinogen into sticky fibrin, which binds the clot.

(a)



Copyright © 2005 Pearson Prentice Hall, Inc.

Disorders of the Circulatory System

- Anemia - lack of iron in the blood, low RBC count.
- Leukemia - white blood cells proliferate wildly, causing anemia.
- Hemophilia - bleeder's disease, due to lack of fibrinogen in thrombocytes.
- Heart Murmur - abnormal heartbeat, caused by valve problems.
- Heart attack - blood vessels around the heart become blocked with plaque, also called myocardial infarction.

The Neuromuscular System

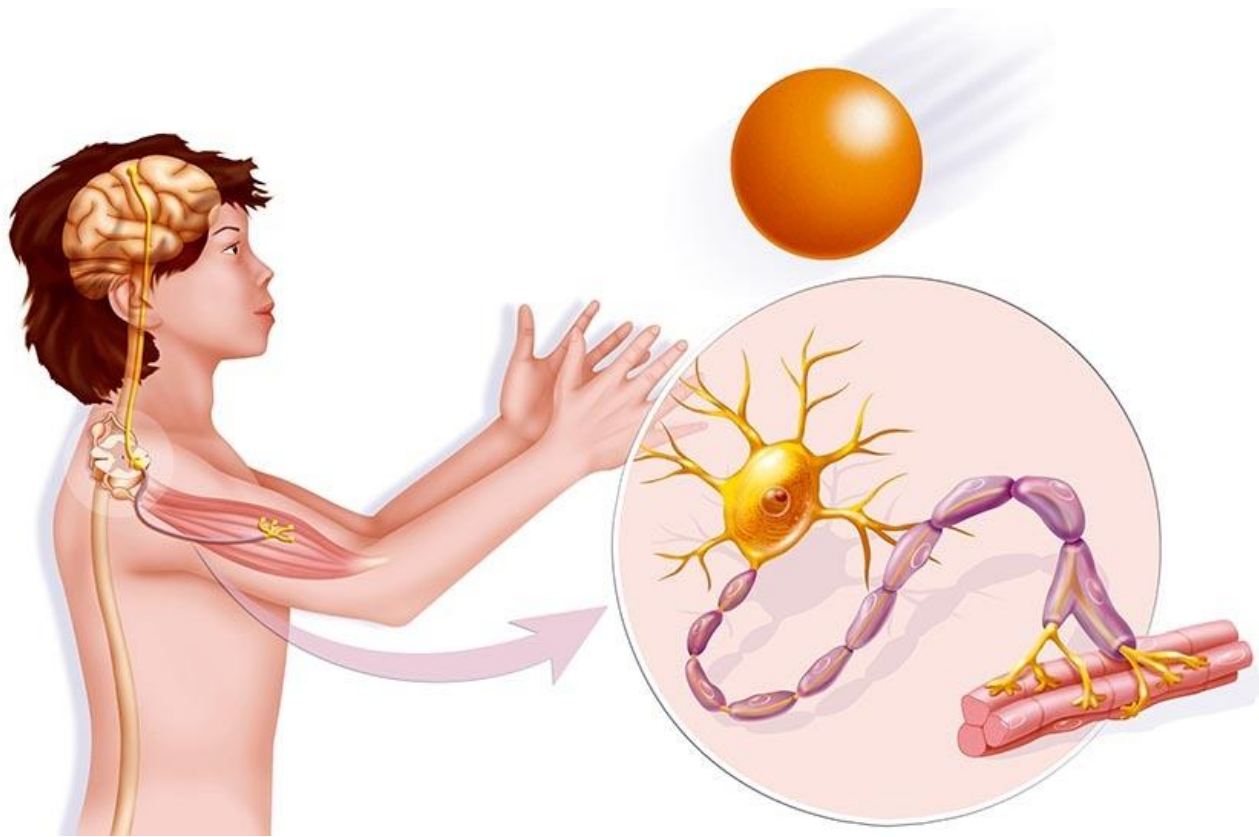
The neuromuscular system includes all the muscles in the body and the nerves serving them. Every movement the body makes requires communication between the brain and the muscles. The nervous system provides the link between thoughts and actions by relaying messages from the brain to other parts of the body.

Nerves and muscles, working together as the neuromuscular system, make the body move as you want it to and also control functions such as breathing.

How does the neuromuscular system work?

Nerves have cells called neurons. Neurons carry messages from the brain via the spinal cord. The neurons that carry these messages to the muscles are called motor neurons.

Each motor neuron ending sits very close to a muscle fibre. Where they sit together is called a neuromuscular junction. The motor neurons release a chemical, which is picked up by the muscle fiber. This tells the muscle fiber to contract, which makes the muscles move.



The Muscular System

The muscular system controls numerous functions, which is possible with the significant differentiation of muscle tissue morphology and ability.

Key Points

- The muscular system is responsible for functions such as maintenance of posture, locomotion, and control of various circulatory systems.
- Muscle tissue can be divided functionally (voluntarily or involuntarily controlled) and morphologically (striated or non-striated).
- These classifications describe three distinct muscle types: skeletal, cardiac and smooth. Skeletal muscle is voluntary and striated, cardiac muscle is involuntary and striated, and smooth muscle is involuntary and non-striated.

Key Terms

- **myofibril:** A fiber made up of several myofilaments that facilitates the generation of tension in a myocyte.
- **myofilament:** A filament composed of either multiple myosin or actin proteins that slide over each other to generate tension.
- **myosin:** A motor protein which forms myofilaments that interact with actin filaments to generate tension.
- **actin:** A protein which forms myofilaments that interact with myosin filaments to generate tension.
- **striated:** The striped appearance of certain muscle types in which myofibrils are aligned to produce a constant directional tension.
- **voluntary:** A muscle movement under conscious control (e.g. deciding to move the forearm).
- **involuntary:** A muscle movement not under conscious control (e.g. the beating of the heart).
- **myocyte:** A muscle cell.

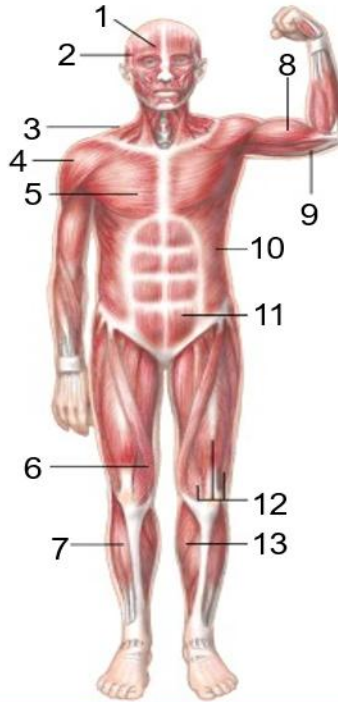
The Musculoskeletal System

The muscular system is made up of muscle tissue and is responsible for functions such as maintenance of posture, locomotion and control of various circulatory systems. This includes the beating of the heart and the movement of food through the digestive system. The muscular system is closely associated with the skeletal system in facilitating movement. Both voluntary and involuntary muscular system functions are controlled by the nervous system.

Section 11.2 Your Muscular System

The Muscular System

- 1) Frontalis
- 2) Temporalis
- 3) Trapezius
- 4) Deltoid
- 5) Pectoralis major
- 6) Sartorius
- 7) Tibialis anterior



- 8) Biceps
- 9) Triceps
- 10) External oblique
- 11) Rectus abdominus
- 12) Quadriceps muscles
- 13) Gastrocnemius

End of Slide



Chapter
Table of Contents

Slide 11 of 16

© Pearson Education, Inc. All rights reserved.

Muscle is a highly-specialized soft tissue that produces tension which results in the generation of force. Muscle cells, or myocytes, contain myofibrils comprised of actin and myosin myofilaments which slide past each other producing tension that changes the shape of the myocyte. Numerous myocytes make up muscle tissue and the controlled production of tension in these cells can generate significant force.

Muscle tissue can be classified functionally as voluntary or involuntary and morphologically as striated or non-striated. Voluntary refers to whether the muscle is under conscious control, while striation refers to the presence of visible banding within myocytes caused by the organization of myofibrils to produce constant tension.

Types of Muscle

The above classifications describe three forms of muscle tissue that perform a wide range of diverse functions.

Skeletal Muscle

Skeletal muscle mainly attaches to the skeletal system via tendons to maintain posture and control movement. For example, contraction of the biceps muscle, attached to the scapula and radius, will raise the forearm. Some skeletal muscle can attach directly to other muscles or to the skin, as seen in the face where numerous muscles control facial expression.

Skeletal muscle is under voluntary control, although this can be subconscious when maintaining posture or balance. Morphologically skeletal myocytes are elongated and tubular and appear striated with multiple peripheral nuclei.

Cardiac Muscle Tissue

Cardiac muscle tissue is found only in the heart, where cardiac contractions pump blood throughout the body and maintain blood pressure.

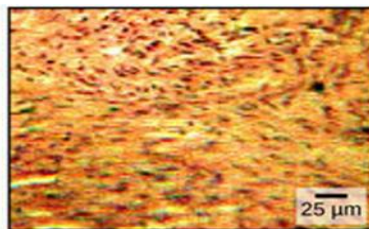
As with skeletal muscle, cardiac muscle is striated; however it is not consciously controlled and so is classified as involuntary. Cardiac muscle can be further differentiated from skeletal muscle by the presence of intercalated discs that control the synchronized contraction of cardiac tissues. Cardiac myocytes are shorter than skeletal equivalents and contain only one or two centrally located nuclei.

Smooth Muscle Tissue

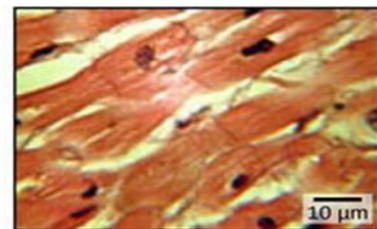
Smooth muscle tissue is associated with numerous organs and tissue systems, such as the digestive system and respiratory system. It plays an important role in the regulation of flow in such systems, such as aiding the movement of food through the digestive system via peristalsis. Smooth muscle is non-striated and involuntary. Smooth muscle myocytes are spindle shaped with a single centrally located nucleus.



Skeletal muscle



Smooth muscle



Cardiac muscle

Types of muscle: The body contains three types of muscle tissue: skeletal muscle, smooth muscle, and cardiac muscle, visualized here using light microscopy. Visible striations in skeletal and cardiac muscle are visible, differentiating them from the more randomized appearance of smooth muscle.

Function of Muscle Tissue

The main function of the muscular system is movement. Muscles are the only tissue in the body that has the ability to contract and therefore move the other parts of the body.

Related to the function of movement is the muscular system's second function: the maintenance of posture and body position. Muscles often contract to hold the body still or in a particular position rather than to cause movement. The muscles responsible for the body's posture have the greatest endurance of all muscles in the body—they hold up the body throughout the day without becoming tired.

Another function related to movement is the movement of substances inside the body. The cardiac and visceral muscles are primarily responsible for transporting substances like blood or food from one part of the body to another.

The final function of muscle tissue is the generation of body heat. As a result of the high metabolic rate of contracting muscle, our muscular system produces a great deal of waste heat. Many small muscle contractions within the body produce our natural body heat. When we exert ourselves more than normal, the extra muscle contractions lead to a rise in body temperature and eventually to sweating.

The Nervous System

Basic Structure and Function of the Nervous System

the nervous system probably includes the brain, the nervous tissue contained within the cranium, and the spinal cord, the extension of nervous tissue within the vertebral column. That suggests it is made of two organs—and you may not even think of the spinal cord as an organ—but the nervous system is a very complex structure. Within the brain, many different and separate regions are responsible for many different and separate functions.

The Central and Peripheral Nervous Systems

The nervous system can be divided into two major regions: the central and peripheral nervous systems.

The central nervous system (CNS) is the brain and spinal cord, and the peripheral nervous system (PNS) are referred to as ganglia and Nerves. The brain is contained within the cranial cavity of the skull, and the spinal cord is contained within the vertebral cavity of the vertebral column.

Basic Functions of the Nervous System

The nervous system is involved in receiving information about the environment around us (sensation) and generating responses to that information (motor responses).

But there is a third function that needs to be included. Sensory input needs to be integrated with other sensations, as well as with memories, emotional state, or learning (cognition). Some regions of the nervous system are termed integration or association areas. The process of integration combines sensory perceptions and higher cognitive functions such as memories, learning, and emotion to produce a response.

Sensation:

The first major function of the nervous system is sensation—receiving information about the environment to gain input about what is happening outside the body (or, sometimes, within the body). The sensory functions of the nervous system register the presence of a change from homeostasis or a particular event in the environment, known as a stimulus. The senses we think of most are the “big five”: taste, smell, touch, sight, and hearing.

Response:

The nervous system produces a response based on the stimuli perceived by sensory structures. An obvious response would be the movement of muscles, such as withdrawing a hand from a hot stove.

Controlling the Body:

The nervous system can be divided into two parts mostly based on a functional difference in responses. The somatic nervous system (SNS) is responsible for conscious perception and voluntary motor responses. Voluntary motor response means the contraction of skeletal muscle, The autonomic nervous system (ANS) is responsible for involuntary control of the body, usually for the sake of homeostasis (regulation of the internal environment). Sensory input for autonomic functions can be from sensory structures tuned to external or internal environmental stimuli.

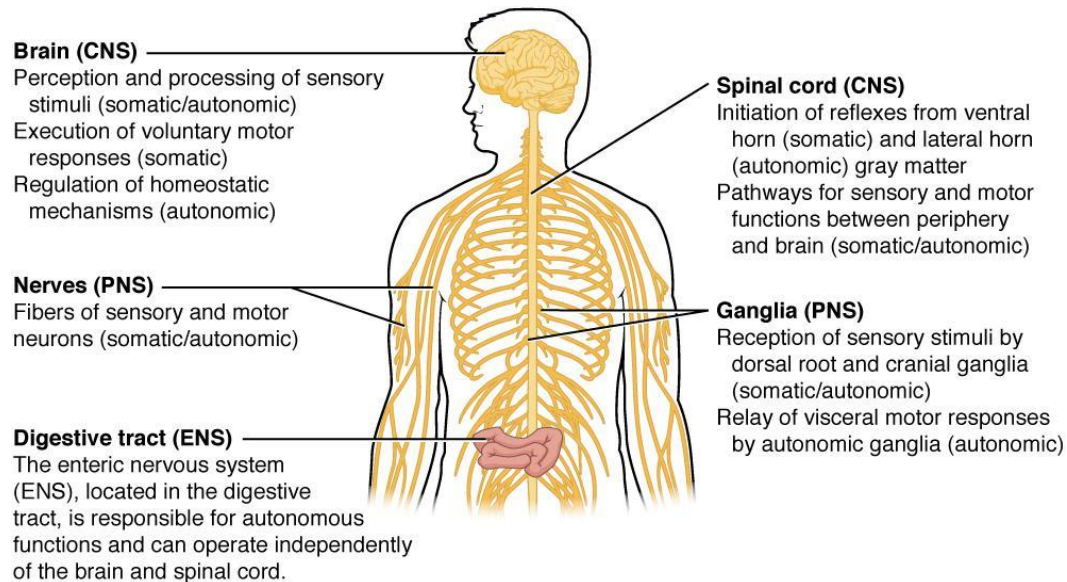


Figure: Somatic, Autonomic, and Enteric Structures of the Nervous System Somatic structures include the spinal nerves, both motor and sensory fibers, as well as the sensory ganglia (posterior root ganglia and cranial nerve ganglia). Autonomic structures are found in the nerves also but include the sympathetic and parasympathetic ganglia. The enteric nervous system includes the nervous tissue within the organs of the digestive tract.

Nervous Tissue:

Nervous tissue is composed of two types of cells, neurons, and glial cells. Neurons are the primary type of cell that most anyone associates with the nervous system.

They are responsible for the computation and communication that the nervous system provides.

Neurons:

Neurons are the cells considered to be the basis of nervous tissue. They are responsible for the electrical signals that communicate information about sensations, and that produce movements in response to those stimuli.

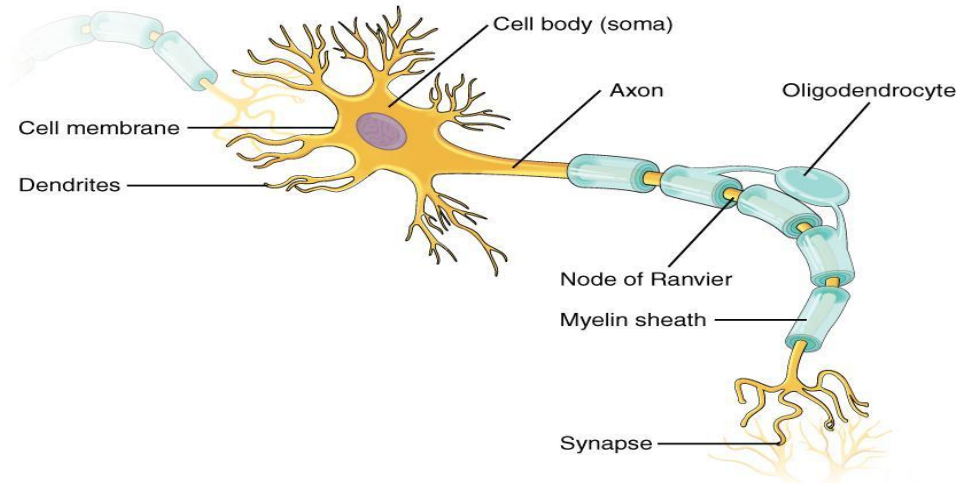


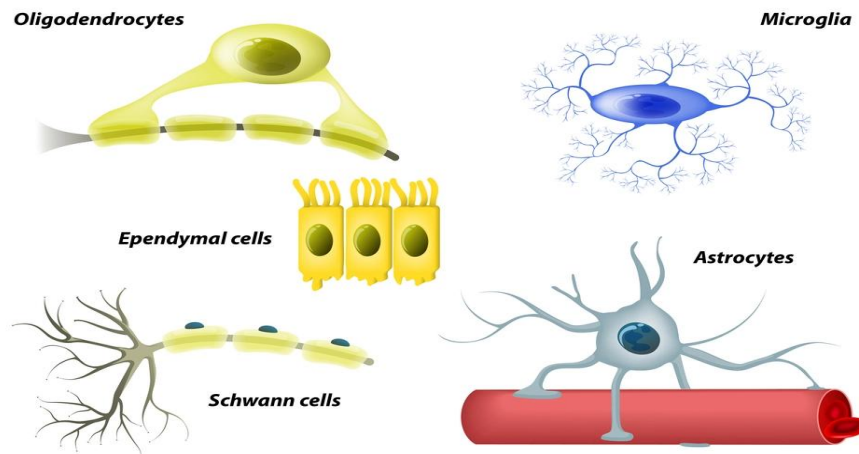
Figure: Parts of a Neuron

Structure: The major parts of the neuron are labeled on a multipolar neuron from the CNS. Where the axon emerges from the cell body, there is a special region referred to as the axon hillock. This is a tapering of the cell body toward the axon fiber. Within the axon hillock, the cytoplasm changes to a solution of limited components called axoplasm. Because the axon hillock represents the beginning of the axon, it is also referred to as the initial segment.

Glial Cells

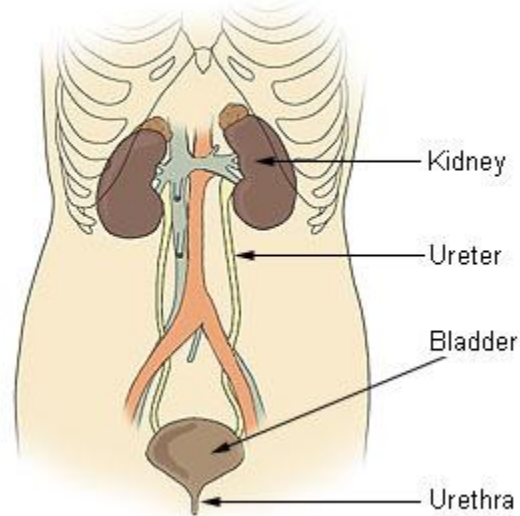
Glial cells, or neuroglia or simply glia, are the other type of cell found in nervous tissue. They are supporting cells, and many functions are directed at helping neurons complete their function for communication.

GLIAL CELLS



Urinogenital system

Components of the Urinary System



1-Urinary System

The Urinary System is a group of organs in the body concerned with filtering out excess fluid and other substances from the bloodstream. The substances are filtered out from the body in the form of urine. Urine is a liquid produced by the kidneys, collected in the bladder and excreted through the urethra. Urine is used to extract excess minerals or vitamins as well as blood corpuscles from the body.

The Urinary organs include the kidneys, ureters, bladder, and urethra. The Urinary system works with the other systems of the body to help maintain homeostasis. The kidneys are the main organs of homeostasis because they maintain the acid base balance and the water salt balance of the blood.

Functions of the Urinary System

One of the major functions of the Urinary system is the process of excretion.

1-Excretion is the process of eliminating, from an organism, waste products of metabolism and other materials that are of no use.

2-The urinary system maintains an appropriate fluid volume by regulating the amount of water that is excreted in the urine. Other aspects of its function include

3-regulating the concentrations of various electrolytes in the body fluids and maintaining normal pH of the blood.

Several body organs carry out excretion, but the kidneys are the most important excretory organ. The primary function of the kidneys is to maintain a stable internal environment (homeostasis) for optimal cell and tissue metabolism. They do this by separating urea, mineral salts, toxins, and other waste products from the blood. They also do the job of

conserving water, salts, and electrolytes. At least one kidney must function properly for life to be maintained.

Six important roles of the kidneys are:

Regulation of plasma ionic composition. Ions such as sodium, potassium, calcium, magnesium, chloride, bicarbonate, and phosphates are regulated by the amount that the kidney excretes. Regulation of plasma osmolarity. The kidneys regulate osmolarity because they have direct control over how many ions and how much water a person excretes.

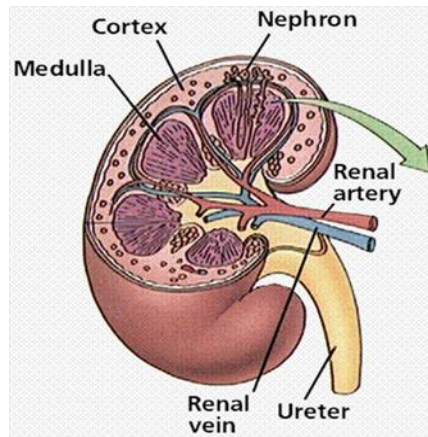
Regulation of plasma volume. Your kidneys are so important they even have an effect on your blood pressure. The kidneys control plasma volume by controlling how much water a person excretes. The plasma volume has a direct effect on the total blood volume, which has a direct effect on your blood pressure. Salt (NaCl) will cause osmosis to happen; the diffusion of water into the blood.

Regulation of plasma hydrogen ion concentration (pH). The kidneys partner up with the lungs and they together control the pH. The kidneys have a major role because they control the amount of bicarbonate excreted or held onto. The kidneys help maintain the blood pH mainly by excreting hydrogen ions and reabsorbing bicarbonate ions as needed.

Removal of metabolic waste products and foreign substances from the plasma. One of the most important things the kidneys excrete is nitrogenous waste. As the liver breaks down amino acids it also releases ammonia. The liver then quickly combines that ammonia with carbon dioxide, creating urea which is the primary nitrogenous end product of metabolism in humans. The liver turns the ammonia into urea because it is much less toxic. We can also excrete some ammonia, creatinine and uric acid. The creatinine comes from the metabolic breakdown of creatine phosphate (a high-energy phosphate in muscles). Uric acid comes from the breakdown of nucleotides. Uric acid is insoluble and too much uric acid in the blood will build up and form crystals that can collect in the joints and cause gout.

Secretion of Hormones The endocrine system has assistance from the kidney's when releasing hormones. Renin is released by the kidneys. Renin leads to the secretion of aldosterone which is released from the adrenal cortex. Aldosterone promotes the kidneys to reabsorb the sodium (Na⁺) ions. The kidneys also secrete erythropoietin when the blood doesn't have the capacity to carry oxygen. Erythropoietin stimulates red blood cell production. The Vitamin D from the skin is also activated with help from the kidneys. Calcium (Ca⁺) absorption from the digestive tract is promoted by vitamin D.

Organs in the Urinary System Kidneys and Their Structure:



The kidneys

The kidneys are a pair of bean shaped, reddish brown organs about the size of your fist. It measures 10-12 cm long. They are covered by the renal capsule, which is a tough capsule of fibrous connective tissue. Adhering to the surface of each kidney is two layers of fat to help cushion them. There is a concaved side of the kidney that has a depression where a renal artery enters, and a renal vein and a ureter exit the kidney. The kidneys are located at the rear wall of the abdominal cavity just above the waistline, and are protected by the ribcage. They are considered retroperitoneal, which means they lie behind the peritoneum. There are three major regions of the kidney, renal cortex, renal medulla and the renal pelvis. The outer, granulated layer is the renal cortex. The cortex stretches down in between a radially striated inner layer. The inner radially striated layer is the renal medulla. This contains pyramid shaped tissue called the renal pyramids, separated by renal columns. The ureters are continuous with the renal pelvis and is the very center of the kidney. 1. Renal pyramid 2. Interlobar artery 3. Renal artery 4. Renal vein 5. Renal hilum 6. Renal pelvis 7. Ureter 8. Minor calyx 9. Renal capsule 10. Inferior renal capsule 11. Superior renal capsule 12. Interlobar vein 13. Nephron 14. Minor calyx 15. Major calyx 16. Renal papilla 17. Renal column.

Renal Vein

The renal veins are veins that drain the kidney. They connect the kidney to the inferior vena cava. Because the inferior vena cava is on the right half of the body, the left renal vein is generally the longer of the two. Unlike the right renal vein, the left renal vein often receives the left gonadal vein (left testicular vein in males, left ovarian vein in females). It frequently receives the left suprarenal vein as well.

Renal Artery

The renal arteries normally arise off the abdominal aorta and supply the kidneys with blood. The arterial supply of the kidneys are variable and there may be one or more renal arteries supplying each kidney. Due to the position of the aorta, the inferior vena cava and the kidneys

in the body, the right renal artery is normally longer than the left renal artery. The right renal artery normally crosses posteriorly to the inferior vena cava. The renal arteries carry a large portion of the total blood flow to the kidneys. Up to a third of the total cardiac output can pass through the renal arteries to be filtered by the kidneys.

Ureters

The ureters are two tubes that drain urine from the kidneys to the bladder. Each ureter is a muscular tube about 10 inches (25 cm) long. Muscles in the walls of the ureters send the urine in small spurts into the bladder, (a collapsible sac found on the forward part of the cavity of the bony pelvis that allows temporary storage of urine). After the urine enters the bladder from the ureters, small folds in the bladder mucosa act like valves preventing backward flow of the urine. The outlet of the bladder is controlled by a sphincter muscle. A full bladder stimulates sensory nerves in the bladder wall that relax the sphincter and allow release of the urine. However, relaxation of the sphincter is also in part a learned response under voluntary control. The released urine enters the urethra. Urinary Bladder The urinary bladder is a hollow, muscular and distensible or elastic organ that sits on the pelvic floor (superior to the prostate in males). On its anterior border lies the pubic symphysis and, on its posterior border, the vagina (in females) and rectum (in males).

The urinary bladder

The urinary bladder can hold approximately 17 to 18 ounces (500 to 530 ml) of urine, however the desire to micturate is usually experienced when it contains about 150 to 200 ml. When the bladder fills with urine (about half full), stretch receptors send nerve impulses to the spinal cord, which then sends a reflex nerve impulse back to the sphincter (muscular valve) at the neck of the bladder, causing it to relax and allow the flow of urine into the urethra. The Internal urethral sphincter is involuntary. The ureters enter the bladder diagonally from its dorsolateral floor in an area called the trigone. The trigone is a triangular shaped area on the postero-inferior wall of the bladder. The urethra exits at the lowest point of the triangle of the trigone. The urine in the bladder also helps regulate body temperature. If the bladder becomes completely void of fluid, it causes the patient to chill.

The urethra

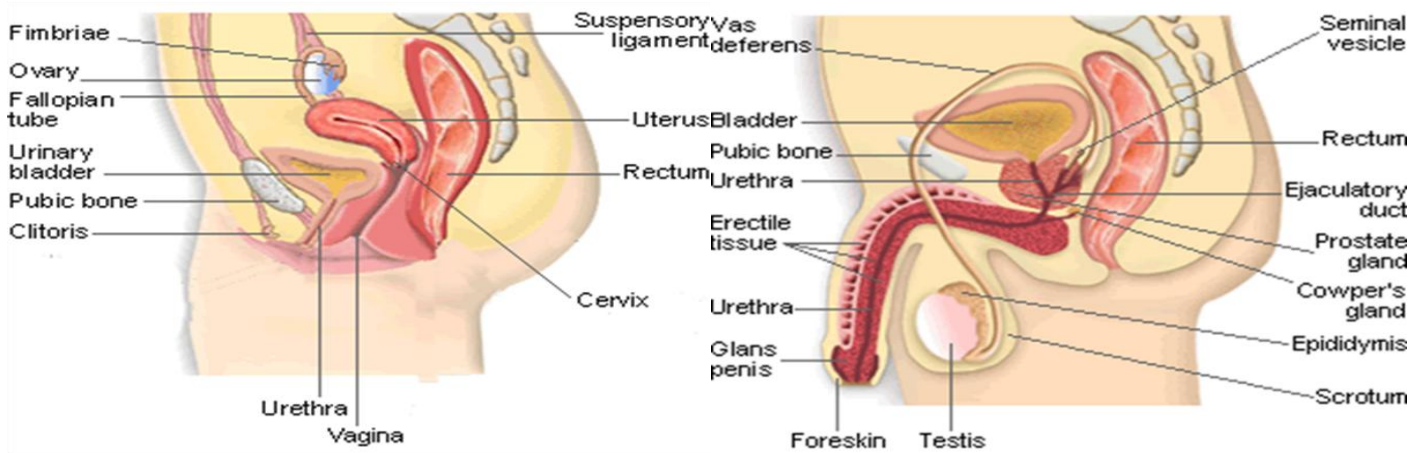
The urethra is a muscular tube that connects the bladder with the outside of the body. The function of the urethra is to remove urine from the body. It measures about 1.5 inches (3.8 cm) in a woman but up to 8 inches (20 cm) in a man. Because the urethra is so much shorter in a woman it makes it much easier for a woman to get harmful bacteria in her bladder this is commonly called a bladder infection or a UTI. The most common bacteria of a UTI is E-coli from the large intestines that have been excreted in fecal matter.

Female urethra in the human female, the urethra is about 1-2 inches long and opens in the vulva between the clitoris and the vaginal opening. Men have a longer urethra than women. This means that women tend to be more susceptible to infections of the bladder (cystitis) and the urinary tract.

Male urethra in the human male, the urethra is about 8 inches long and opens at the end of the head of the penis. The length of a male's urethra, and the fact it contains a number of bends, makes catheterisation more difficult.

The urethral sphincter is a collective name for the muscles used to control the flow of urine from the urinary bladder. These muscles surround the urethra, so that when they contract, the urethra is closed.

- There are two distinct areas of muscle: the internal sphincter, at the bladder neck and • the external, or distal, sphincter. Human males have much stronger sphincter muscles than females, meaning that they can retain a large amount of urine for twice as long, as much as 800mL, i.e . "hold it".



Nephrons

The filtering units of the kidneys is the nephrons. There are approximately one million nephrons in each kidney. The nephrons are located within the cortex and medulla of each kidney.

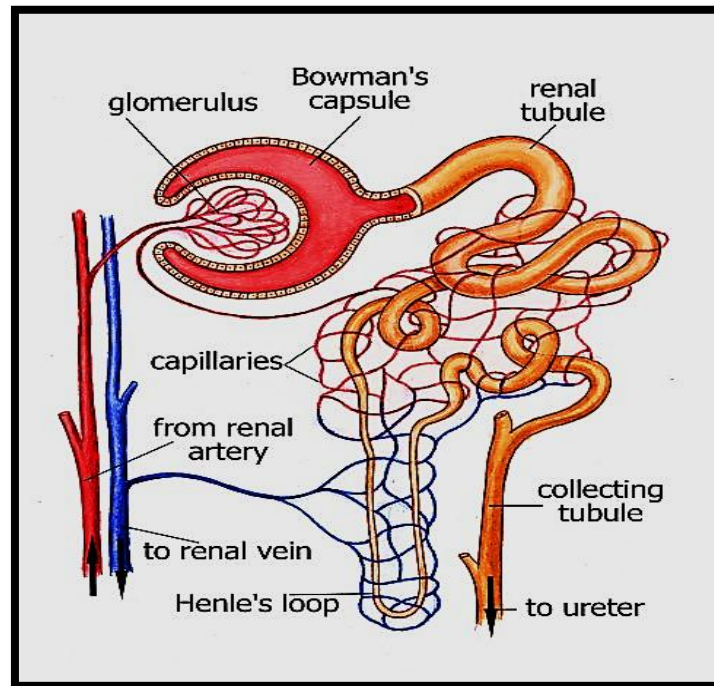
The tubes of the nephron are surrounded by cells and a network of blood vessels spreads throughout the tissue. Therefore, material that leaves the nephron enters the surrounding cells and returns to the bloodstream by a network of vessels.

Parts of the Nephron

Each nephron consists of the following parts:

- 1) glomerulus
- 2) Bowman's capsule
- 3) proximal tubule

- 4) loop of Henle
- 5) distal tubule
- 6) collecting duct



The **glomerulus** is a mass of thin-walled capillaries.

The **Bowman's capsule** is a double-walled, cup-shaped structure.

The **proximal tubule** leads from the Bowman's capsule to the Loop of Henle.

The **loop of Henle** is a long loop which extends into the medulla.

The **distal tubule** connects the loop of Henle to the collecting duct.

Function of the Kidney

The principal function of the kidney is to filter blood to remove cellular waste products from the body. At any given time, 20 % of blood is in the kidneys. Humans can function with one kidney.

The kidney has other functions but it is usually associated with the excretion of cellular waste such as:

- 1) urea (a nitrogenous waste produced in the liver from the breakdown of protein. It is the main component of urine).
 - 2) uric acid (usually produced from breakdown of DNA or RNA).
 - 3) creatinine (waste product of muscle action).
- All these compounds have nitrogen as a major component.
 - The kidneys are more than excretory organs.
 - They are one of the major homeostatic organs of the body.
 - They control blood pH
 - Secrete erythropoietin (a hormone that stimulates red blood cell production)
 - Activate vitamin D production in the skin.

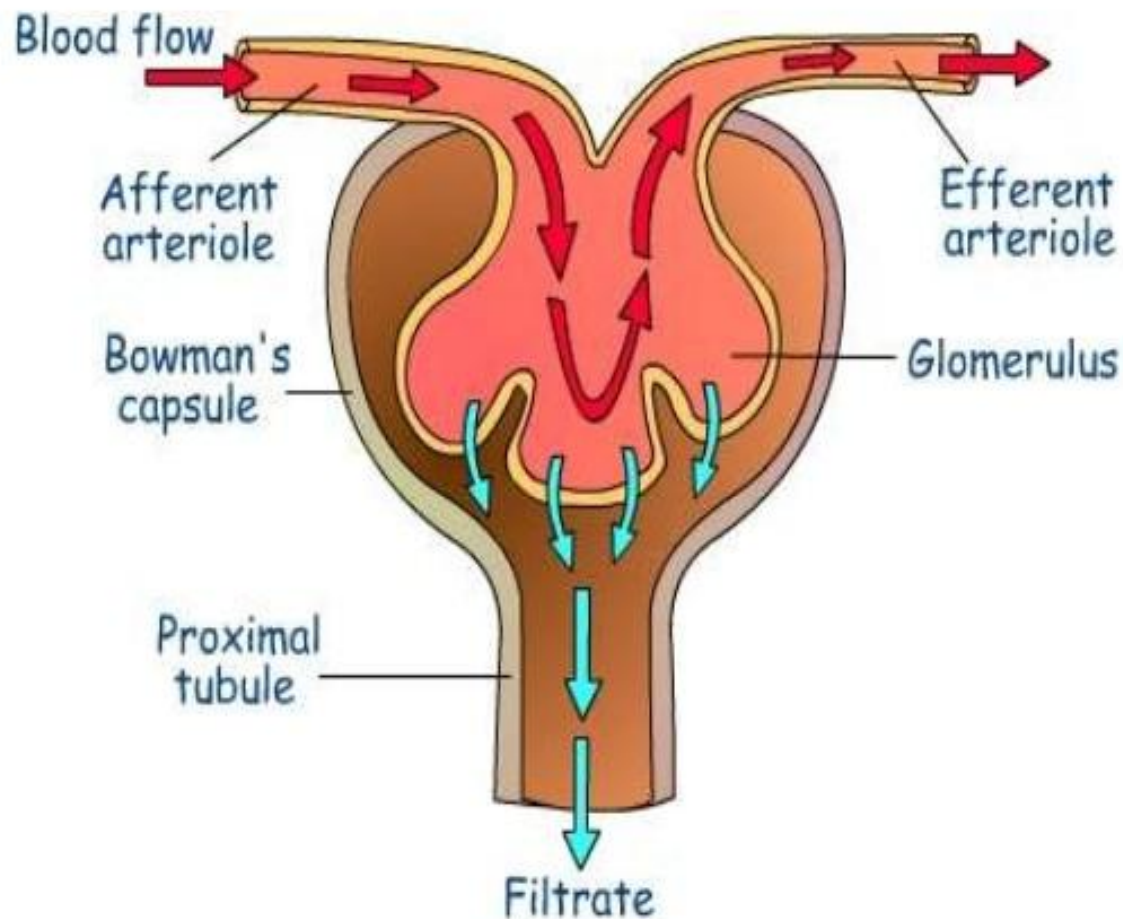
Formation of Urine

Urine is formed in three steps: Filtration, Reabsorption, and Secretion.

Filtration Blood enters the afferent arteriole and flows into the glomerulus. Blood in the glomerulus has both filterable blood components and non-filterable blood components. Filterable blood components move toward the inside of the glomerulus while non-filterable blood components bypass the filtration process by exiting through the efferent arteriole. Filterable Blood components now take on plasma like form called glomerular filtrate. A few of the filterable blood components are water, nitrogenous waste, nutrients and salts (ions). Nonfilterable blood components include formed elements such as blood cells and platelets along with plasma proteins. The glomerular filtrate is not the same consistency as urine, as much of it is reabsorbed into the blood as the filtrate passes through the tubules of the nephron.

Reabsorption Within the peritubular capillary network, molecules and ions are reabsorbed back into the blood. Sodium Chloride reabsorbed into the system increases the osmolarity of blood in comparison to the glomerular filtrate. This reabsorption process allows water (H₂O) to pass from the glomerular filtrate back into the circulatory system. Glucose and various amino acids also are reabsorbed into the circulatory system. These nutrients have carrier molecules that claim the glomerular molecule and release it back into the circulatory system. If all of the carrier molecules are used up, excess glucose or amino acids are set free into the urine. A complication of diabetes is the inability of the body to reabsorb glucose. If too much glucose appears in the glomerular filtrate, it increases the osmolarity of the filtrate, causing water to be released into the urine rather than reabsorbed by the circulatory system. Frequent urination and unexplained thirst are warning signs of diabetes, due to water not being reabsorbed. Glomerular filtrate has now been separated into two forms: Reabsorbed Filtrate and Non-reabsorbed Filtrate. Non-reabsorbed filtrate is now known as tubular fluid as it passes through the collecting duct to be processed into urine.

Secretion Some substances are removed from blood through the peritubular capillary network into the distal convoluted tubule or collecting duct. These substances are Hydrogen ions, creatinine, and drugs. Urine is a collection of substances that have not been reabsorbed during



21

Glomerular filtration

Glomerular filtration occurs when blood enters the glomerulus through the afferent arteriole. Due to glomerular blood pressure, water and small solutes (such as glucose, amino acids, nitrogenous wastes and ions) present in blood move from the glomerulus to the inside of the glomerulus capsule. This is a filtration process because large molecules (such as proteins) and formed elements (blood cells and platelets) are unable to pass through the capillary wall. The filtered fluid (called the glomerular filtrate) is essentially protein-free and devoid of cells. On an average, the daily volume of glomerular filtrate is about 180 L in adult males and 150 L in adult females. More than 99% of the glomerular filtrate returns to the bloodstream via tubular reabsorption, so only 1-1.5 L is excreted as urine. The volume of fluid filtered by the renal corpuscle is much larger than in other capillaries of the body for three reasons:

1. Glomerular capillaries present a large surface area for filtration because they are long.
2. The filtration membrane (the endothelial cells of glomerular capillaries and the podocytes, which completely encircle the capillaries, form a leaky barrier known as the filtration membrane) is thin and porous.

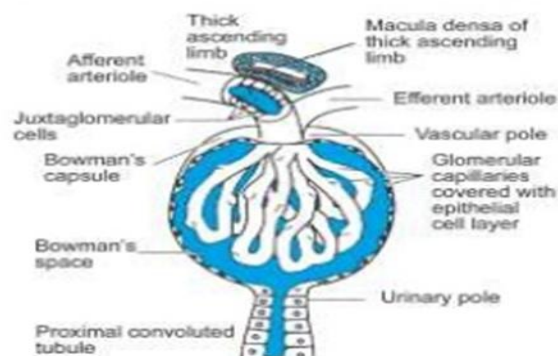
3. Glomerular capillary blood pressure is high. Because the efferent arteriole is smaller in diameter than the afferent arteriole.

Glomerular filtration rate (GFR)

The amount of filtrate formed in all the renal corpuscles of both kidneys per minute is called GFR. The GFR in a healthy individual is approximately 125 ml/minute (7.5 L/hr or 180 L/day). The GFR is determined by the net filtration pressure and the glomerular filtration coefficient. The net filtration pressure represents the sum of the hydrostatic and colloid osmotic pressures that either favour or oppose filtration across the glomerular capillaries. Glomerular hydrostatic pressure is the blood pressure in glomerular capillaries. It is about 55 mm Hg. It promotes filtration by forcing water and solutes present in blood plasma to pass through the filtration membrane. Capsular hydrostatic pressure is the hydrostatic pressure exerted against the filtration membrane by fluid already present in the capsular space. It opposes filtration. Its value is about 15 mm Hg. Blood colloid osmotic pressure is the pressure develops due to the pressure of proteins such as albumin, globulins and fibrinogen in blood plasma. Because plasma proteins cannot be filtered, they are in the glomerular capillaries but not in Bowman's capsule. Blood colloid osmotic pressure also opposes filtration. Its value in glomerular capillaries is about 30 mm Hg. Net filtration pressure: The force favoring filtration is the glomerular hydrostatic pressure which is about 55 mm Hg. The total of the two forces opposing filtration is about 45 mm Hg. The net difference favoring filtration (about 10 mm Hg) is called net filtration pressure.

Introduction

❖ Glomerular filtration rate (GFR):



- Rate at which plasma is filtered from the glomerular capillaries into bowman's capsule per unit time.
- In average, GFR is about 125ml/min or 180 l/day and filtration fraction is about 0.2(20%)

Regulation of Glomerular filtration rate (GFR)

The mechanisms that regulate glomerular filtration rate operate in two main ways: (1) By adjusting blood flow into and out of the glomerulus. GFR increases when blood flow into the glomerular capillaries increases. (2) By altering the glomerular capillary surface area available for filtration. Coordinated control of the diameter of both afferent and efferent arterioles regulates glomerular blood flow. Constriction of the afferent arteriole decreases blood flow into the glomerulus; dilation of the afferent arteriole increases it. Three mechanisms control GFR: renal autoregulation, neural regulation, and hormonal regulation. (A) Renal autoregulation The kidneys themselves help maintain a constant renal blood flow and GFR despite normal, everyday changes in blood pressure, like those that occur during exercise. This capability is called renal autoregulation and consists of two mechanisms—the myogenic mechanism and tubuloglomerular feedback. A1. Myogenic autoregulation: Myogenic constriction of the afferent arteriole occurs due to the ability of the smooth muscle to sense and respond to an increase in arterial pressure. As blood pressure rises, GFR also rises because renal blood flow increases. However, the elevated blood pressure stretches the walls of the afferent arterioles. In response, smooth muscle fibers in the wall of the afferent arteriole contract, which narrows the arteriole's lumen. As a result, renal blood flow decreases, thus reducing GFR to its previous level. Conversely, when arterial blood pressure drops, the smooth muscle cells are stretched less and thus relax. The afferent arterioles dilate, renal blood flow increases, and GFR increases. The myogenic mechanism normalizes renal blood flow and GFR within seconds after a change in blood pressure. A2. Tubuloglomerular feedback: It is so named because part of the renal tubules—the macula densa—provides feedback to the glomerulus. When GFR is above normal due to elevated systemic blood pressure, filtered fluid flows more rapidly along the renal tubules. As a result, the proximal convoluted tubule and loop of Henle have less time to reabsorb Na^+ , Cl^- , and water. Macula densa cells are thought to detect the increased delivery of Na^+ , Cl^- , and water and to inhibit release of nitric oxide (NO) from cells in the juxtaglomerular apparatus (JGA).⁵ Because NO causes vasodilation, afferent arterioles constrict when the level of NO declines. As a result, less blood flows into the glomerular capillaries, and GFR decreases. When blood pressure falls, causing GFR to be lower than normal, the opposite sequence of events occurs, although to a lesser degree. Tubuloglomerular feedback operates more slowly than the myogenic mechanism. (B) Neural regulation All the blood vessels of the kidneys, including the afferent and the efferent arterioles, are richly innervated by sympathetic nerve fibres. Activation of renal sympathetic nerves releases norepinephrine. Norepinephrine causes vasoconstriction of afferent arterioles and thus decreases the GFR. (C) Hormonal regulation Two hormones contribute to regulation of GFR. Angiotensin II reduces GFR; atrial natriuretic peptide (ANP) increases GFR. Angiotensin II is a very potent vasoconstrictor that narrows both afferent and efferent arterioles and reduces renal blood flow, thereby decreasing GFR. Cells in the atria of the heart secrete atrial natriuretic peptide (ANP). Stretching of the atria, as occurs when blood volume increases, stimulates

secretion of ANP. By causing relaxation of the glomerular mesangial cells, ANP increases the capillary surface area available for filtration. Glomerular filtration rate rises as the surface area increases.

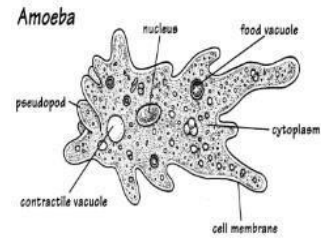
Cytology

Part

Cytology

Organisms and Cells

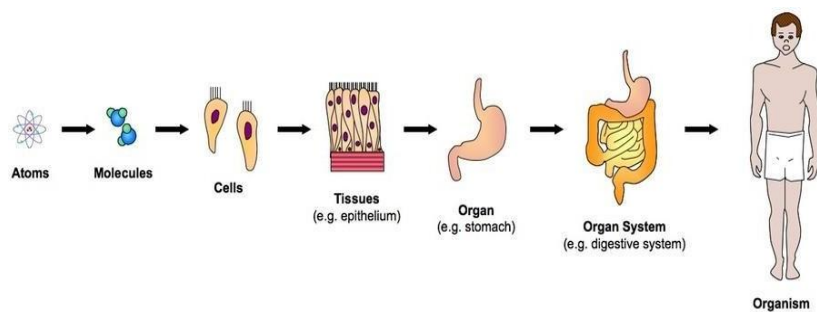
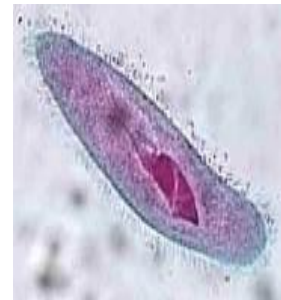- Some organisms are unicellular.
 - This means they are made of only one cell.
 - Examples: bacteria, yeast
- Some organisms are multicellular.
 - This means they are made of many cells.
 - Examples: humans, trees



40

Organisms and Cells

- Unicellular organisms have nothing but a single cell.
- However, multicellular organisms have many more levels of organization to make sure the whole body can work correctly, even when it is doing many things at the same time.



41

There are 5 Levels of Organization in Multicellular Organisms:

- 1. Cells
- 2. Tissues
- 3. Organs
- 4. Organ Systems
- 5. Organisms

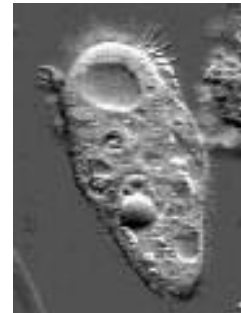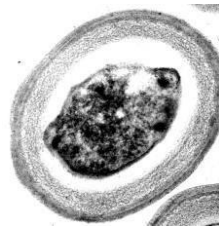42

The CELL

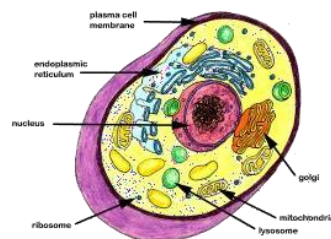
The cell is the basic unit of life.

Cells are specialized by size and shape for the job they do.

Example: skin cell



The paramecium above is made of only one cell and it must perform all the jobs of the organism.

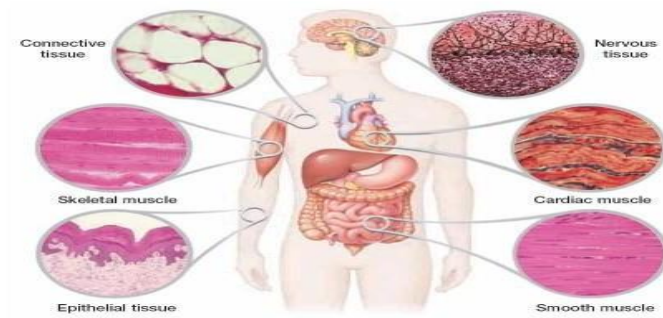

43

TISSUES

Tissues are made of the same type of cells grouped together to do a specific job.

Human Body Tissues



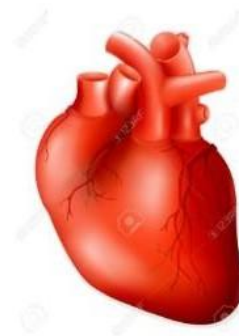Example: Humans have four kinds of tissue in their Bodies: Epithelia, Muscle, Connective, and Nerve.



Organs

Organs are made up of different tissues that work together to do a job.

Example: a heart is an organ .

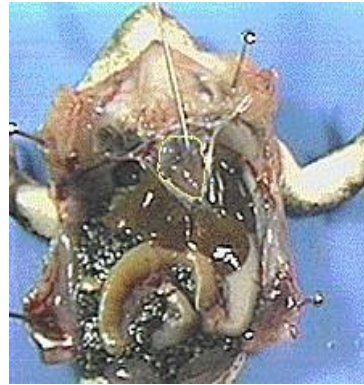

Organ Systems

An organ system is a group of organs working together.

Examples:

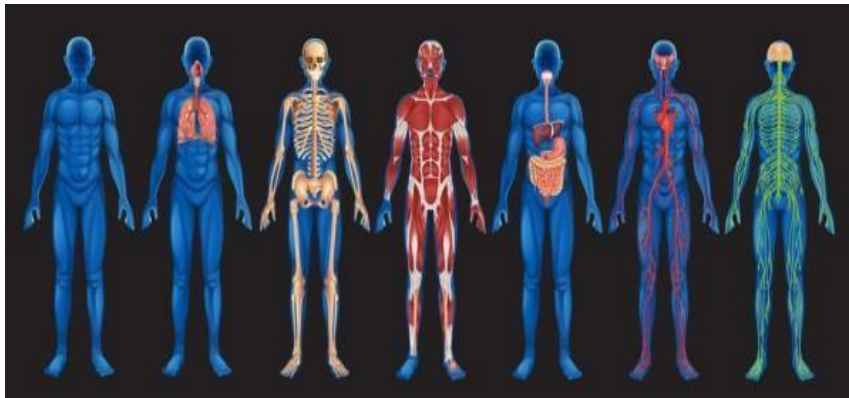
- Human organ systems include circulatory, reproductive, digestive, nervous, respiratory.
- Plant organ system-roots, stems, leaves= transport system.



46

Organisms

All cells, tissues, organs and organ systems working together makes an organism.



Example: a human

The Cell Theory

The cell theory (proposed independently in 1838 and 1839) is a cornerstone of biology.

All organisms are composed of one or more cells.

Cells are the smallest living things.

Cells arise only by division of previously existing cells.

All organisms living today are descendants of an ancestral cell.



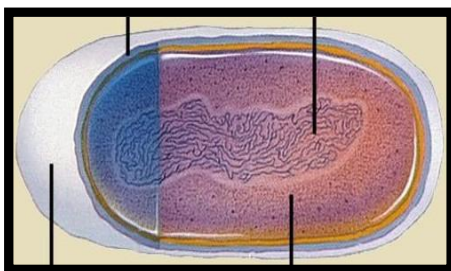
Schleiden



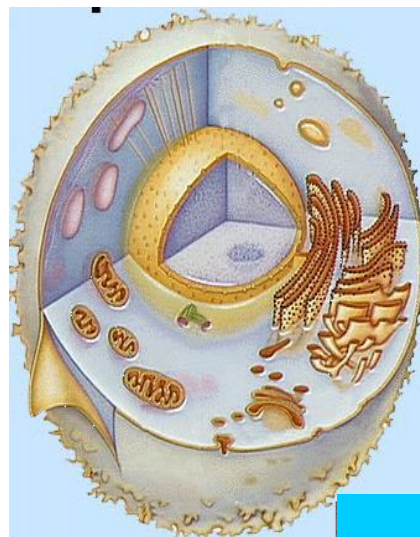Schwann

48

Two Fundamentally Different Types of Cells










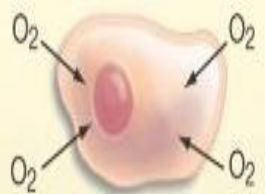


A prokaryotic cell



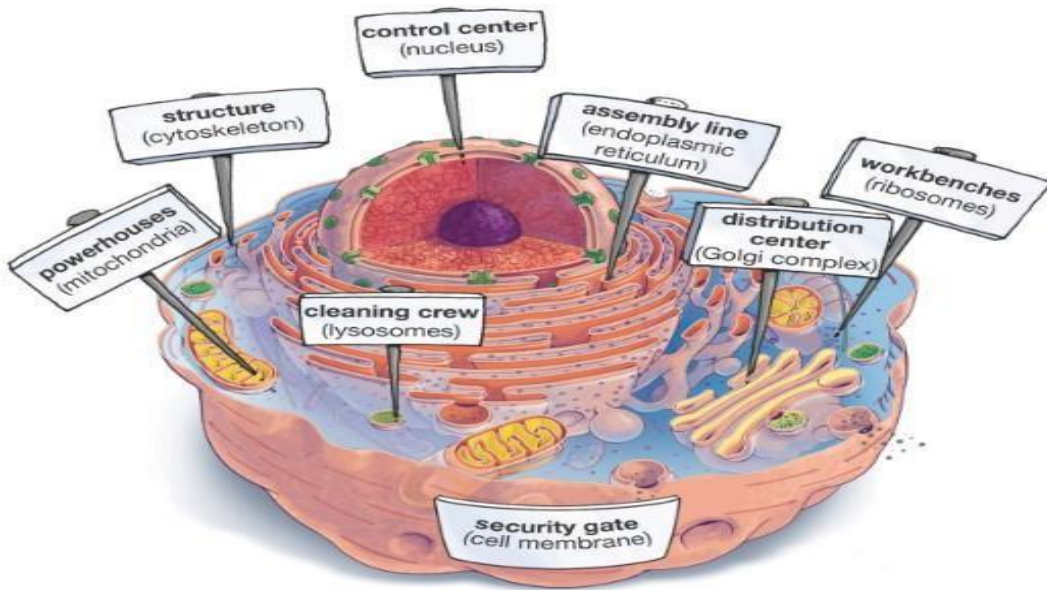
A eukaryotic cell

49

Us vs. Them -Eukaryotes and Prokaryotes

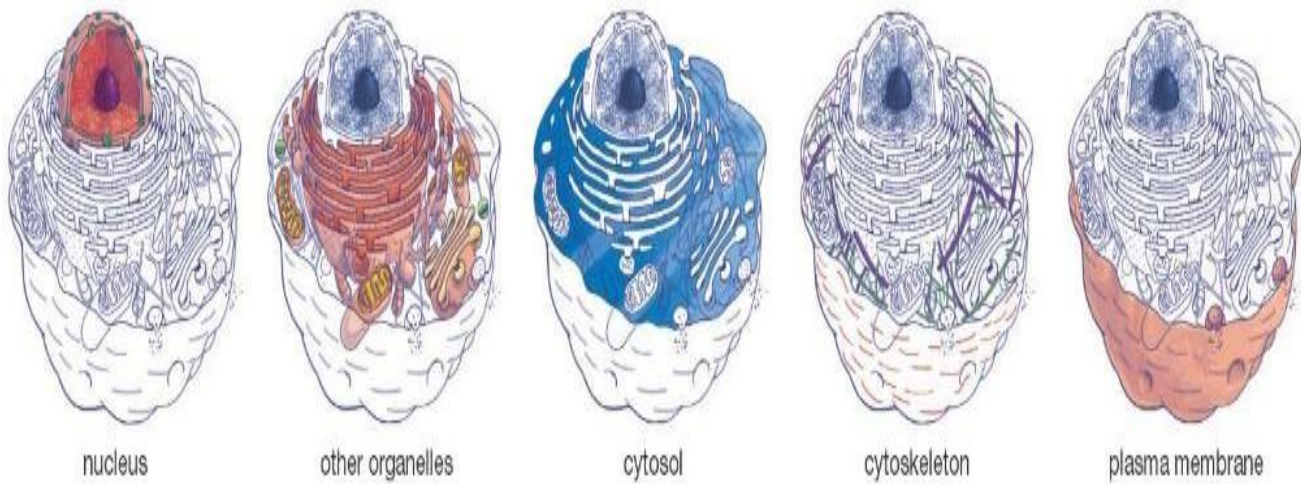
	Prokaryotes	Eukaryotes
DNA	 <p>in "nucleoid" region</p>	 <p>within membrane-bound nucleus</p>
Size	 <p>usually smaller</p>	 <p>usually larger</p>
Organization	 <p>usually single-celled</p>	 <p>often multicellular</p>
Metabolism	 <p>may not need oxygen</p>	 <p>usually need oxygen to exist</p>
Organelles	 <p>no membrane-bound organelles</p>	 <p>membrane-bound organelles</p>

An Idealized Animal Cell



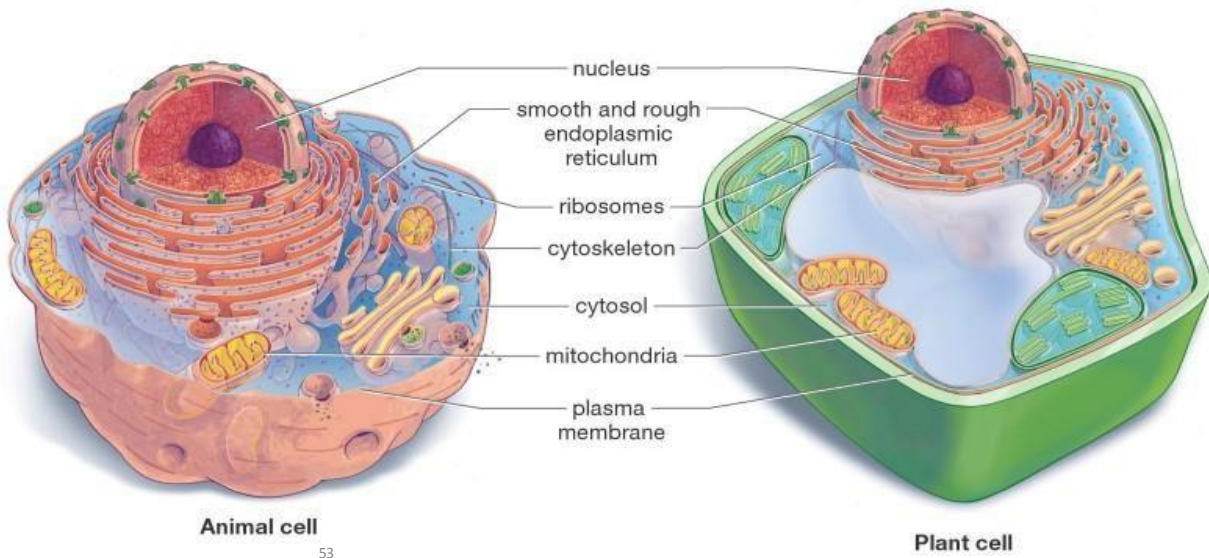
51

Major Divisions of the Eukaryotic Cell



52

Animal and Plant Cells Have More Similarities Than Differences

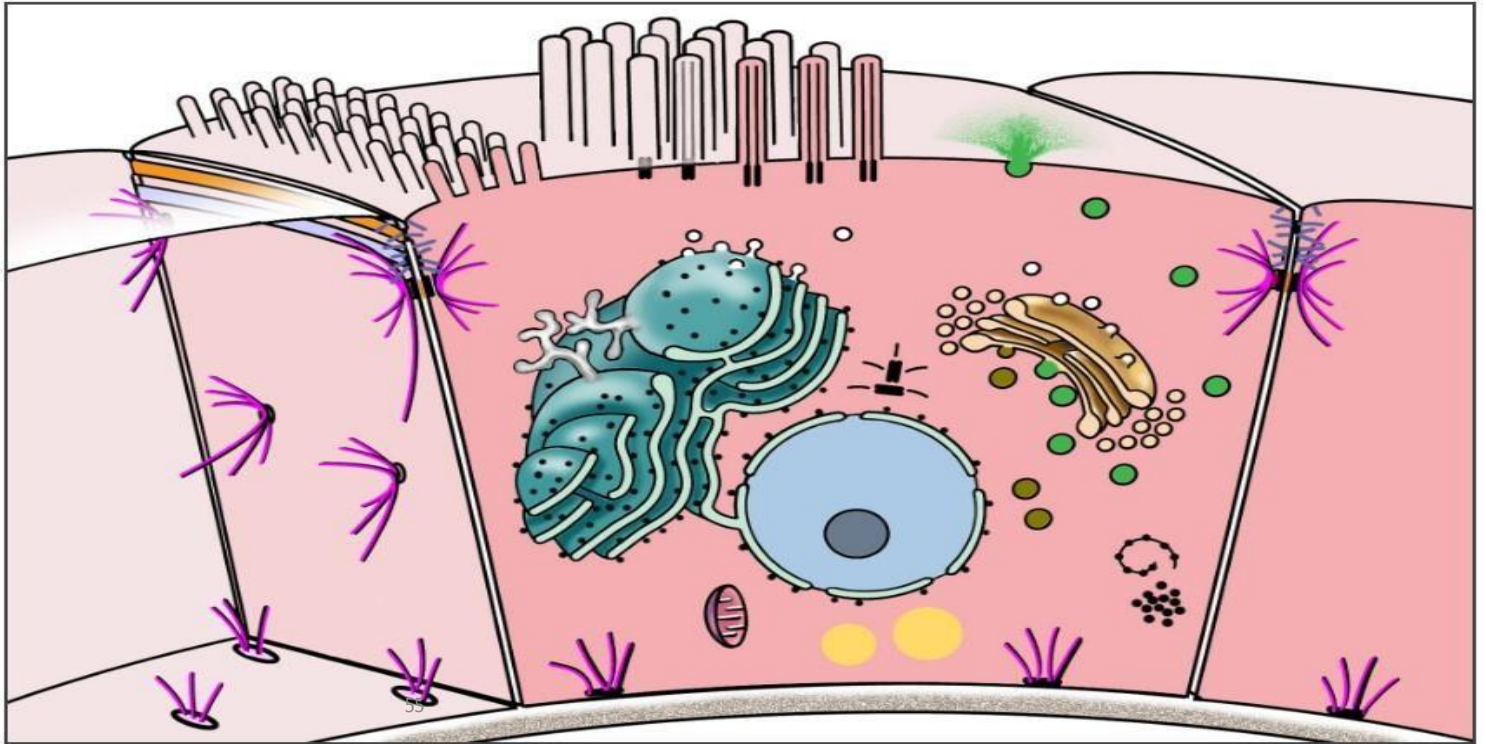


- Give the function (job) of each organelle below

- | | |
|--------------------------|-----------------|
| a. Nucleus | e. Golgi body |
| b. Cell membrane | f. Vacuole |
| c. Mitochondrion | g. Lysosome |
| d. Endoplasmic reticulum | h. Cytoskeleton |

- Overview of cell structures

- The cell consists of two major compartments, cytoplasm and nucleus. Located throughout the cytoplasm are membranous organelles, e.g., endoplasmic reticulum, lysosomes and mitochondria, as well as non-membranous organelles, e.g., polysomes and centrioles. The nucleus is surrounded by two membranes which are continuous with the endoplasmic reticulum.



- **Cells are the structural units of all living organisms .**
- Although there are approximately 200 different cell types in the body, cells are more alike than different. Specialization of function, (e.g., glandular cells for secretion or muscle cells for contraction) is really an emphasis of a function that all cells possess to some degree. In some cases, cells have become so specialized that some functions are lost altogether (e.g., cell proliferation).
- Cells vary in size and shape according to location and function .
- Cells widely vary in diameter, from the largest, the mature human ovum (120 microns) to the smallest, the red blood cell (7-8 microns).
- Cells vary in internal structure depending upon their function . Specialized cells possess abundant internal structures related to their specific function, e.g., contractile filaments in muscle cells or secretory granules in gland cells.
- Cells vary in their life his₅tory, for example, rates of cell renewal.

Functions of cells

As you already know that a cell is a structural and functional unit of living. Let us study 6 of the most vital functions performed by a cell.

1- Structure and Support

You know a house is made of bricks. Similarly, an organism is made up of cells. Though there are certain cells such as collenchyma and sclerenchyma are present for offering structural support however in general too, all cells generally provide the structural basis of all organisms.

2- Growth

In complex organisms such as humans, the tissues grow by simple multiplication of cells. Hence, cells are responsible for the growth of the organism. The entire thing takes place via a process of mitosis.

3- Transport

Cells import the nutrients that are used in the different chemical process which take place inside them. As a result of these processes, a waste product is produced. Cells then work to get rid of this waste. In this manner, the small molecules like such as oxygen, carbon dioxide, and ethanol pass through the cell membrane by

diffusion. This method is known as passive transport. On the other hand, the larger molecules like the proteins and polysaccharides, go in and out of the cell via active transport.

4- Energy Production

Organisms need energy to perform different chemical reactions. In plants, the energy comes from the process of photosynthesis while in the animals the energy comes via respiration.

5- Metabolism

Cell is responsible for metabolism that includes all the chemical reactions that take place inside an organism to keep it alive.

6- Reproduction

A cell helps in reproduction by the processes of mitosis (in more evolved organisms) and meiosis.

- **Chemical Composition of the Cell**

Chemical compounds in the cell can be divided into two major groups : Organic and Inorganic compounds

Organic compounds are chemical compounds that contain the element carbon. Organic compounds in the cell include carbohydrates, protein, lipids and nucleic acids. Some of these compounds are synthesized by the cell itself.

Water is an inorganic compound which is composed of hydrogen and oxygen . It is an important compound in the cell.

Table : inorganic chemical compounds in the cell.

Percentage of Body Weight	Element	Usage
65%	Oxygen	This element is obviously the most important element in the human body. Oxygen atoms are present in water, which is the compound most common in the body, and other compounds that make up tissues. It is also found in the blood and lungs due to respiration.
18.6%	Carbon	Carbon is found in every organic molecule in the body, as well as the waste product of respiration (carbon dioxide). It is typically ingested in food that is eaten.

9.7%	Hydrogen	Hydrogen is found in all water molecules in the body as well as many other compounds making up the various tissues.
3.2%	Nitrogen	Nitrogen is very common in proteins and organic compounds. It is also present in the lungs due to its abundance in the atmosphere.
1.8%	Calcium	Calcium is a primary component of the skeletal system, including the teeth. It is also found in the nervous system, muscles, and the blood.
1.0%	Phosphorus	This element is common in the bones and teeth, as well as nucleic acids.
0.4%	Potassium	Potassium is found in the muscles, nerves, and certain tissues.
0.2%	Sodium	Sodium is excreted in sweat, but is also found in muscles and nerves.
0.2%	Chlorine	Chlorine is present in the skin and facilitates water absorption by the cells.
0.06%	Magnesium	Magnesium serves as a cofactor for various enzymes in the body.
0.04%	Sulfur	Sulfur is present in many amino acids and proteins.
0.007%	Iron	Iron is found mostly in the blood since it facilitates the transportation of oxygen.
0.0002%	Iodine	Iodine is found in certain hormones in the thyroid gland.

- **The Importance of Organic Compounds in the Cell**

- **Carbohydrates**

- Supply energy for cell processes
- A means of storing energy
- Give structural support to cell walls

- **Lipids**

- Store large amounts of energy over long periods of time
- Act as an energy source
- Play a major role in the structure of the cell membranes
- Act as a source of metabolic water
- Reduce the loss of water by evaporation

62

- **Proteins**

- Act as building blocks of many structural components of the cell ; required for growth
- Form enzymes which catalyze chemical reactions
- Form hormones which control growth and metabolism

- **Nucleic acids**

- Contain the genetic information of cells
- Play a vital role in protein synthesis

63

- **The importance of water in the cell**

- Water is important for life because its chemical and physical properties allow it to sustain life.
- Water is a polar molecule which consists of 2 hydrogen atoms and 1 oxygen atom. A polar molecule is a molecule with an unequal distribution of charges. Each molecule has a positively charged and a negatively charged end. Polar molecules attract one another as well as ions. Because of this property, water is considered the solvent of life.
- It is the transport medium in the blood.
- It acts as a medium for biochemical reactions.
- Water helps in the maintenance of a stable internal environment within a living organism. The concentration of water and inorganic salts that dissolve in water is important in maintaining the osmotic balance between the blood and interstitial fluid.
- It helps in lubrication.
- Water molecules have very high cohesion. Water molecules tend to stick to each other and move in long unbroken columns through the vascular tissues in plants.

Quick review

Definition of a cell	Smallest functional unit within a living organism that can function independently
Components	Plasma membrane, cytoplasm, nucleus, membranous organelles, non-membranous organelles
Membranous organelles	Nucleus, Endoplasmic reticulum, Golgi apparatus, mitochondria, peroxisomes, lysosomes, transport vesicles
Non-membranous organelles	Ribosomes, microtubules, cytoskeleton (actin filaments, intermediate filaments, centrioles)

- ✓ The cell is the structural and functional unit of all tissues. It consists of a mass of protoplasm divided into nucleus and cytoplasm. The cytoplasm is the part of protoplasm located around the nucleus designed to perform synthetic and metabolic activities.
- ✓ The cytoplasmic matrix (cytosol) is the non-organelle component of the cytoplasm occupying the intracellular spaces between organelles and inclusions. It contains any soluble proteins, lipids, carbohydrates and small ions.
- ✓ Cytoplasmic Organelles

They are permanent, living cytoplasmic structures that perform specific functions. Two types of cytoplasmic organelles are recognized: membranous and non-membranous organelles.

► Membranous organelles

The membranous organelles are cytoplasmic organelles that possess a bounding membrane of their own and they include cell membrane, mitochondria, endoplasmic reticulum, Golgi apparatus, lysosomes, and peroxisomes.

1- Cell membrane

The cell membrane (plasmalemma or plasmamembrane) is the outer membrane of the cell that acts as a barrier between its internal and external environment.

With light microscope (LM) it is too thin (8-10 nm) to be seen. The cell boundary that is often seen is mainly due to condensation of cytoplasm on the inner aspect of the cell membrane, condensation of the stain (such as silver or PAS) on the carbohydrate-rich coat and obliquity of the sections.

With electron microscope (EM) it appears as a trilaminar structure consisting of outer and inner electron-dense layers separated by an intermediate electron-lucent layer.

The molecular structure of the cell membrane

The most recent and currently acceptable model for the cell membrane is the

Fluid mosaic model

According to this model, the cell membrane is made up of three major components phospholipids, proteins, and carbohydrates.

The phospholipids molecules form a central bimolecular layer. Each molecule is formed of two ends; polar or hydrophilic (has affinity with water) end, and non-polar or hydrophobic (has no affinity with water) tail. The phospholipids molecules are arranged with their hydrophilic ends are directed outward, while hydrophobic tails are directed inward toward the center of the membrane.

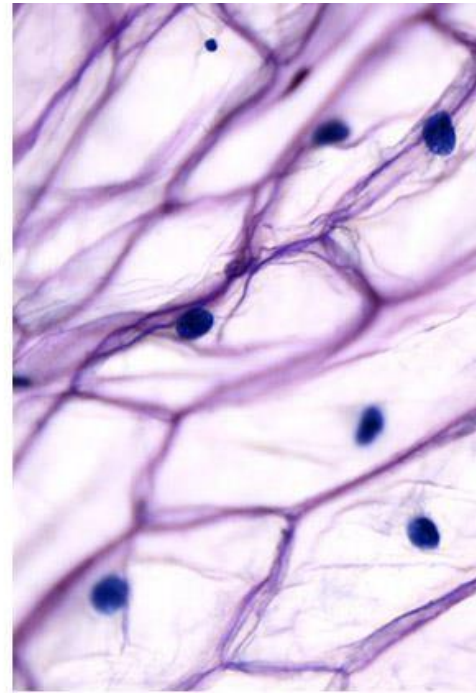
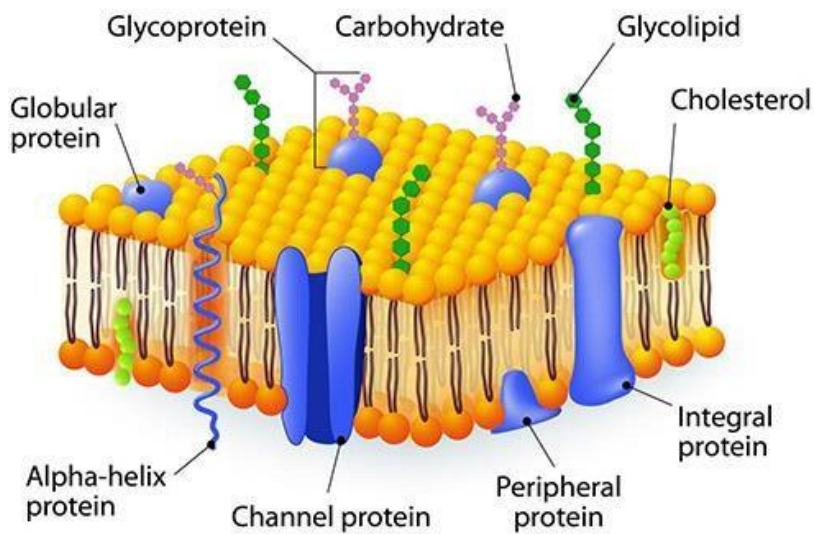
The protein is the second major constituent of the cell membrane. The protein molecules are arranged as globules moving freely within the lipid layer. Two types of protein globules are recognized: intrinsic or integral protein and extrinsic or peripheral proteins.

The intrinsic proteins are firmly attached to the lipid bilayer. Some of them extend throughout the entire thickness of the membrane and constitute transmembrane channels for the passage of water-soluble ions and molecules

The extrinsic or peripheral proteins are only partially embedded to either aspect of the membrane.

The carbohydrate fractions are conjugated with the protein (glycoprotein) and lipid (glycolipid) molecules of the cell membrane. These glycoproteins and glycolipids project from the outer surface of the cell membrane as cell coat or glycocalyx.

CELL MEMBRANE



Functions of the cell membrane

The cell membrane is the part of the cell that regulate the exchange of molecules and ions between its internal and external environment. This occurs by several ways:

1. **Passive Diffusion:** this involves the entrance of small molecules into the cytoplasm. It depends on the presence of a concentration gradient across the plasmalemma (e.g., diffusion of lipid soluble substances, oxygen, CO₂, water and small ions).
2. **Facilitated Diffusion:** this type of diffusion is also concentration-dependent and involves the transport of large water-soluble molecules such as glucose and amino acids. It requires the presence of carriers to which the molecules have to bind in order to pass through the plasmalemma.
3. **Active Transport:** this process requires the utilization of energy provided as ATP. (e.g., sodium-potassium pump).
4. **Selective transport:** it depends on the presence of specific cell surface receptors to pick up specific molecules into the cytoplasm (e.g., hormones).

5. Endocytosis and Exocytosis

Endocytosis involves either the engulfment of solid particles (phagocytosis) or minute droplet of fluid (pinocytosis). The engulfed material is surrounded first by cytoplasmic extensions called pseudopodia. When the particles become surrounded, the plasma membrane fuses and the membrane surrounding the engulfed particles forms a vesicle, known as a phagosome or endocytotic vesicle, which detaches from the cell membrane to float freely within the cytoplasm.

Once the phagosome enters the cytoplasm it fuses with the lysosomes and their contents are subjected to enzymatic digestion.

6. Exocytosis

Exocytosis (Exo = out) is the process by which some membranous vesicles located within the cytoplasm fuse with the plasma membrane and release their contents outside the cell. It occurs in many secretory processes.

Functions of the cell coat (Glycocalyx)

- Mechanical and chemical protection the cell membrane.
- Aids in the induction of immunological (antigen-antibody) response.
- Site for binding of hormones.
- Shares in the formation of intercellular adhesions.
- Contributes to the formation of the basement membrane.
- Cell recognition.

Other functions of the cell membrane include

- Transmission of nerve impulses in muscle and nerve cells.
- Myelin sheath formation (Schwan cell around peripheral nerves).
- Share in the formation of microvilli, cilia, flagella and cell junctions.

2- Mitochondria

Mitochondria are membranous organelles involved primarily in cell respiration and energy production.

With LM, they appear as granules, rod-like or thread-like. Their size range from 5-10 μm length and 0.5-1 μm in diameter. The number is highly variable according to the energy requirements of the cells. Liver cells (active cells) contain as many as 1000 mitochondria. Small lymphocytes (inactive cells) contain very few.

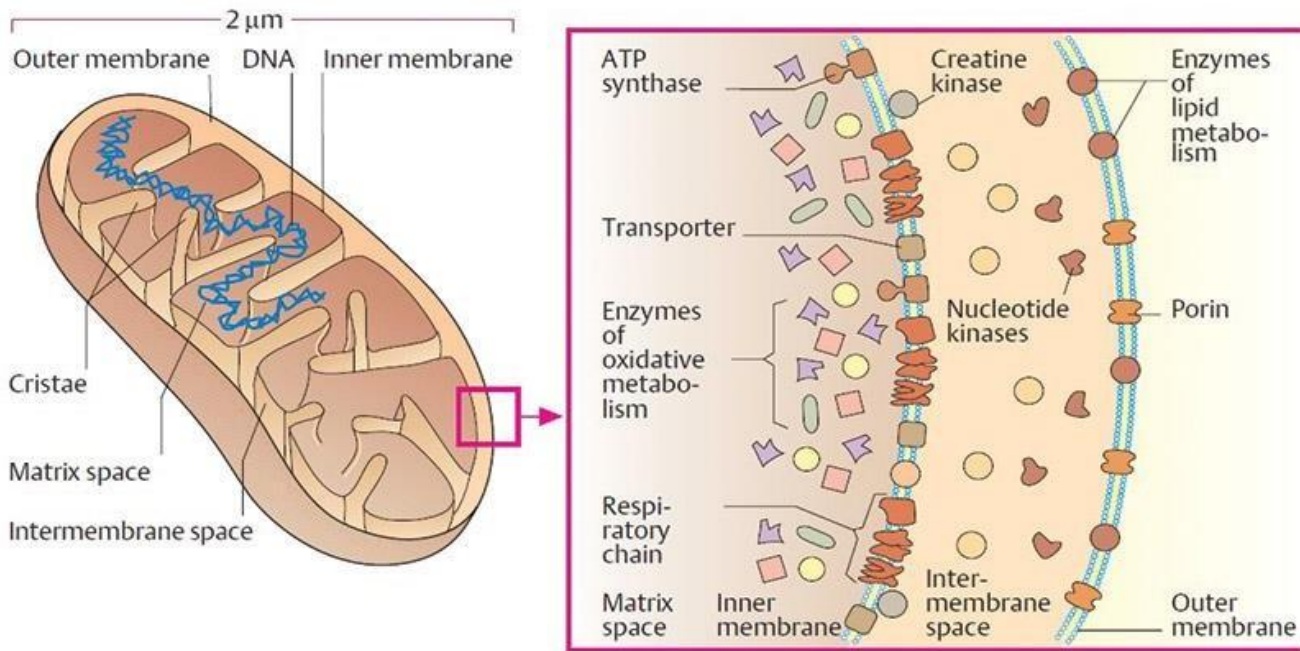
They are motile organelles and localize at intracellular sites of high-energy requirements such as basal regions of ion-transporting cells.

They could be selectively stained with iron hematoxylin, Janus green B in supravital staining of living cells.

With EM, they appear as ovoid or elongated structures bounded by two membranes. The outer membrane is smooth. The inner membrane is thrown into folds called cristae projecting into the inner cavity that is filled with an amorphous substance called matrix. The number of the cristae seen in mitochondria is directly related to the energy requirement of cell.

The inner membrane is covered with tiny spherical projections about 9 μm in diameter supported at narrow stalks. These are called inner membrane spheres or elementary particles and are believed to represent an enzyme known as F₁, which couple electron transport to the phosphorylation of ADP.

The mitochondrial matrix is also containing many electron-dense granules called matrix granules that are the sites for Ca⁺⁺ ions storage. The mitochondrial matrix contains DNA and RNA that explain the mitochondrial ability to grow, divide and synthesis some of their proteins.



Functions

- They house the chains of enzymes that catalyze reactions that provide the cells with most of its ATP (adenosine triphosphate).
- On demands, the ATP yields its high-energy phosphate bond to another molecule and become transformed into ADP.
- Within the mitochondrial matrix, ADP is transformed again into ATP. These processes take place within the mitochondrial matrix and inner mitochondrial membranes.
- The matrix contains enzymes of Krebs cycle and fatty acid oxidation. The inner membrane contains the cytochromes and the enzymes involved in ATP production.
- Due to their role in energy production, the mitochondria are likened to powerhouses of the cells.
- Participate in regulation of calcium level within the cytosol.

3- Endoplasmic reticulum (ER)

The Endoplasmic reticulum (Endo=inside; plasm=cytoplasm; reticulum = network) is an irregular network of branching and anastomosing tubules, cisternae and vesicles. Two types of ER are recognized, rough and smooth.

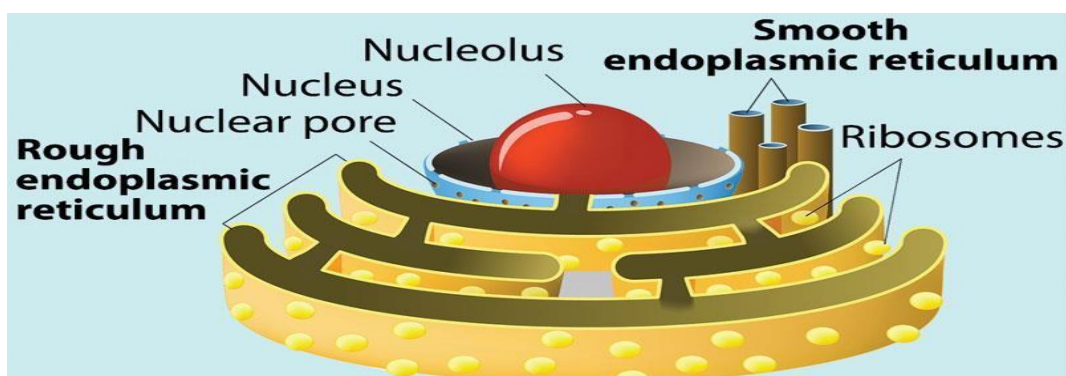
Rough endoplasmic reticulum (rER)

The rough endoplasmic reticulum is a membranous organelle concerned principally with synthesis and secretion of proteins. It is called rough due to the presence of large number of ribosomes attached to its limiting membrane. With LM, it appears as basophilic cytoplasmic areas that are referred to as the ergastoplasm or chromidial substances. The cytoplasmic basophilia may be diffuse (plasma cells), localized (pancreatic acinar cells) or arranged into clumps (Nissl granules in nerve cells) . Aggregates of rER appear basophilic mainly due to the presence of ribosomes on their outer surface .

With EM, it consists of an anastomosing network of tubules, vesicles and flattened cisternae that ramifies throughout the cytoplasm. Much of the surface of the rER is studded with ribosomes giving the reticulum a rough or granular appearance.

Functions:

- Synthesis of proteins for extracellular use (secretory proteins, lysosomal proteins and membrane proteins).
- Glycosylation of proteins to form glycoproteins.



Smooth endoplasmic reticulum (sER)

The smooth endoplasmic reticulum is a membranous organelle consists primarily of a network of branching and anastomosing tubules and vesicles.

It differs from the rER in that its limiting membrane is smooth and devoid of ribosomes. With LM, it does not appear. The cytoplasm of the cells contained abundant sER usually appears acidophilic.

With EM, it appears as irregular network of membranous tubules and vesicles devoid of ribosomes in contrast to the flattened ribosome-studded cisternae of rER. The sER tubules may be continuous with those of rER and Golgi apparatus .

Functions

- Steroid hormone synthesis in the testicular interstitial cells, the cells of the corpus luteum and adrenal cortex cells.
- Drug detoxification in liver cells.
- Lipid synthesis in the intestinal absorptive cells.
- Release and storage of Ca^{++} ions in striated muscle cells.
- Production of HCL in gastric parietal cells.

4- Golgi Apparatus (Golgi complex)

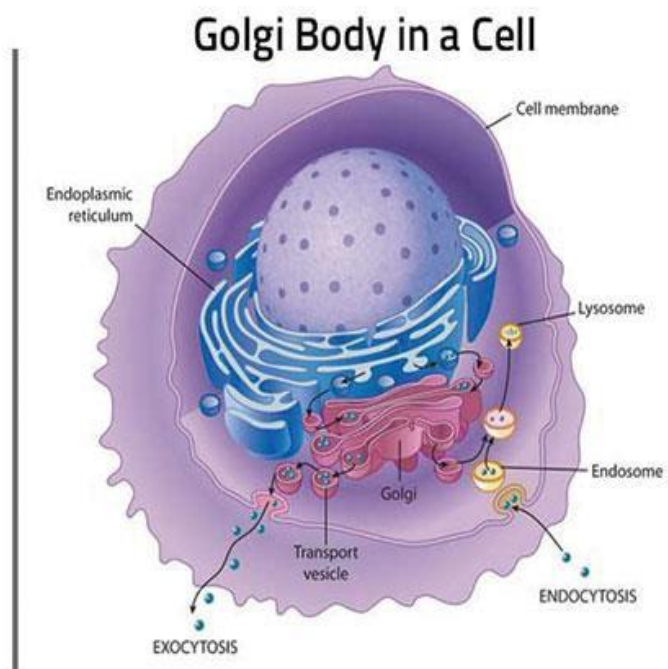
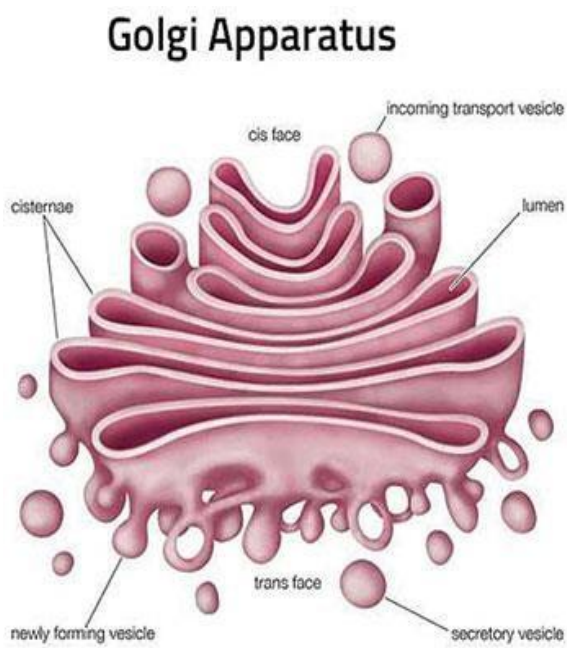
The Golgi apparatus is a membranous organelle concerned principally with synthesis, concentration, packaging and release of the secretory products.

With LM, it can be selectively stained with silver salts or osmium where it appears as a black network located near the nucleus. In H&E sections, it may be visible as a lighter-stained region called negative Golgi image. It is seen to great advantage in secretory cells such as osteoblasts.

With EM, the main structure unit of the Golgi apparatus is a flattened membranous vesicle called Golgi saccule.

The Golgi saccules are arranged in Golgi stacks that contain from 3-10 saccules. Most cell types possess several stacks of Golgi saccules forming an elaborate ramifying network termed the Golgi complex.

Each stack of saccules has 1) a forming face or Cis face that is convex in shape. 2) a maturing face or trans face that is concave. The Cis face is usually associated with a number of small transfer vesicles. The trans face characterized by being associated with much larger secretory granules.



Functions

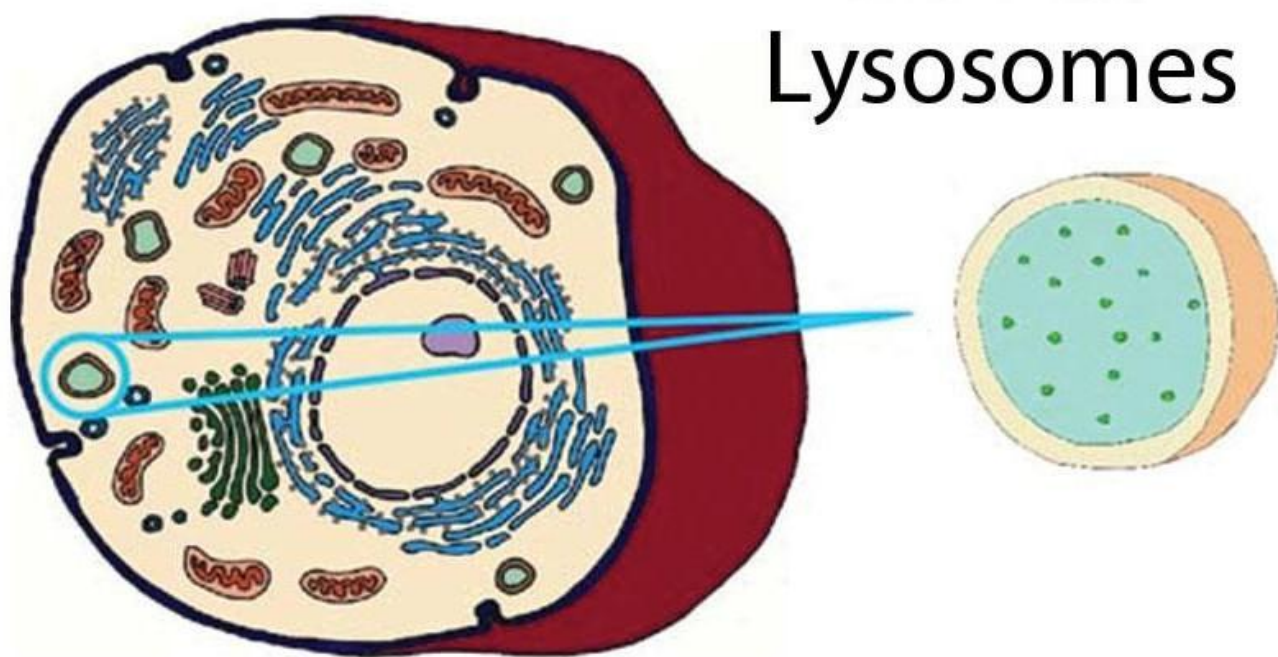
- Packaging and concentration of secretions.
- Modification of the secretory products such as glycosylation and sulfation of proteins to form glycoproteins and sulfated glycoproteins (mucus).
- Production of primary lysosomes.

5- Lysosomes

They are membrane-bounded vesicles (0.2-0.4 μ m) containing a number (more than 40) of hydrolytic enzymes that are active at acid pH (acid hydrolases) maintained within their interior. This group of enzymes can destroy all the major macromolecules (e.g., proteins and lipids) of the cells.

LM provides no direct evidence for the existence of lysosomes. The lysosomes are resolved at the LM level when their enzyme contents (e.g., acid phosphatase) are stained by histochemical methods.

With EM, the lysosomes appear as spherical membrane-bounded vacuoles with their contents showing varying degree of electron density.



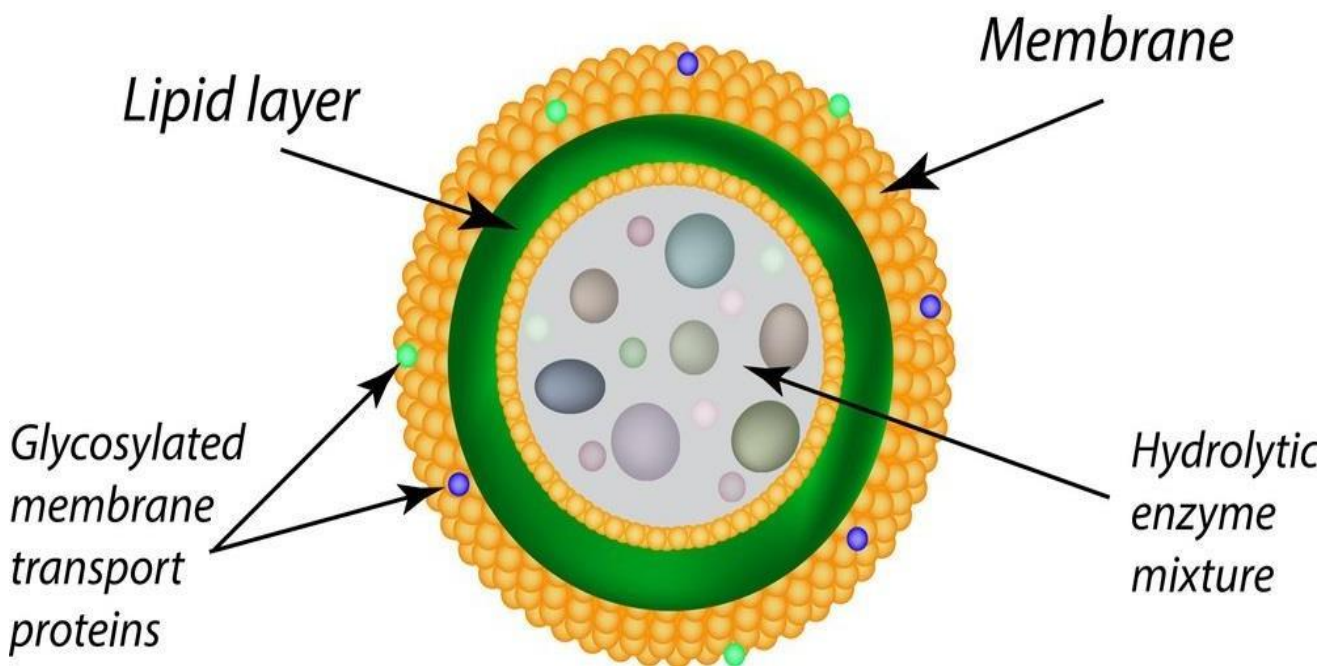
Types of lysosomes

Primary lysosomes are lysosomes freshly formed from the Golgi or sER. They contain nothing but hydrolytic enzymes.

Secondary lysosomes formed as the result of fusion of primary lysosomes with phagosomes. A phagosome is a membrane-bounded vesicle containing either exogenous material (e.g., bacteria) and it is called heterophagosome or endogenous material (e.g., damaged organelle) and it is called autophagosome.

Multivesicular bodies are spherical forms of heterophagosomes. They are membrane-bounded vesicles containing a number of smaller vesicles.

Residual bodies are debris containing vacuoles representing the terminal stage of lysosomal activities. Their contents may either be extruded from the cell by exocytosis or accumulate in the cytoplasm as lipofuscin pigments.



Functions

- Degradation of any exogenous macromolecules (phagocytosis and pinocytosis).
- Disposition of any organelles or cell constituents that are no longer useful to the cell (autophagy).

6- Peroxisomes

Peroxisomes are spherical, membrane-bounded organelles containing peroxide forming enzymes and catalase that are involved in the formation and degradation of intracellular hydrogen peroxide.

With LM, it does not appear. With EM, they are membrane-bounded vacuoles, vary in size and appearance depending on species and cell types. They are relatively large in hepatocytes and kidney cells and small in intestinal cells (microperoxisomes).

In human cell, they contain finely granular matrix of moderate density. In many other species, they have crystalline core called a nucleoid.

Such nucleoid is absent from liver peroxisomes from reptiles, birds, and human being which are species that lack urate oxidase, an enzyme that degrades urates.

Peroxisome

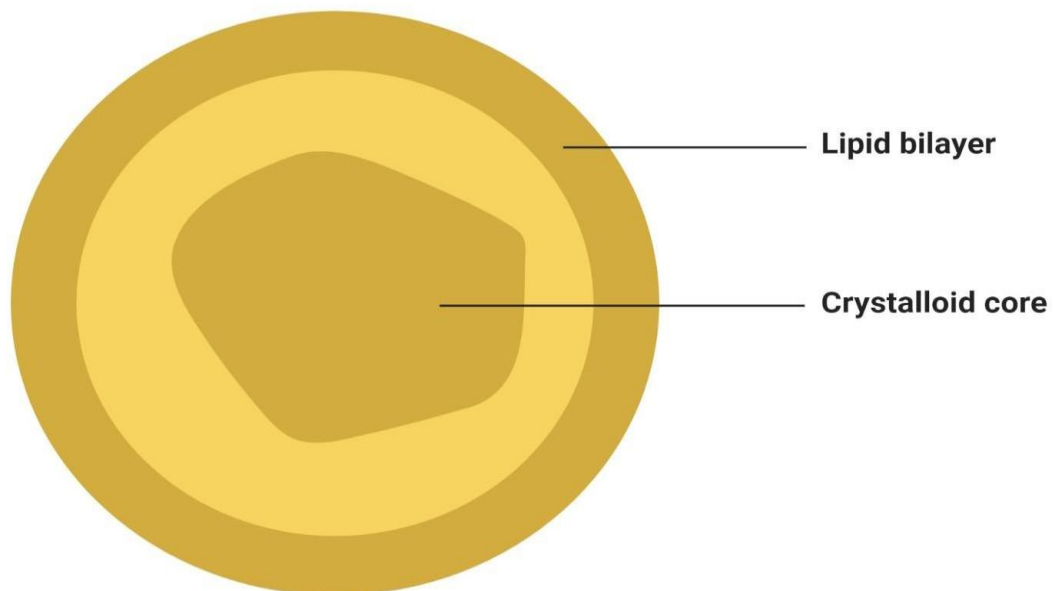


Figure: Peroxisome, Image Copyright © Sagar Aryal, www.microbenotes.com

Functions

- Peroxisomes contain at least three oxidase (D-amino acid oxidase, urate oxidase and catalase).
- The D-amino acid oxidase, urate oxidases are responsible for the production of hydrogen peroxide (H₂O₂).
- The catalase then utilizes the H₂O₂ in oxidation (and therefore, detoxification) of various toxic substances such as phenol, alcohol and fatty acids.

1. Non-membranous organelles

They are cytoplasmic organelles that possess no bounding membrane of their own. They include ribosomes, and centrioles.

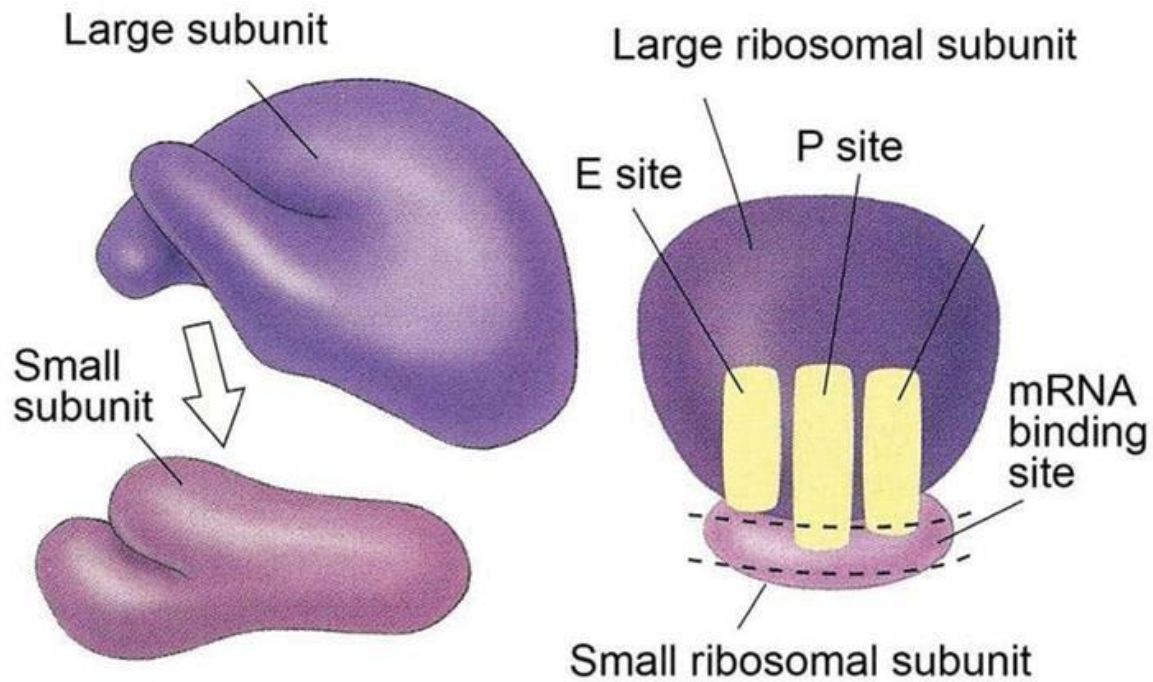
7- Ribosomes

They are rounded ribonucleoprotein particles, 20-30 nm in diameter that provide the intracellular sites where amino acids are linked together to form polypeptide chains (proteins).

With LM they are too small to be seen. However, cell containing abundant ribosomes usually has basophilic cytoplasm. Such cytoplasmic basophilia is largely due to the strong affinity of rRNA for hematoxylin.

With EM, the ribosomes are seen free in the cytoplasm either as separate entities or attached to messenger RNA molecules in small aggregation called polyribosomes or polysomes. Polyribosomes may also be attached to the surface of rER.

Each ribosome composed of a large and a small subunit that are made of rRNA and different types of proteins.



Functions

Free ribosomes are responsible for synthesis of proteins for internal use (cytoplasmic proteins and enzymes).

Attached ribosomes are responsible for synthesis of proteins for external use (secretory or lysosomal enzymes).

8- Centrosome and Centrioles

The centrosome is a specialized zone of cytoplasm contains a pair of centrioles together known as a diplosome, spherical bodies, procentrioles organizer and centriolar satellites that function as microtubular organization center.

With LM, the centrioles are selectively stained with iron hematoxylin where they appear as two tiny dots located close to the nucleus. In some epithelial cells,

centrioles are located in the apical cytoplasm immediately beneath the ciliated surface. Such apical centrioles are called basal bodies and from which cilia originate.

With EM, each centriole is a hollow cylinder, closed at one end. The two centrioles of each diplosome are arranged with their long axes at right angles to each other. The wall of each centriole is made up of nine triplet of parallel microtubules connected to each other by fine filaments, the protein link.

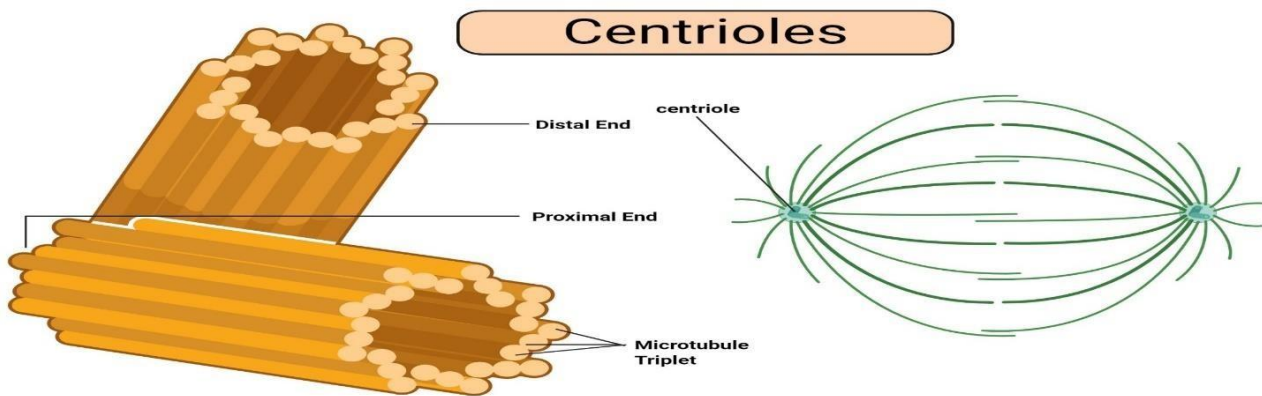


Figure: Centrioles, Image Copyright © Sagar Aryal, www.microbenotes.com

Functions

Formation of mitotic spindle during cell division.

Microtubular organization center

Ciliogenesis by the formation of procentrioles from the procentrioles organizer.

9- Cytoskeleton

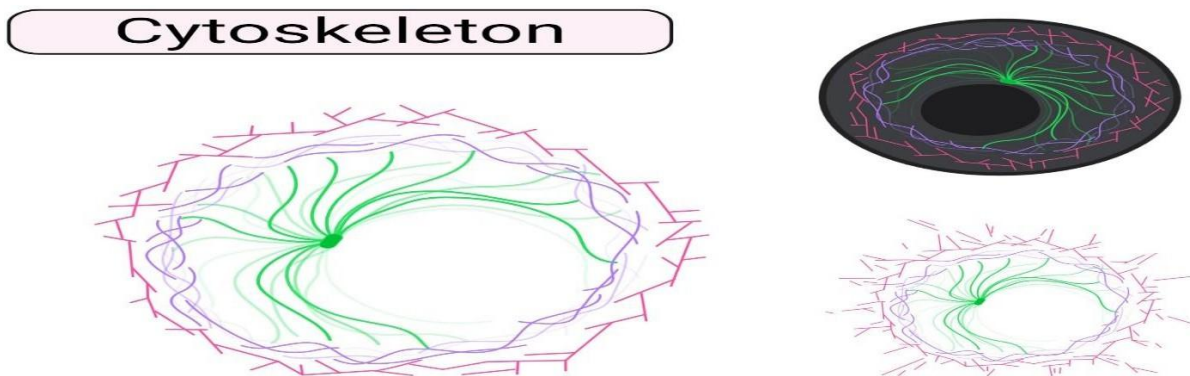
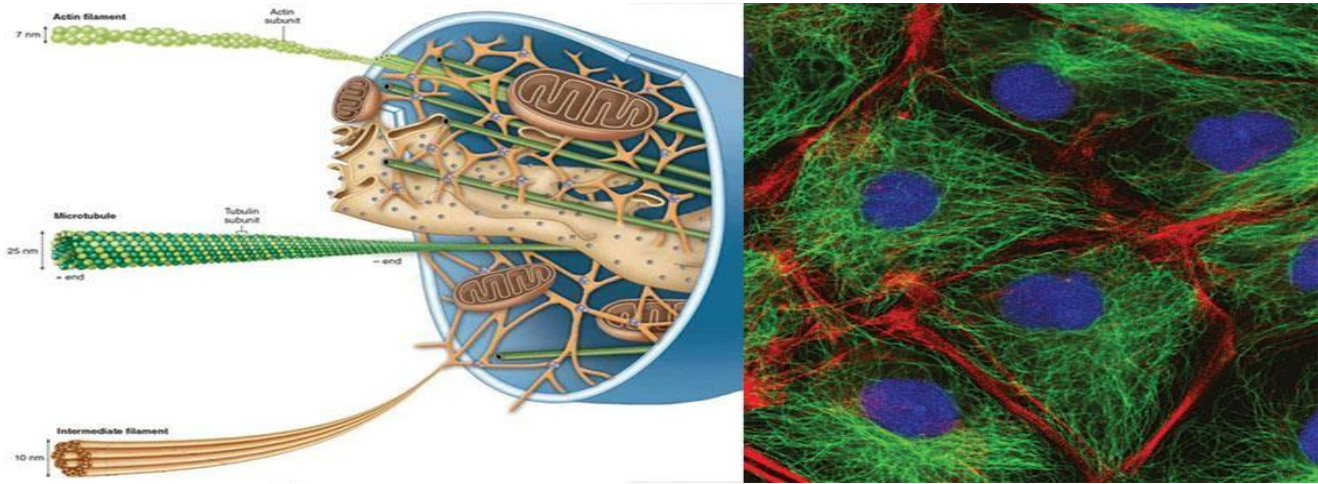


Figure: Cytoskeleton, Image Copyright © Sagar Aryal, www.microbenotes.com

The cytoskeleton is a complex network of minute filaments and tubules located within every cell, that maintain cell shape and stability and are responsible for some cell functions. It includes cytofilaments and microtubules.



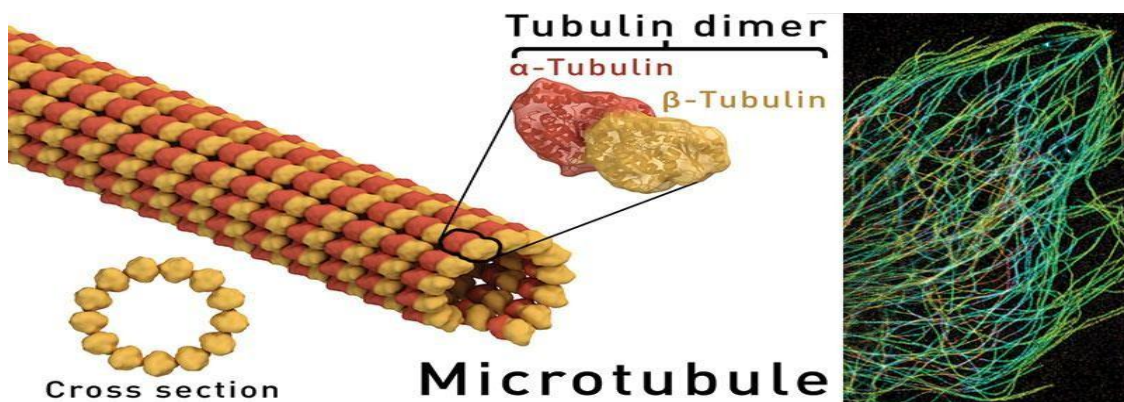
Cytofilaments: are minute thread-like structures of three types:

The Actin (thin filaments) is found in muscle cell, in the core of each microvillus, in motile cells such as macrophages and in developing nerve cells. Their diameter is about 5 nm.

The Myosin (thick filaments) occurs mainly in muscle cells in association with actin filaments. They have a diameter of 15 nm.

The Intermediate filaments are 10 nm in diameter and include neurofilaments in neurons, glial filaments in astrocytes and tonofilaments in epithelial cells.

Microtubules



Microtubules

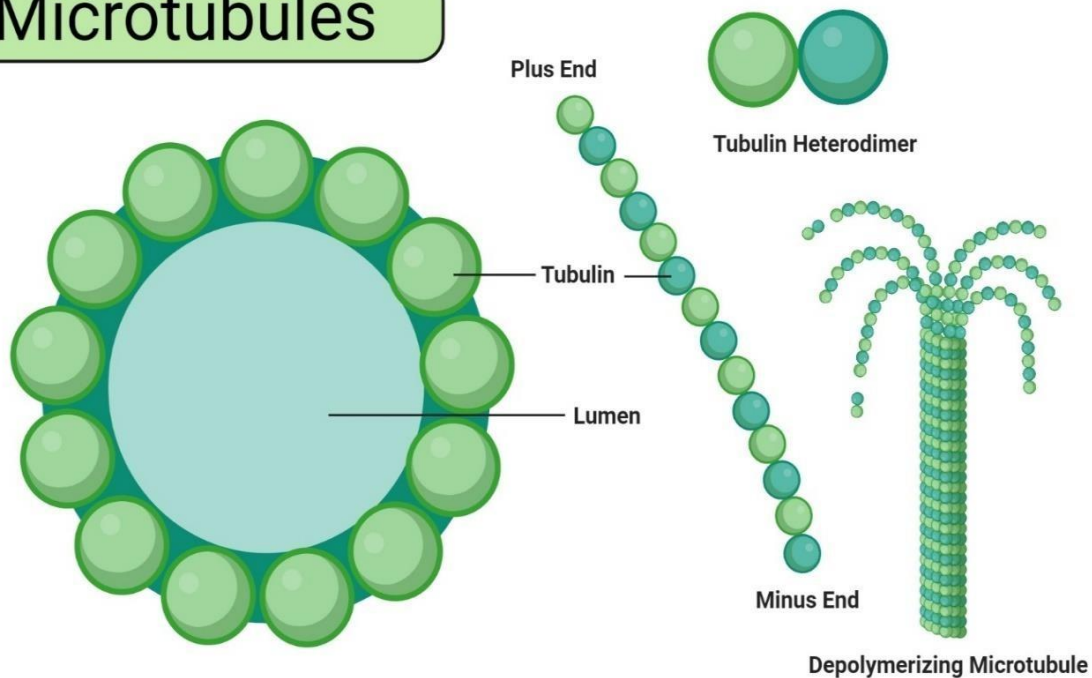


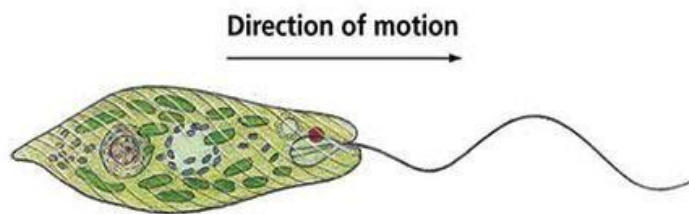
Figure: Microtubules, Image Copyright © Sagar Aryal, www.microbenotes.com

They are hollow tubular structures of variable length with a constant diameter of 25nm. Microtubules are stable permanent structures in cilia, flagella, centrioles and basal bodies. Each microtubule is made up of protein molecules (tubulin) that appear to organize into protofilaments that run parallel to the length of the tubule. A total of 13 protofilaments comprise the wall of a microtubule.

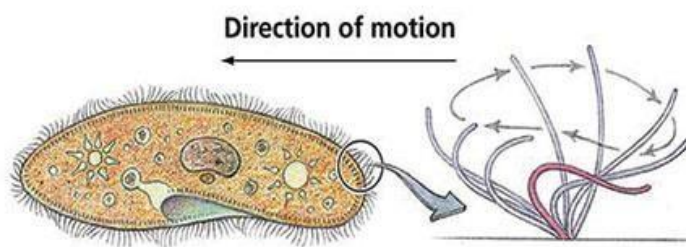
Functions of the cytoskeleton

- It provides the structural support for the plasmalemma, cellular organelles and some cytosol enzyme system.
- It provides the means for the movement of intracellular organelles within the cytoplasm.

- It plays an essential role in cell motility as well as provides the framework of motile structures such as cilia and flagella.
- It is responsible for contractility of the muscle cells.
- It plays an important role in epithelial cell adhesion as well as cell division.

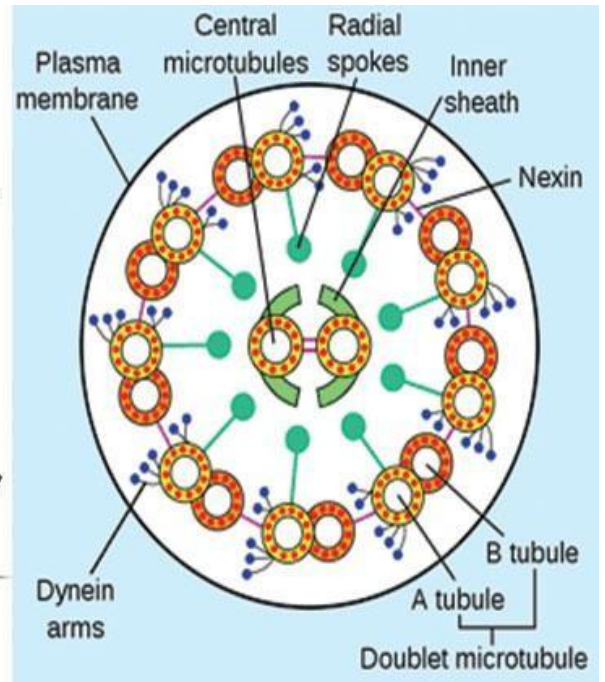


(a) Flagella



(b) Cilia

Copyright © 2006 Pearson Education, Inc., publishing as Benjamin Cummings.



Cilia and Flagella

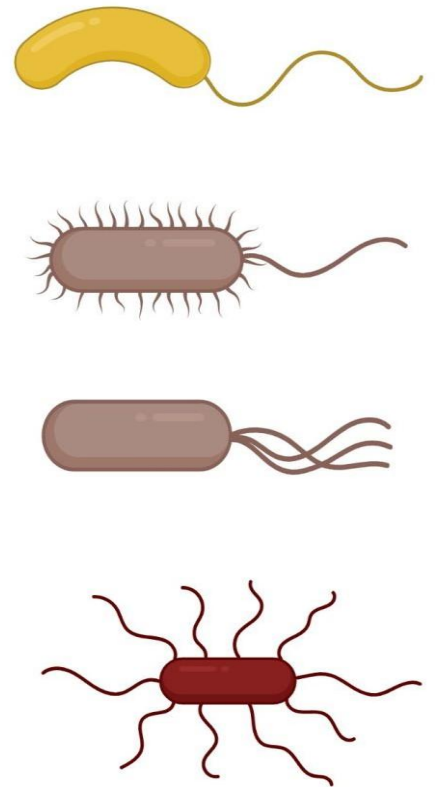
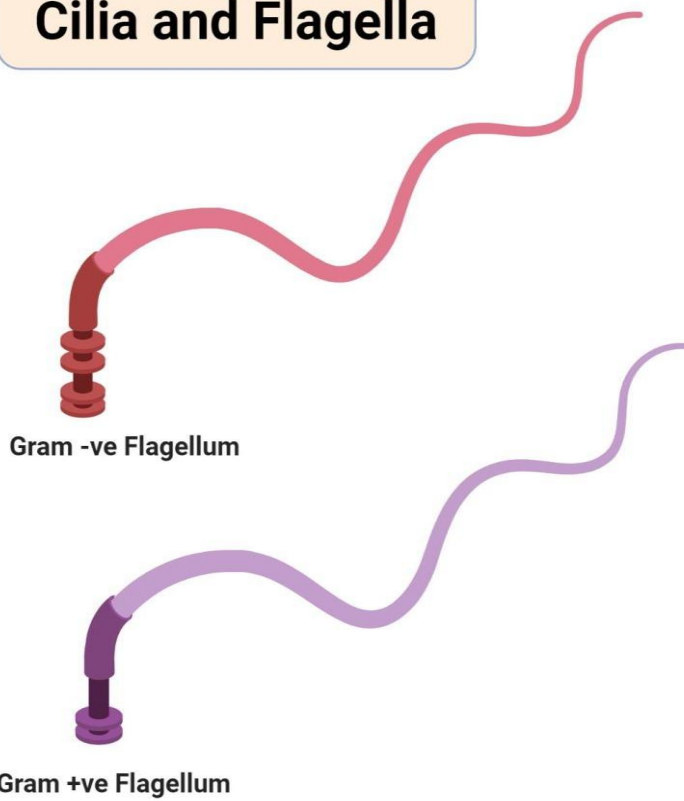

Figure: Cilia and Flagella, Image Copyright © Sagar Aryal, www.microbenotes.com

	Microfilaments	Microtubules	Intermediate filaments
1- diameter	7 nm.	25 nm.	10 nm.
2- LM	Seen only by immunohistochemistry.	Seen only by immunohistochemistry	Seen only by immunohistochemistry
3- EM	Thin electron dense filaments.	Fine tubules.	Thicker electron dense filaments.
4- Structural proteins	Monomers of G actin polymerize to form F actin.	Tubulin dimer polymerize to protofilaments. 13 protofilaments form a microtubule,	Woven ropes.
5- Functions	Dynamic 1- Muscle contraction. 2- Contractile ring in cell division. 3- Pseudopodia in migration. 4- Microvilli. 5- Cytoplasmic streaming.	Dynamic. 1- Transport of organelles & vesicles. 2- Formation of centrioles, cilia & flagella.	Not dynamic. Structural support.

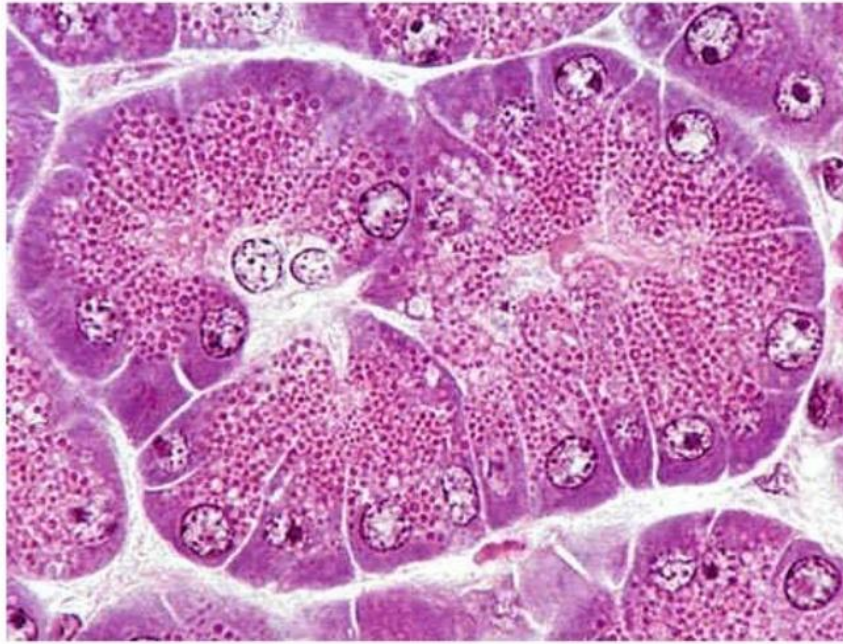


10- Cytoplasmic Inclusions

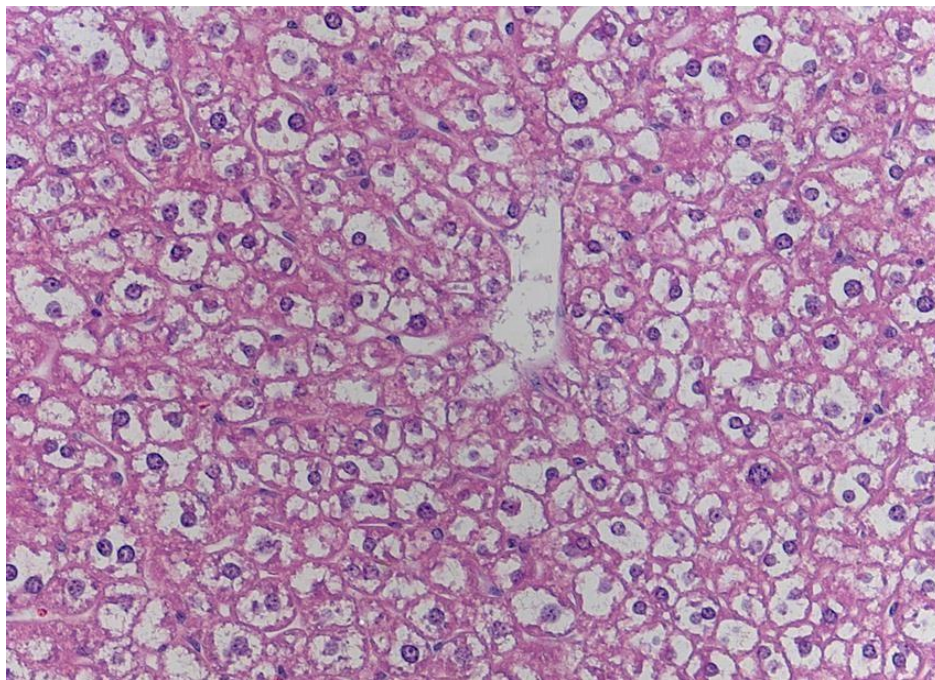
They are temporary lifeless accumulation of metabolites or cell products, such as stored food, pigments and crystals.

1. Stored food

Pancreas – Secretory acini w/ zymogen granules



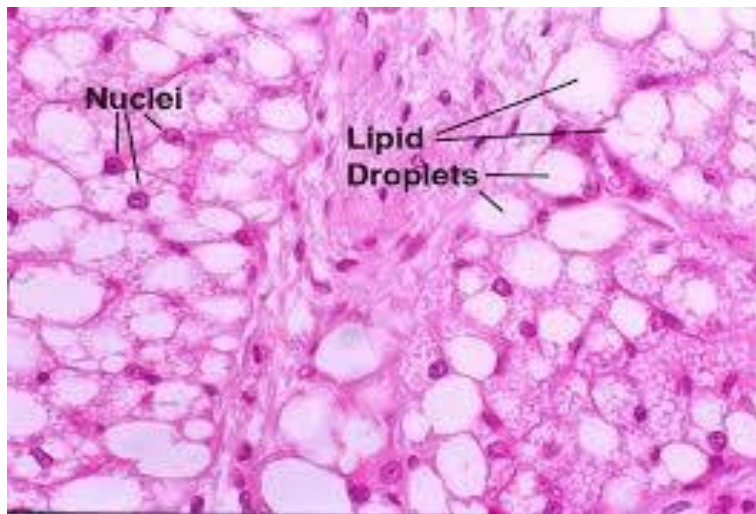
2. Glycogen



3. Lipids

The fat cells of adipose tissues and the fat storing cells of the liver store the lipids. Routine processing generally extracts lipids from tissue and therefore, in H&E sections, lipid droplets within cells appear as unstained vacuoles.

Lipids are best demonstrated in frozen sections stained by specific lipid methods such as osmium or sudan III with which lipids are stained black and orange respectively.



4. Pigments

They are substances that have their own color in their nature state.

a. Exogenous pigments

The exogenous pigments are those that have been produced outside the body. They include carotenes, dusts, minerals and tattoo marks.

1. Carotenes

Carotenes are a family of fat-soluble compound found in vegetable such as carrots, tomatoes and vegetable juice. When animals fed on carotene-containing vegetables, it colors its body fat yellow. Carotenes are provitamins and may be converted into vitamin A.

Ingestion of large amount of carotenes cause the skin of the body to appear yellow or even reddish color due to its great contents of carotenes. This condition is called carotenemia (increase carotene level in the blood). It might be confused with the more serious pathological condition called jaundice (caused by increase bilirubin level in the blood).

2. Dusts

The lungs of heavy smokers usually blackened due to accumulation of carbon particles in the alveolar macrophages located in the wall of the lung alveoli.

3. Minerals

Silver causes a gray pigmentation of the body. Lead can impart a blue line to the gum.

4. Tattoo marks

They are inorganic pigments inserted deeply into the skin with needles.

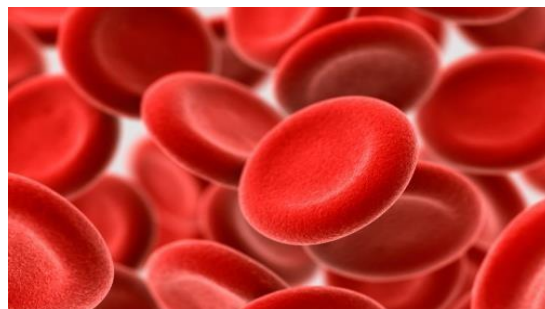The pigments are ingested by the subcutaneous macrophages and remain permanently within their cytoplasm.

b. Endogenous pigments

They include hemoglobin, hemosiderin, bilirubin, melanin and lipofuscin.

1. Hemoglobin

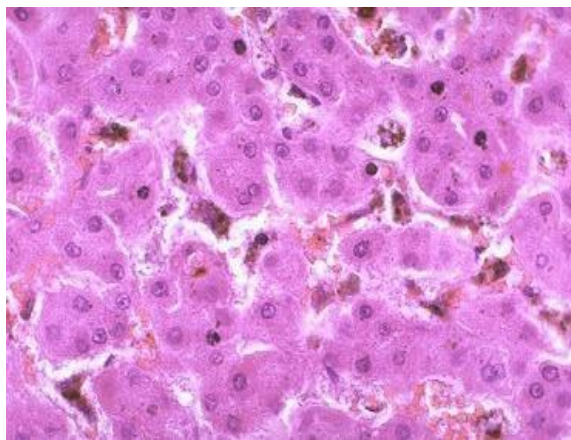
he hemoglobin is an iron-containing pigment of erythrocytes has the function of oxygen transport throughout the body.



2. Hemosiderin and bilirubin

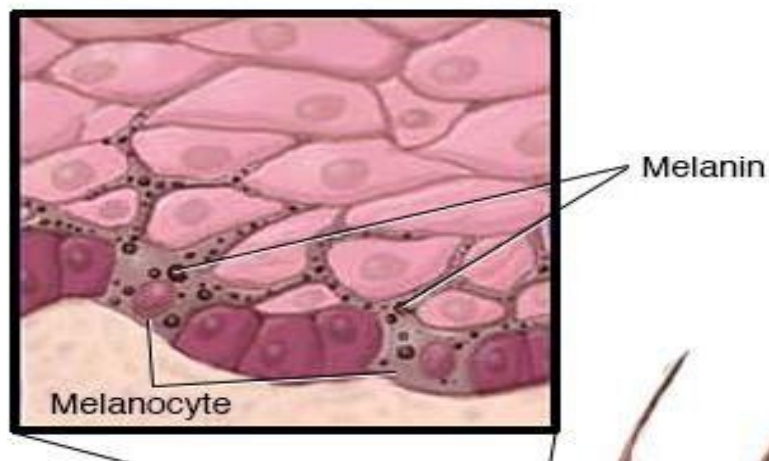
They are formed as the result of degradation of old erythrocytes by the spleen macrophages. Hemoglobin is degraded into hemosiderin and bilirubin. The hemosiderin is a golden brown iron-containing pigment usually seen within the cytoplasm of the splenic macrophages.

The bilirubin is yellowish-brown pigment. It has to be removed from the blood stream by the liver and excreted in bile.



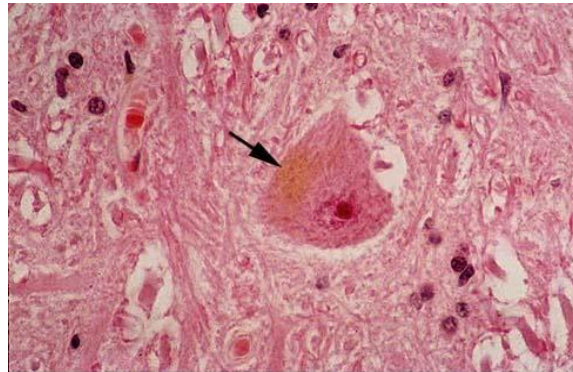
3. Melanin

The melanin is a brown-to-black pigment presents in skin, hair and eyes. There is two type of melanin: eumelanin, which has a brownish black color, and pheomelanin that has a reddish-yellow color.



4. Lipofuscin

The lipofuscin is a golden-brown intracellular pigment represents a normal product of organelle's degradation. It accumulates with increasing age particularly in long-lived cells such as neurons and cardiac muscle cells (hence, they are referred to as age pigments or wear and tear pigments).



c. Crystals

Such as calcium oxalate and calcium carbonate crystals can be seen in the cytoplasm during certain disease conditions.

11. Nucleus

The nucleus is the archive of the cell that carries the genetic information necessary to regulate the different cell functions. It consists primarily of DNA (20% of its mass), DNA-binding proteins, and some RNA.

The DNA-binding proteins are of two major type histones and non-histones. The histones are involved in the folding of DNA strands and regulation of DNA activity. The non-histones are involved in the regulation of gene activity.

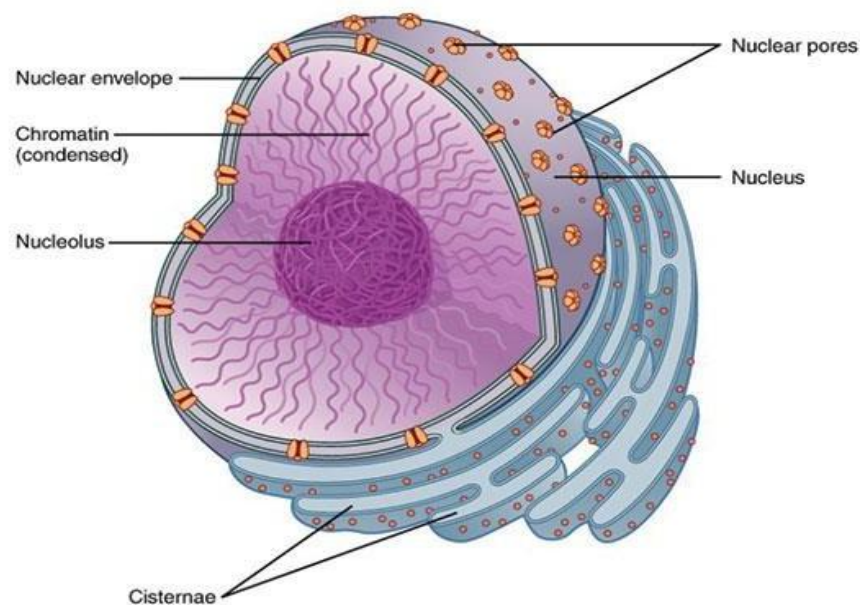
The nuclear RNA represents newly synthesized transfer and ribosomal RNA that has not yet passed into the cytoplasm.

With LM, the nuclei appear as basophilic structure located either centrally, eccentric or in a peripheral position. Most commonly nuclei are spherical or ovoid but they may be spindle-shaped (smooth muscle), bean or kidney-shaped (monocytes), or multilobulated (neutrophils).

Most often, cells are mononucleated. Some however, may be binucleated or even multinucleated. The interphase (not engaged in cell division) nucleus consists of nuclear envelope, chromatin, nucleolus and nuclear sap (karyolymph).

Nucleus

Structure and Functions



1. Nuclear envelope

With LM, it appears as a single basophilic line due to the presence of condensed chromatin adherent to its inner surface (peripheral chromatin) as well as ribosomes on the outer surface of the nuclear envelope.

With EM, the nuclear envelope consists of two membranes separated by a perinuclear space 25nm wide.

The outer membrane is continuous with the membranes of both the rER and sER and it may be studded with ribosomes. At the inner surface of the inner membrane, a layer of condensed chromatin known as granular lamina is usually encountered.

Numerous pores through which the nucleus communicates with the cytoplasm interrupt the nuclear envelope. The nuclear pore is guarded by two annuli, an outer and an inner annulus, each with eight globular subunits 15-20 nm diameter, projecting inwards from them are eight radially arranged spokes. In the center of the pore there is a central granule or plug. Such structure is called nuclear pore complex.

2. Chromatin

Two types of chromatin are distinguished: heterochromatin and euchromatin.

Heterochromatin

The heterochromatins consist of tightly coiled portions of chromosomes. The genes are repressed and transcription does not occur. It predominates in inactive cells.

With LM, they appear as fine and coarse basophilic granules scattered throughout the different regions of the nucleus.

With EM, it appears as electron-dense areas tend to be clumped around the periphery of the nucleus (peripheral chromatin), around the nucleolus (nucleolus associated chromatin) and also forms irregular clumps throughout the nucleus (chromatin islets).

In females, the inactive X-chromosome forms a small mass located at the edge of the nucleus and is called Barr body.

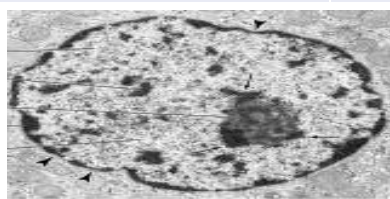
Euchromatin

The euchromatin is the extended, uncoiled portions of chromosomes in which the transcription of DNA is active. This type of chromatin is found in active cells. With LM, euchromatin is invisible because they are very thin and extended. With EM, they appear

as electron-dense nuclear materials represent the parts of the DNA that are active in RNA synthesis.

	Heterochromatin	Euchromatin
1- LM	Dense basophilic clumps .	Lightly stained basophilic areas.
2- EM	Electron dense filaments or granules distriibnuted 1- around nucleolus . 2- associated with inner nuclear membrane . 3- swimming in nuclear sap .	Dispersed fine filaments or granules.
3- Function	Inactive part acts as a reserve (transformedeui nchtoromatinwhen needed).	Active part (transcribed into RNA).
4- Site	Inactive cells .	Active cellse.g.dividing cells .

103



3. Nucleolus

It is a conspicuous, spherical, basophilic structure that is primary concerned with synthesis of ribosomal RNA.

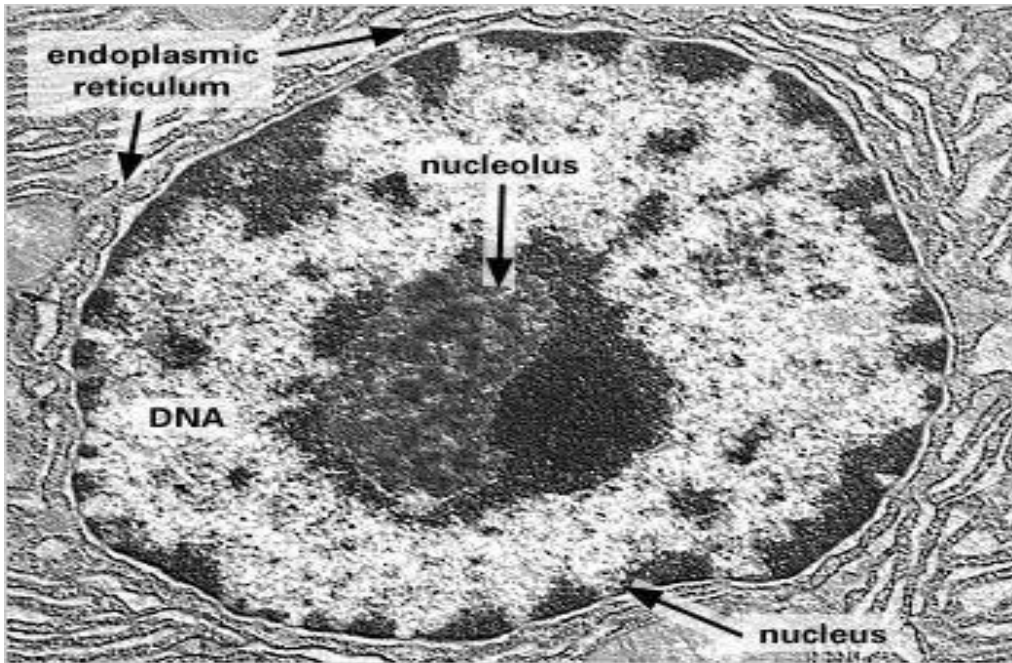
With LM, usually one, sometimes several nucleoli are seen. They are usually basophilic mainly due to nucleolus associated chromatin.

With EM, the nucleolus consists of a sponge showing dark materials of granular (pars granulosa) and fibrillar (pars fibrosa) both form the nucleonema which is ribonucleoprotein permeated by dispersed filaments of DNA (pars amorpha).

The primary function of the nucleolus is the synthesis of ribosomal RNA (rRNA). The genes that code for rRNA are known as nucleolar genes that lie along five different pairs of chromosomes.

4. Nuclear sap (karyolymph)

The nuclear sap is a colloidal solution in which chromatins are suspended. It helps in the movement of RNA (rRNA, tRNA, and mRNA) toward the nuclear pores.



Nucleus

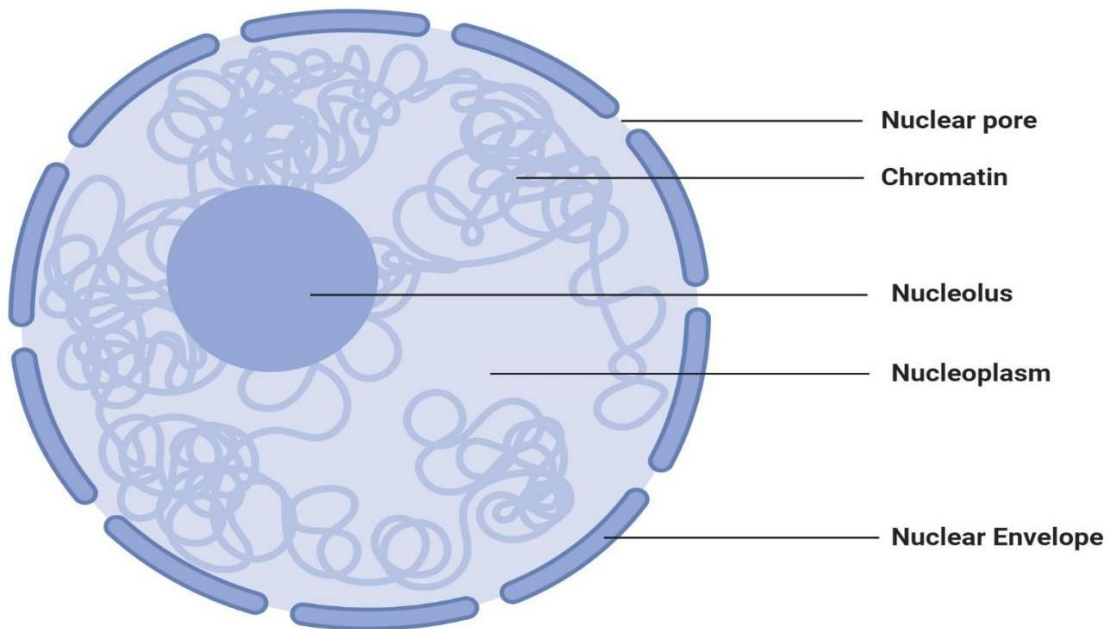


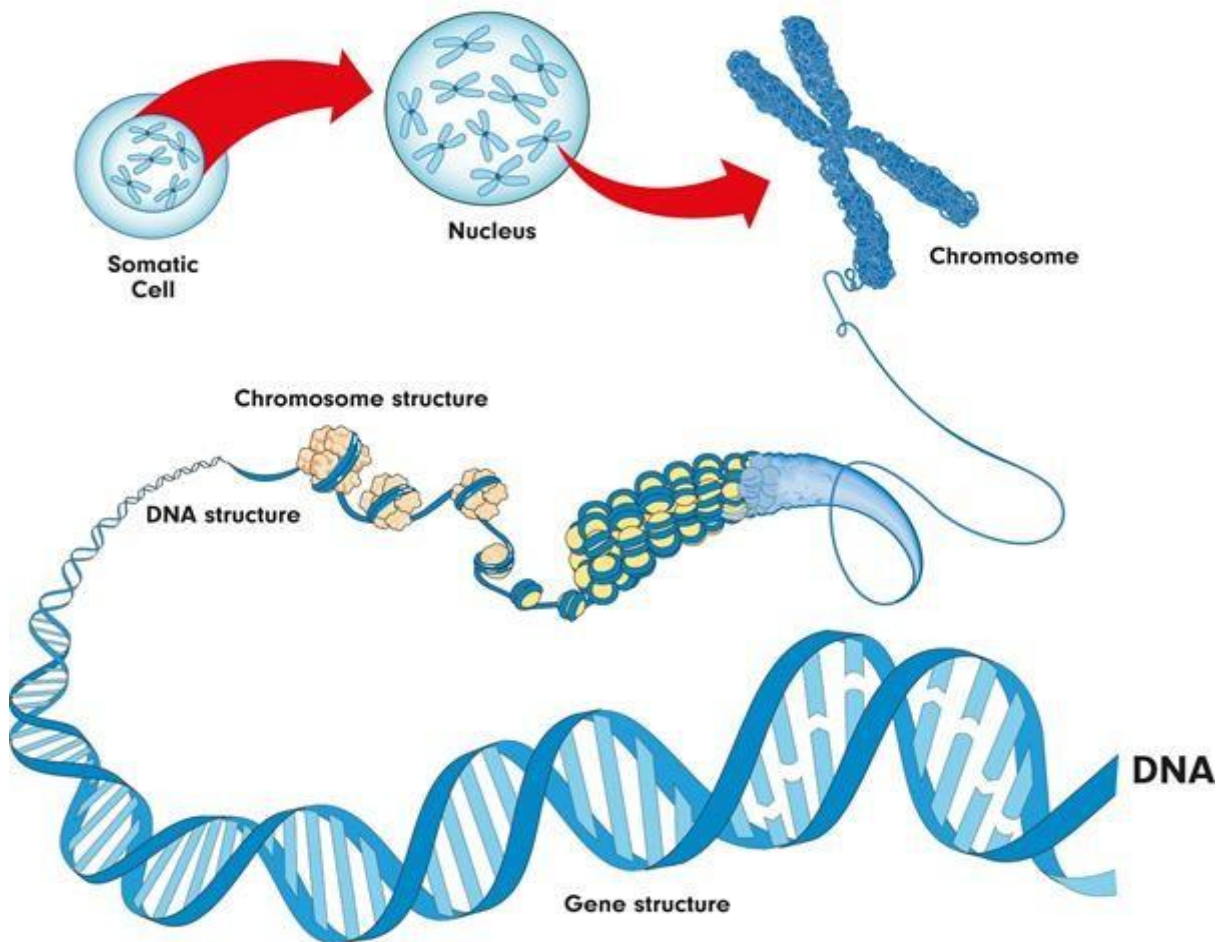
Figure: Nucleus, Image Copyright © Sagar Aryal, www.microbenotes.com

DNA and chromosomes

Inside the nucleus of a cell, there are thread-like structures called chromosomes. Each chromosome is made out of a long, coiled up strand of DNA (genetic material), which means that each chromosome contains many genes.

Normally, there are 46 chromosomes inside the nucleus of each human body cell. Chromosomes are usually found in pairs.

Chromosome structure



A **diploid** cell contains two complete sets of chromosomes in its nucleus, one from each parent. In humans, all body cells are diploid cells. Human diploid cells have 23 pairs of chromosomes (46 in total). The diploid number is often represented as **2n**, with n being the number of chromosomes. In humans, $2n = 46$.

The word **haploid** means half. It describes a cell that contains a single set of chromosomes. The symbol **n** is often used to show the haploid number. In humans, $n = 23$. Human sex cells (egg and sperm cells) contain a single set of chromosomes, so they are haploid cells.

- Sex cells are also called **gametes**

12- Vacuoles

A vacuole may be described as a space inside the cell that does not contain cytoplasm. It is surrounded by a membrane and filled with a fluid. Vacuoles store various molecules including enzymes, waste products of the cell, water, and even food material depending on the type of cell.

In cases where vacuoles contain waste products of the cell, they are also involved in the exportation of waste from the cell thus protecting the cell from toxicity.

Some vacuoles also play a role in maintaining the internal hydrostatic pressure of the cell as well as regulating pH.

- **Other features of a cell include:**
- **Cell Wall**
- Some books do not consider the cell wall to be an organelle. However, it's one of the most important components of plant cells. The cell wall surrounds the cell membrane and serves to strengthen and protect the cell.
- For instance, in the cells of plant roots, the cell wall protects the cell as they grow deeper in the soil. The cell wall also serves as a filter that controls the movement of molecules in and out of the cell.
- **Cytoplasm** is also not considered as an organelle in some books. However, it is an important component of the cell. Cell cytoplasm is composed of protoplasm in which all the other cell organelles are suspended. Many of the cell processes

(protein synthesis, respiration etc) take place in the cytoplasm. The cytoplasm also plays an important role in the movement of various materials around the cell.

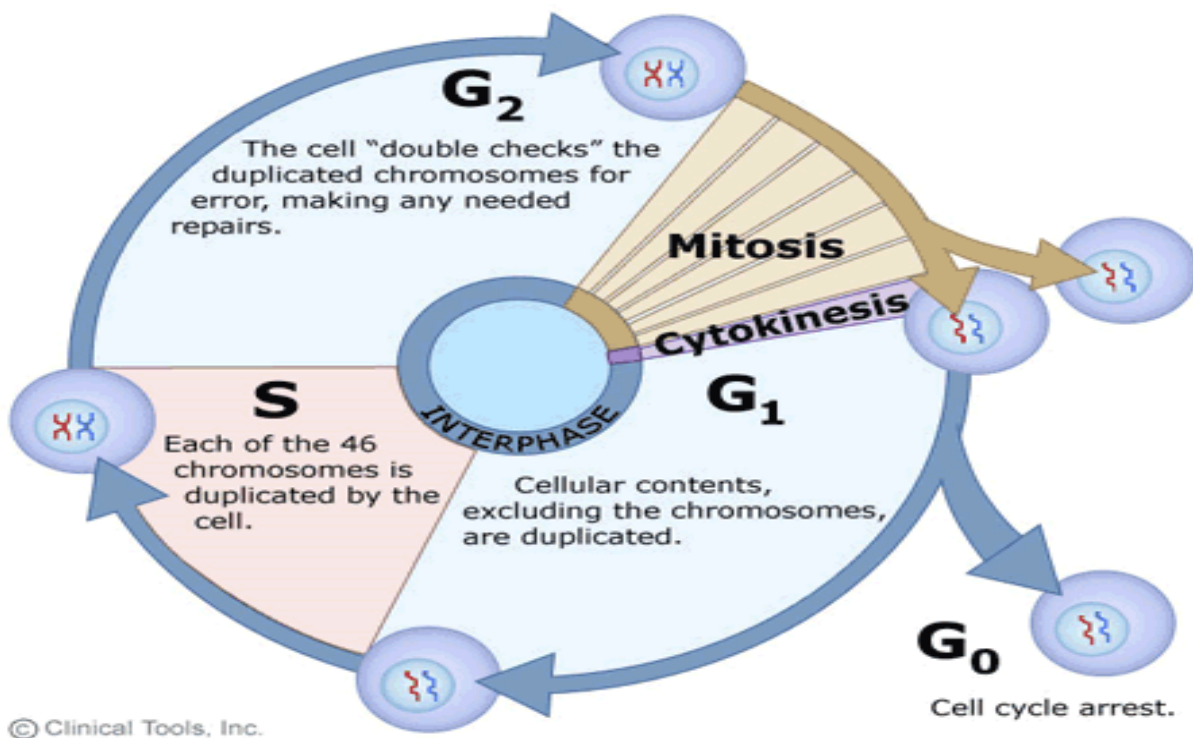
Cell cycle & division

- Definition: it is the alternation between interphase and mitosis.

I-Interphase: a longer period:

- 1- The cell increases in size.
- 2- Performs its normal functions.
- 3- Replicates its DNA for preparing itself for division.

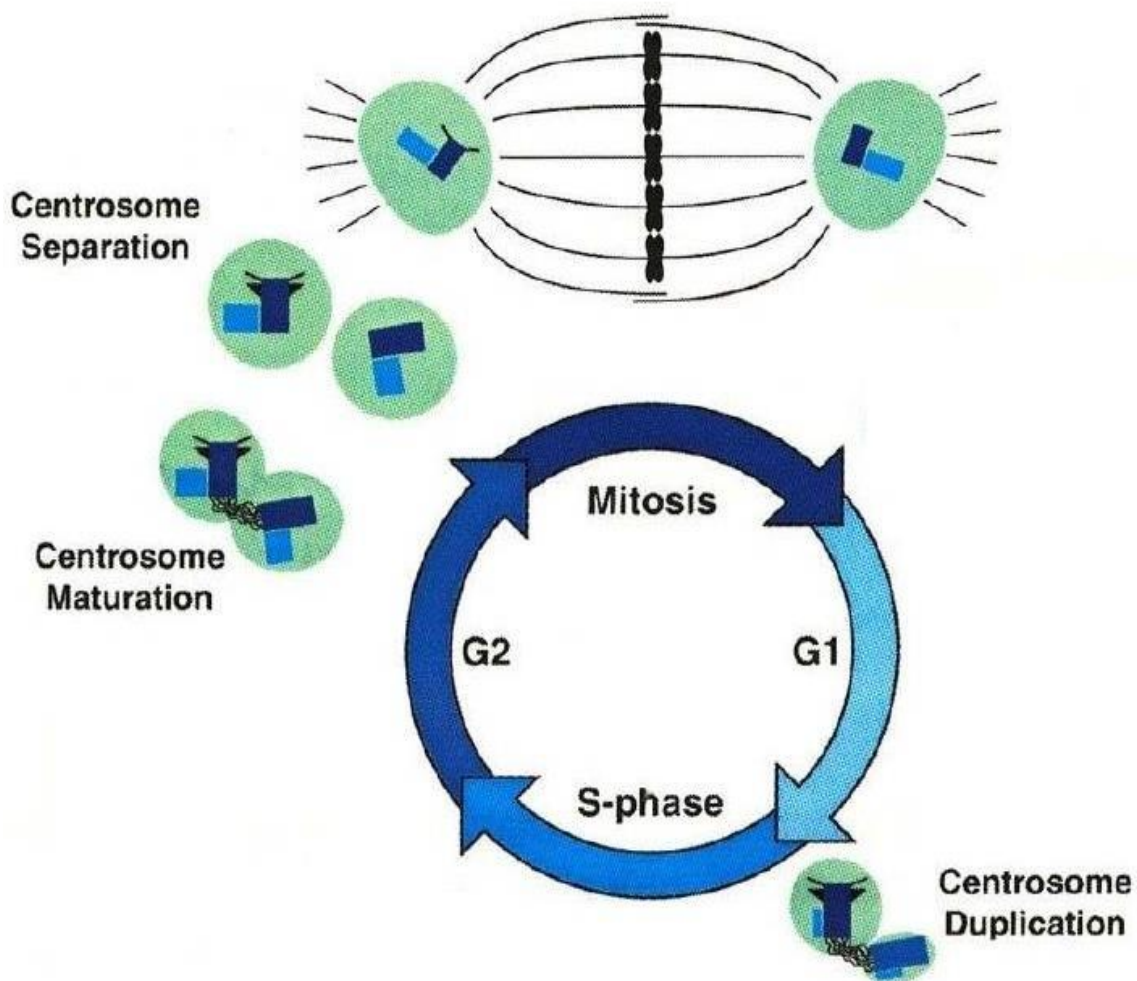
II-Mitosis: a shorter period during which parent cell gives 2 daughter cells each containing the same number of chromosomes (identical to the parent cell =46 chromosomes).



I-Interphase

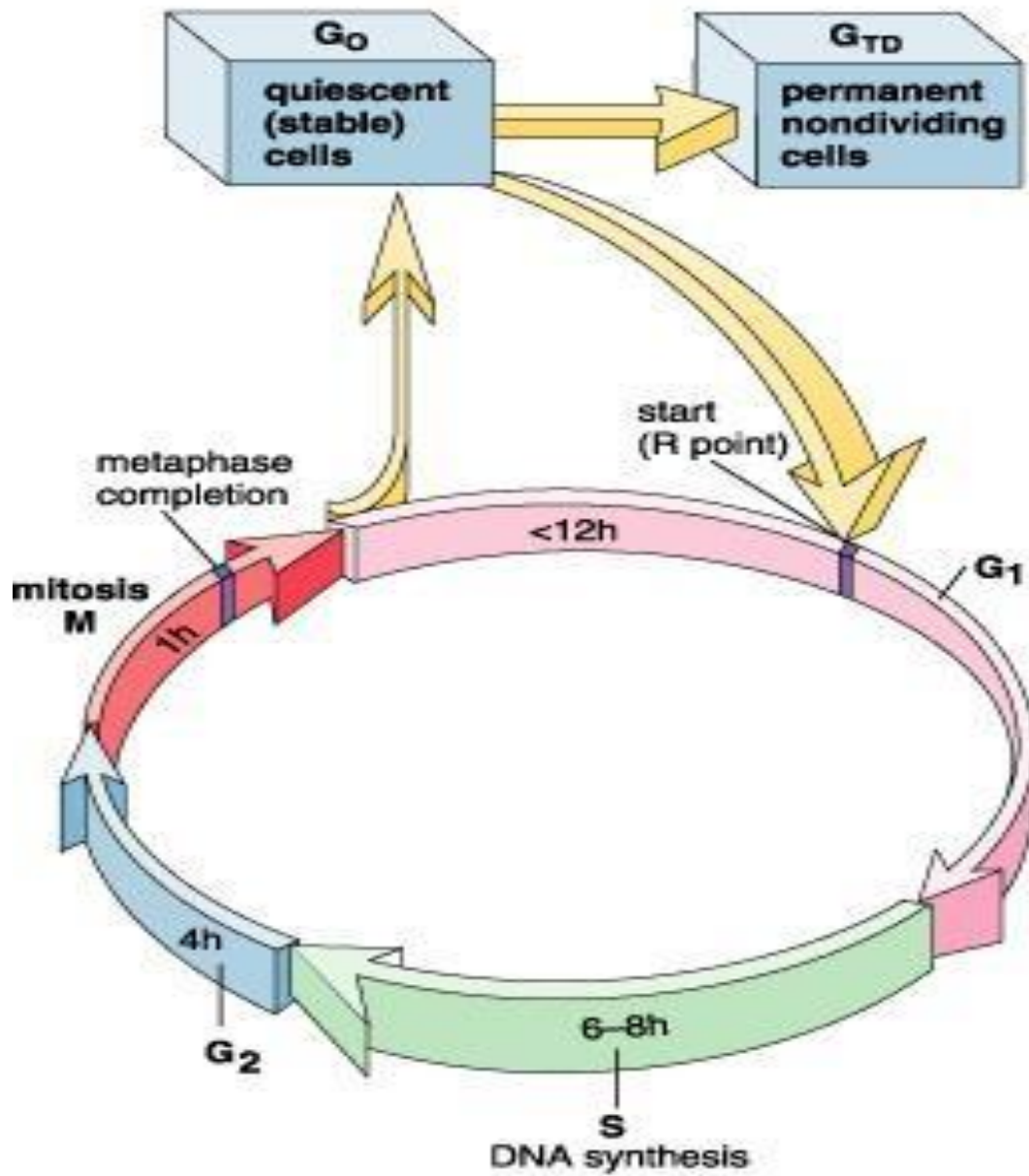
First gap phase (G₁ phase)

- It is *the longest period* of the cell cycle between the end of mitosis and the beginning of DNA replication:
 - 1- The RNA and protein synthesis occurs.
 - 2- The cell attains its full size.
 - 3- The cell performs its function.
 - 4- Duplication of centrosomes occurs near the transition between G₁ and S phase.



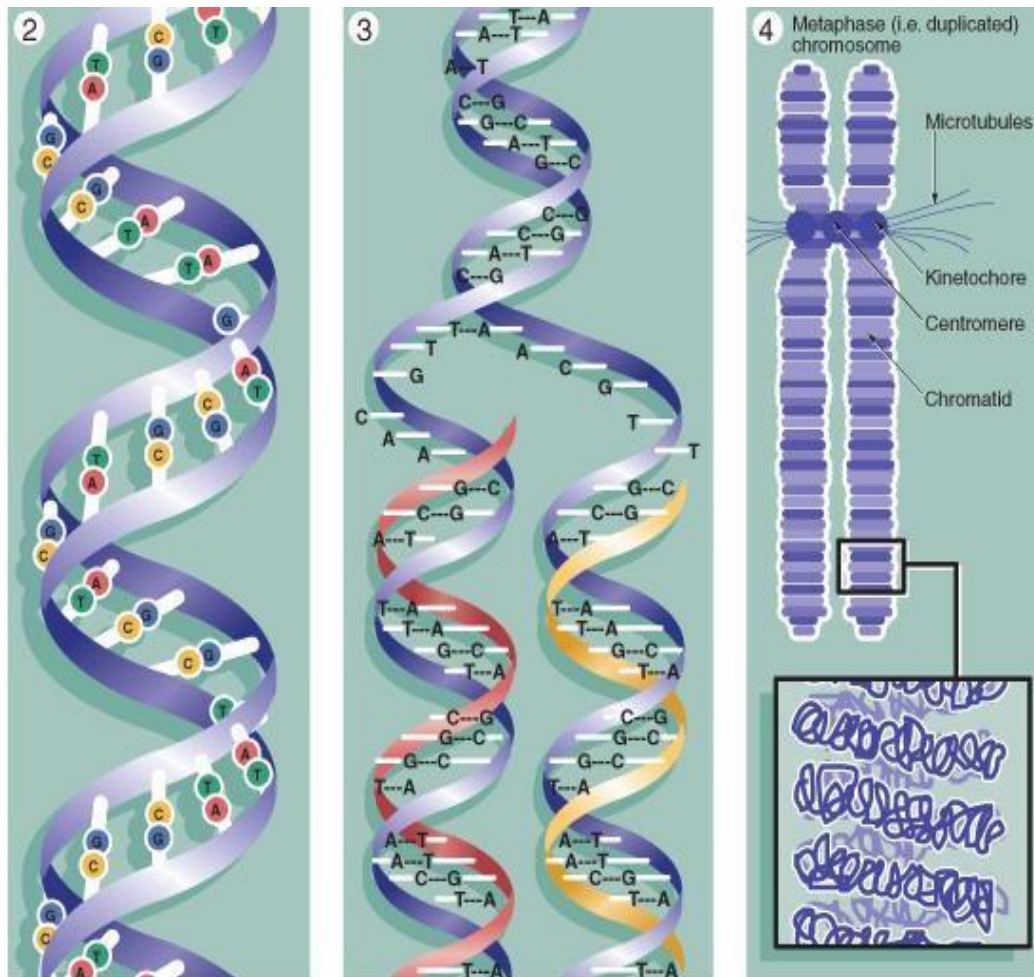
GO Phase

- **Definition:** Differentiation of the cell to carry out specialized function and no longer divide (*outside the cycle*).
- GO may be *permanent* or *temporary*.



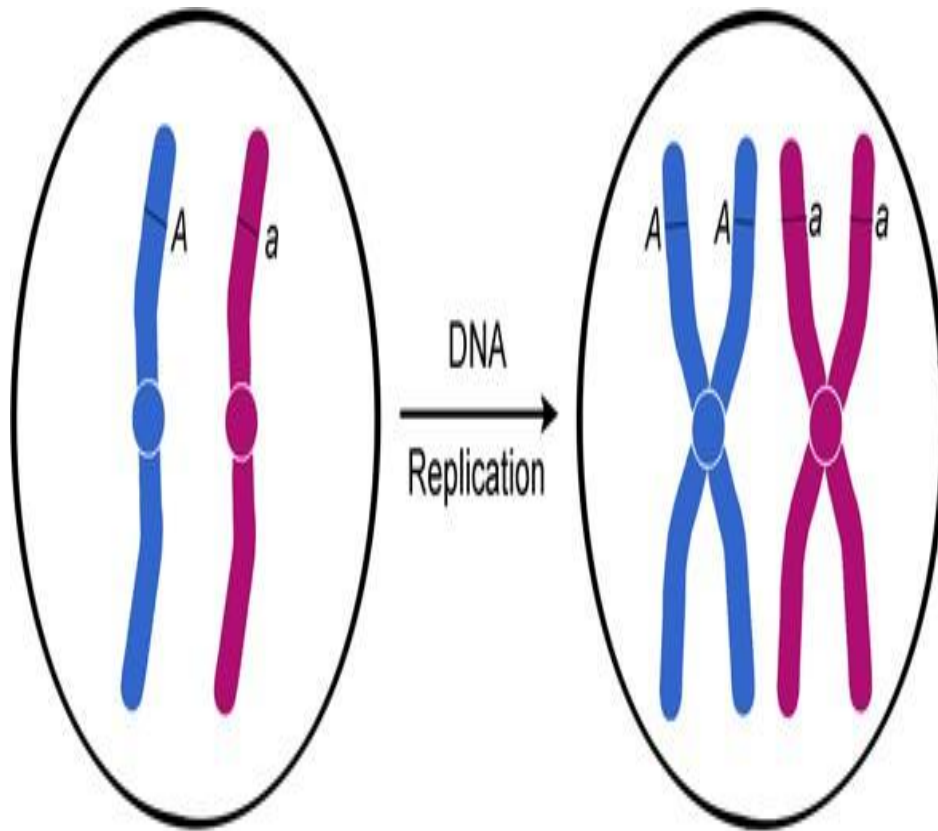
DNA synthesis phase (S phase)

- Replication of DNA, thus the amount of DNA is doubled but *not the total chromosomal number*.

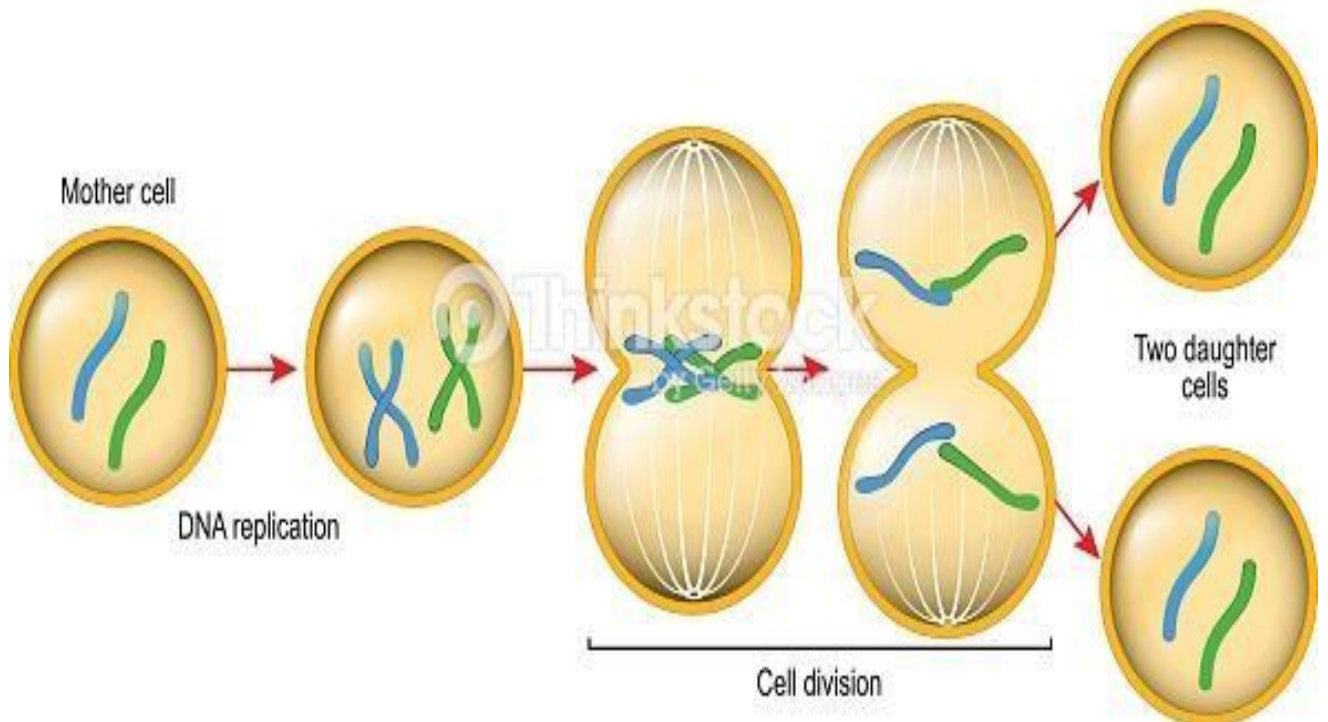


© Elsevier: Young et al. Wheater's Functional Histology 5e - www.studentconsult.com

- **Types of chromosomes** **s-chromosomes** made of one DNA molecule (interphase chromosomes = chromatin or chromatids).
- **d-chromosomes (mitotic chromosomes):** are formed during the S phase. Each d-chromosome is formed of two chromatids, linked at the centromere. Each chromatid is made of a DNA molecule.

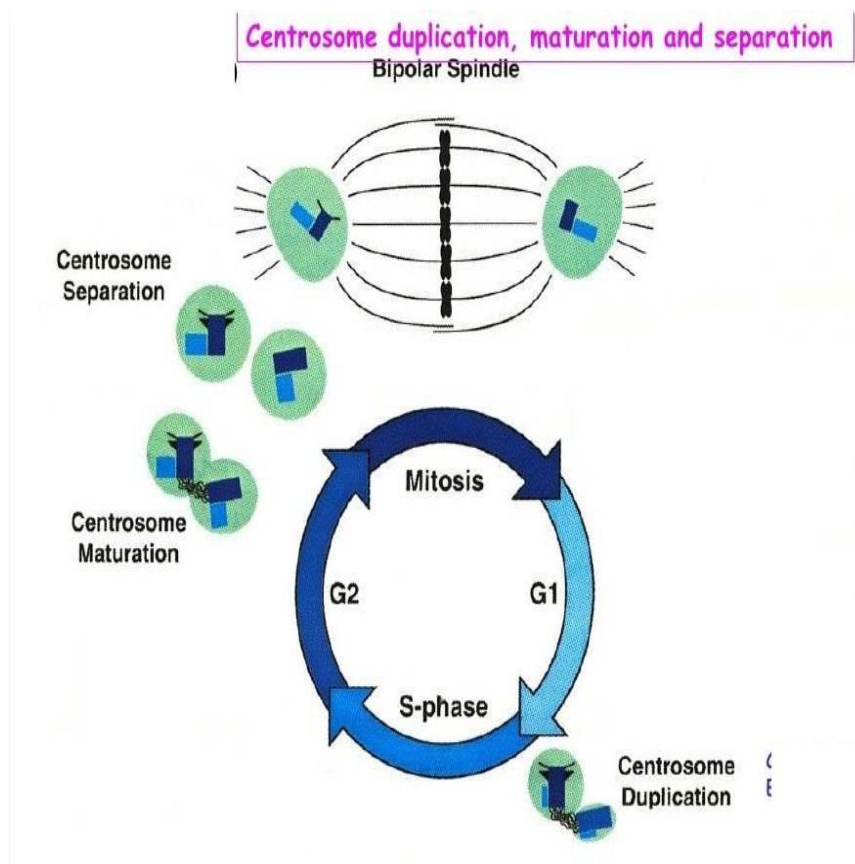


MITOSIS



Second gap phase (G₂ phase)

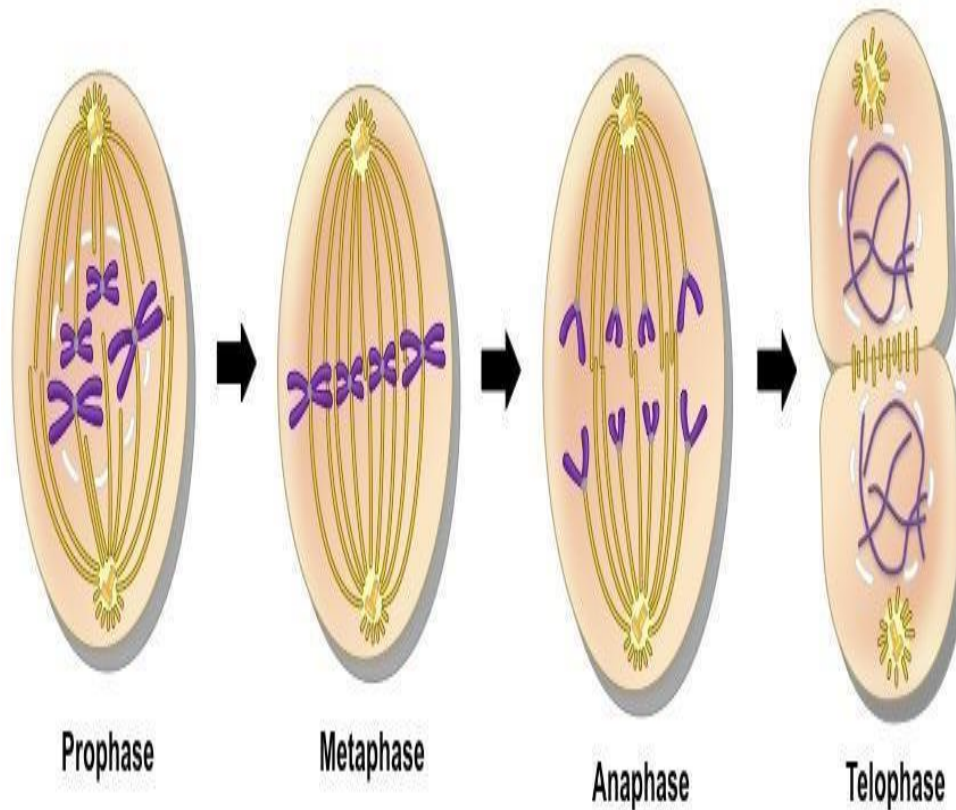
- It starts by the end of the DNA replication and lasts until the beginning of mitosis.
 - 1- Proteins and energy essential to mitosis are stored.
 - 2- Duplication of the centrosome is *completed*.



Cell division

Mitosis

- Definition: division of the somatic cell into two daughter cells identical to the mother cell.
- **Function:**
 - 1- Growth and development of the organism.
 - 2- Renewal and repair of cells.

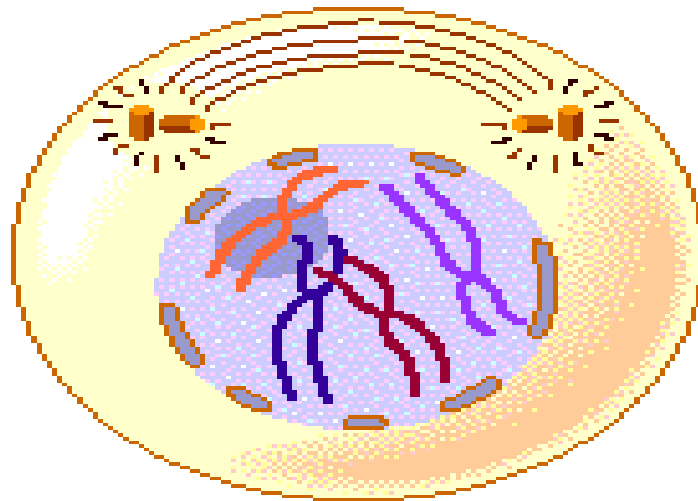
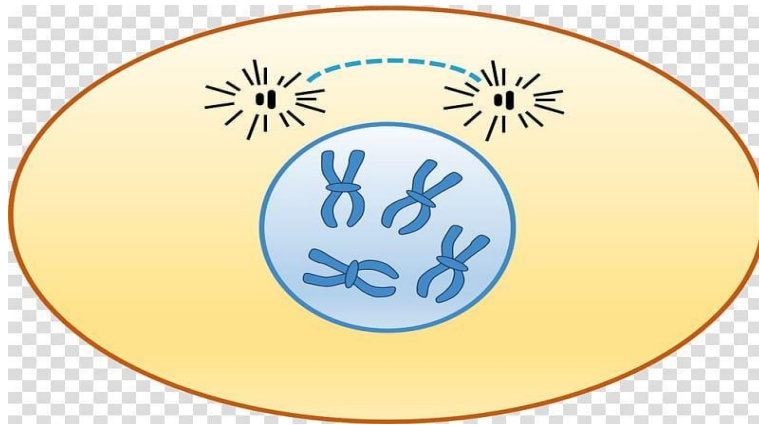


1-Prophase

- 1- The *nucleolus* disappears.
- 2- Condensation of *chromatin* gives rise to 46 rod-shaped short d-chromosomes.

3- Each pair of *centrioles* migrates to opposite pole of the cell forming the mitotic spindles.

4- The *nuclear envelope* breaks up into small vesicles

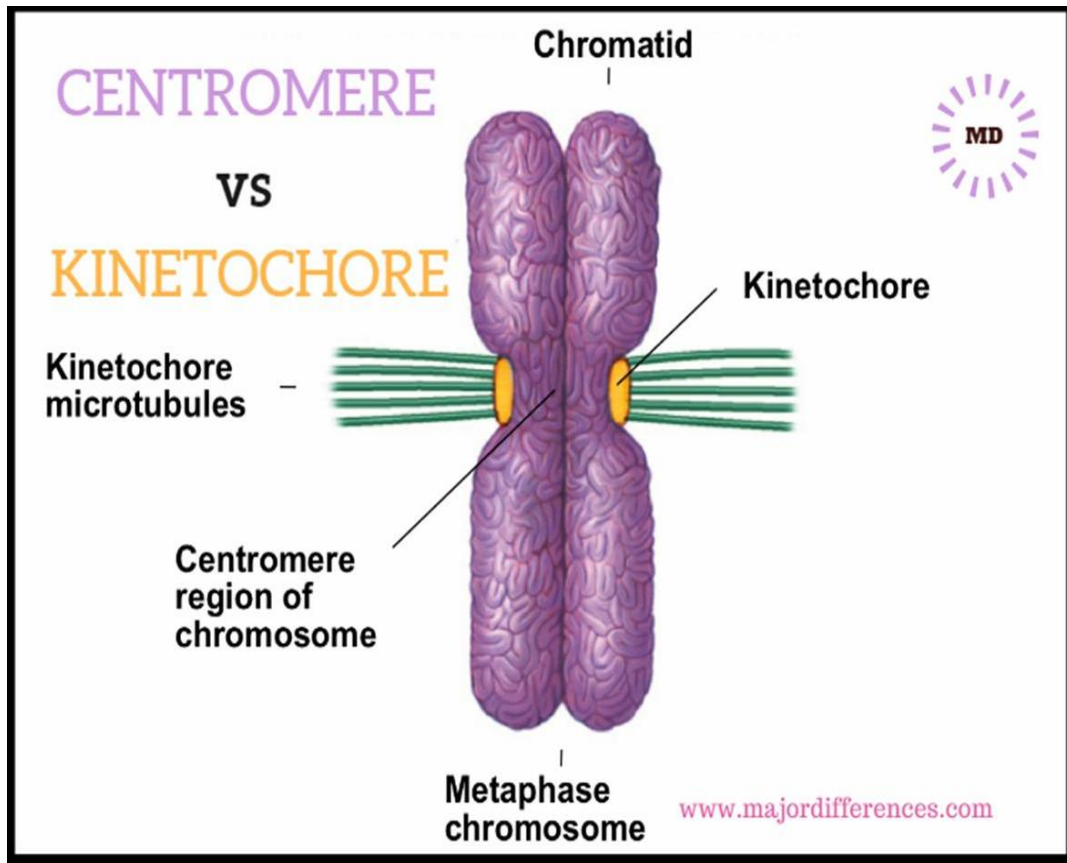


2-Metaphase

1- The 46 d-chromosomes become maximally condensed.

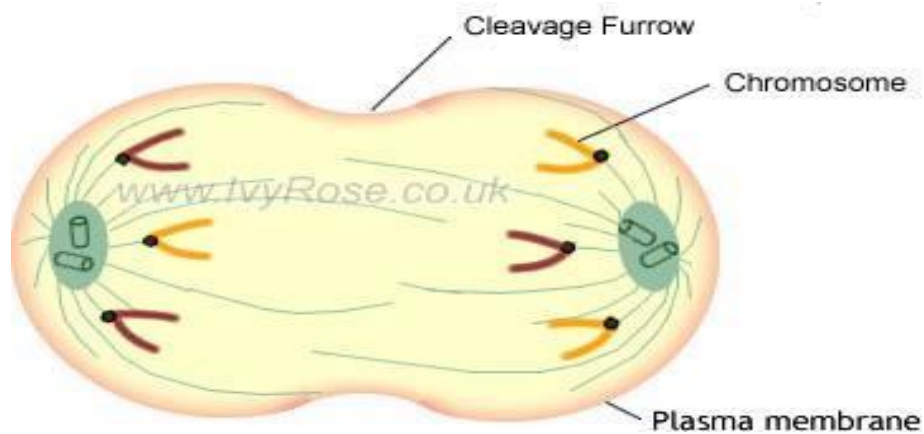
2- The chromosomes *aligned at the equatorial plate* of the cell.

- Each pair of sister chromatid is attached to the mitotic spindles at *the kinetochore*.



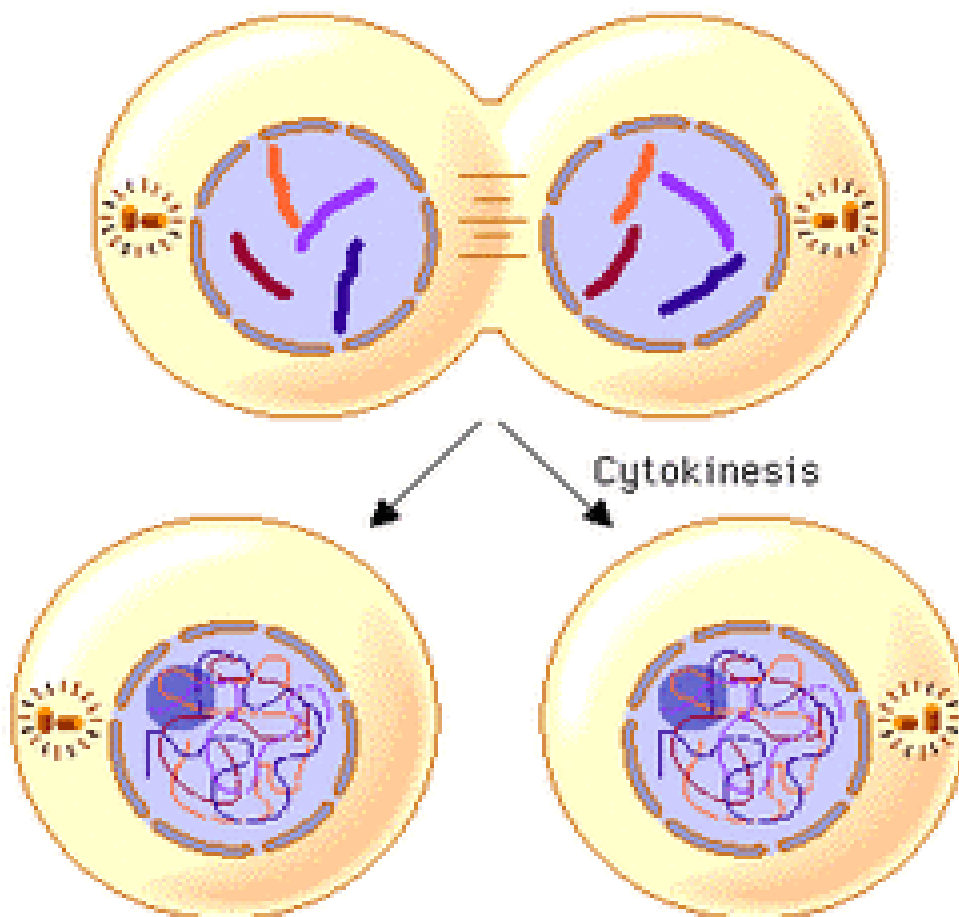
3- Anaphase

- 1- *Division of the centromere* results in the separation of the sister chromatids.
- 2- Each 46 chromatids migrate toward the opposite poles of the cell.
- 3- In late anaphase, a *constriction (cleavage furrow)* develops at the equatorial plate of the cell.



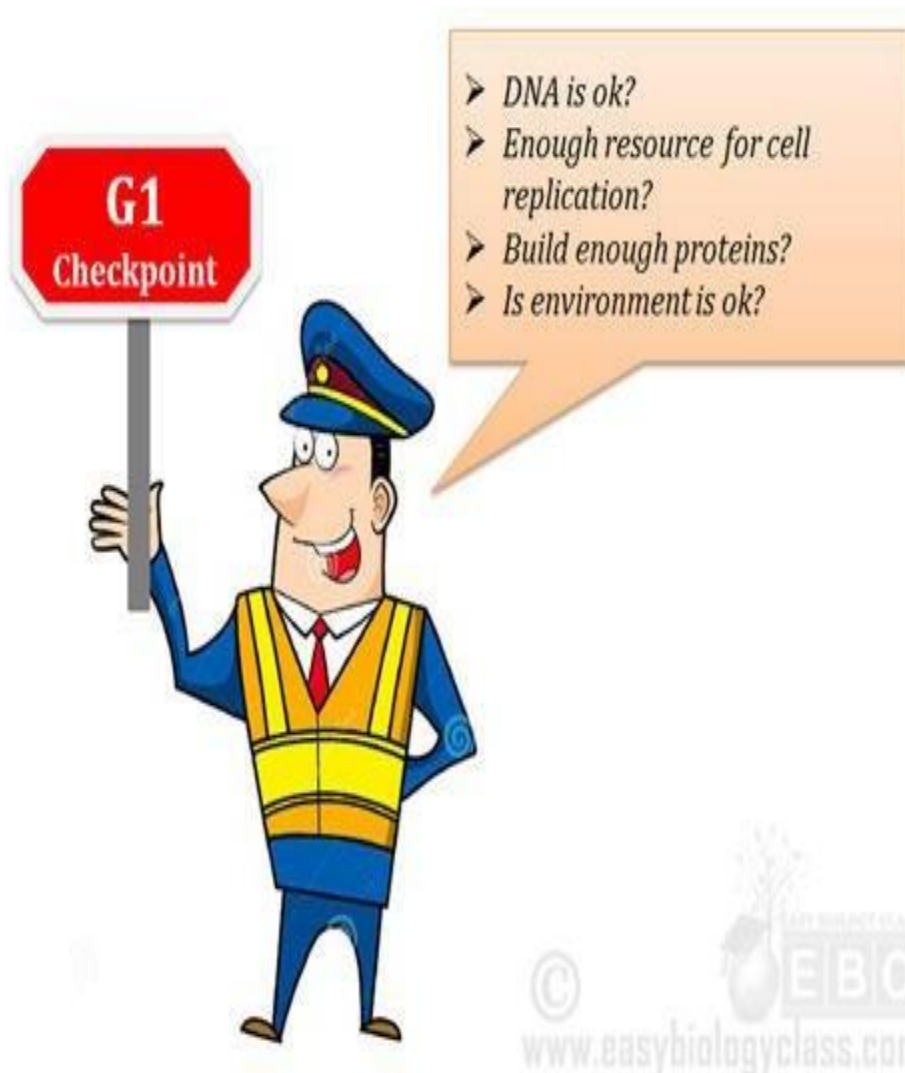4-Telophase

- 1- The *mitotic spindle* disappears.
- 2- The *nucleolus* reappears.
- 3- The *chromosomes* start uncoiling (46 s-chromosomes).
- 4- The *nuclear envelope* is reformed around the new sets of chromosomes.
- 5- Division of the *cytoplasm* (cytokinesis): the cleavage furrow becomes deeper due to the formation of a contractile ring of microfilaments until it divides the cytoplasm and its organelles in half resulting into two daughter cells.



Regulation of the cell cycle

- The cell cycle is regulated by growth factors that control cell proliferation to keep its coordination with the needs of the living organism.
- Several *checkpoints* control the transition between the cycle stages.
- Checkpoints detect external or internal problems and stop the cycle until the problem solved.



Checkpoints of cell cycle

1-The restriction checkpoint

- It occurs in the G₁ phase.
- It detects *the cell size & its interactions with the surrounding environment*.
- Cells that do not receive appropriate growth stimuli do not progress past this point (G₁ phase) and will die by apoptosis.

It is the most important checkpoint in the cell cycle

2-DNA damage checkpoints

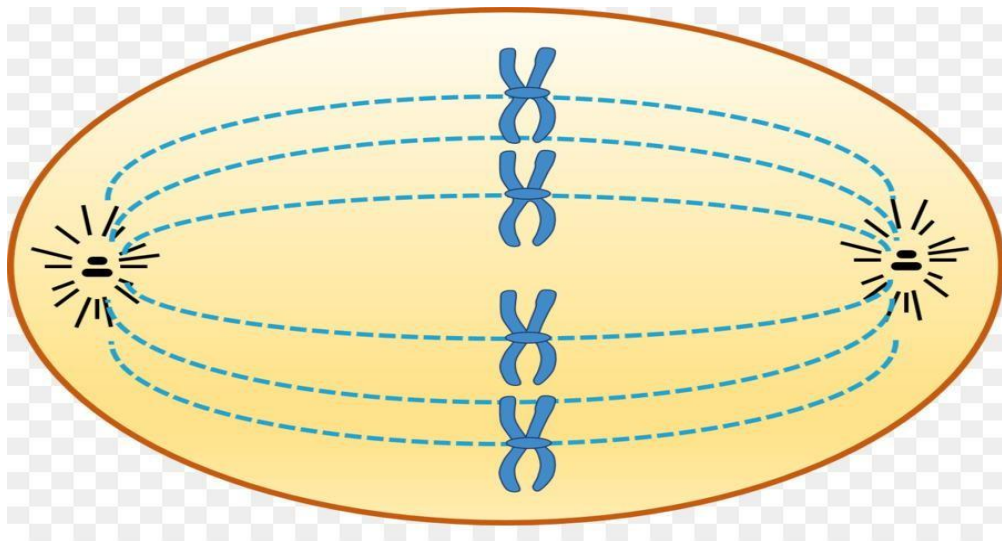
- It occur in G₁, S, and G₂ phases.
- It blocks cell cycle progression until repair of the damaged DNA or cell apoptosis occurs.

3-The unreplicated DNA checkpoint

- It occurs in the G₂ phase.
- It prevents progression of the cycle into the mitosis before complete synthesis of DNA.

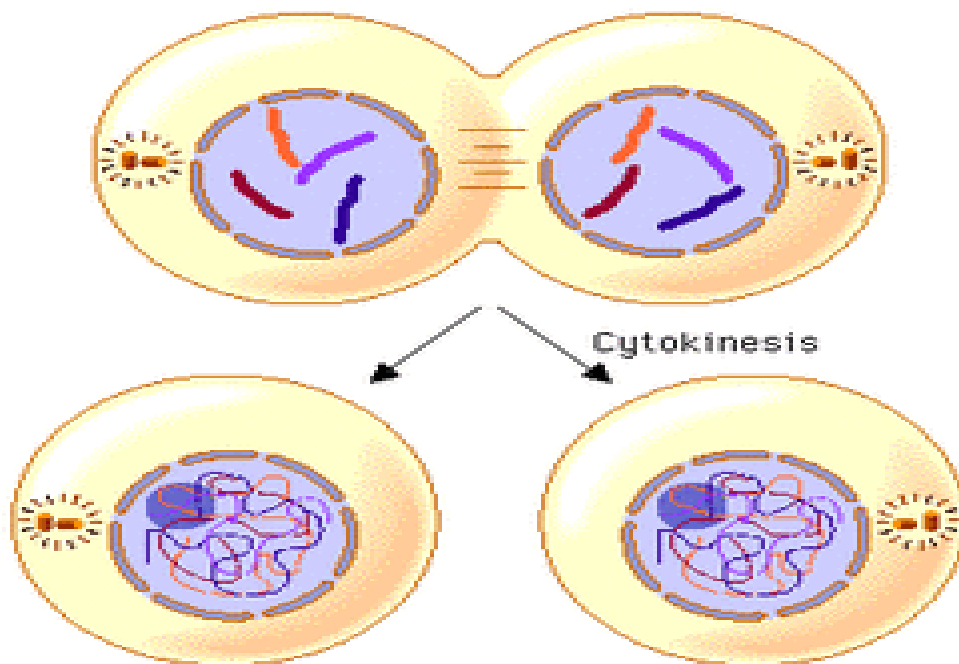
4- The spindle-assembly checkpoint (the metaphase checkpoint)

- It occurs in mitosis.
- It prevents entry into anaphase until all chromosomes have attached properly to the mitotic spindle.



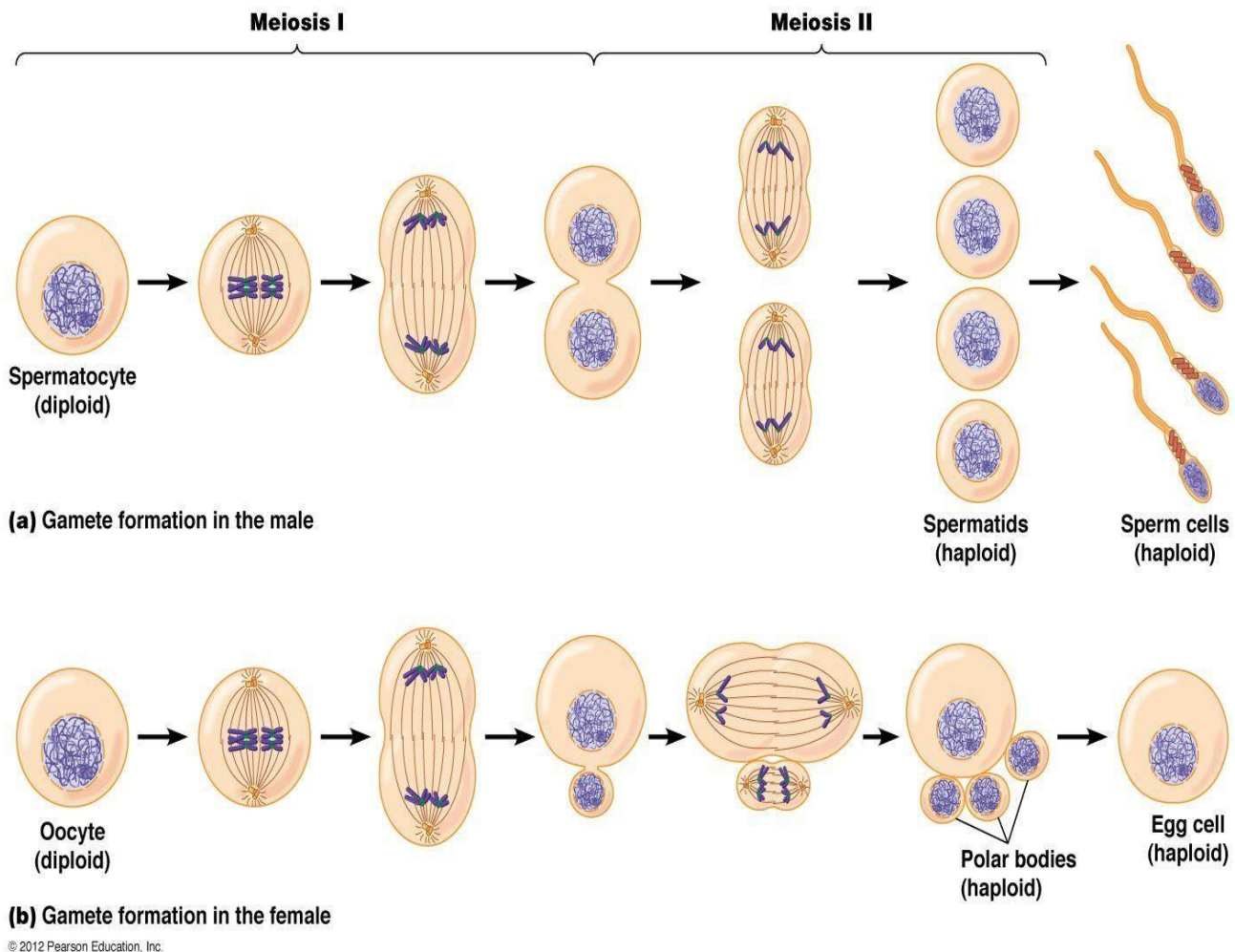
5- The chromosome-segregation checkpoint

- It occurs in telophase.
- It prevents the cytokinesis until all of the chromosomes have been correctly separated.



Meiosis

- It occurs in *germ cells* and results in the formation of gametes.
- It results in formation of *4 daughter cells* (each contains 23 s-chromosomes=haploid number).
- It consists of two successive divisions; *without an intervening S phase*.



I-First meiotic division (reductional division)

is preceded by interphase with an *S phase*, in which the chromosomes are replicated (46 s chromosomes → 46 d chromosomes).

1-Prophase I:

A- *Pairing of the homologous chromosomes* occurs forming tetrads(bivalent).

B- Crossing-over occurs between the chromatids of the homologous chromosomes so that each homologous chromosome is no longer solely paternal or maternal but a mixture of both.

3- The nucleolus and the nuclear envelope disappear and the mitotic spindle is formed.

2- Metaphase I:

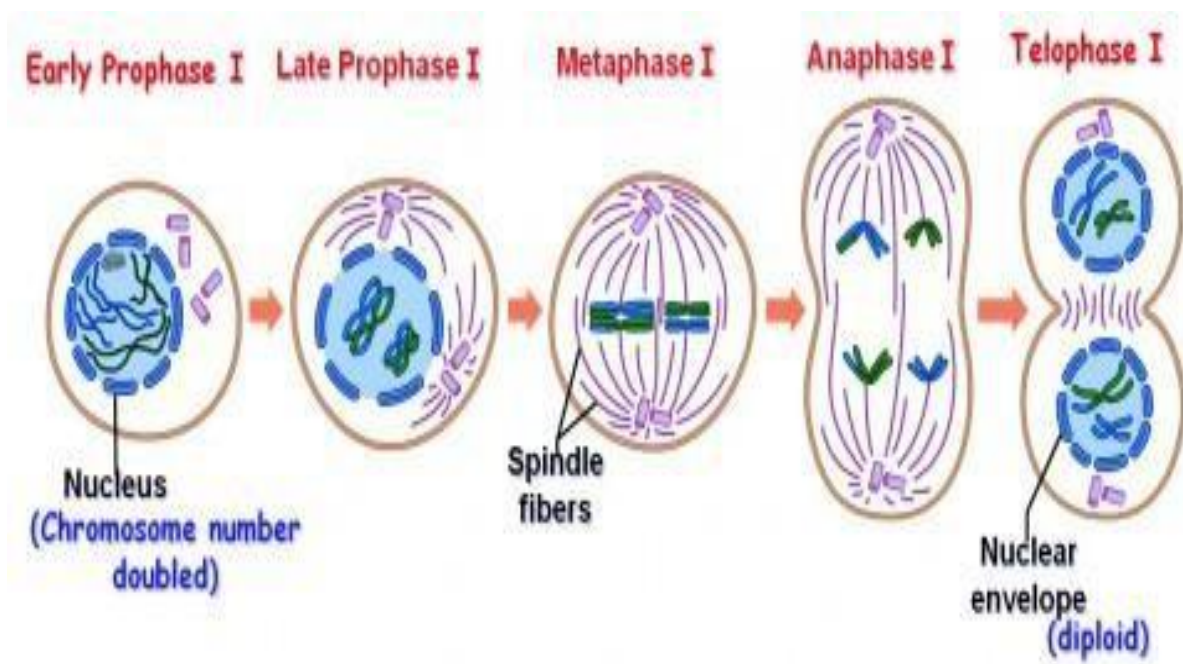
The *paired chromosomes* arrange themselves at the equatorial plate of the cell.

3- Anaphase I:

The centromeres *do not divide*, instead, each chromosome of homologous pairs moves separately towards the opposite poles of the cell.

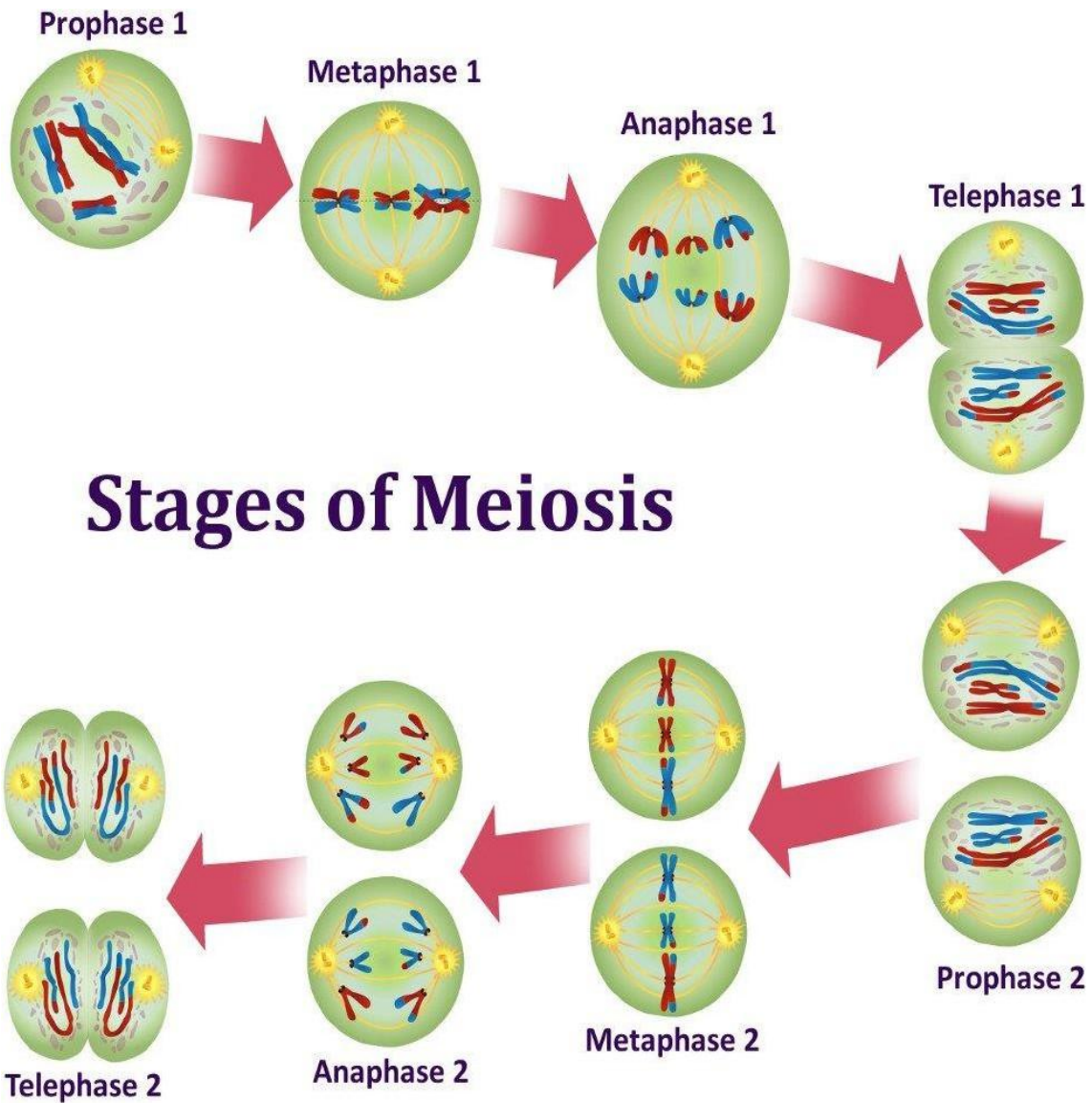
4- Telophase I:

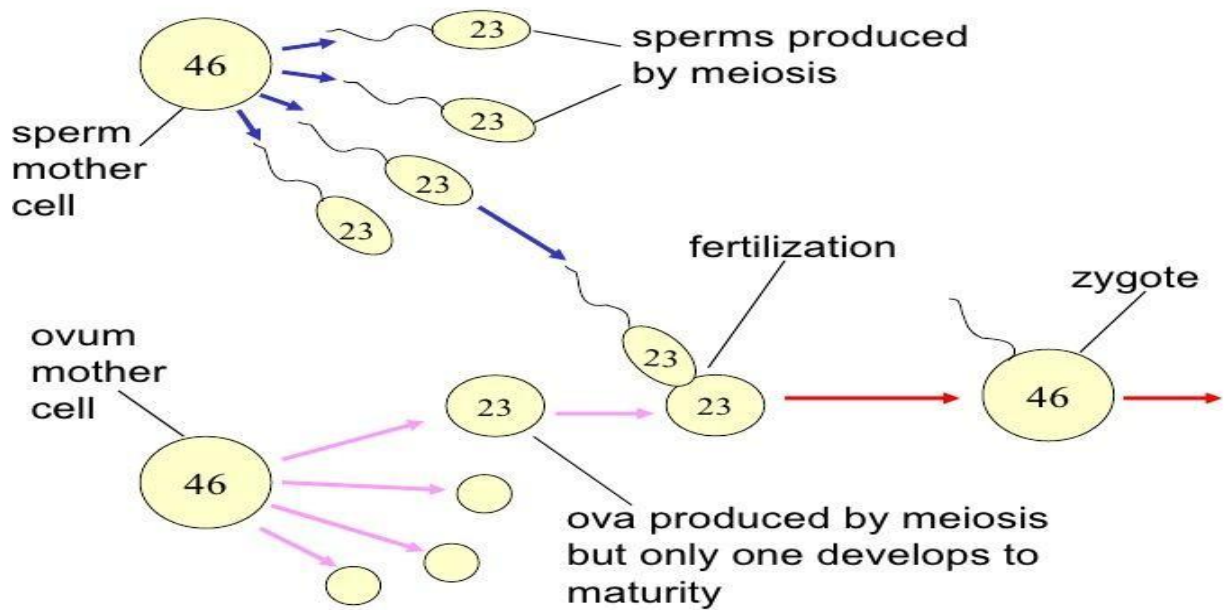
Cytokinesis occurs results in two daughter cells each containing the haploid number (23d-chromosomes).



II-Second meiotic division (equatorial division)

- It is similar to mitosis but, it is *not preceded* by S phase.
- It results information of *4 daughter cells*, each contains 23 s-chromosomes (haploid number).

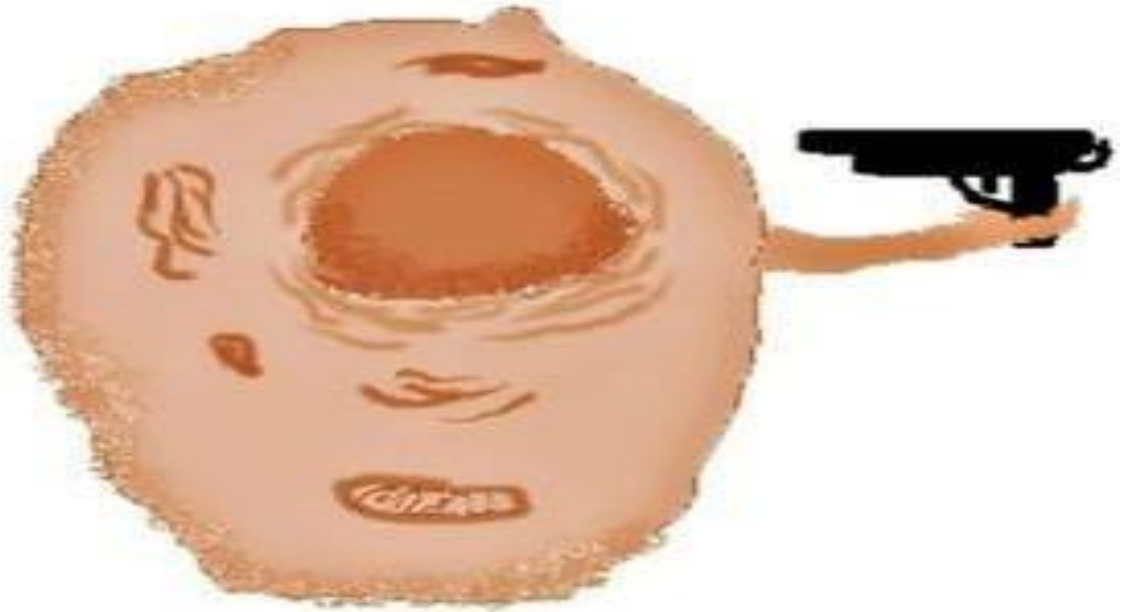



	Mitosis	Meiosis
1-Types of cells	Somatic cells	Germ cells of testis & ovaries
2- Number of division	Single division	2 successive divisions: Meiosis I & Meiosis II.
3- Interphase	Preceded by interphase with S phase	Meiosis I preceded by interphase with S phase, Meiosis II not preceded by S phase.
3- Prophase	No crossing over	Meiosis I: Crossing over occurs
4-Metaphase	46 d chromosomes arranged individually at the equatorial plane of the cells.	In Meiosis I :23 bivalent arranged at the equatorial plane of the cells.
5- Anaphase	Each chromosome divides at centromere into 2 chromatids	In Meiosis I: each chromosome of a bivalent moves apart.
6- Cells produced	Two daughter cells with diploid number of chromosomes (46 S) Daughter cells are genetically identical	Four daughter cells with haploid number of chromosomes (23 S) Daughter cells are genetically variable.

	Meiosis I	Meiosis II
1- Preceded S phase	Present (the cell enter the prophase with 46 d chromosomes).	Absent (the cell enter the prophase with 23 d chromosomes).
2- Prophase	Pairing of homologous chromosomes result in 23 tetrad. Crossing over occurs between each tetrad .	No pairing No crossing over.
3- Metaphase	23 tetrad arranged at the equatorial plane of the cells.	23 d chromosomes arranged individually at the equatorial plane of the cells.
4- Anaphase	No division of the centromere. Each chromosome moves independently to the opposite pole of the cell.	Centromere splits so each chromatid moves independently to the opposite pole of the cell.
5- Telophase	Cytokinesis results in 2 daughter cells each with 23 d chromosomes.	Cytokinesis results in 4 daughter cells each with 23 S chromosomes.

Cell death




When a cell want to die...

Types of cell death

Apoptosis



Necrosis



Necrosis = accidental cell death

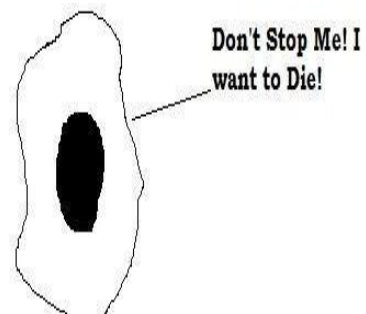
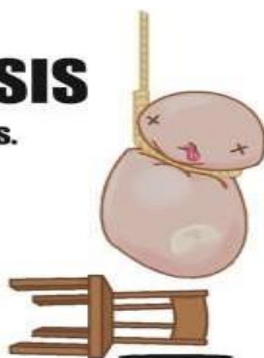
- **Causes:** It is a *pathological process* due to e.g. hypoxia, radiation or pathogens such as viruses.
- **Morphological features:**
 - 1- *Damage of the cell membrane* with cell swelling & rupture.
 - 2- Breakdown of cell organelles.
 - 3- Denaturation or coagulation of cytoplasmic proteins.
 - 4- Inflammation with extensive damage of the surrounding tissue.

Apoptosis = programmed cell death

It is a *physiological process* controlled by several genes (loss of mitochondrial function initiates several reactions that lead to cell death).

What makes a cell decide to commit suicide?

APOPTOSIS Know the signs.



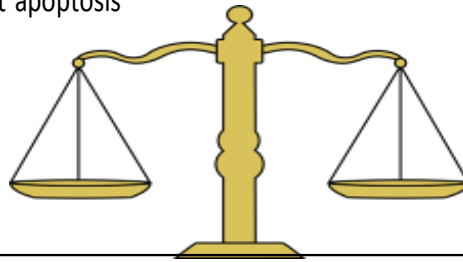
Each cell receives

Positive signals

From other cells and extracellular matrix that inhibit apoptosis

Negative signals

Promote apoptosis



There is a Balance Between them

Receiving of negative signals

OR

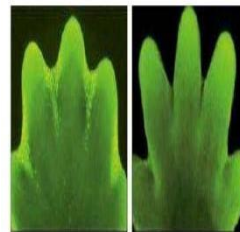
Withdrawal of positive signals



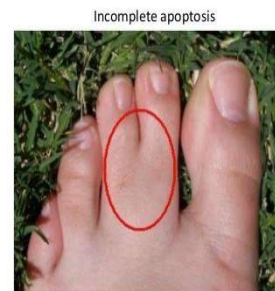Apoptosis

I-During embryonic development

Removal of excess cells that have no function e.g. during morphogenesis and for determination of organ size.



Development of toes

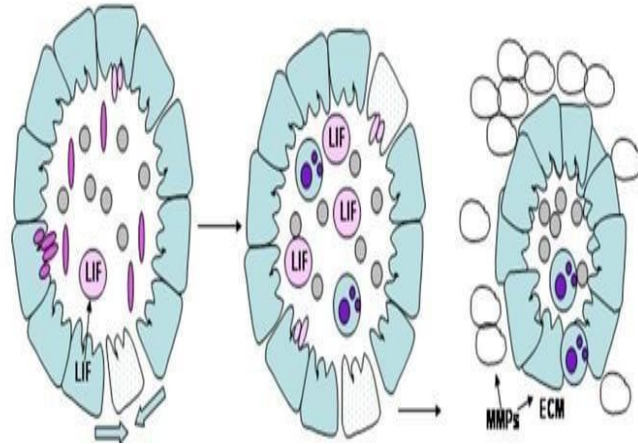


Incomplete apoptosis

II-In adult

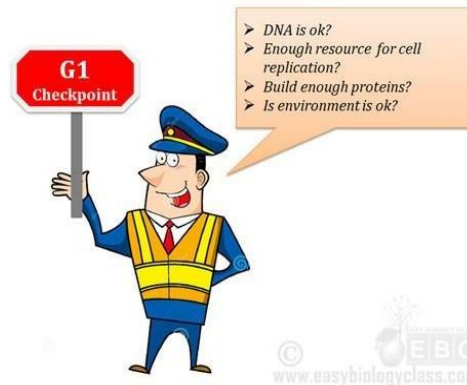1- Hormone-dependent:

- Involution of the endometrium during the menstrual cycle.
- Regression of lactating mammary gland after weaning.
- Regression of prostate in old males.



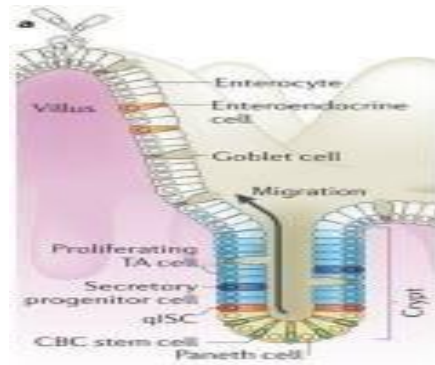
II-In adult

- 2- Elimination of cells during cell cycle when their DNA damage is not repaired.



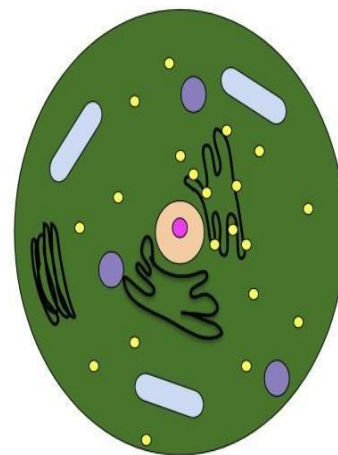
II–In adult

3– Maintaining a constant number of cells in proliferating cell populations, e.g. intestinal epithelium.

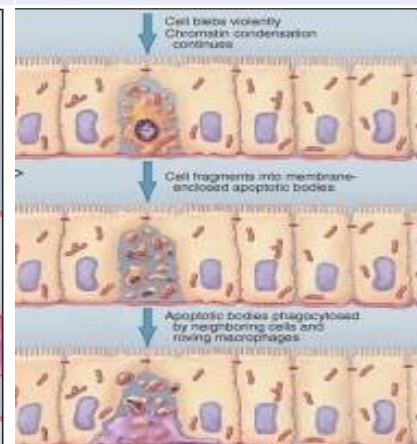
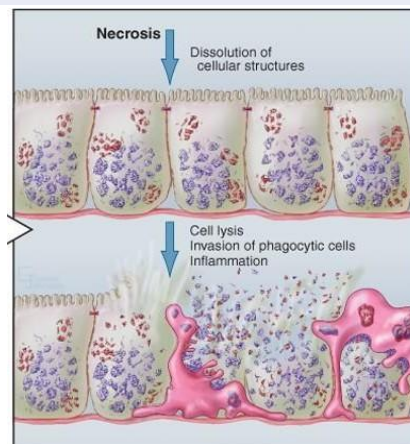


Morphological features of apoptosis

- 1– Loss of microvilli and intercellular junctions.
- 2– Shrinkage of the cell with membrane blebbing.
- 3– Breakdown of DNA with hypercondensation of chromatin and its collapse against the nuclear periphery.
- 4– Change of cell membrane characters *without loss of its integrity*.
- 5– Cell organelles remain apparently normal but become clumped inside the cytoplasm.
- 6– Fragmentation of the cell into *apoptotic bodies* that contain fragments of the nucleus, mitochondria and other organelles.
- 7– The apoptotic bodies are removed by the phagocytic cells.



	Necrosis	Apoptosis
1- Type	Pathological.	Physiological.
2- Cell membrane	Damage with loss of its integrity.	Change of some characters without loss of its integrity.
3- Organelles	Broken down.	Intact.
4- Proteins	Denatured or coagulated.	Broken down of DNA with hypercondensation of chromatin.
5- Apoptotic bodies	Absent	Present
6- inflammation	Present	Absent

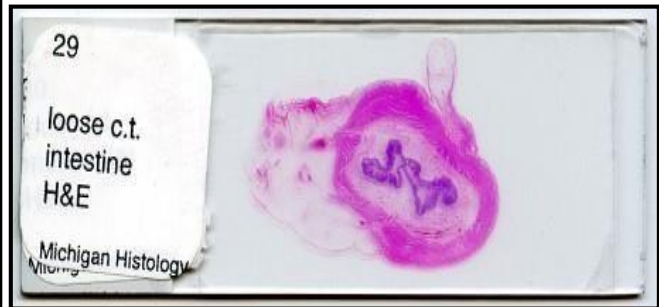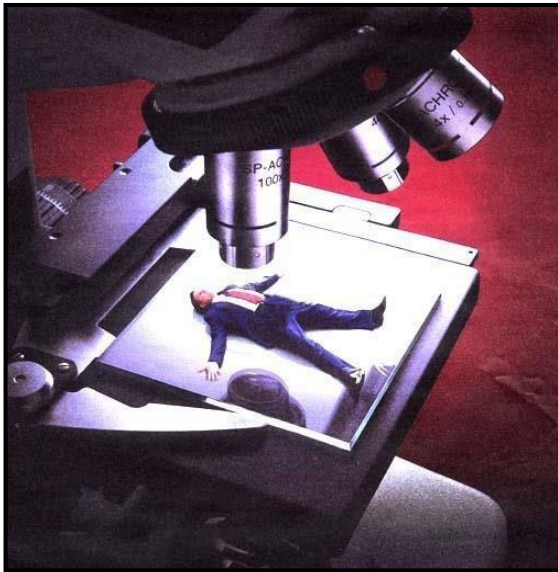


HISTOLOGY

Part

HISTOLOGY

The study of cells and tissues, a.k.a. micro-anatomy



Tissue Preparation for Light Microscopy

1. Stabilize cellular structures by chemical fixation.
2. Dehydrate and infiltrate tissues with paraffin or plastic.
3. Embed fixed tissues in paraffin or plastic blocks.
4. Cut into thin slices of 3–10 micrometer thick; collect sections on slides.
5. Re-hydrate and stain with Hematoxylin (a basic dye): Stains basophilic structures (e.g. nucleic acids) blue/purple.
6. Counter-stain with Eosin (an acidic dye): Stains acidophilic or "eosinophilic" structures (e.g. proteins, membranes) red/pink.

"H & E" staining is routine, but other dyes and staining techniques may be used to visualize other structures.

Types of tissues (A group of cells that all perform the same specific function)

1. Epithelial Tissue – covers body surfaces and organs, lines body cavities
2. Connective Tissue – binds and supports body parts
3. Muscular Tissue – contracts producing movement

4. Nervous Tissue – responds to stimuli and transmits nerve impulses

1. Epithelial Tissue

The epithelium is a sheet of aggregated cells of similar type that covers body surfaces, lines hollow organs or modified to form glands or neuroepithelium.

General Features of Epithelium

- It may originate from all three embryonic germ layers (ectoderm, mesoderm and endoderm).
- It is composed of high number of closely applied cells with very little intercellular substances.
- It is separated from the underlying connective tissue by a basement membrane.
- It is avascular, blood and lymph vessels do not penetrate the basement membrane. Thus, it receives its nutritional support by diffusion.
- The epithelial cells have high capacity for regeneration.
- The epithelium can change from one form to another in a process called metaplasia.
- It performs many functions such as protection, secretion, excretion, absorption and sensory reception.

II. Simple epithelium

It consists of single layer of epithelial cells resting on basement membrane.

الأنسجة الطلائية

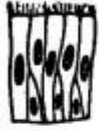Simple بسيطة

(تنظم خلاياها أساساً في طبقة واحدة)

(Cells arranged principally in one layer)

مهدبة
طبقة كاذبة

Pseudo-
stratified
ciliated



بطانة القصبة
الهوائية
Inner lining
of trachea

طبقة كاذبة

Pseudo-
stratified



الجدار المبطن
لقنوات بعض
الغدد الكبيرة
Inner wall
lining ducts
of some large
glands

عمودية
مهدبة

Ciliated
columnar



النشاء المخاطي
المبطن لتجويف
المنطقة الأمامية
لقناة البيض في
الصفدة
Mucous mem-
brane lining
the anterior
region of the
oviduct of
the toad

عمودية

Columnar



النشاء المخاطي
للقناة الهضمية
في الصفدة،
من المريء
حتى المستقيم
Mucous
membrane of
alimentary
canal of the
toad, from
oesophagus
to rectum

مكعبانية
(مكعبة)

Cuboidal



جدار الغدة
العرقية
Wall of
sweat gland

حرفشية

Squamous



البطانية ، في
جدار محفظة
بومان
Endothelium;
wall of Bow-
man's capsule

a. Simple squamous epithelium

It consists of a single layer of thin flat, scale-like cells. On surface view, the cells have an irregular shape with a slightly serrated border. Each cell has a centrally located spherical or oval nucleus.

In a side view, the cells are so flat that they can only recognize by their elongated nuclei that bulge into the lumen. The cytoplasm is scanty and has sparse organelles.

Location: lung alveoli, glomerular capsule of the kidneys, lines the blood and lymph vessels (endothelium), lines the serous membranes (peritoneum, pleura and pericardium) and is called mesothelium, lines the subarachnoid and subdural spaces (mesenchymal epithelium), the anterior chamber of the eye and perilymphatic spaces of the ear.

b. Simple cuboidal epithelium

It consists of a single layer of cube-like cells whose width and heights are nearly equal. In sections, the cells are square with spherical centrally located nuclei. It is usually located in organs that have secretory or absorptive functions.

Locations: thyroid follicles, glandular ducts and kidney tubules.

c. Simple columnar epithelium

It consists of a single layer of tall, narrow cells having greater height than width. The nuclei are oval and are located near the base of the cells.

Locations: simple columnar absorptive with microvili (small intestine, gall bladder), simple columnar secretory (stomach) or simple columnar ciliated (oviducts and bronchioles).

d. Pseudostratified columnar epithelium

It is composed of single layer of irregular cells. All the cells rest on the basement membrane but not all the cells reach to the luminal surface. The nuclei are located at

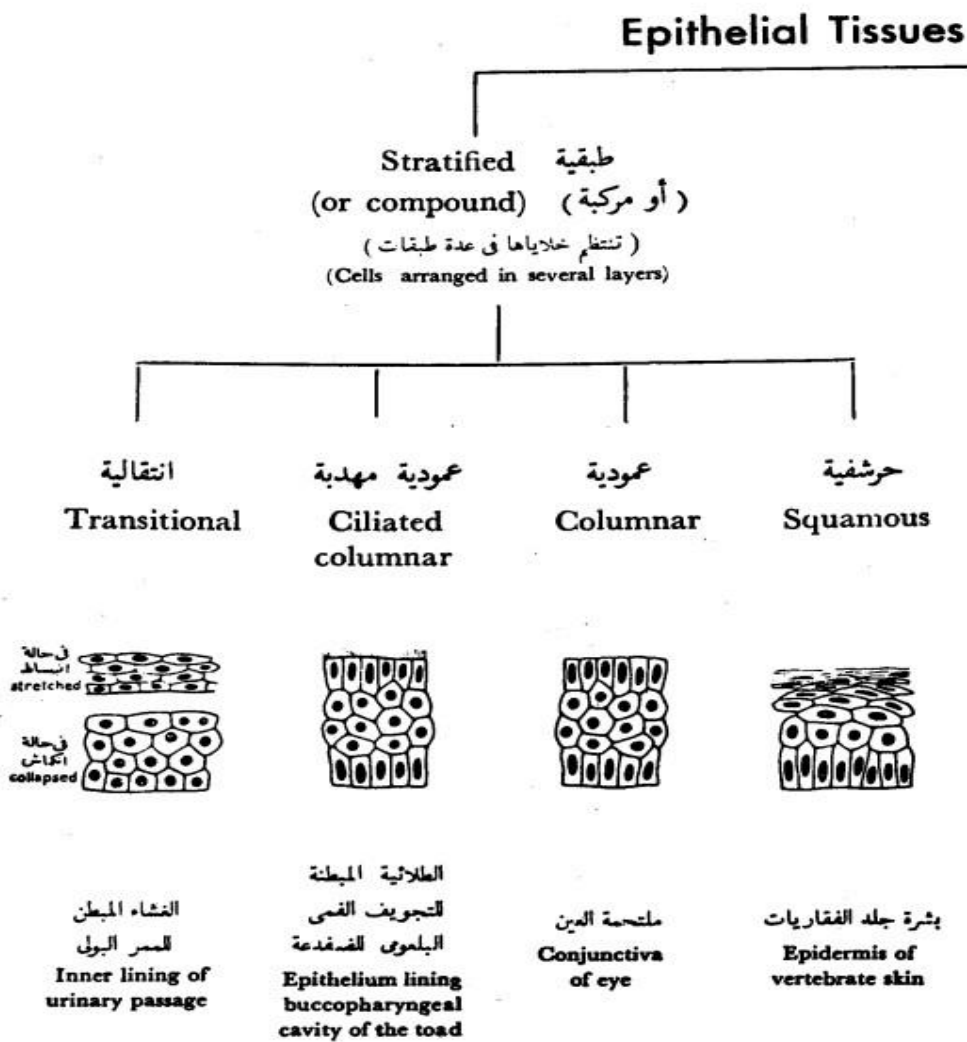
different levels, thus creating the illusion of cellular stratification. The cells reaching the surface are either ciliated or goblet cells.

The short cell acts as progenitors for the tall cells. The pseudostratified columnar ciliated epithelium may be differentiated from the stratified epithelium by 1) cilia are never exists on stratified epithelium. 2) the apical cytoplasm of the cell forming the pseudostratified epithelium does not contain nuclei.

Locations: in reproductive and respiratory epithelium.

II. Stratified epithelium

It consists of two or more than two layers of cells.



b. Stratified squamous epithelium

It consists of several layers of cells with only the superficial cells having squamous shape.

c. Stratified squamous non-keratinized epithelium

It consists of three layers:

1. Stratum basale is a single layer of cuboidal to columnar cell rest on a wavy basement membrane.

2. Stratum spinosum is composed of several layers of polyhedral cells tightly adhere to each other by numerous desmosomes. In H&E sections, the desmosomal attachments appear as small spiny processes, hence the name of this layer (spiny layer or stratum spinosum). The stratum basale and the deep layer of stratum spinosum are involved in active mitosis, therefor this region is referred to as stratum germinativum.

3. Stratum squamosum is the superficial layer and is made up of few layers of flat squamous cells with ovoid small nuclei.

Locations: oral cavity, pharynx, esophagus, anal canal, and vagina. Such sites are normally subjected to moderate mechanical abrasion and are kept moist by local glandular secretions.

d. Stratified squamous keratinized epithelium

It consists of five layers:

1. Stratum basale: consists of single layer of cuboidal to columnar cells resting on a wavy basement membrane.

2. Stratum spinosum: has the same structure as that of the stratified squamous non-keratinized epithelium.

3. Stratum granulosum consists of few layers of flattened cells having small pyknotic nuclei and rich in keratohyaline granules.
 4. Stratum lucidum found only in non-hairy skin. It is a layer of flattened, keratinized cells between the stratum granulosum and stratum corneum. It has a translucent or shiny appearance because the cytoplasm of these cells is rich in protenecious materials called eleidin.
1. Stratum corneum is the outermost layer and consists of dead, keratinized cells. The cells have lost their nuclei and their cytoplasm filled with keratin that is a water-resistant protein.
 2. Stratum disjunctum formed of groups of cells in the outermost layer of the stratum corneum that become loose and detach to constitute this layer.

Locations: epidermis, hoof and horns.

e. Stratified cuboidal epithelium

It consists of two or more layers of cells, with only the superficial cells having a cuboidal shape. It is frequently occurs as two-layered epithelium located in the large glandular ducts.

f. Stratified columnar epithelium

It consists of several layers of cells with only the superficial layer having tall columnar cells.

Locations: distal portion of the urethra, parotid and mandibular ducts, lacrimal sac and lacrimal duct.

g. Transitional epithelium

It is a form of stratified epithelium found only in the urinary tract (lines the ureter and urinary bladder). It is highly specialized to resist a great degree of stretch and to withstand the toxicity of urine.

In relaxed state (empty bladder) it consists of 4-5 layers of cells, the basal layer is cuboidal in shape rests on thin basal lamina . The intermediate layer consists of several layers of polyhedral or pear-shaped cells. The surface cells are large cuboidal or dome-shaped with convex outer surface and concave inner surface. Their nuclei are large, spherical with prominent nucleoli, some cells are binucleated.

In stretched state (full bladder) it appears only as two or three cell layers thickness. The intermediate and surface layers are extremely flattened. The superficial cells have a thicker plasmalemma that acts as a barrier against diffusion of fluid from the subepithelial tissue to the hypertonic urine.

Membrane specialization of epithelia

The basal, luminal and intercellular surfaces of epithelial cells have a variety of specializations.

1. Basal surface
2. Basement membrane

The epithelium is separated from the underlying connective tissue by a thin membrane known as basement membrane . It consists of two layers; basal lamina and reticular lamina.

The basal lamina is synthesized by the adjacent epithelial cells and is located in contact with the epithelial basal plasmalemma. It is composed of type IV collagen embedded in an amorphous matrix of structural glycoprotein called laminin.

The reticular lamina is derived mainly from the underlying connective tissue and is located deep to the basal lamina. It consists of fine reticular fibers embedded in an amorphous ground substance.

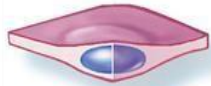In addition to underlying all epithelia, a basal lamina is found around muscle cells, neurolemmocytes and between epithelia in the renal corpuscle.

The basement membranes are difficult to resolve in common H&E sections, however, they can be selectively stained with silver (black) or PAS (magenta color).

Functions

1. Support epithelial surfaces.
2. It may act as selective filter, such as the glomerular basement membrane of the kidneys.
3. It acts as a selective barrier to passage of cells between epithelia and connective tissue. For example, they permit the passage of the immune cells but prevent epithelial and connective tissue cells.


Cell shapes



Squamous

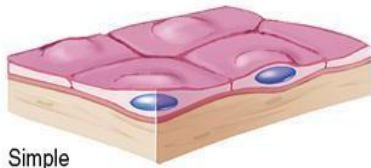


Cuboidal

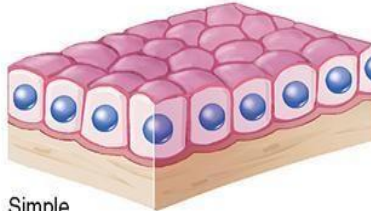


Columnar

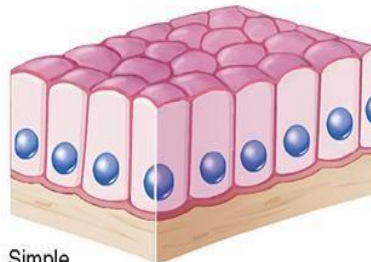
Simple



Simple squamous

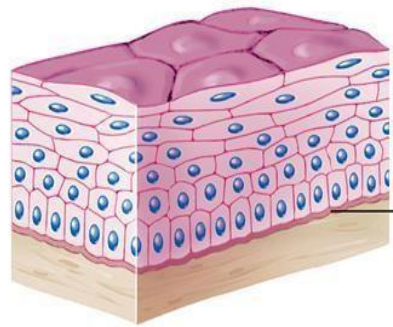


Simple cuboidal



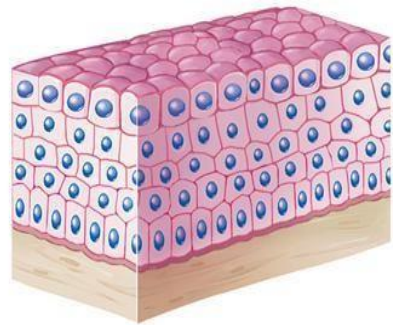
Simple columnar

Stratified



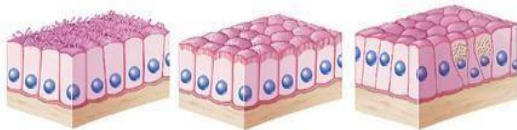
Basement membrane

Stratified squamous



Stratified cuboidal

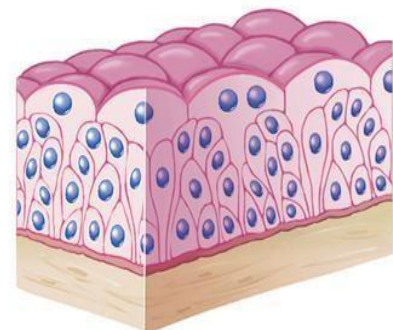
Examples of columnar tissue



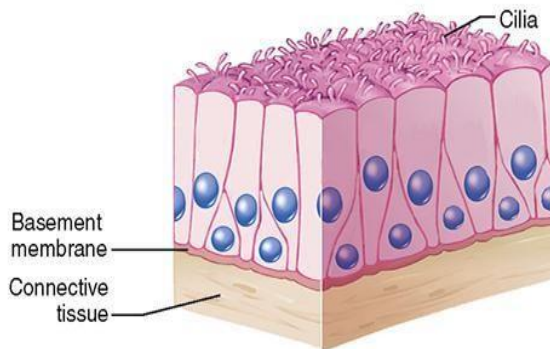
Ciliated

With microvilli (brush/striated border)

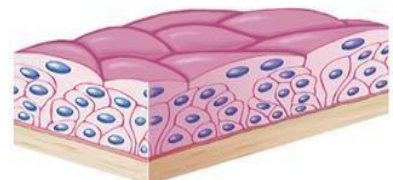
With goblet cells



Transitional, relaxed

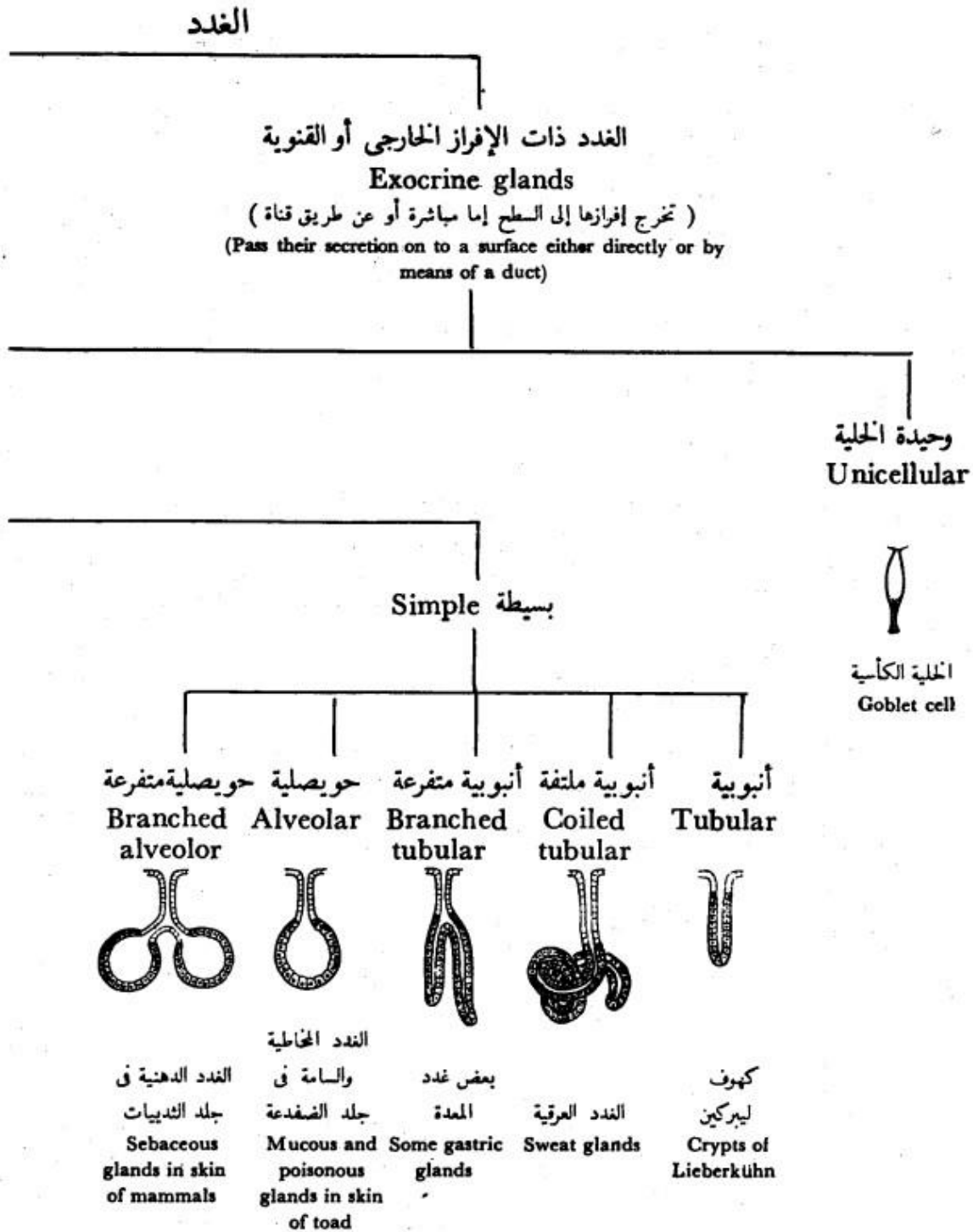


Pseudostratified columnar



Transitional, stretched

Glandular epithelium



The Glands

الغدد ذات الإفراز الداخلي أو الصم
Endocrine or ductless glands
(تخرج إفرازها إلى الدم أو اللمف مباشرة)
(Pass their secretion directly into the blood or lymph)

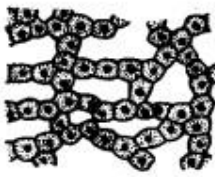
مثل الكظر
e.g. Adrenal gland

Multicellular

عديدة الخلايا

Compound مركبة

شبكة
Reticular



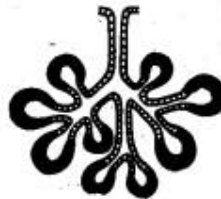
كبد الثدييات
Liver of mammals

أنبوبية حويصلية
Tubulo-alveolar



البنكرياس والغدد
البنية
Pancreas and
mammary glands

حويصلية
Alveolar



الغدة اللعابية
Parotid salivary
gland

أنبوبية
Tubular



الغدة الدمعية
Lacrymal gland

Classification

1. According to the presence or absence of ducts

2. Exocrine glands

They are glands that have a duct system to convey their secretory products to the sites of utilization (e.g., salivary glands).

1. Endocrine glands

They do not have a system of duct (ductless). The secretory product (hormone) reaches the site of utilization through blood or

lymph (e.g., pituitary gland and thyroid gland).

2) According to the number of cells forming the gland

Unicellular glands

It consists of a single secretory cell in a non-secretory epithelium (e.g., goblet cells).

Multicellular glands

It is composed of more than one cell (e.g., salivary gland).

3) According to the morphology of duct and the secretory parts

1. Simple tubular where the duct is not branched and the secretory part is in the form of tubule (e.g., glands of the large intestine).

2. Simple acinar or alveolar glands where the duct is not branched and the secretory part is in the form of alveolus or acinus (e.g., sebaceous gland and the glands of skin of amphibians).

1. Simple tubuloalveolar glands where the duct system is not branched and the secretory part is tubular and alveolar (are rare).

4. Simple branched tubular where the duct is not branched while the tubular secretory part is branched (e.g., glands of the stomach).
5. Simple branched alveolar where the duct is not branched while the alveolar secretory part is branched (e.g., sebaceous glands).
6. Simple branched tubuloalveolar where the duct is not branched while the tubular and alveolar secretory part is branched (e.g., minor salivary glands).
7. Compound tubular glands where the duct is branched and the secretory parts are tubular (e.g., liver).
8. Compound alveolar glands where the duct is branched and the secretory parts are alveolar (e.g., mammary glands).
9. Compound tubuloalveolar glands where the duct is branched and the secretory parts are tubular and alveolar (e.g., salivary glands and pancreas).

4) According to the nature of secretion

1. Mucous glands

They produce thick, viscous secretions (mucus). The cells of the mucous secretory units are cuboidal in shape and

filled with mucinogen, the precursor of mucus that stain light (foamy or vacuolated) in H&E.

The nuclei are flattened and rest on the basement membrane. The lumen is wide (e.g., palatine glands and the glands of the tongue).

2. Serous glands

They produce thin watery secretion.

The cells of the secretory units are pyramidal in shape. The nuclei are spherical and situated near the center of the cells.

The cytoplasm has two zones, basal zone that appears basophilic due to the presence of rER and apical eosinophilic zone due to the presence of zymogen granules. (e.g., parotid glands and pancreas).

3. Seromucoid or mixed glands

They produce mixed secretions.

They consist primarily of mucous secretory units with crescent-shaped clusters of serous cells (serous demilunes)

located at the periphery of the mucous units.

The serous secretion reaches the lumen through intracellular canaliculi located between the mucous cells. (e.g., submandibular and sublingual salivary glands).

5) According to the mode of secretion

Merocrine glands (secretion without loss)

The cells of which remain intact and not destroyed during the process of secretion. The secretory granules are

discharged by exocytosis (e.g., salivary glands).

Apocrine glands (secretion with apical loss)

The apical parts of the cells are destroyed during the secretory process (e.g., some sweat glands and

mammary glands).

Holocrine glands (secretion with whole loss)

The whole secretory cells are discharged then destroyed to release the secretory product (e.g., sebaceous glands).

2. Connective Tissue

It is one of the basic tissues of the body designed primarily to connect and support various others tissues.

General Features

The connective and supportive tissues are derived from the mesoderm. However, the ectoderm of the head region may also contribute to their formation.

The connective tissues are made up of three main components:

Cells (widely separated from each other)

Fibers (different types)

Amorphous ground substances.

It is well vascularized.

It performs many functions:

- a. Mechanical functions: Connection, Support, e.g., bone and Protection e.g., bone and cartilage.
- b. Body defenses: Presence of phagocytes, Presence of immunocompetent cells and Physical properties of the ground substances which act against the spread of pathogenic organism.
- c. Storage: Water and electrolytes, Fat in adipose tissue.

d. Temperature (heat) regulation: Adipose tissue.

e. Tissue repair: Formation of scar tissue.

The connective tissue proper is formed of:

1. Cells
2. Fibers
3. Amorphous ground substance

1. Connective tissue cells

The cells of the connective tissue are divided into two main groups:

Fixed or permanent cell

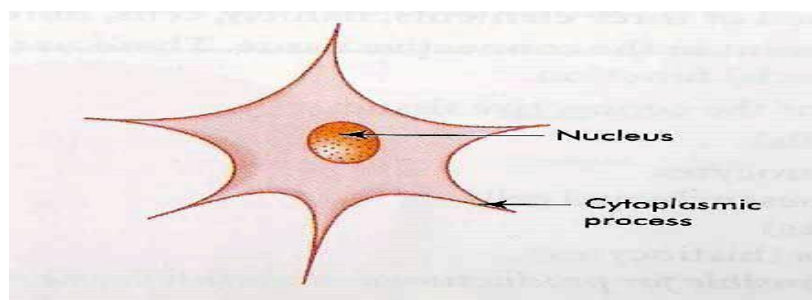
Mesenchymal cells

They have an irregular stellate shape with delicate branching cytoplasmic processes that form an interlacing network throughout the tissue. The nucleus is oval with dispersed chromatin and prominent nucleoli.

Functions

Mesenchymal cells are relatively unspecialized and are capable of differentiation into all types of connective tissue cells including that of the skeleton and smooth muscles.

Some mesenchymal cells remain in mature connective tissue and provide a source for other types of connective tissue cells.



Macrophages (histiocytes)

The connective tissue macrophages may be seen in two forms: fixed macrophage or histiocytes and stimulated or active macrophage.

a. Fixed macrophages or histiocytes

It is considered one of the fixed connective tissue cells. The cells are stellate or fusiform that are difficult to distinguish from fibroblasts.

They could be differentiated from fibroblasts through:

They have smaller and darker nuclei.

They give a strong positive reaction when stained for lysosomal enzymes such as acid phosphatase.

They can be stained vitally with vital dyes such as trypan blue.

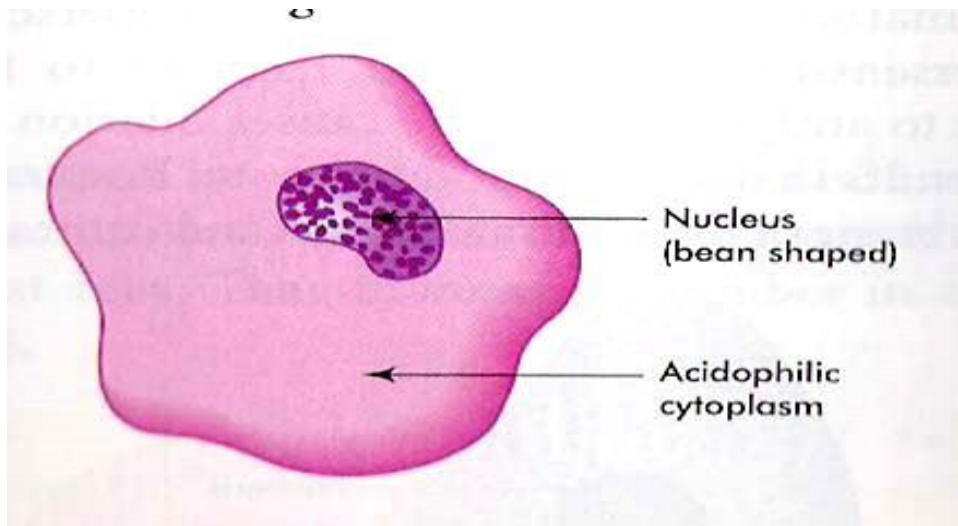
b. Stimulated or active macrophages

They are large ovoid or spherical cells with eccentric kidney-shaped nuclei and foamy cytoplasm.

At the EM level, the macrophage nucleus is indented with heterochromatin typically clumped around the nuclear envelope.

Actively phagocytic cells exhibit irregular cytoplasmic projections or pseudopodia.

The cytoplasm shows well-developed Golgi apparatus, abundant lysosomes, many phagosomes and residual bodies, a few mitochondria and variable amount of free ribosomes and rER.



Functions

Phagocytosis.

Antigen processing and antigen presentation thus participating in both humoral and cell mediated immunity.

Synthesis and secret many substances such as lysozyme (antibacterial agent), interferon (antiviral), interleukin that are essential for the proliferation of T and B-lymphocytes.

Many macrophages can fuse with each other forming large multinucleated cells called foreign body giant cells that can engulf large foreign bodies.

The macrophage and blood monocytes are considered identical. Monocytes circulate in the blood then they migrate to the connective tissue where they are called macrophages.

The macrophages are present practically in all organs, constituting a diffuse system called mononuclear phagocyte system.

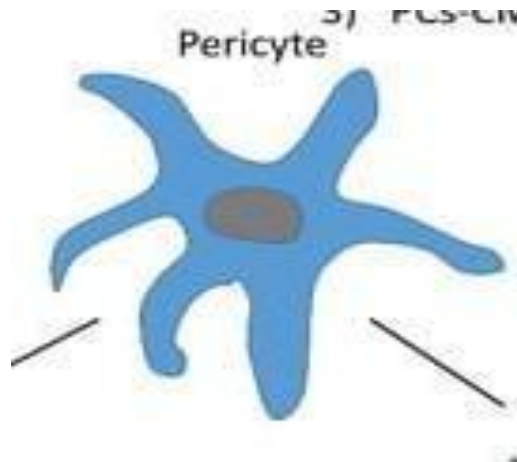
They may have other names such as: osteoclasts in bone; monocytes in blood; dust cells or heart failure cells in lung alveoli; Kupffer cells in liver, and microglia in the central nervous system.

Pericytes

Pericytes are elongated connective tissue cells with long cytoplasmic processes located external to the endothelium of blood capillaries and small venules.

They share a common basal lamina with the adjacent endothelial cells.

They have a fusiform nucleus and scanty cytoplasm that contains many mitochondria, rER, free ribosomes, and small Golgi complex.



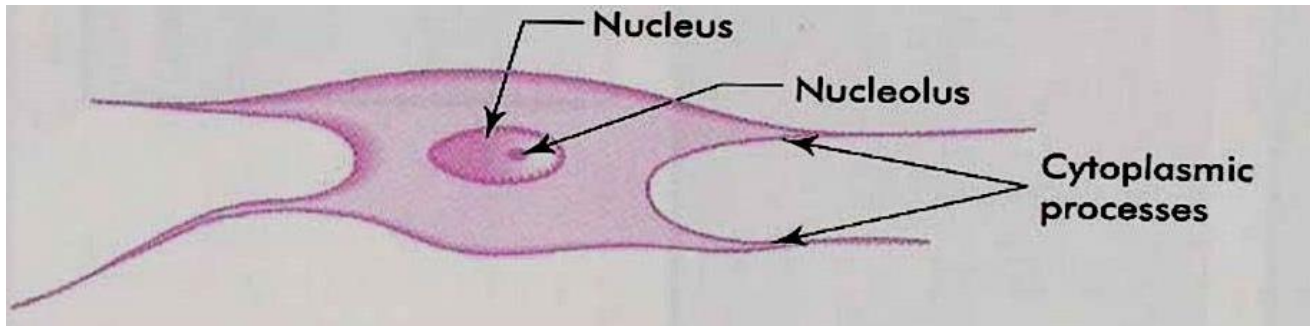
Functions

The pericytes are undifferentiated cells, they serve as progenitor for fibroblasts, osteocytes, chondrocytes and smooth muscle cells.

Fibroblasts and fibrocytes

Fibroblasts or fiber-forming cells are the most common type of fixed connective tissue cells. Active fibroblasts are demonstrated in healing wounds. They have large ovoid lightly stained nuclei with prominent nucleoli. The cytoplasm is extensive and strongly basophilic with numerous interconnected cytoplasmic extensions. At the EM level, the cytoplasm is rich in rER and the Golgi apparatus is well developed.

The inactive fibroblasts (fibrocytes) are smaller and appear spindle in shape with fewer processes. At the EM level, the small quantities of cytoplasm contain sparse network of rER, poorly developed Golgi and few organelles.



Functions

Fibroblasts synthesis and secret the precursors of collagen (tropocollagen), elastin (tropoelastin), the glycosaminoglycans, and all other extracellular components.

They are the principal cells involved in wound repair and growth of connective tissue.

Free, wandering or visitant cells of connective tissue

Adipose cells (Adipocytes)

There are two types of fat cells; white (monolocular) and brown (multilocular).

The white adipocytes are polygonal or spherical in shape. The cell occupied by a single large lipid droplet surrounded by a thin rim of cytoplasm.

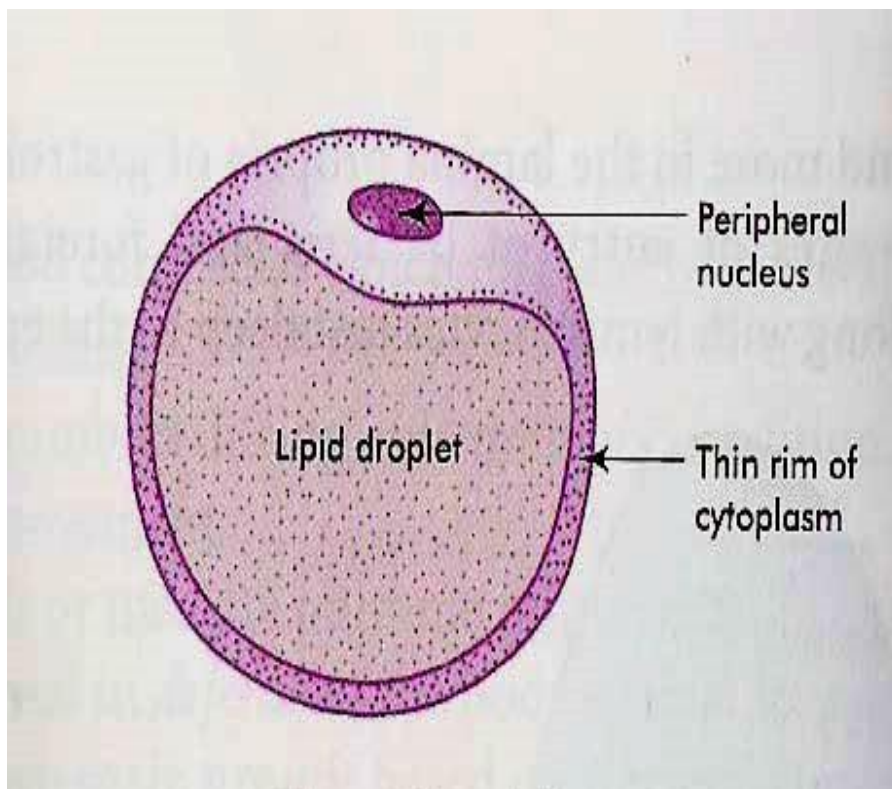
The nuclei are flattened and displaced to on side. In H&E sections, fat is dissolved during the dehydration and clearing processes.

Fat cells appear as large clear spaces surrounded by thin layer of cytoplasm giving the cells a signet ring appearance. With EM, the lipid droplet is surrounded by a thin layer of cytoplasm contains a flattened nucleus, a small Golgi apparatus, rER and

mitochondria. The lipid inclusion is not membrane-bounded, but the cytoplasm adjacent to its surface often contains microfilaments.

The white fat cells tend to occur along the course of blood vessels and they may also occur either singly or in-groups within the loose connective tissue layers.

The brown adipocytes are smaller than white one, the nuclei are oval, eccentricity located and surrounded by a significant amount of strongly acidophilic cytoplasm.



They could be differentiated from the white adipose tissue on the basis of:

Lipid is stored as multiple, small droplets (multilocular fat cells) that give the cytoplasm a vacuolated appearance.

Brown adipocytes have relatively large amount of cytoplasm contains abundant mitochondria that are rich in cytochromes, which give the brown color of this tissue.

Brown adipose tissue is more vascular than the white one.

Mast cells

Mast cells are found in the loose connective tissues specially that of the skin and intestine, particularly in association with blood vessels. They are large polymorphic, spherical or ovoid cells with spherical centrally located nuclei. The nuclei are completely obscured by numerous large metachromatic granules (they take a different color than that of the dye used. (e.g., when stained with toluidine blue they take red color). This property is known as metachromasia.

With EM, the granules are membrane-bounded and contain dense amorphous materials. The cytoplasm contains a prominent Golgi complex, cisternae of rER, free ribosomes and mitochondria.

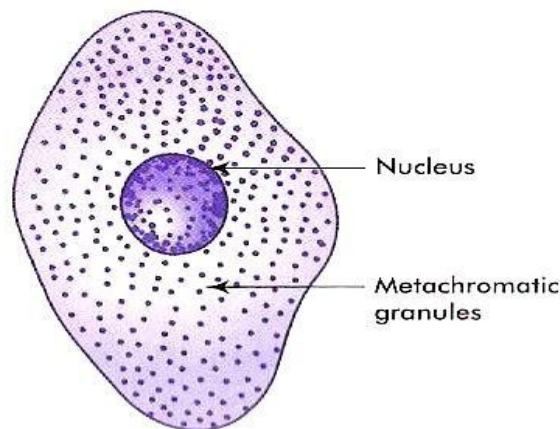


Fig. 4.6 Mast cell

Functions

The surface of the mast cell contains specific receptors for immunoglobulin E (IgE). In allergic and anaphylactic reactions, the interaction of foreign antigen with the antibody bound to the surface of mast cells induces the release of the chemical mediators stored in mast cell granules that promote the immediate hypersensitivity reaction or anaphylaxis.

The granules of the mast cells contain histamine, heparin, ECF-A (eosinophil chemotactic factor for anaphylaxis) and serotonin in rat and mouse. The histamine causes dilatation of small vessels and increases capillary permeability. The serotonin is a vasoconstrictor. The heparin is a potent blood anticoagulant.

Plasma cells

Plasma cells are spherical, oval or pear-shaped cells with spherical, eccentric nucleus. The nuclear chromatin is condensed peripherally giving the nucleus a characteristic “cartwheel” appearance. The cytoplasm is strongly basophilic with a prominent negative Golgi image.

With EM, the cytoplasm contains a prominent Golgi apparatus, abundant rER with dilated cisternae contain electron-dense spherical inclusion known as Russel bodies, free ribosomes and mitochondria.

They are located in the loose connective tissue specially that of the digestive, respiratory and female reproductive system. Plasma cells develop from B-lymphocytes.

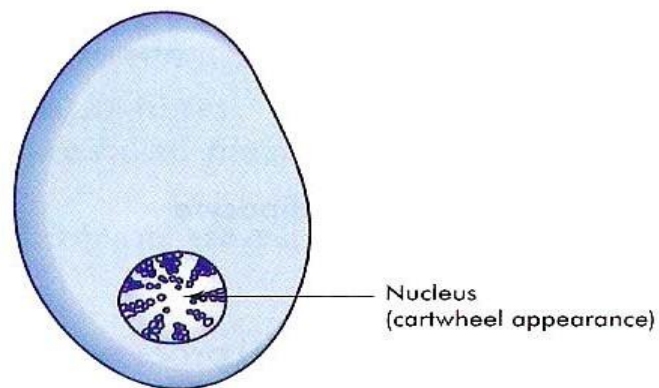


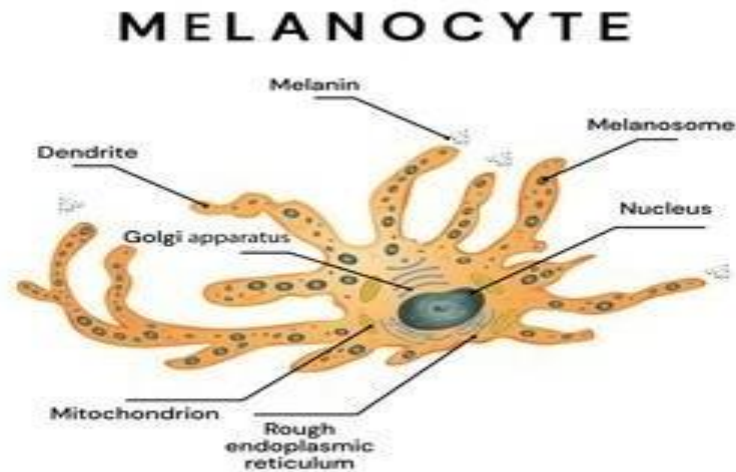
Fig. 4.5 Plasma cell

Functions

Production of antibodies.

Melanocytes

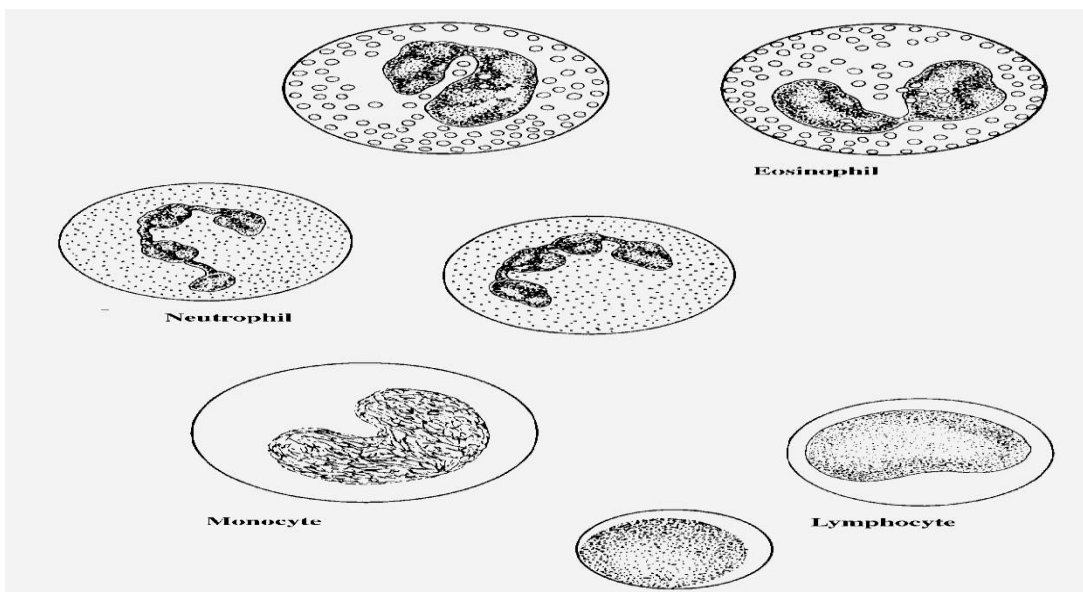
Melanocytes are derived from neural crest. They are large pigmented cells with numerous long branching processes. They occur in epidermis, uterine caruncles of sheep, meninges, choroid and iris.



shutterstock.com · 1449276722

Other connective tissue cells

They include lymphocytes, monocytes and granulocytes (especially eosinophils and neutrophils).



2. Connective tissue fibers

White collagenous fibers

They are called white because they have a white color when fresh, called collagenous because on boiling they become hydrated and yield gelatin (glue). (Kolla=glue).

They are destroyed with weak acids and alkalis and digested by pepsin and collagenase (which is an enzyme produced by the testis and some pathogenic bacteria).

With LM, they are arranged into wavy bundles. The bundles may branch, but the individual fibers do not. They are acidophilic, they stain pink with H&E; red with Van Gieson's; green with Masson's trichrome stain and blue with Mallory stain.

With EM, they are formed of bundles of microfibrils know as collagen fibrils. The fibrils are formed of tropocollagen molecules, and they have a characteristic periodicity repeated at 64 nm intervals.

This periodicity is due to the unique arrangement of tropocollagen molecules where they are arranged in end-to-end manner with each molecule overlapping the adjacent one by one quarter of its length.

Collagen is secreted into the intercellular matrix as tropocollagen molecules that polymerize to form collagen of 5 different types:

Collagen type I


It constitutes about 90% of total collagen in the body. It is found in fibrous connective tissue, skin tendon, ligaments and bone. The tropocollagen molecules are arranged to form fibers. Parallel collagen fibers are further arranged into strong bundles. These bundles are visible with LM and are responsible for the great tensile strength of this type.

Collagen type II

It is found in hyaline cartilage and consists of collagen fibrils dispersed in the ground substance.

Collagen type III (reticular fibers)

They form delicate supporting network in liver and lymphoid organs.



Collagen type IV and V

They do not form fibrils; type IV collagen is present in basement membranes and type V is found in small amount in most connective tissue.

Yellow elastic fibers

Elastin is a rubber-like material that is arranged as fibers and discontinuous sheets (in the wall of arteries). When present in sufficient number, elastic fibers give a yellow color to the fresh tissue (e.g., ligamentum nuchae of ruminants).

Elastic fibers are resistant to boiling and to hydrolysis by acid or alkali. They are also resistant to digestion by trypsin, but elastase from pancreas will digest it.


The elastic fibers can be stretched as much as 2.5 times their original length, to which they return when, released. They are found in organs whose normal function requires great elasticity such as vocal cords, lung, ligamentum nuchae, skin and arteries.

They are not identified in H&E sections but the large elastic fibers in elastic ligaments and the elastic sheets in arterial walls are seen as highly refractile light pink strands.

They can be selectively stained by Verhoeff's stain, orcein (brown) and resorcin fuchsin (blue).

With EM, elastic fibers have two main components: Elastin that appears as an amorphous protein of low electron density. Microfibrils that are embedded in the periphery of the fibers and occurring in small fascicles in its interior.

They are synthesized by fibroblasts and smooth muscle cells as tropoelastin. The microfibrils are secreted prior elastin and provide scaffolding on which elastin forms fibers and sheets.



Reticular fibers

The reticular fiber form delicate network rather than coarse bundles around capillaries, muscle cells, nerve, adipose cells and liver cells. They also constitute the fibrous supporting tissue of endocrine, lymphoid and blood forming organs.

With LM, reticular fibers are not visible in H&E sections but can be selectively stains black by silver impregnation (hence the term argyrophilic or argentaffin fibers) or with the periodic acid-schiff (PAS) reagent.

With EM, they are actually individual collagen fibrils (type III collagen) coated by glycoproteins. They have the same 64-periodicity typical of collagen fibrils.

3. Ground substance

The ground substance is an amorphous gel-like material composed of polysaccharide chains (glycosaminoglycans) bound to protein.

With LM, in H & E sections, they are not visible when present in low concentration. However, at higher concentration (as in hyaline cartilage), they stain basophilic. When stained with toluidine blue or crystal violet, they are metachromatic (take a different color than the color of the dye used). The ground substance includes two major groups:

Non-sulfated glycosaminoglycans (hyaluronic acid)

The hyaluronic acid consists of long molecule that form a network whose spaces are filled with tissue fluid forming gel-like material. The hyaluronic acid predominate in loose connective tissue, vitreous humor, synovial fluid and umbilical cords.

Sulfated glycosaminoglycans

Chondroitin-4-sulfate and chondroitin-6-sulfate are abundant in cartilage, bone, skin, and cornea.

Dermatan sulfate is found in skin, tendon, ligamentum nuchae, sclera and lung.

Keratan sulfate is present in cartilage, bone and cornea.

Heparan sulfate in arteries and lung.

Heparin in mast cells, in lung, liver and skin.

Functions of the ground substance

The glycosaminoglycans and proteoglycans are highly hydrophilic. The tissue fluid within the meshes permits the diffusion of nutrients and metabolites between the connective tissue cells and circulatory system.

The gel-like nature of the hyaluronic acid is thought to act as a barrier against the spread of bacteria that may enter the tissues. Invasive bacteria produce the enzyme hyaluronidase that facilitates their spread.

Types of Connective tissue

I) Embryonic connective tissue

Mesenchyme

The mesenchyme is primitive embryonic connective tissue from which all other connective tissue types are derived. It consists of primitive mesenchymal cells that have an irregular, stellate shape with delicate branching cytoplasmic processes that form an interlacing network throughout the tissue. The extracellular material consists of non-sulfated amorphous ground substances with no fibers.

Mucous connective tissues

The mucous connective tissue is found in many parts of the embryo especially under the skin and in the umbilical cord “Warton’s Jelly”.

In adults, it is found in omasal laminae and in the comb and wattles of the chickens. It consists of large stellate, fibroblasts with branching and anastomosed cytoplasmic processes. Few macrophages and lymphoid cells are also present. The intercellular substance is rich in mucin and contains thin collagenous fibers which increase with age.

II) Adult connective tissues

Loose (ordinary or areolar) connective tissue

It is the most widely distributed type of connective tissue in the adult animals. It consists of all types of connective tissue cells, fibers that are embedded in non-sulfated amorphous ground substances. The cells are relatively more abundant than fibers that are loosely arranged leaving comparatively wide spaces in between.

The loose connective tissue is present around blood vessels and nerves and between muscle bundles. It supports the epithelial lining of gastrointestinal tract, respiratory and urinary tracts, also forms the deeper layers of skin and occurs as loose interstitial packing in many other organs.

1. Dense connective tissue

The fibers are more abundant than cells and amorphous ground substances. According to the arrangement of its fibrous component, two types are identified:

2. Dense irregular connective tissue

It is formed of the same cell types like the loose connective tissue (all connective tissue cell type), although fibroblasts usually predominate, they are inactive with highly condensed nuclei and minimal cytoplasm.

The collagen fibers predominate, and they are arranged in coarse irregular interwoven bundles with very narrow space in-between.

It is found in lamina propria of the initial portion of the digestive tract, the capsule of the lung, the capsule of various organs (spleen, liver, kidney, testis), fascia, joint capsule and dermis.

3. Dense regular connective tissue

a. Dense regular collagenous (tendon)

The tendon consists of bundles of parallel collagen fibers that are bounded together by sparse, loose connective tissue contains small blood vessels, nerves and active fibroblasts (peritendineum interna).

The peritendineum interna is continuous with the peritendineum externa that is a loose connective tissue capsule that covers the outer surface of the tendon.

The active fibroblasts that are located in the loose connective tissue layer between the bundles are responsible for the repair of tendons whenever the need arises.

The fibrocytes located between the collagen fibers are inactive cells and appear as long, flat cells with wing-like cytoplasmic processes extending between adjacent collagen fibers, giving them a stellate appearance (bird cells) in cross sections.

b. Dense regular elastic (Elastic ligaments)

It consists of branching and interconnected parallel elastic fibers surrounded by loose connective tissue (e.g., ligamentum nuchae and the elastic fascia of the abdominal muscle of herbivores).

4. Reticular connective tissue

It is made up of stellate reticular cells and a complex network of delicate thin branched and anastomosed reticular fibers.

It forms a delicate supportive framework for many highly cellular organs such as endocrine glands, liver and lymphoreticular organs (tonsils, spleen, and lymph nodes).

5. Adipose tissue

It is a special type of connective tissue designed to perform many functions such as mechanical protection, thermal insulation and body metabolism. There are two types of adipose tissue white and brown adipose tissues.

6. White adipose tissue


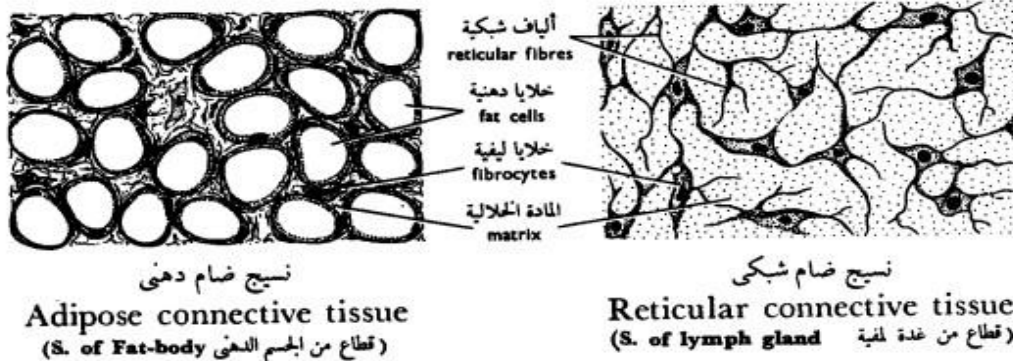
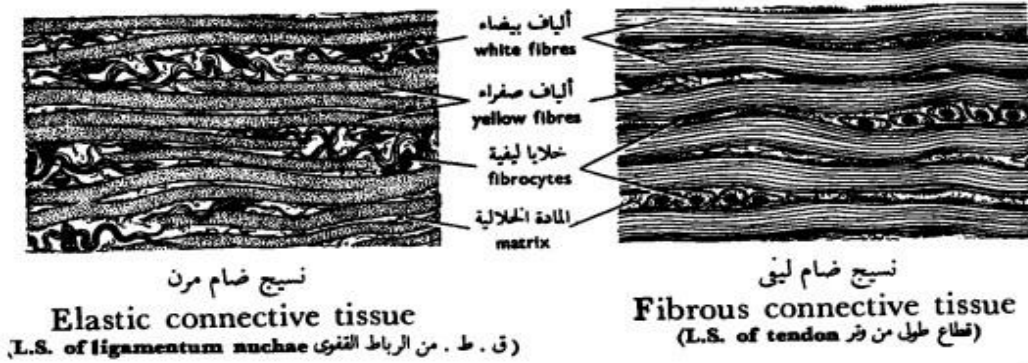
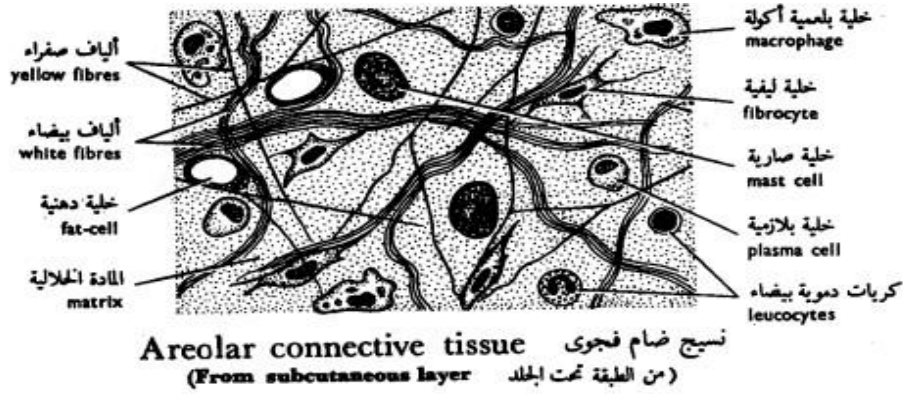
It is distributed throughout the body especially in the deep layer of the skin and around the kidneys. White fat is divided by septa of loose connective tissue into clusters of adipose cells known as lobules. A delicate network of collagen and reticular fibers that support a dense capillary plexus and nerve fibers surrounds each adipocyte. In addition, the narrow intercellular spaces contain a few fibrocytes, mast cells, and scanty amorphous ground substance.

Fat stored in adipocytes as single large droplet (monolocular fat cell) which occupies most of the cytoplasm. The nucleus is compressed and displaced to one side of the cytoplasm giving the cells their characteristic signet ring appearance.

7. Brown adipose tissue

It is a highly specialized form of adipose tissue found in newborn mammals, rodents and some hibernating animals, where it plays an important part in body temperature regulation.

The brown adipose tissue is more vascular than the white ones. The brown adipocytes are smaller than white one, the nuclei are oval, eccentricity located and surrounded by a significant amount of strongly acidophilic cytoplasm.



شكل ٣٩ - الأنسجة الضامة الأصيلة
FIG. 39 - CONNECTIVE TISSUES PROPER

Skeletal Connective tissue

1- Cartilage

The cartilage is a semi-rigid, flexible, avascular form of connective tissue designed to perform a supportive function. It is composed of cells and matrix (fibers and amorphous ground substance).

Types of cartilage

1. Hyaline cartilage

The hyaline cartilage consists of:

Perichondrium

It is a vascular connective tissue capsule that invests the external surface of cartilage. It is composed of two layers: a) Outer fibrous layer, composed of dense irregular connective tissue containing blood vessels and nerves. b) Inner cellular or chondrogenic layer made up of chondroblasts that are actively involved in production of matrix during cartilage growth and regeneration.

Cartilage cells

Chondroblasts (cartilage forming cells)

They are found mainly in the inner chondrogenic layer of the perichondrium. They are oval or spindle-shaped cells with oval euchromatic nuclei. The cytoplasm is basophilic rich in ribosomes, rER and Golgi saccules. They secrete matrix around themselves and become deeply buried in the cartilage matrix where they are called chondrocytes.

Chondrocytes (mature cartilage cells)

They are located in tiny spaces within the cartilage matrix known as lacunae.

Beneath the perichondrium, chondrocytes are small and their lacunae are elliptical with their long axes parallel to the surface.

Deep within the cartilage, the cells are larger and polyhedral with short processes. They have a spherical nucleus with one or more nucleoli. The cells accumulate glycogen and lipid in their cytoplasm those appear vacuolated.

Some lacunae contain only one cell; others contain two, four, or sometimes six cells. These multicellular lacunae are called cell nests or isogenous groups because each cluster is the progeny of one cell.

Matrix

The hyaline cartilage matrix is an amorphous gel consists mainly of sulfated glycosaminoglycans that are strongly basophilic, PAS positive and metachromatic.

The fibrous component represented by fine collagen fibrils made up of type II collagen that has the same index of refraction as the amorphous ground substance, therefore, they can not be seen in common H&E sections.

The hyaline cartilage occurs in many places such as articular surface, fetal skeleton, nasal septum, larynx, trachea and bronchi.

2. Elastic cartilage

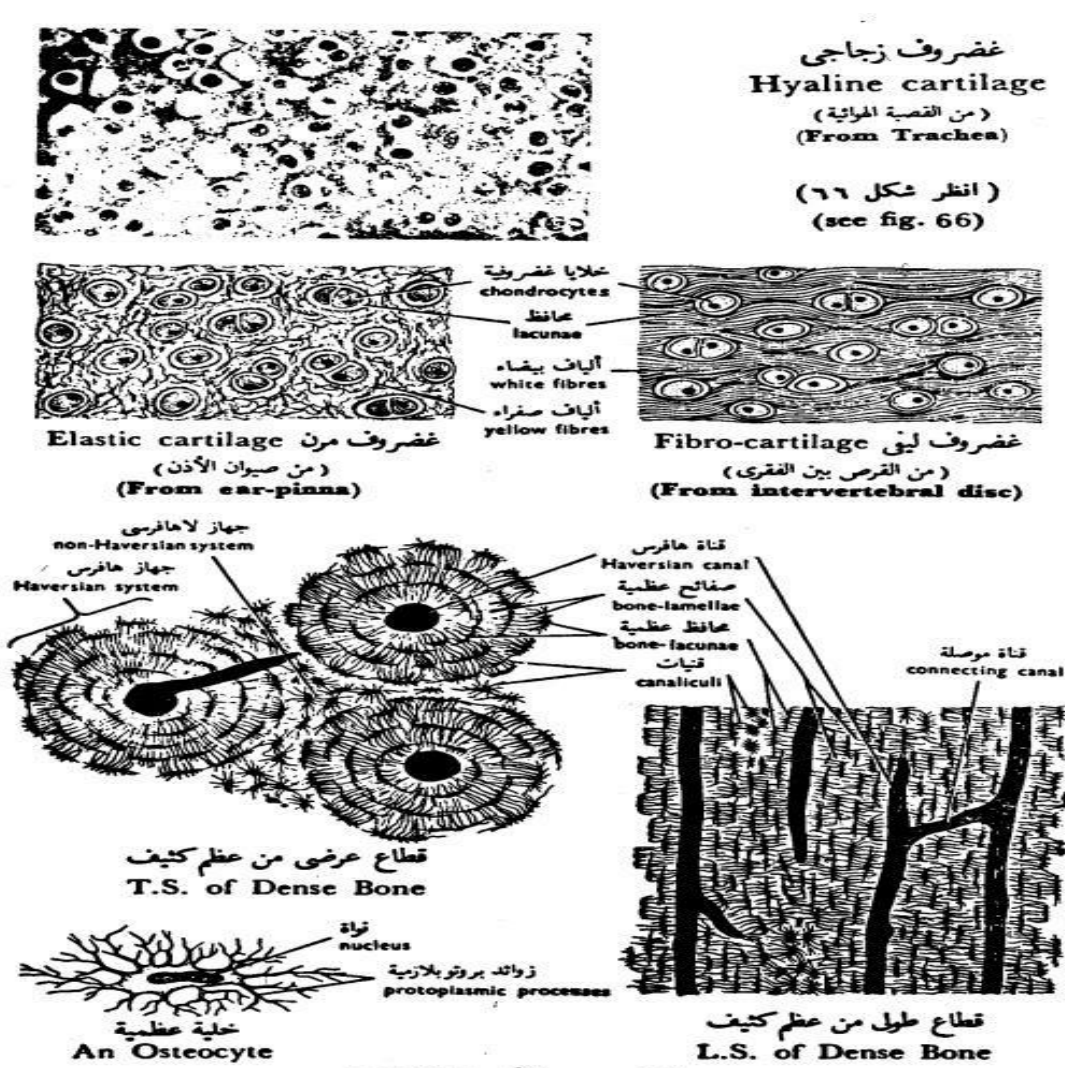
The histological structure of the elastic cartilage is similar to that of the hyaline cartilage except: 1) cell nests are few. 2) The matrices contain a dense network of elastic fibers that are visible in H&E sections.

The elastic cartilage occurs in the external ear and external auditory canal, the epiglottis, corniculate and cuneiform cartilage of the larynx.

3. Fibrocartilage

It is a transitional form between hyaline cartilage and dense regular connective tissue. It consists of regular parallel bundles of collagen fibers separated by encapsulated chondrocytes that occur singly, in pairs or sometimes form rows. The ground substances are little and only found around the chondrocytes. The fibrocartilage is found in the intervertebral discs, menisci of the stifle joint and at the attachment of tendons and bones.

Calcification of the cartilage matrix may occur in aging and during bone development. In this case, diffusion is blocked and the cartilage cells die.



شكل ٤٠ - الأنسجة الهيكلية
FIG. 40 - SKELETAL TISSUES

2- Bone

The bone is a specialized form of connective tissue in which the extracellular components are mineralized. Like other connective tissues, bone is composed of cells (osteogenic cells, osteoblasts, osteocytes, osteoclasts) and matrix (a mixture of collagen fibers, ground substance and mineral salts).

Bone cells

Osteogenic cells

They are undifferentiated cells found in the endosteum, the inner osteogenic layer of the periosteum and the lining of the osteonal canal. The cells have pale-staining oval or elongated nuclei and little acidophilic or faintly basophilic cytoplasm.

They develop from the mesenchymal cells and they are capable in times of need (i.e. bone growth or fracture repair) to divide and transform into any of the other bone cells.

Osteoblasts (bone forming cells)

They are small, ovoid branching cells. During active bone formation, they are arranged in an epithelial-like layer of cuboidal cells connected to each other by short slender processes.

The nucleus is oval, eccentric (at the cells end away from the bone surface), and euchromatic with prominent nucleolus.

The cytoplasm is deeply basophilic and shows a negative Golgi image near the nucleus.

With EM, the cytoplasmic features reflect a high rate of protein synthesis with abundant rER and prominent Golgi apparatus.

Functions

Osteoblasts are responsible for the formation of organic components of bone matrix (osteoid tissue).

They secrete matrix vesicles that participate in the nucleation of crystalline bone minerals.

Resorption of osteoid tissue (unmineralized matrix).

Osteocytes (mature bone cells)

The osteocytes are the principal cells of mature bone. They are located inside lacunae within calcified bone matrix. They are less active than osteoblasts and can not divide inside their lacunae. The cell body is flattened with numerous cytoplasmic processes that extend through tiny channels within the bone matrix called canaliculi.

The processes of the adjacent cells are interconnected with each other via gap junctions permitting flow of ions and small molecules between blood and osteocytes.

With LM, the nuclear and cytoplasmic characteristics are similar to those of osteoblasts except the Golgi region is less prominent and the cytoplasm is less basophilic.

With EM, the rER and the Golgi are still prominent, however, osteocytes situated deeper in bone matrix may have less prominent rER and Golgi saccules.

Functions

Preserve and maintain the integrity of the bone matrix.

Osteoclasts

They are large (about 50 μ m) multinucleated cells lining in depressions on the bone surface called Howships lacunae. With LM, the cell has an irregular shape with an

acidophilic foamy cytoplasm. The part of the cell border facing the bone surface has striated border-like structure.

With EM, the striated border seen with LM is formed of: 1) Ruffled border that is made up of branching finger-like processes projecting from the cell membrane. 2) Collagen fibrils exposed through extracellular digestion of bone matrix.

Osteoclasts originate from blood monocytes, which fuse with each other to form multinucleated osteoclast.

Functions

Degradation of mineralized bone matrix through:

Focal decalcification through production of organic acids (carbonic, lactic and citric) to generate local acidic environment capable of dissolving calcium from the bone matrix.

Extracellular digestion of the organic components of the bone matrix through liberation of acid hydrolase to the extracellular matrix.

Bone matrix

It consists of organic and inorganic elements:

Organic matrix

It is made up of a mixture of glycoprotein ground substance and type I collagen.

Inorganic matrix

It consists of mineral salts, mainly calcium phosphate that is deposited as submicroscopic hydroxyapatite crystals within the collagen fibers.

Types of bone

Compact bone

This type forms the dense wall of the shaft or diaphysis of the long bone

Cancellous or spongy bone

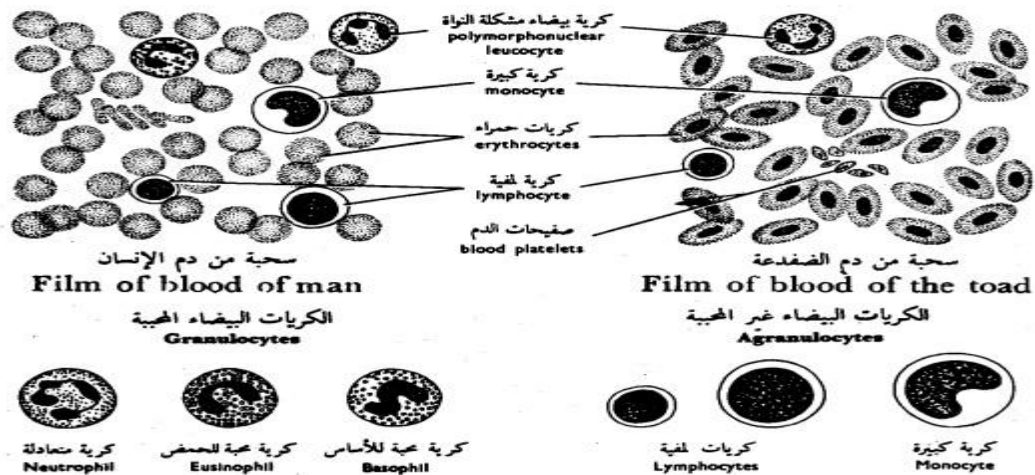
The cancellous bone is composed of a network of bony trabeculae separated by interconnecting spaces containing bone marrow. The trabeculae are thin and composed of bone matrix with lacunae containing osteocytes, which exchange metabolites via canaliculi with blood sinusoids in the marrow cavity.

The trabeculae are lined by endosteum that contains osteogenic cells, osteoblasts and osteoclasts. Cancellous bone forms the epiphysis of the long bone and the cores of flat and irregular bone.

Vascular connective tissue

Blood

Blood is one of the body fluid that is formed of a variety of cells suspended in a fluid medium, the plasma.



شكل ٤١ - الأنسجة الوعائية
FIG. 41 - VASCULAR TISSUES

Blood cells

The blood cells are grouped into three main categories: red blood cells (erythrocytes), white blood cells (leukocytes) and blood platelets (thrombocytes).

2- Red blood cells (Erythrocytes)

The mature red cells of domestic mammals are non-nucleated, biconcave discs.

In pig and goat, red blood cells have no biconcavity and therefore appear as flattened discs.

In tylopoda (camels and llama), they are elliptical, biconcave and non-nucleated. In birds, reptiles, fishes and amphibian, they are oval, biconvex and nucleated.

The size of RBCs range from 4-7 μm , the largest erythrocyte is found in the dog (7 μm) and the smallest in the goat (4 μm).

The number of the RBCs varies among species, in dog is about 7 million/ mm^3 , cattle 6.3 million, goat 14 million and horse 9.5 million.

With LM, the erythrocytes in a stained blood smear are stained pink due to their high content of hemoglobin. They have a central pale staining region due to their biconcave disc shape.

The erythrocytes sometimes adhere to each other via their broad surface and become arranged in long chains similar to a stack of coins. This arrangement is called rouleaux.

With EM, the shape of the erythrocytes depends on the plane of section through the cell. The cytoplasmic content of erythrocytes appears electron dense due to the iron atoms of hemoglobin.

When placed in hypotonic solution (lower concentration than plasma), the RBCs swell and ruptures. This is called hemolysis.

In hypertonic solution (higher concentration than plasma), the cell volume diminishes and the cells become crenated.

The life span of erythrocytes is about 120 days. Spleen, bone marrow and liver phagocytes engulf old RBCs. The iron of the hemoglobin is reused in formation of new cells. The porphyrin portion is used to form bilirubin or bile pigment.

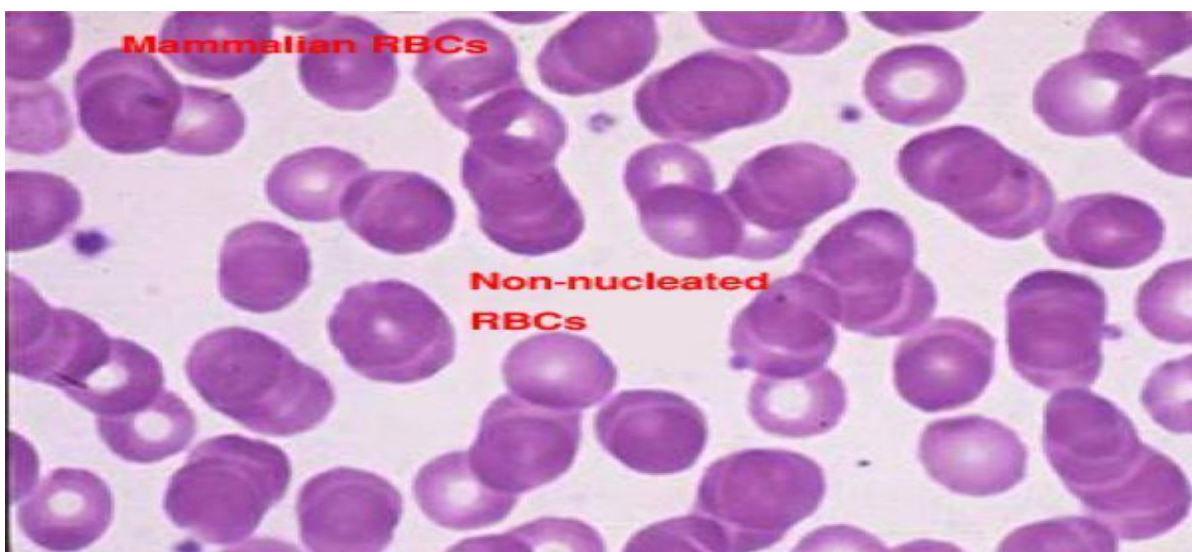
The erythrocytes are highly adapted to their function that is the transport of oxygen and carbon dioxide:

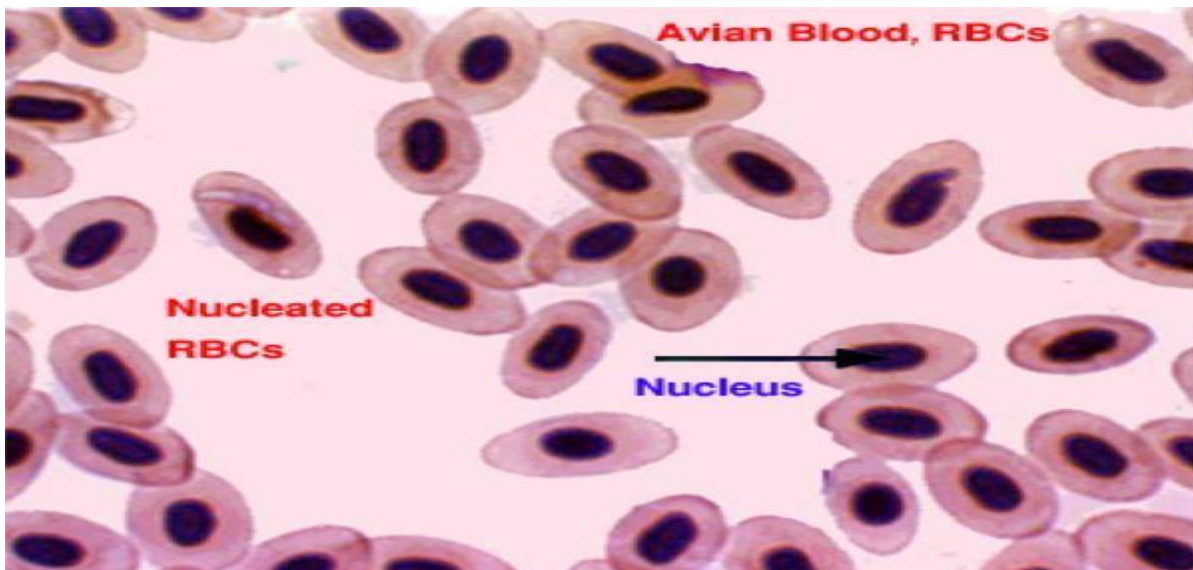
The plasma membrane is highly selective. It is permeable to water and electrolytes, but it is impermeable to hemoglobin.

The elasticity of the plasma membrane allows the erythrocytes to deform and pass through the smallest capillaries (2-4 μ m diameter).

The biconcave shape provides a large surface area relative to cell volume, which greatly enhance gaseous exchange.

Before release into the circulation, the nucleus is extruded and by maturity, all cytoplasmic organelles degenerate which give more space to carry more hemoglobin.





Reticulocytes

They are immature RBCs that are released into the peripheral circulation from the bone marrow. They are slightly large than mature RBCs and when stained with supravital dyes such as brilliant cresyl blue, blue-stained fine networks are seen inside their cytoplasm. This is due to ribosomal RNA still remaining in their cytoplasm. The number of reticulocytes increases in circulation after blood loss.

3- White blood cells (leukocytes)

There are five cell types of the WBCs that are subdivided into two main groups:

Granulocytes

Neutrophils

They are the most common type of leukocytes and account for about 28 % (cattle) and 70 % (dog) of the total leukocytic count. The mature cell is about 10-12 μm in diameter.

In mature cell, the nucleus is lobulated or segmented consists of 2-5 lobes connected by fine chromatin strands. Young neutrophil has U-V- or S-shaped, non-segmented nucleus

and is called band or non-segmented cells. Band cells increase in number during bacterial infection.

In female neutrophils, the quiescent X-chromosome or Barr bodies appear as a small drumstick-shaped appendage of one of the nuclear lobes. The cytoplasm contains purplish granules called azurophilic granules that are large lysosomes. Numerous smaller specific granules, are also present but they are poorly stained.

With EM, neutrophil has few cytoplasmic organelles. The specific granules are relatively smaller rod-like containing bactericidal substances (phagocytins) and alkaline phosphatase. The non-specifics (azurophilic granules) are larger in size and fewer in number. They are considered lysosomes containing hydrolytic and peroxidase enzymes. Besides, glycogen granules are found. Actively migrating cells protrude pseudopodia, which are cytoplasmic extensions of the cell contain a few glycogen granules but are largely devoid of organelles.

Functions

Phagocytosis of invading microorganisms particularly bacteria.

They are the main WBCs type involved in acute inflammatory response. Dead leukocytes are called pus cells.

Eosinophils

They account for 1-6 % of the total leucocytic counts. The cell size range from 12-15 μm . Eosinophil has a bilobed, less deeply stained nucleus. The cytoplasm is packed with coarse, large, refractile, eosinophilic granules.

With EM, the cytoplasm is filled with large, ovoid, specific granules containing dense crystalloid in the long axis of the granules (dog, cat and goat). They are membrane-bound

and their matrix contains a variety of hydrolytic enzymes including histaminase. Other cytoplasmic organelles such as mitochondria, rER and Golgi are relatively sparse.

Functions

The number of eosinophils in circulating blood increases during parasitic infestations and allergic conditions.

Phagocytosis of the antigen-antibody complex.

Deactivate histamine produced during inflammatory or allergic response.

Basophils

They are about 10-12 μm in diameter. They are the least common cell types that constitute less than 1% of the total leucocytic count. The nucleus is bilobed and completely obscured by numerous large deeply basophilic granules.

With EM, the bilobed nucleus is clearly visible and the cytoplasm is filled with membrane-bound electron dense granules.

Functions

The specific granules of the basophils contain heparin, histamine, other inactive amines, and slow reacting substance of anaphylaxis (SRS-A).

The contents of the specific granules are released by exocytosis in response to interaction of antigen with antibodies attached to the basophil cell membrane.

Heparin is anticoagulant. Histamine causes dilatation of small blood vessels and increase capillary permeability leading to exudation of fluid. SRS-A Cause contraction to the smooth muscle cells.

Agranulocytes

Lymphocytes

They are the second most common leukocytes in circulating blood. They account for 20-45% of the total leukocytic counts. A round, densely stained nucleus and a relatively small amount of pale basophilic non-granular cytoplasm characterize them. According to their size, there are three types: small (6- μm), medium (8-10 μm) and large (12-14 μm).

With EM, the nucleus is small spherical and often slightly indented. The little cytoplasm contains a few mitochondria, a rudimentary Golgi apparatus, little or no rER and large number of free ribosomes accounting for the LM basophilia. Azurophilic granules (lysosomes) are also present.

On the basis of their functional properties, small lymphocytes are classified into two main groups: T and B-lymphocytes. Their functions will be considered with the immune system.

Monocytes

They are the largest members of the white blood cell series that account for 2-10% of the total leucocytic count. They are highly motile cells and migrate into connective tissue where they are called histiocytes or tissue fixed macrophages. The large eccentricity located nucleus is bean or kidney-shaped with less densely stained chromatin than that of other leukocytes.

With LM, The cytoplasm is extensive and is filled with azurophilic granules (lysosomes). It has a frosted-glass appearance.

With EM, lysosomes are abundant, the Golgi is well developed, rER is diffuse and mitochondria are abundant than other leukocytes. It is also rich in microtubules and

microfilaments. Pseudopodia are prominent reflecting their capacity for amoeboid movement and phagocytosis.

Function

The principal function of the macrophage is phagocytosis and destruction of the cellular debris.

Antigen presentation and antigen processing thus participating in both humoral and cell-mediated immune response.

4- Blood platelets (thrombocytes)

They are small, non-nucleated cells formed in the bone marrow by budding from the cytoplasm of huge cells called megakaryocytes. In birds, platelets are nucleated hence they are called thrombocytes.

With LM, they are round or oval biconvex discs about 2-3 μm in diameter.

The cytoplasm has a purple-stained granular appearance due to its high contents of organelles. The organelles are concentrated towards the center of the cell (granulomere). The peripheral cytoplasm (hyalomere) contains microfilaments and microtubules arranged underneath the plasmalemma. It has few organelles and is very poorly stained.

With EM, the cytoplasm is rich in membrane bound granules of two types: 1) very dense granules are sparse and contain serotonin, ADP, ATP and calcium. 2) Alpha granules which are more common and contain hydrolytic enzymes.

Functions

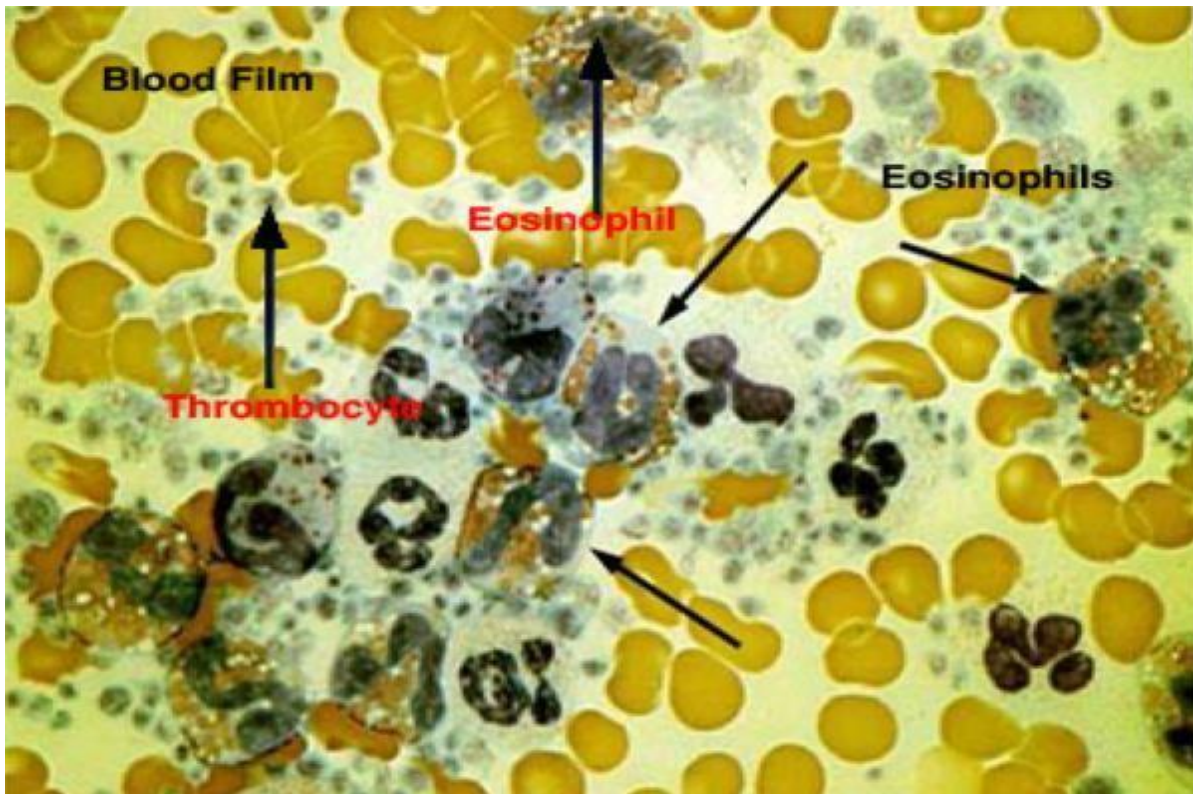
Blood clot formation.

Release serotonin that reduces the blood flow by constricting the damaged vessels.

Function

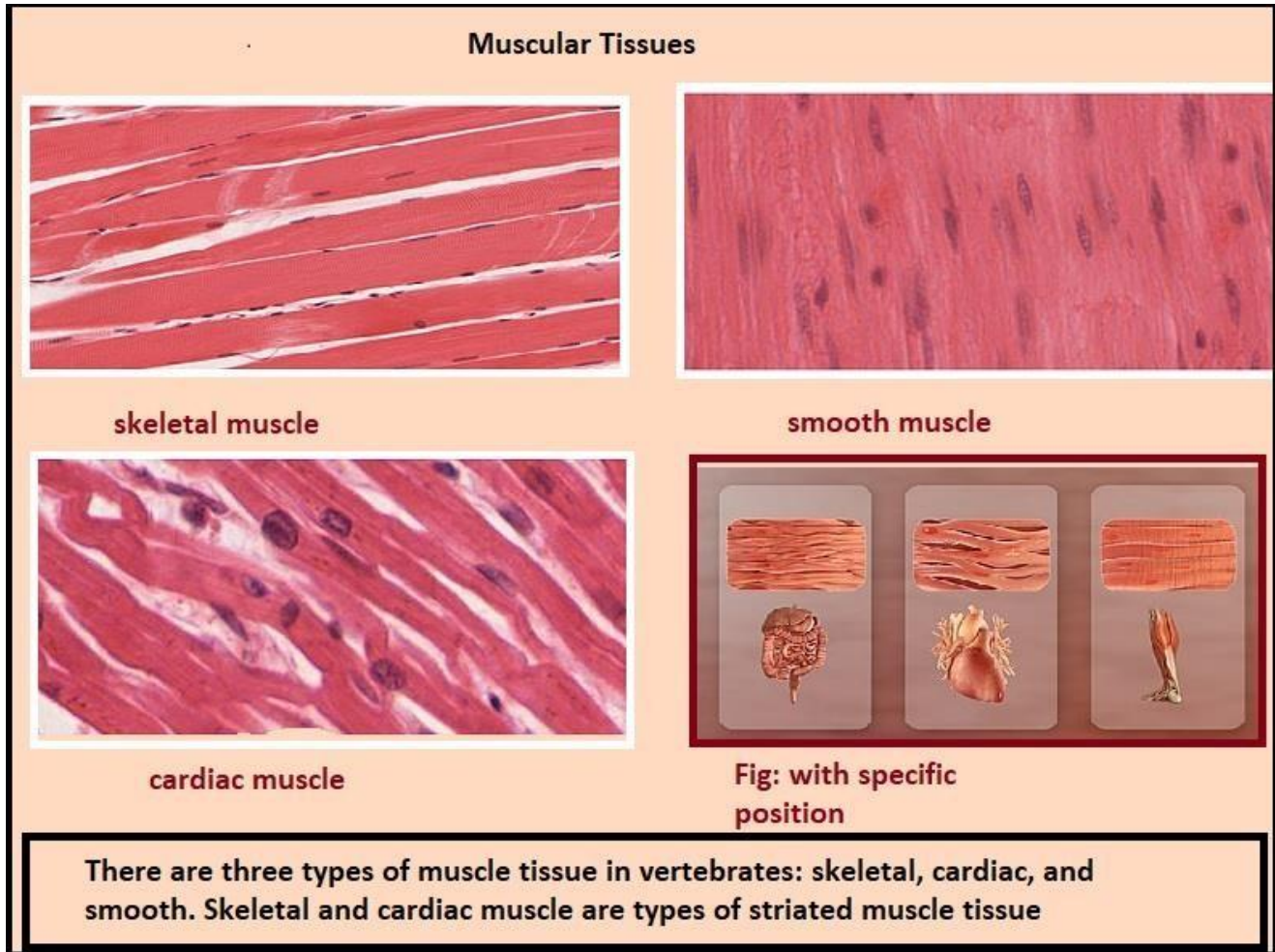
The principal function of the macrophage is phagocytosis and destruction of the cellular debris.

Antigen presentation and antigen processing thus participating in both humoral and cell-mediated immune response.



3. Muscular tissue

It is one of the four basic types of tissues primarily responsible for locomotion and movement of the various body parts.



General features

Muscle cells are long and narrow; therefore they are called muscle fibers or myofibers.

Muscle fibers are highly specialized for contractility, which occurs due to the presence of contractile proteins within their cytoplasm.

Muscle fibers originate primarily from the mesoderm, except the muscle of the iris, and myoepithelial cells that are ectoderm.

Special terms are used for muscle fibers: plasmalemma = sarcolemma; cytoplasm = sarcoplasm; endoplasmic reticulum = sarcoplasmic reticulum; mitochondria = sarcosomes.

Muscle tissue is a composite tissue where it contains a minimal amount of connective tissue beside its principal cells.

There are three types of muscle tissue: skeletal, cardiac and smooth muscles.

Skeletal muscle (Striated and voluntary myofibers)

They are found in all skeletal muscles, tongue larynx, pharynx and eye. It is called skeletal because its contraction moves some parts of the skeleton; voluntary because its contraction is under conscious control, and striated because under microscope, its fiber shows alternating dark and light bands called cross-striation.

A skeletal muscle is composed of skeletal myofibers and connective tissue. A sheath of dense connective tissue called epimysium encloses the entire muscle. From the epimysium, thin collagenous septa extend inward to divide the muscle into a number of bundles or fascicles. These septa are called the perimysium. The perimysium is continuous with the endomysium that is a delicate connective tissue layer surrounds each individual myofibers.

At least five cell types are found within the bundle of the skeletal muscle: myofibers, endothelial cells, fibroblasts and myosatellite cells.

The connective tissue in between the myofibers is needed for two reasons: 1) through which blood vessels, lymphatics and nerve enter or leave the interior of the muscle. 2) At the ends of the muscle, the connective tissue elements merge to form tendons that anchor the muscle to other structures such as bone or cartilage.

Cardiac muscle (Striated and involuntary)

It is called cardiac because it constitutes most of the heart although some cardiac muscle can also be found in the wall of pulmonary vein and vena cava.

Cardiac myofibers are striated, however, the striation is less distinct than that of the skeletal myofibers due to: irregular branching shape of the fiber, the less myofibrils content and the abundance of non-contractile sarcoplasm. They are involuntary, they contract spontaneously without any nerve supply. The rate this inherent rhythm can be modulated by autonomic and hormonal stimuli.

Structure of cardiac muscle

At the LM level, the cardiac myofibers are long (50-100 μm), cylindrical cells that are branched and anastomosed forming a network. They are traversed at intervals by dark-staining structures called intercalated discs that extend across the fiber in a stepwise manner.

Most of the cells have one nucleus and at most two nuclei. The nuclei are oval and centrally located within the cell. Like the skeletal muscles, the cytoplasm is acidophilic and striated consisting of an alternated dark and light bands.

The cells are surrounded by delicate connective tissue containing fibroblasts, pericytes and dense capillary network necessary to meet their high metabolic demands. Myosatellite cells are absent.

In TS, the cardiac muscle fibers are spherical or oval with a regular diameter of about 20 μm containing single central nuclei.

At the EM level, the fine structure of the cardiac muscle is similar to that of the skeletal muscle except:

Cardiac myocytes has a less extensive sarcoplasmic reticulum and does not form dilated terminal cisternae.

Purkinje fibers

They are modified cardiac muscle fibers designed for rapid conduction of nerve impulses. They differ from the ordinary cardiac muscle fibers in the following aspects:

They are larger in size.

The nucleus is smaller and eccentricity situated.

The cytoplasm is paler, vacuolated because it is rich in glycogen.

The myofibrils are fewer and concentrated at the periphery.

The T tubules are absent.

Smooth muscle (Visceral muscle)

Smooth muscles are found in the walls of hollow viscera and blood vessels. It is called smooth because it has no cross striations, involuntary because its contraction can not be elicited at will and visceral because they are found in visceral organs.

Structure of smooth myofibers

At the LM level, the smooth muscle cell is elongated, spindle-shaped with pointed ends. It has a diameter of 3-10 μ m with length ranges between 30-500 μ m.

The cytoplasm is acidophilic and contains only one nucleus. The nucleus is elongated and centrally located in the cytoplasm at the widest part of the cell. During contraction, the nuclei may appear spiral in shape .

The smooth muscle fibers are bound together into irregular branching bundles. Within the bundles, individual muscle fibers are arranged parallel to each other with

the thick part of the cell lying against the thin parts of adjacent cells. A sheath of delicate connective tissue containing capillaries and few nerve fibers invests each muscle bundle.

The cytoplasm is filled with parallel thin (actin) and thick (myosin) filaments. The filaments do not have the arrangement seen in the sarcomeres.

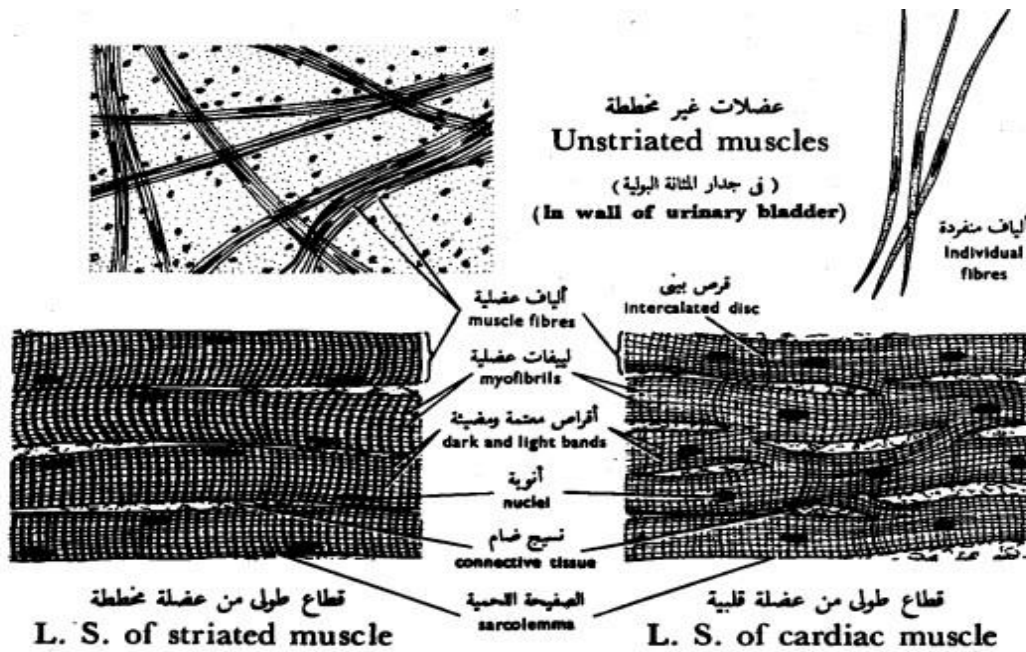
Intermediate filaments (desmin, vimentin and synemin) are also located within the cytoplasm.

Functions

Contraction of the smooth muscle is an inherent property however, it can be modulated by the autonomic nervous system.

The smooth muscle maintains prolonged partial contraction (tonus) in the wall of arterioles that is necessary to keep normal blood pressure in the blood capillaries.

In the small intestine, the smooth muscle cell undergoes continuous rhythmic constrictions passing along the tract propelling the luminal contents distally.



شكل ٤٢ - الأنسجة العضلية
FIG. 42 - MUSCULAR TISSUES

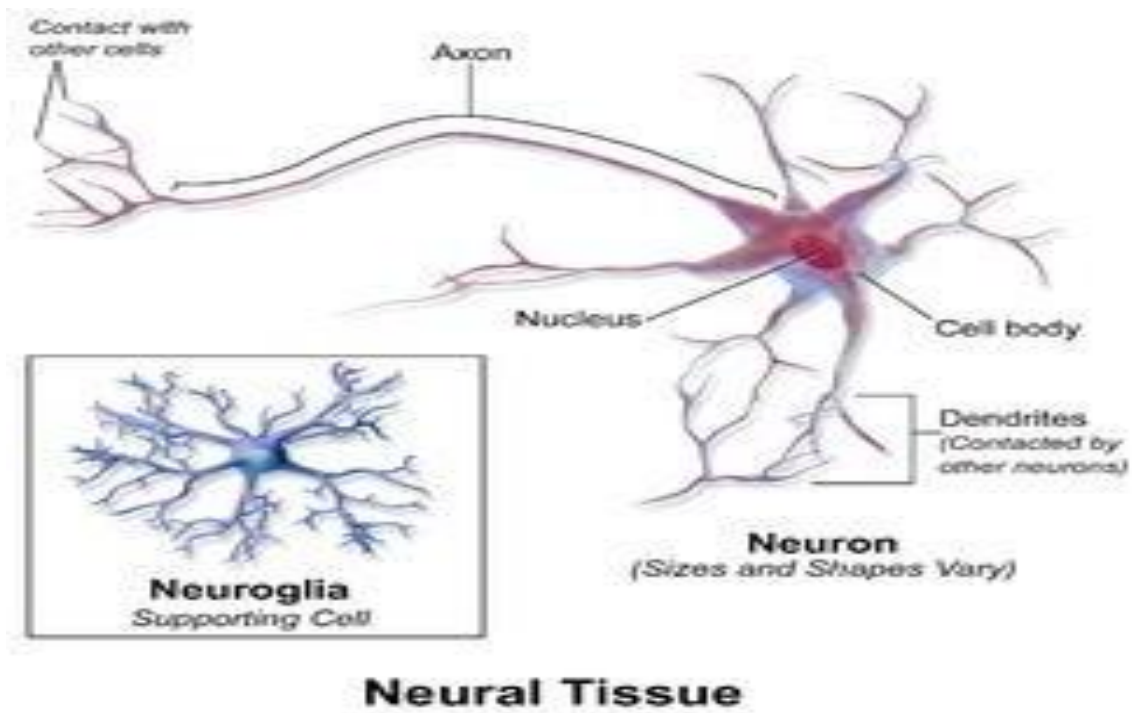
4. Nervous tissue

It is one of the four primary basic tissues.

It consists of two types of cells:

1- Neurons (nerve cells)

2- Neuroglia (supporting cells).



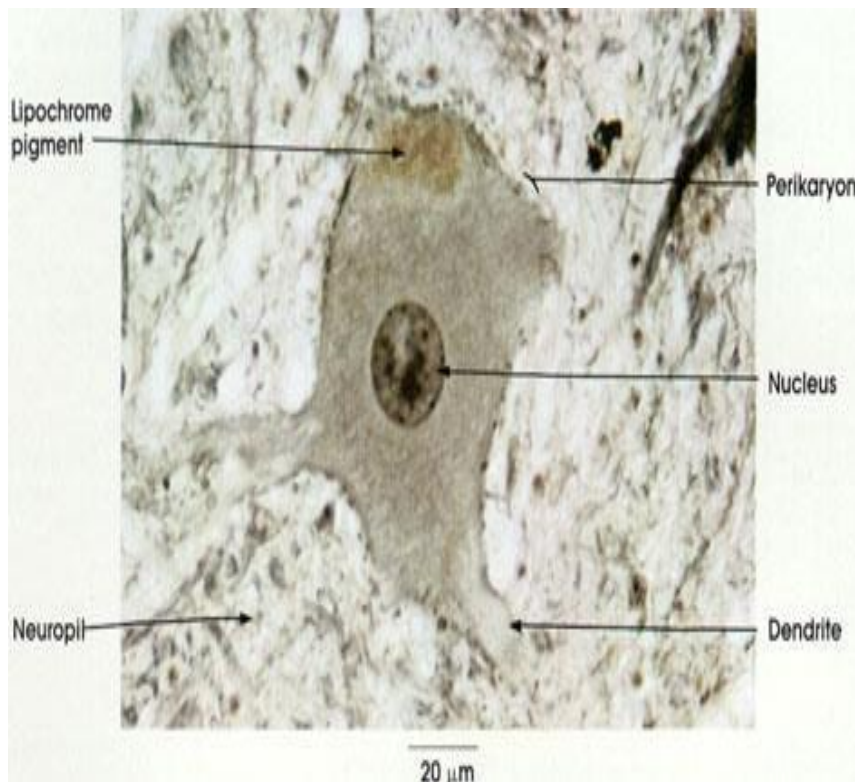
Neuron=Nerve cell

- It is *the structural and functional unit* of the nervous tissue.
- It is characterized by:
 - 1- Excitability: they respond to environmental changes by generation of action potential or nerve impulse.
 - 1- Conductivity: they are capable of propagation of nerve impulse to other neurons, muscles& glands.

Histological structure of the neuron

I- Cell body (perikaryon, soma)

- It is composed of:
 - 1- Nucleus: euchromatic.
 - 2- Cytoplasm: contains:
 - Nissl bodies
 - LM: basophilic granules.
 - EM: aggregates of ribosomes and rER.
 - Function: protein synthesis.
 - Distribution: in the cell body *except* in the region of axon hillock.
 - Large perinuclear Golgi apparatus: for packaging of neurotransmitters into synaptic vesicles.
 - Cytoskeleton: formed of neurofibrils that include neurofilaments and microtubules playing a role in the transmission of nerve impulses.
 - Inclusions: lipofuscin pigments and lipids.

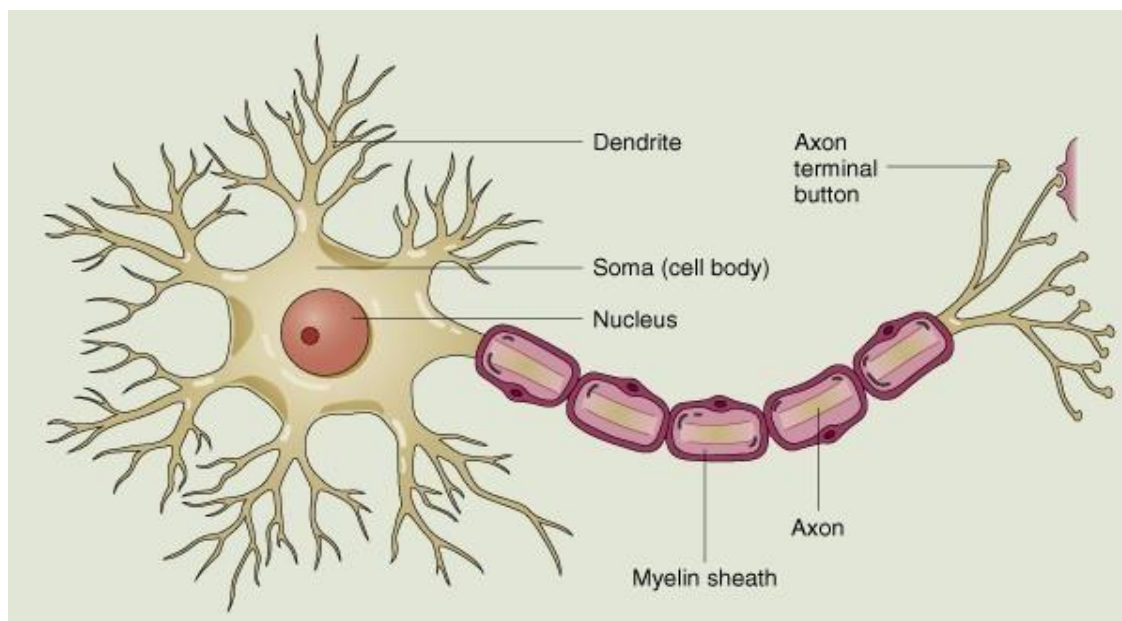


II-

Cell processes

1- Axon:

- Origin: from the axon hillock.
- Number: always single.
- Direction of impulses: conducts nerve impulses away from the cell body.
- Shape: long, with a regular cylindrical shape.
- Branching: no branches except at axon termination forming terminal arborizations. It may give off collaterals arising at right angles.
- Structure: the axoplasm contains few organelles (neurofibrils, synaptic vesicles and mitochondria). Nissl bodies are *absent*.
- Surrounding sheath: axolemma may be surrounded by sheaths according to the type of nerve fiber.

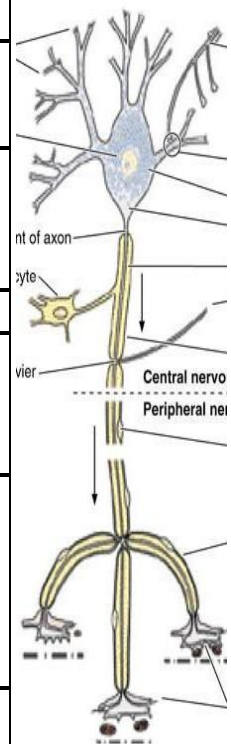


2- Dendrite:

- Origin: from any part of the cell body.
- Number: usually multiple (in multipolar neurons). It may be single (in bipolar neurons).
- Direction of impulses: conducts nerve impulses towards the cell body

- Shape: short, thick near its origin and tapers towards its end.
- Branching: many branches arising at acute angles, having short spines for synapses.
- Structure: contains most of the organelles as in the perikaryon *except* the Golgi apparatus. Nissl bodies are present.
- Surrounding sheath: not surrounded by sheaths.

	The axon	The dendrite
1- Origin	Arises from axon hillock	Arises from any part of the cell
2- Direction of the impulse.	conducts nerve impulse away from the cell body	conducts nerve impulse toward the cell body
3- Number	Always single	Usually multiple (in multipolar neurons). It may be single (in bipolar neurons)
4- Length	Long	Short
5- Thickness	Thin with a constant diameter.	Thick near its origin and tapers as it goes toward its end.
6- Branching	Does not branch except at its termination (terminal arborization). It may give off collaterals arising at right angles.	Many branches arising at acute angles, having short spines.
7- Organelles present	Contains few organelles (neurofibrils, vesicles and mitochondria. Nissl granules are absent.	Contains most of the organelles as in the perikaryon except Golgi. Nissl granules are present
8- Surrounding structures	It may be surrounded by sheaths.	It is not surrounded by sheaths



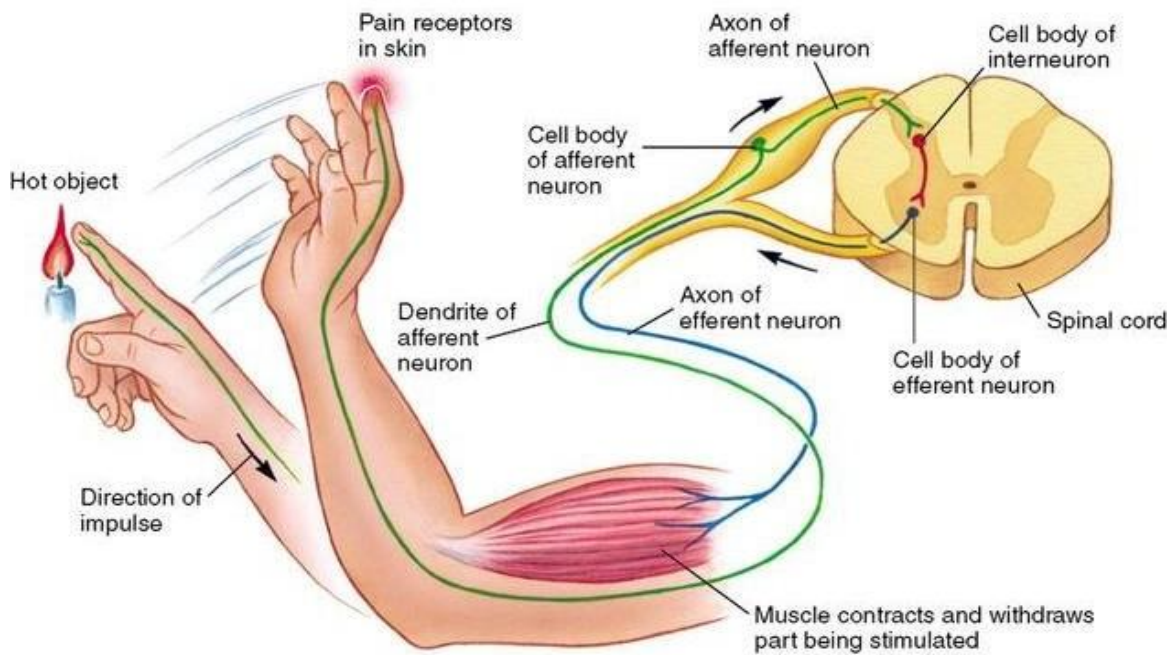
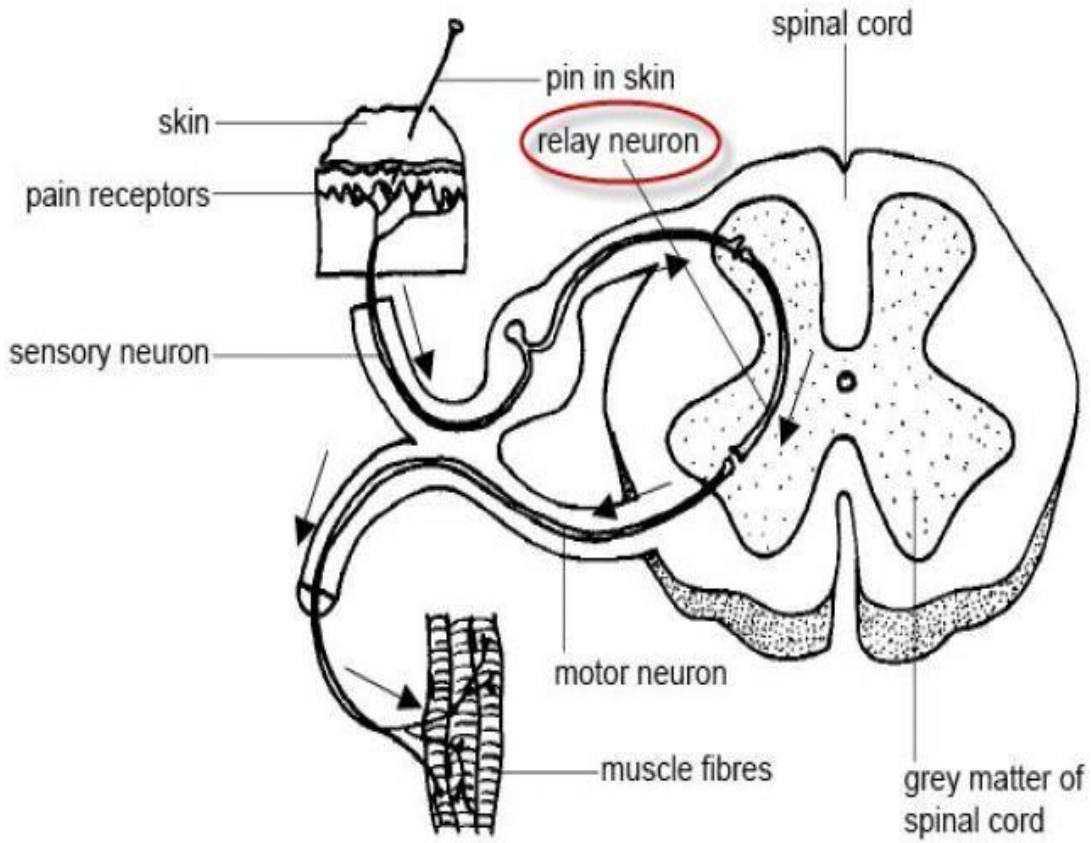
Classification of the neurons

I- Functionally

1- Sensory neurons: they carry impulses from receptors to the CNS.

2- Motor neurons: they carry impulses from CNS to the effector organs.

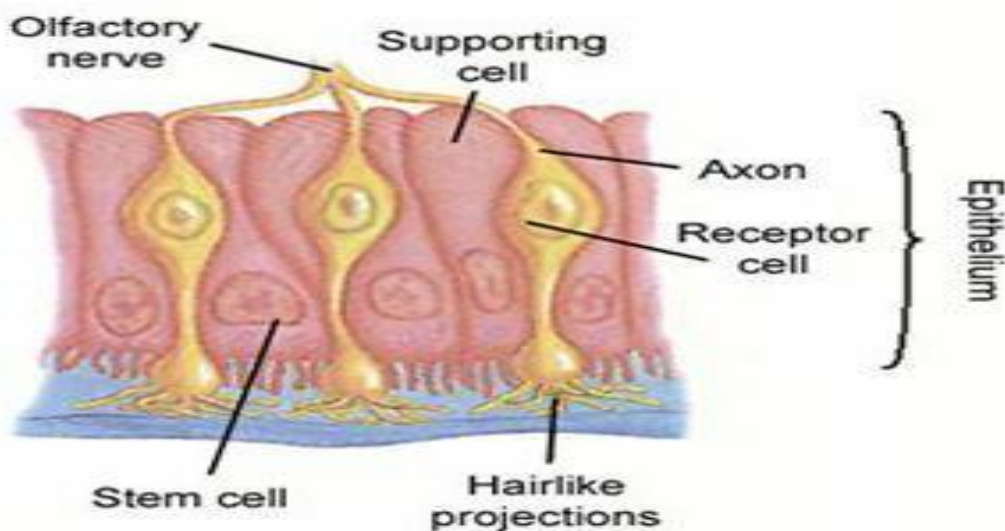
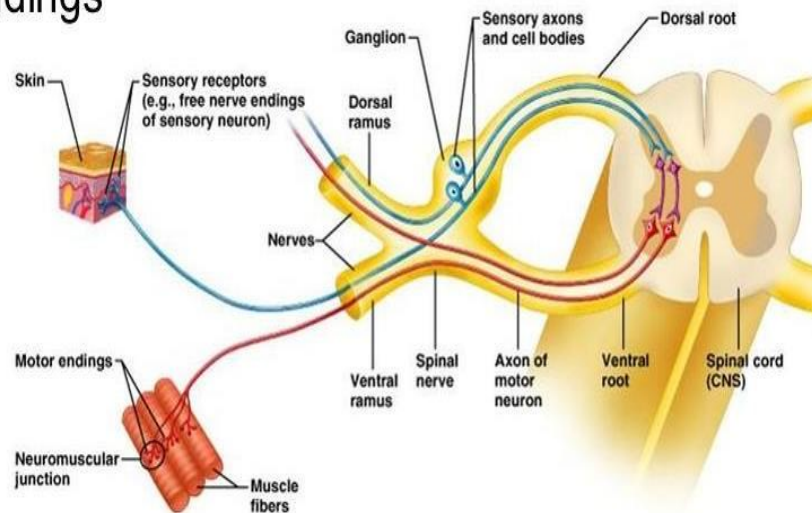
3- Interneurons (association neurons): act as a link between sensory and motor neurons in CNS only.



II-Morphologically

- Neurons are classified according to the number of their processes into:
 - 1- Unipolar: have only one cell process.
 - 2- Pseudounipolar: have a single process that divides like the letter T into two branches (both are axons).
 - 3- Bipolar: have two processes, one is an axon and the other is a dendrite.
- Site: present in the embryonic stage.
- Site: in the cranio spinal ganglia.
- Site: the olfactory neurons present in the olfactory mucosa of the nose.

- sensory receptors
- motor endings
- nerves
- ganglia



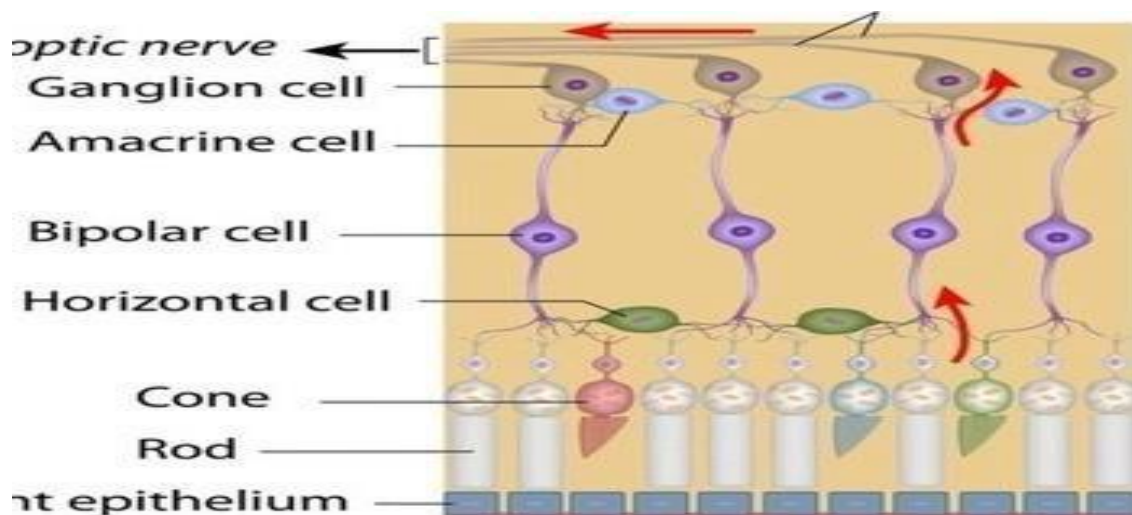
4- Multipolar: have more than two processes. These are classified according to the shape of their perikaryon into:

A-Stellate neurons: they are the anterior horn cells of the spinal cord and the autonomic ganglion cells.

B- Pyramidal neurons: in the cerebral cortex.

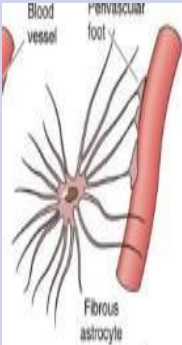
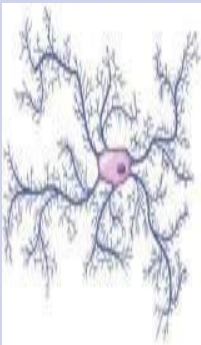
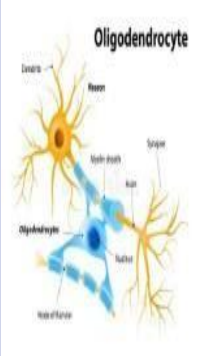
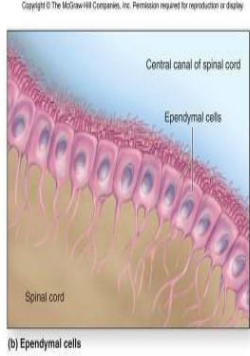
C- Pyriform neurons: in the cerebellar cortex (Purkinje cells)& the retina (ganglion cells).

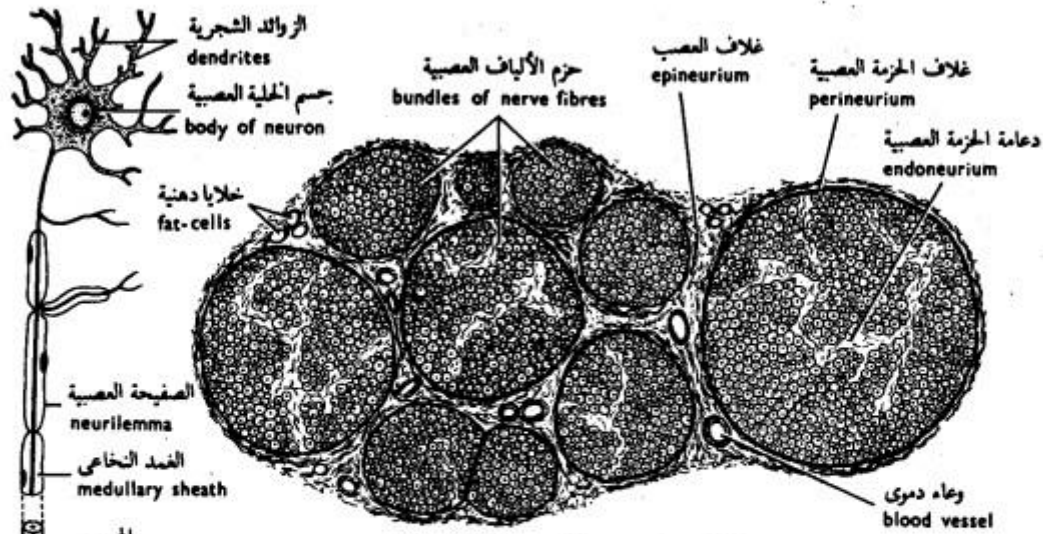
D- Granule cells: in the cerebellar cortex.



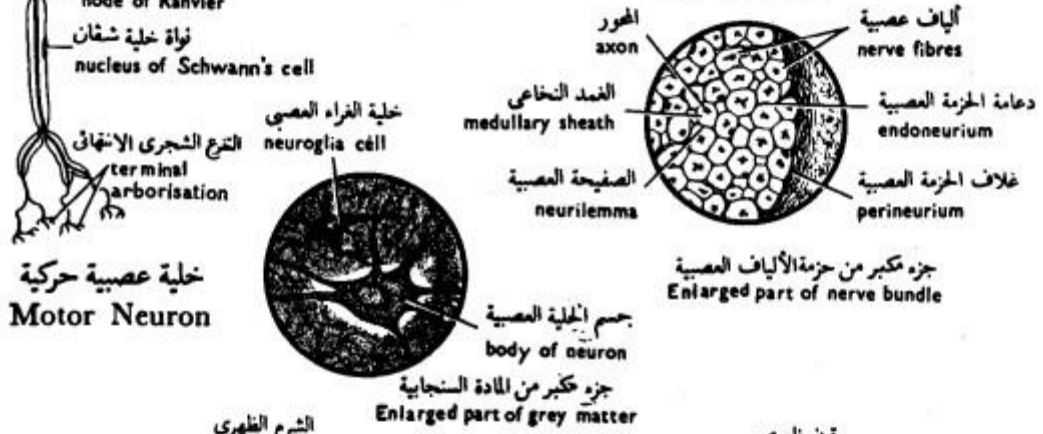
Nerve fiber

- Definition: It is an axon enveloped by a special sheath.
- It differs in the enveloping sheaths according to whether the fibers are part of the central or peripheral nervous system.

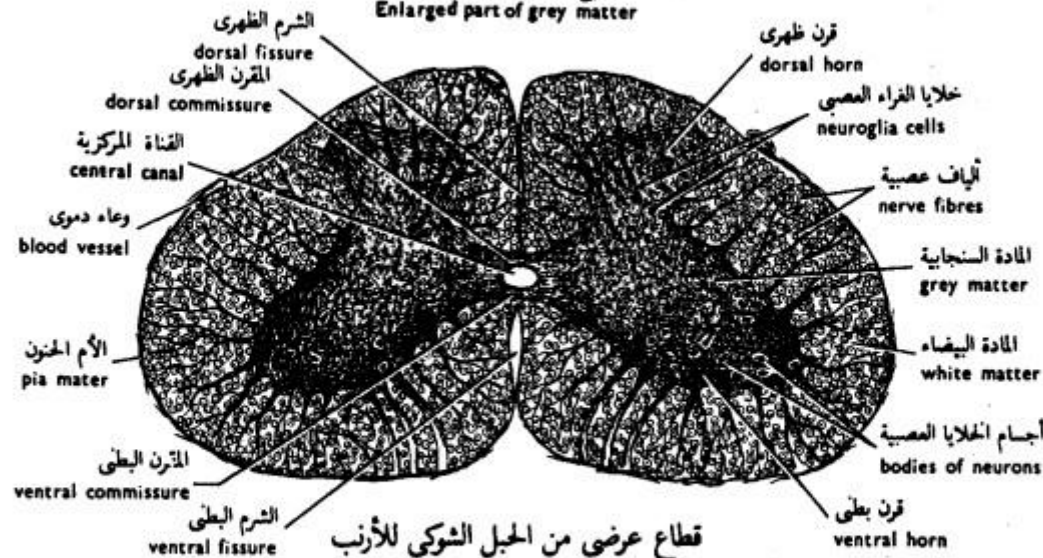
	Astrocyte =Macroglia	Microglia	Oligodendrocyte	Ependymal cell
LM: Shape	<ul style="list-style-type: none"> •Large stellate. •Multiple processes, end by foot like expansion on the blood vessels. 	<ul style="list-style-type: none"> •Small, oval. •Processes arising from the two poles. The cell body and the processes have minute spines. 	<ul style="list-style-type: none"> •Small cells. •Few short processes. • They are aligned in rows between the axons in the white matter. 	<ul style="list-style-type: none"> •Epithelial-like cuboidal cells, lining the brain ventricles and the central canal of the spinal cord. •Apically have microvilli and few cilia, while basally have numerous infoldings without a basement membrane.
Function	<ul style="list-style-type: none"> •Supportive •nutritive •Metabolic •Formation of blood brain barrier. 	Phagocytosis of bacteria, apoptotic and malignant cells.	Formation of the myelin sheath in the white matter of CNS	Formation of cerebro-spinal fluid.
	 <p>Blood vessel Perivascular foot Fibrous astrocyte</p>		 <p>Oligodendrocyte</p> <p>Labels: Dendrite, Process, Axon sheath, Spine, Nucleus, Head of fiber</p>	 <p>Copyright © The McGraw-Hill Companies, Inc. Permission required for reproduction or display.</p> <p>Central canal of spinal cord Ependymal cells Spinal cord</p> <p>(b) Ependymal cells</p>



قطاع عرضي من العصب الوركي للقط
T.S. of the Sciatic Nerve of the Cat



خلية عصبية حركية
Motor Neuron

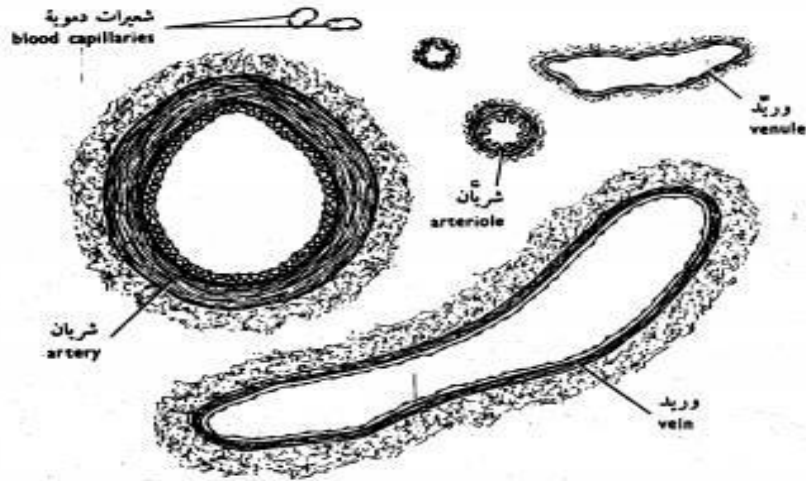


قطاع عرضي من الحبل الشوكي للارنب
T.S. of the Spinal Cord of the Rabbit

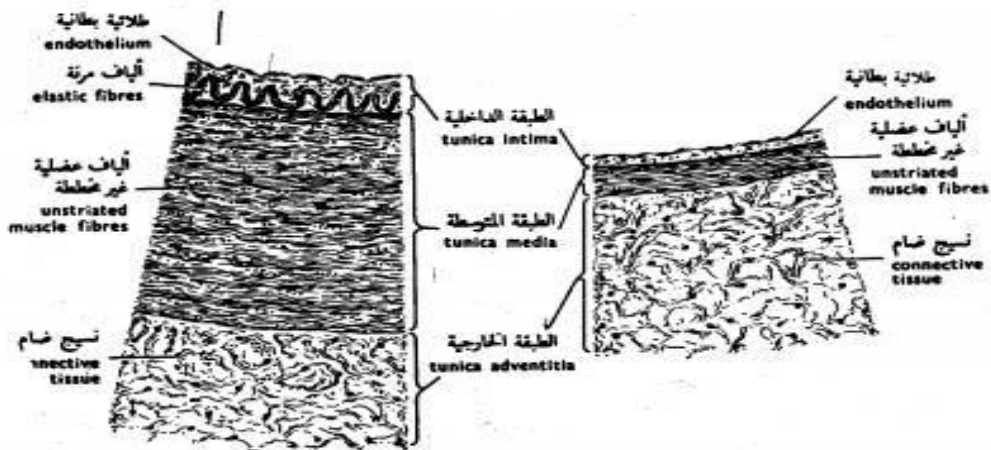
شكل ٤٣ - الأنسجة العصبية
FIG. 43 - NERVOUS TISSUES

The Organs

Blood vessels



قطاعات عرضية من أوعية دموية مختلفة
T.S. of different Blood Vessels

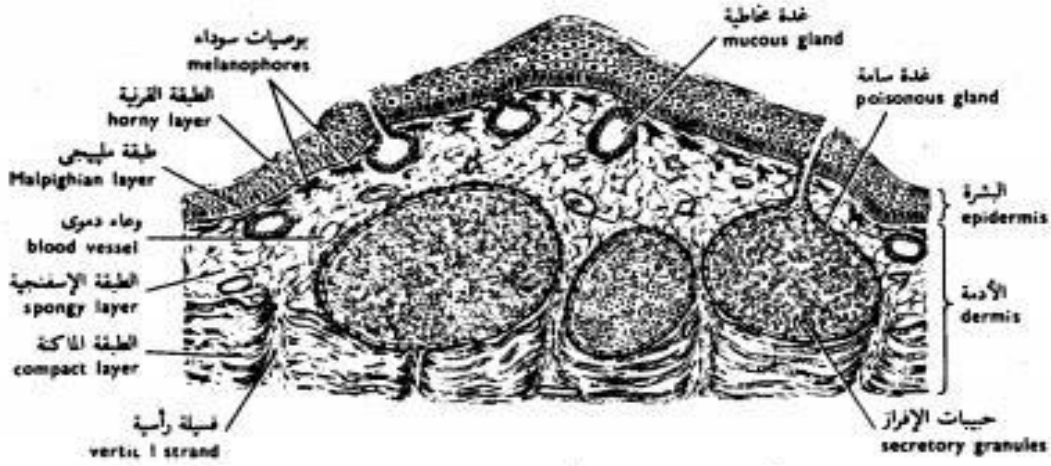


جزء من قطاع عرضي من جدار شريان
Sector of the wall of an Artery

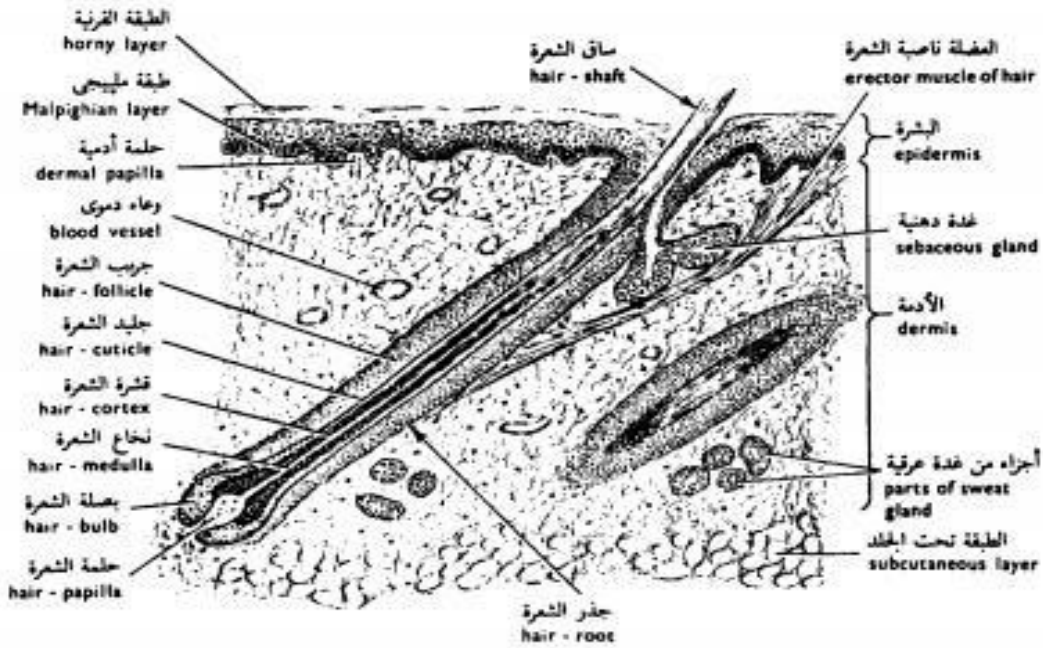
جزء من قطاع عرضي من جدار وريد
Sector of the wall of a Vein

شكل ٤٤ - الأوعية الدموية
FIG. 44 - BLOOD VESSELS

Skin

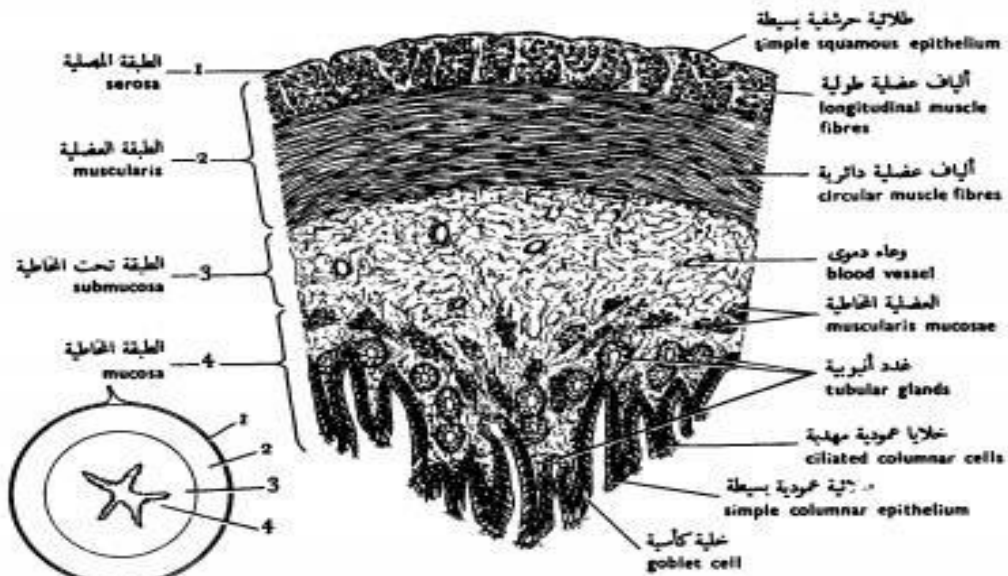


شكل ٤٥ - قطاع رأسي من جلد الضفدعة
 FIG. 45 - V. S. OF THE SKIN OF THE TOAD

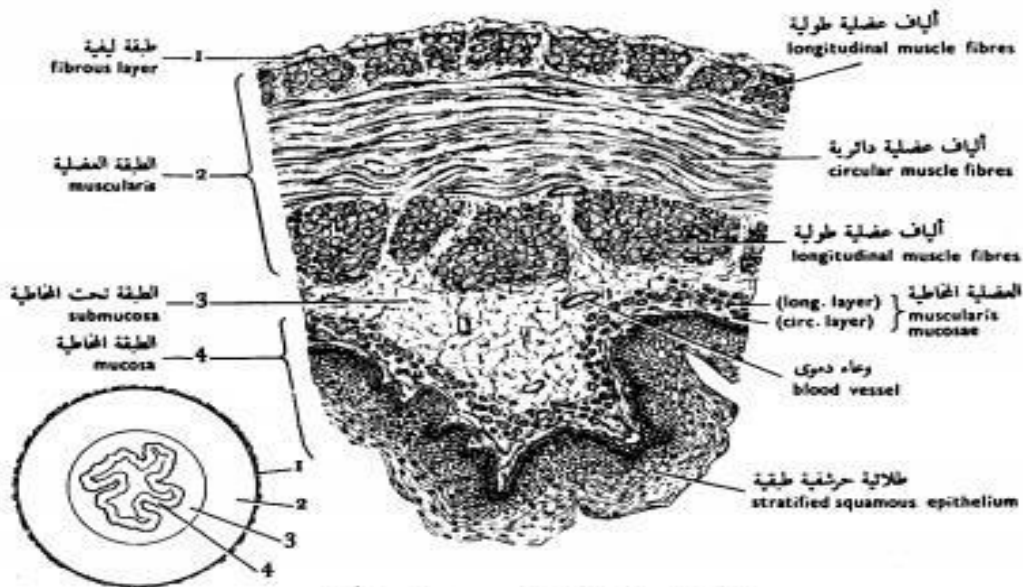


شكل ٤٦ - قطاع رأسي من جلد الخنزير
 FIG. 46 - V. S. OF THE SKIN OF THE PIG

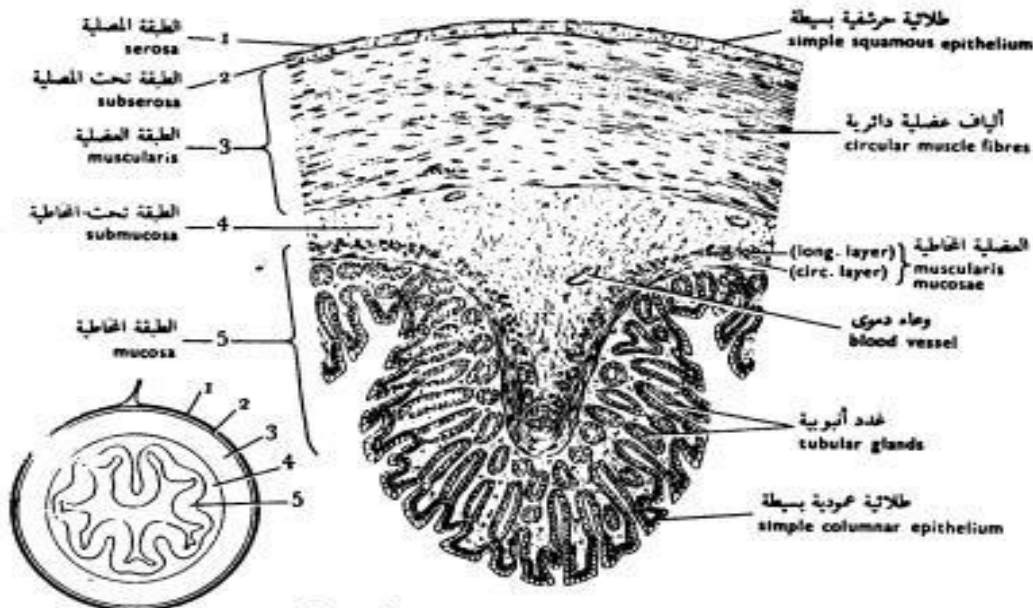
Digestive tract



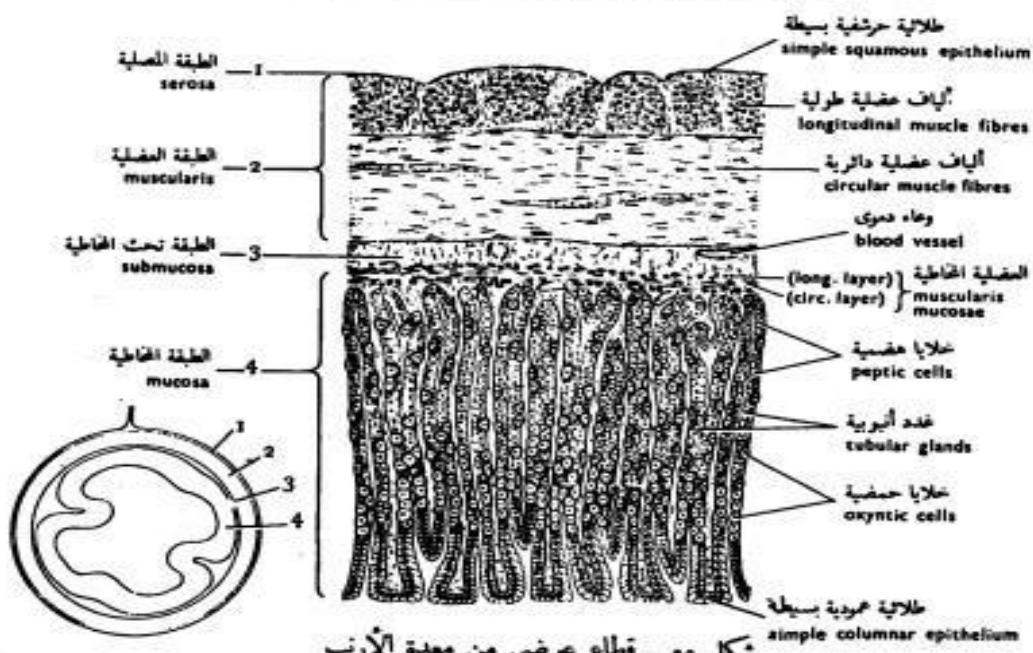
شكل ٥٢ - قطاع عرضي من مريء الضفدعة
 FIG. 52 - T.S. OF THE OESOPHAGUS OF THE TOAD



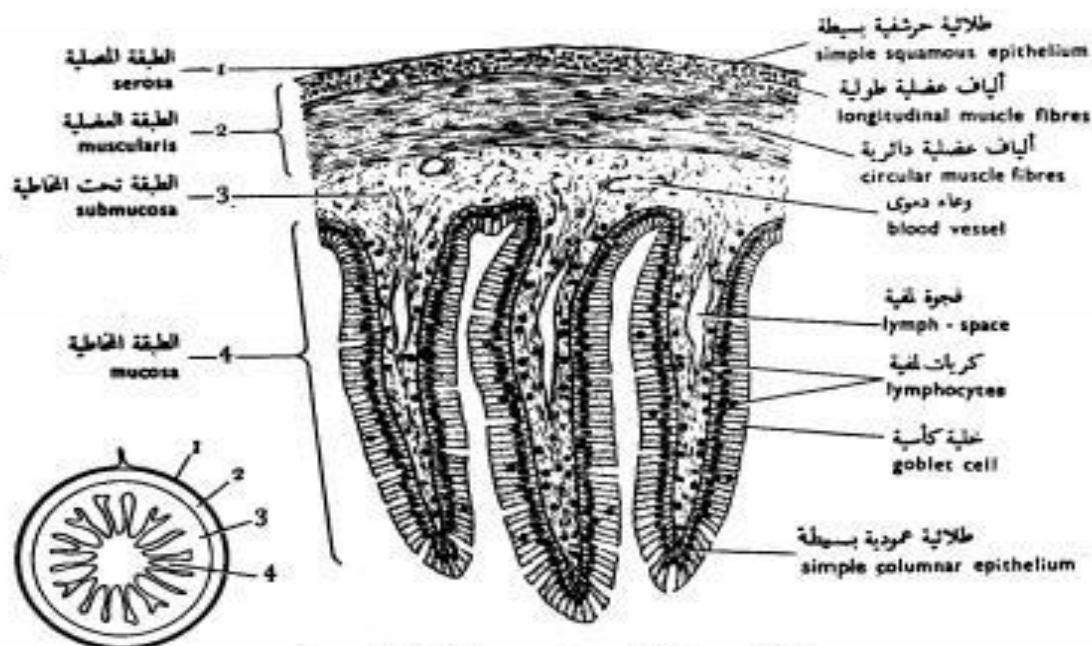
شكل ٥٣ - قطاع عرضي من مريء الأرنب
 FIG. 53 - T.S. OF THE OESOPHAGUS OF THE RABBIT



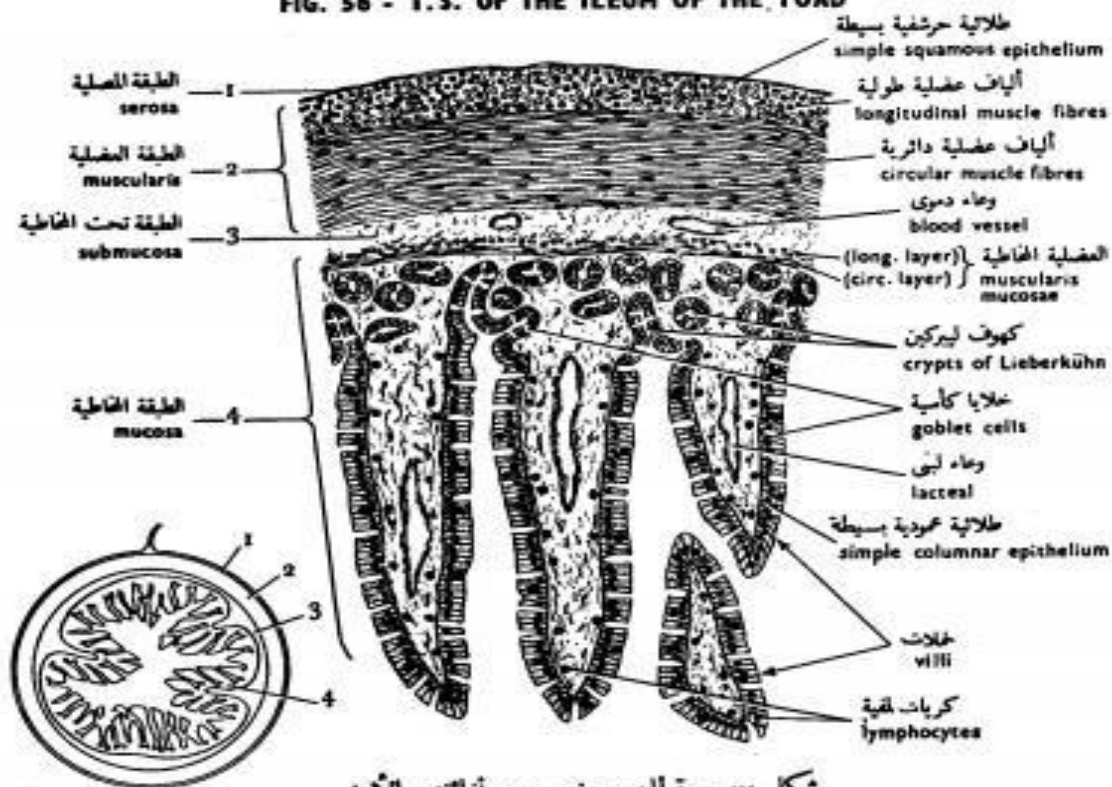
شكل ٥٤ - قطاع عرضي من معدة الضفدعة
 FIG. 54 - T.S. OF THE STOMACH OF THE TOAD



شكل ٥٥ - قطاع عرضي من معدة الأرنب
 FIG. 55 - T.S. OF THE STOMACH OF THE RABBIT



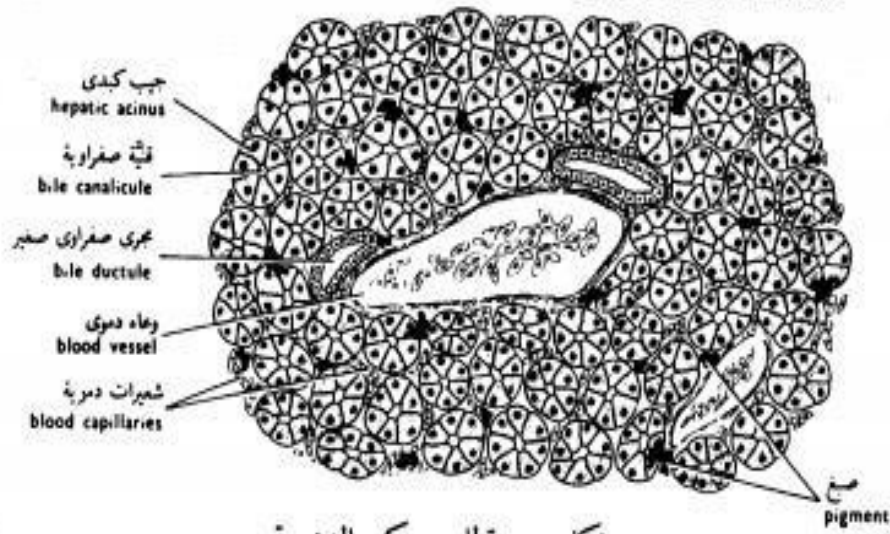
شكل ٥٦ - قطاع عرضي من لفاتقى الضفدعة
 FIG. 56 - T.S. OF THE ILEUM OF THE TOAD



شكل ٥٧ - قطاع عرضي من لفاتقى الأرنب
 FIG. 57 - T.S. OF THE ILEUM OF THE RABBIT

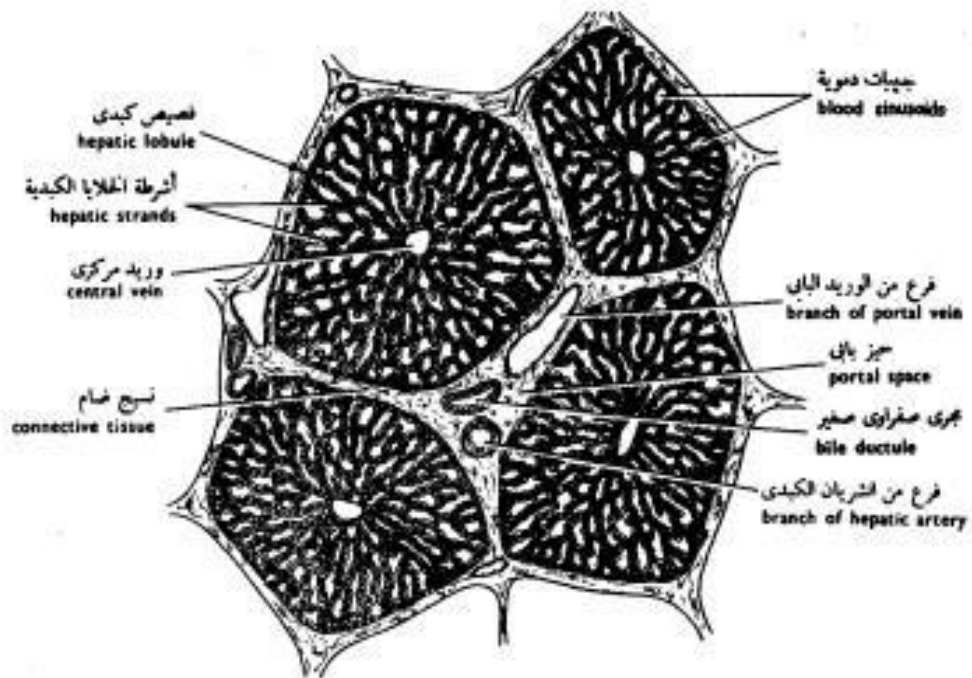
Liver

of the Toad's Liver



شكل ٥٩ - قطاع من كبد الضفدعة

FIG. 59 - S. OF THE LIVER OF OF THE TOAD



شكل ٦٠ - قطاع من كبد الخنزير

FIG. 60 - S. OF THE LIVER OF THE PIG

Kidney

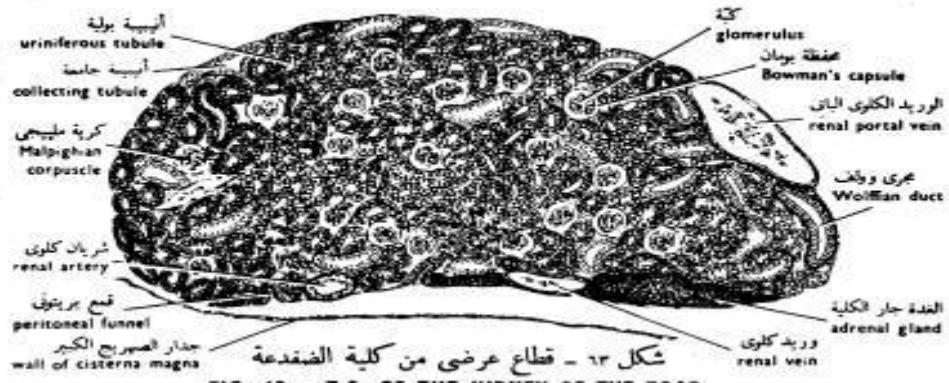

FIG. 63 - T.S. OF THE KIDNEY OF THE TOAD

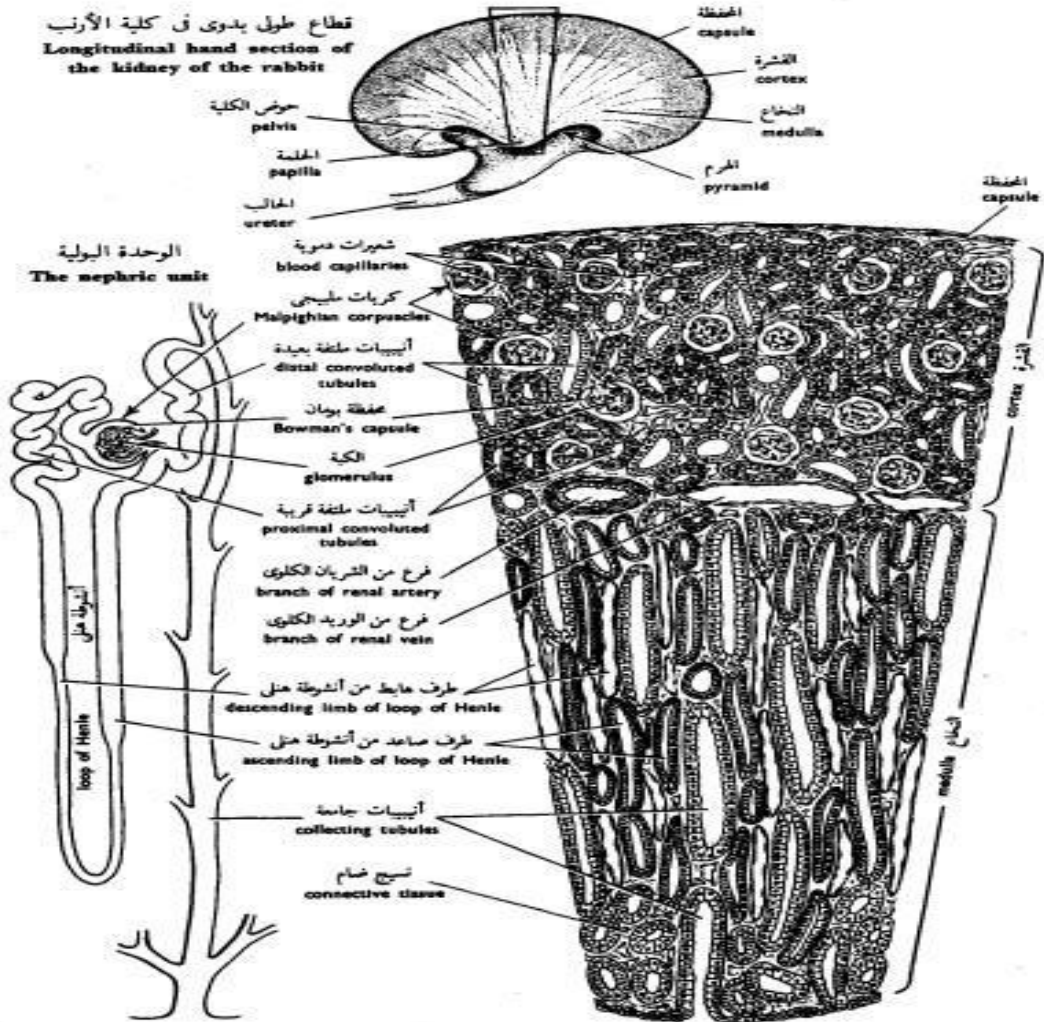
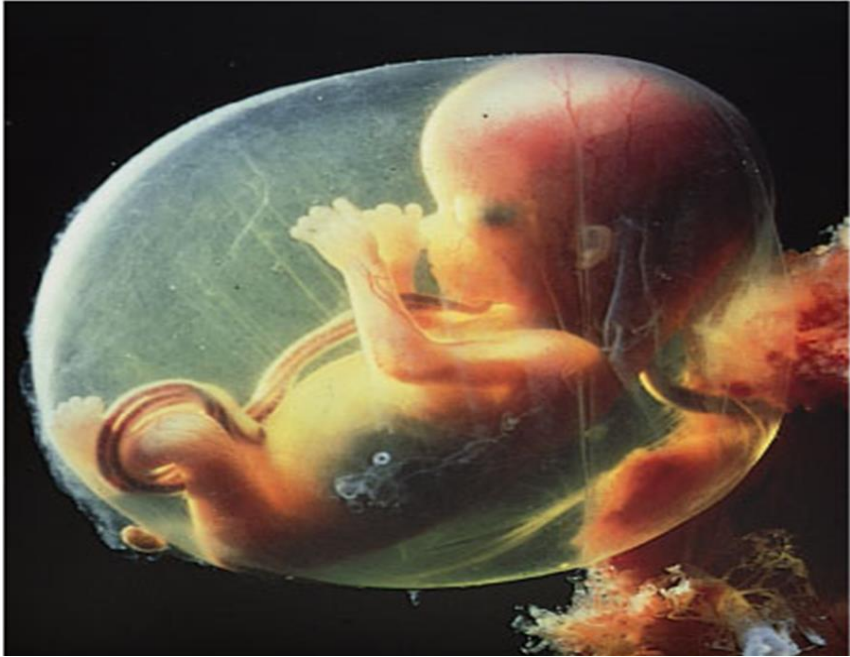

FIG. 64 - T.S. OF THE KIDNEY OF THE RABBIT

Embryology



علم الأجنة
د/ زينب كمال سيد

List of content

Embryology Definition	7
Historical of Embryology	7
Theories of embryology	8
1-Preformation Theory	8
3-Epigenesis Theory	10
3- Recapitulation Theory:	10
Embryology in Holy Quran	11
Branches of Embryology	13
1-Descriptive embryology	13
2-Experimental embryology	13
3-Teratology.....	13
4-Comparative Embryology	13
5- Developmental Biology.....	14
The value of Embryology	14
Reproduction	15
A- Asexual Reproduction	15
1- Fission :	15
2-Budding:	16

3- Sporulation:	16
4- Fragmentation:.....	17
5- Regeneration:.....	17
6-Parthenogenesis:	18
B- Sexual Reproduction :.....	19
The Normal Sequence of Events in Embryology	20
Vitellogenesis	26
Polarity and types of eggs	27
A- According to the amount of yolk.....	28
2- Oligolecithal type.....	28
4-Macrolecithal type	28
B- According to distribution of yolk	28
2- Fertilization.....	30
Types of Fertilization	30
External fertilization:	30
Internal fertilization:	30
3- Cleavage.....	31
Planes of cleavage.....	33
1- Meridional plane.....	34
2- Vertical plane.....	34

3- Equatoril plane.....	34
4- Latitudinal plane	35
Patterns of cleavage	35
Determinate cleavage.....	32
Indeterminate cleavage	33
1- Complete or holoblastic cleavage.....	35
2- Meroblastic (partial)cleavage	37
3-Radial cleavage.....	36
4-Spiral cleavag	37
Embryonic development of Amphioxus	40
Cleavage and blastula formation of Amphioxus	41
Gastrulation.....	43
Fates of the Primary Germ Layers	44
Ectoderm	44
Mesoderm.....	44
Endoderm.....	44
Embryonic development of Toad.....	45
The toad eggs	45
Cleavage:-	46
The toad blastula	47

Embryonic Development of Birds	50
Early embryonic development of birds.... Error! Bookmark not defined.	
The Blastula stage:	52
Embryonic Development of Mammals	54
Mammals classification according the embryonic development	54
Types of Mammals Uterus.....	54
Early Embryonic Development of human	55

List of figures

Figure1 : preformation theory	9
Figure2 :Embryos and Receptulation theory	11
Figure3 : Asexual reproduction by fission.....	15
Figure4 : Asexual reproduction by budding	16
Figure5 : Fragmentation in Planaria	17
Figure6 : Asexual reproduction by regeneration	18
Figure 7: Parthenogenesis	18
Figure 8:Sexual Reproduction	19
Figure 9: T.S. of testis of rat	22
Figure 10 : Human embryo (4 weeks old)	25

Figure11 :Animal – vegetal polarity	27
Figure12 :Telolecithal egg	29
Figure13 :Alecithal and Isolecithal egg	29
Figure14 :Isolecithal egg.....	29
Figure15 :Centrlecithal egg.....	29
Figure16 :Fertilization.....	30
Figure 17:cleavage	34
Figure18 : Meroblastic cleavage.....	39
Figure19 :Radial and spiral cleavage.....	39
Figure20 : Lateral view of Amphioxus.....	40
Figure 21 :Cleavage of Amphioxus	42
Figure 22: T.S. of blastula.....	42
Figure 23: Formation of gastrula (gastrulation).....	43
Figure 24: Toad egg	45
Figure 25: Cleavage and blastula formation of toad.....	49
Figure 26: birds egg	50
Figure 27: Cleavage and blastula formation of birds.....	52
Figure 28:cleavage and blastula formation of mammals	55
Figure 29: Formation of monozygotic twins	56

Embryology Definition

1- Embryology is the study of the origin and development of an organism

2- Embryology is the study of an animal's development from the fertilized egg to the formation of all major organ systems. But in its broadest sense it deals with the complex changes which an individual organism undergoes in its life cycle from fertilization to death.

Almost all higher animals start their lives from a single cell, the fertilized ovum (*zygote*). The zygote has a dual origin from two gametes- a spermatozoon from the male parent and an ovum from the female parent. The time of fertilization represents the starting point in the life history, or *ontogeny*, of the individual. In its broadest sense, ontogeny refers to the individual's entire life span.

The development of many animals is divided by the incident of the birth or hatching into - prenatal period and postnatal periods.

Historical of Embryology

Embryology as a branch of biology was initiated by the famous Greek philosopher Aristotle (384-322 B.C). He was

the first embryologist to describe the development and reproduction of many kinds of organisms in his book entitled "*Degenerazione Animalium*".

Theories of Embryology

1-Preformation Theory

Biologists of the seventeenth and eighteenth centuries believed in preformation, the concept that gametes contain miniaturized versions of all of the elements present in the adult. Some biologists thought that the ovum contained miniature of the adult, which was in some way stimulated to growth

by the seminal fluid. Some other biologist believed that preformed miniature organism presented in the head of the sperm.

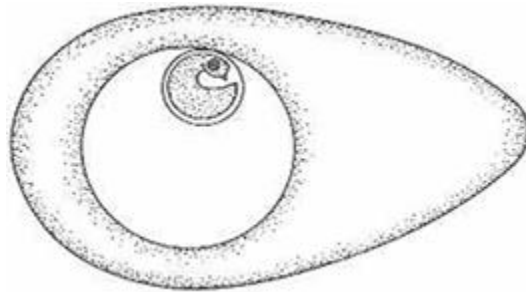
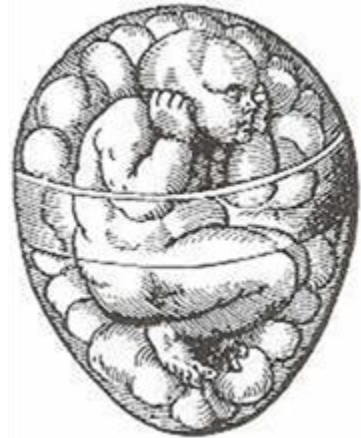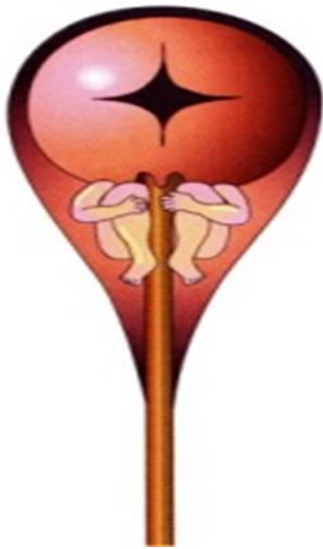


Figure1 : preformation theory

2-Epigenesis Theory

In the mid-eighteenth century, the theory of epigenesis maintained that the egg contains the material from which the embryo is gradually built. This theory assumes that embryonic development and differentiation originate in a homogeneous mass of living matter in which there is no preformed materials, neither tissue nor organs.

3- Recapitulation Theory:

This theory was postulated by *Ernst Haeckel* (1868) and *Muller* (1864). It is based on the contribution of evolutionary theory. This theory states that higher animals in their development passes through stages which are similar to the adult stages of lower animals which were their ancestors. That is the *ontogeny* briefly repeats or recapitulates the *phylogeny*. In other words the ancestral characters reappear in the developmental stages of an individual. Thus the recapitulation theory states that the embryonic stages of a higher animal resemble the adult stages of its ancestor.

4-Cell theory

After the formation of the cell theory, embryological research entered an entirely new avenue. It was discovered that the ovum was a single cell and that fertilization consisted of the union of the ovum and spermatozoon in the formation of the zygote.

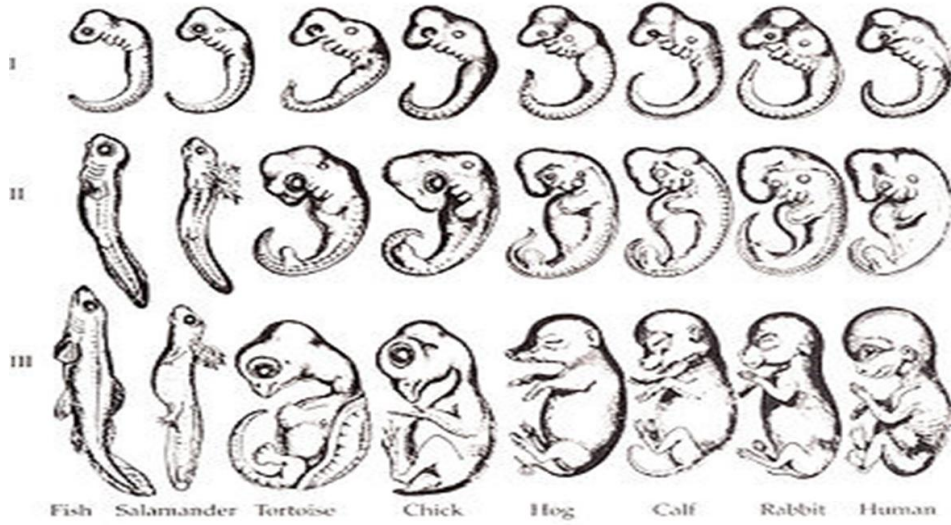


Figure2 : Receptulation theory

Embryology in Holy Quran

Before all these modern devices and technologies, the Holy Qur'an described many of the discoveries which discovered by modern science. the Holy Qur'an includes an accurate and comprehensive description of human creation from the time of the union of the gametes, during the formation of the organs, and after that.

قال الله تعالى:

(وَلَقَدْ خَلَقْنَا الْإِنْسَانَ مِنْ سُلَالَةٍ مِنْ طِينٍ (12) ثُمَّ جَعَلْنَاهُ نُطْقَةً فِي قَرَارٍ مَكِينٍ (13) ثُمَّ خَلَقْنَا النُّطْقَةَ عَلَقَةً فَخَلَقْنَا الْعَلَقَةَ مُضْغَةً فَخَلَقْنَا الْمُضْغَةَ عِظَامًا فَكَسَوْنَا الْعِظَامَ لَحْمًا ثُمَّ أَنْشَأْنَاهُ خَلْقًا آخَرَ فَتَبَارَكَ اللَّهُ أَحْسَنُ الْخَالِقِينَ (14) [المؤمنون].

(مَا لَكُمْ لَا تَرْجُونَ لِلَّهِ وَقَارًا (13) وَقَدْ خَلَقَكُمْ أَطْوَارًا (14) [نوح].

- وقوله تعالى: (يَخْلُقُكُمْ فِي بُطُونِ أُمَّهَاتِكُمْ خَلْقًا مِّن بَعْدِ خَلْقٍ فِي ظُلُمَاتٍ ثَلَاثٍ ذَلِكُمُ اللَّهُ رَبُّكُمْ لَهُ الْمُلْكُ لَا إِلَهَ إِلَّا هُوَ فَاتَىٰ تُصْرَفُونَ [الزمر: 6].

- وقوله تعالى: (يَا أَيُّهَا الْإِنْسَانُ مَا غَرَّكَ بِرَبِّكَ الْكَرِيمِ (6) الَّذِي خَلَقَكَ فَسَوَّاكَ فَعَدَلَكَ (7) فِي أَيِّ صُورَةٍ مَّا شَاءَ رَكَّبَكَ (8)] الانفطار].

- وقوله تعالى: (إِنَّا خَلَقْنَا الْإِنْسَانَ مِن نُّطْفَةٍ أَمْشَاجٍ نَّبْتَلِيهِ فَجَعَلْنَاهُ سَمِيعًا بَصِيرًا (2) [الإنسان]

- وقوله تعالى: (يَا أَيُّهَا النَّاسُ إِنَّا خَلَقْنَاكُمْ مِّن ذَكَرٍ وَأُنثَىٰ وَجَعَلْنَاكُمْ شُعُوبًا وَقَبَائِلَ لِتَعَارَفُوا ۗ إِنَّ أَكْرَمَكُمْ عِندَ اللَّهِ أَتْقَاكُمْ ۗ إِنَّ اللَّهَ عَلِيمٌ خَبِيرٌ (13) [الحجرات].

- وقوله تعالى: (يَا أَيُّهَا النَّاسُ إِن كُنْتُمْ فِي رَيْبٍ مِّنَ الْبَعْثِ فَإِنَّا خَلَقْنَاكُمْ مِّن تُرَابٍ ثُمَّ مِّن نُّطْفَةٍ ثُمَّ مِّن عَلَقَةٍ ثُمَّ مِّن مُّضْغَةٍ مُّخَلَّقَةٍ وَغَيْرِ مُخَلَّقَةٍ لِّنُبَيِّنَ لَكُمْ ۗ وَنُقِرُّ فِي الْأَرْحَامِ مَا نَشَاءُ إِلَىٰ آجَلٍ مُّسَمًّى ثُمَّ نُخْرِجُكُمْ طِفْلًا ثُمَّ لِتَبْلُغُوا أَشُدَّكُمْ ۖ وَمِنْكُمْ مَّن يُّتَوَفَّىٰ وَمِنْكُمْ مَّن يُّرَدُّ إِلَىٰ أَرْدَلِ الْعُمْرِ لِكَيْلَا يَعْلَمَ مِن بَعْدِ عِلْمٍ شَيْئًا (5) [الحج].

(وَصَيَّنَا الْإِنْسَانَ بِوَالِدَيْهِ إِحْسَانًا حَمَلَتْهُ أُمُّهُ كُرْهًا وَوَضَعَتْهُ كُرْهًا وَحَمَلُهُ وَفِصَالُهُ ثَلَاثُونَ شَهْرًا) (15) [الأحقاف].

Branches of Embryology

1-Descriptive embryology

Describes developmental stages of an animal with direct observation and description. (Development of a new animal begins with a sperm fertilizing an egg.)

2-Experimental embryology

Experiments are used for studying the developmental. It helps to understand the fundamental developmental mechanisms. In experimental embryology the various parts of developing embryo are removed, transplanted, parts exchanged or the environmental conditions altered. This helps to understand induction, gradient system, etc.

3-Teratology

It is a branch of embryology concerned with the study of malformations. During this century, great effort is being spent to identify and eliminate genetic and environmental factors that cause congenital defects.

4-Comparative Embryology

The embryological development of different animals are studied and compared. In recent years, comparative embryology has undergone a resurgence through the investigations of taxonomists, who have recognized that

valuable clues to taxonomic relationships among species can be found by studying their embryonic development.

5- Developmental Biology

It includes not only embryonic but also development postnatal processes such as normal and neoplastic growth, metamorphosis, regeneration and tissue repair.

The value of Embryology

1- From embryology we can learn in one short, story how each individual grows into an adult.

2- Much of the new technology is based on the results of laboratory researches.

3- Recent techniques make possible the diagnosis and/or treatment of genetic diseases and birth defects before a baby is born.

4- Study of the gene action by transfer the genes from one species into the egg of another species.

5- Examination of a small amount of the amniotic fluid that surrounds an embryo makes it possible to determine the sex of a baby before it is born and to detect the presence of genetic conditions that could lead to a defective child.

6-The " test-tube baby (IVF) in vitro fertilization and , has allowed some childless couples to have children from their own genetic heritage.

Reproduction

The process of reproduction is one of the characteristics of living organisms, and necessary to maintain the type of the organism to extinct.

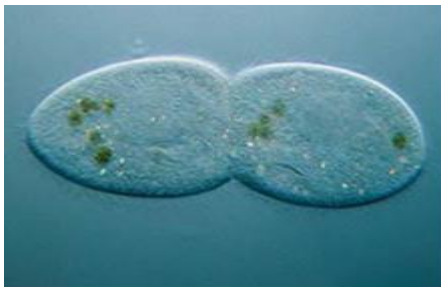
Types of Reproduction

A- Asexual Reproduction

Asexual reproduction is characterized by the transformation of a part of the old organisms into a new independent organism. This occurs through growth or budding or fission. The process of creating new individual using one parent organism. Asexual reproduction results in the generation of genetically identical offspring.

1- Fission :

Fission is the process where the body of the organism divides into two or more parts, each of them develops into a new organism. It is classified to simple binary fission, longitudinal or transverse binary fission.



Asexual reproduction of an aggregating sea anemone (*Anthopleura elegantissima*) by fission

Figure3 : Asexual reproduction by fission

2-Budding:

a new organism develops from an outgrowth or bud due to cell division at one particular site. The new organism remains attached as it grows, separating from the parent organism only when it is mature, leaving behind scar tissue. The budding may be simple (when one bud formed) or may be multiple (when many buds develop from the parental body simultaneously).

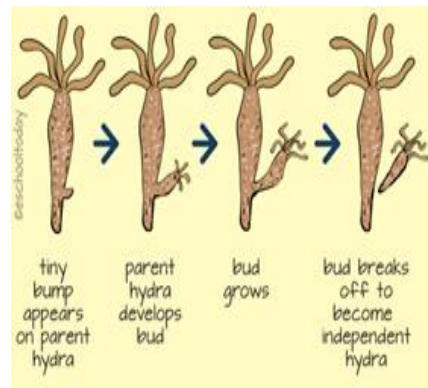
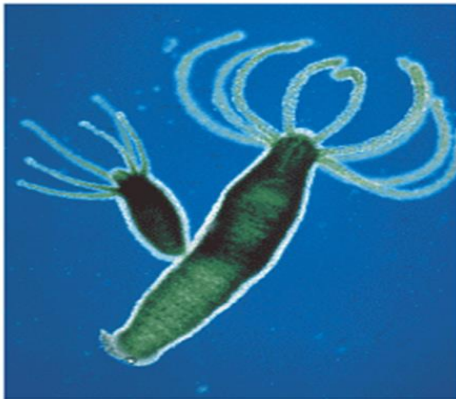


Figure4 : Asexual reproduction by budding

3- Sporulation:

The nucleus of the organism divides mitotically to produce a number of daughter nuclei. Then the entire organism having a number of daughter nuclei, secretes a hard and protective membrane to tide over the unfavorable conditions. When the favorable conditions come, each

nucleus along with a bulk of cytoplasm develops into new individual.

4- Fragmentation:

In such reproduction, small parts of one organism split off and subsequently mature as daughter organism. As in sea anemone, in which parts of the base are detached and grow into adult individuals.

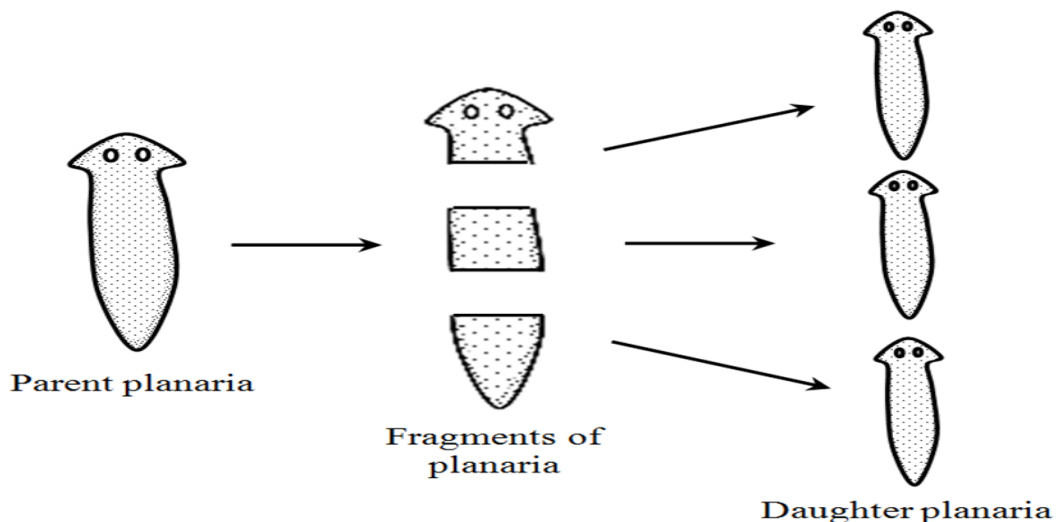


Figure5 : Fragmentation in Planaria

5- Regeneration:

Regeneration is equivalent to developing anew. Regeneration is employed to designate the reconstitution or new formation of an organ or part of an organism subsequent to remove the injury of these parts.

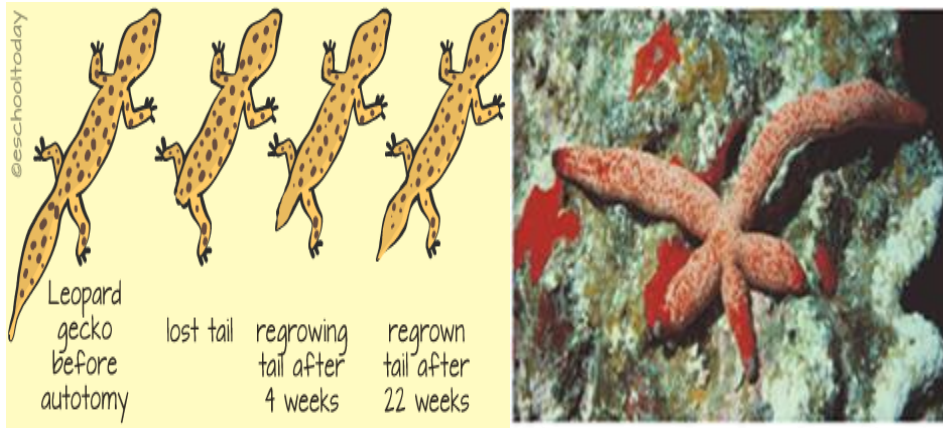


Figure6 : Asexual reproduction by regeneration

6-Parthenogenesis:

Is the phenomenon where the female gametes develop into new organisms without fertilization. The male and female gametes are formed but the male gametes fail to fertilize the female gametes.

Some organisms are able to do both sexual and asexual reproduction. This is particularly true for fungi and plants (and rarely, animals - as in parthenogenesis). Often, the type of reproduction that they undergo depends on their environmental conditions or the point in their growth cycles.



Figure 7: Parthenogenesis

B- Sexual Reproduction :

Sexual reproduction is characterized by fusion of male's smaller sperm and a female's large ovum (or egg). Each gamete contains half the number of chromosomes to form zygote. In some animals both kinds of gametes spermatozoa and ova are produced by a single individuals (Hermaphrodite). Process of creating new individual using two parent organisms. Sexual reproduction results in the generation of genetically unique offspring.

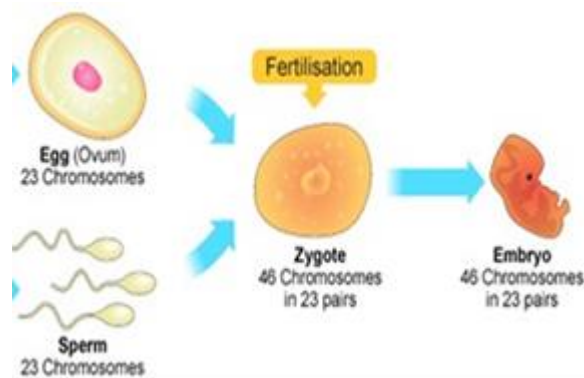


Figure 8:Sexual Reproduction

The Normal Sequence of Events in Embryology

- 1- Gametogenesis
- 2- Fertilization
- 3- Cleavage and blastula formation
- 4- Gastrulation
- 5- Organgogenesis

SOME TERMS

Gamete: egg or sperm

Gametogenesis: production of eggs or sperm

Oogenesis: production of eggs

Spermatogenesis: production of sperm

Spermiogenesis: differentiation of sperm morphology

Follicle: where eggs mature in the ovary

Ovulation: release of egg from follicle

Polar body: nonfunctional product of meiotic divisions in oogenesis

Zygote: Fertilized egg

Oogonia: mitotically dividing cells in the ovary, will become oocytes

Primary oocyte: decision has been made to undergo meiosis, cell has grown. Cells are arrested at this stage until puberty.

Secondary oocyte: has completed first meiotic division, the division was unequal in terms of cytoplasm

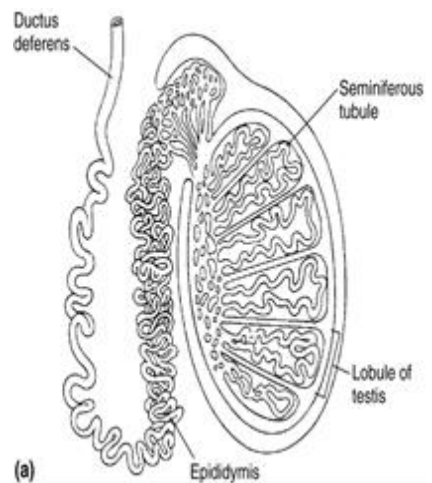
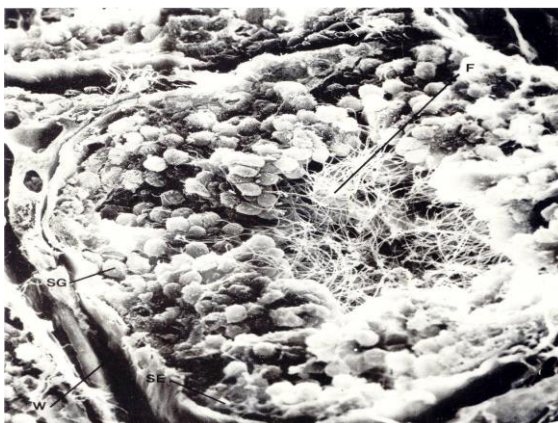Ovum: Ovulated egg, ready to be fertilized. If fertilized, the second meiotic division will occur, another polar body will be given off.

Diploid: Having the full chromosome number (46 in humans).

Haploid: Having half the full chromosome number (23 in humans).

Male Reproductive System

The mammalian testes are divided into many lobules, and each lobule contains many tiny seminiferous tubules. Sperm develop in an ordered fashion in these tubules. Cells start to mature on the outside and move inward (towards the lumen) as they become mature sperm.



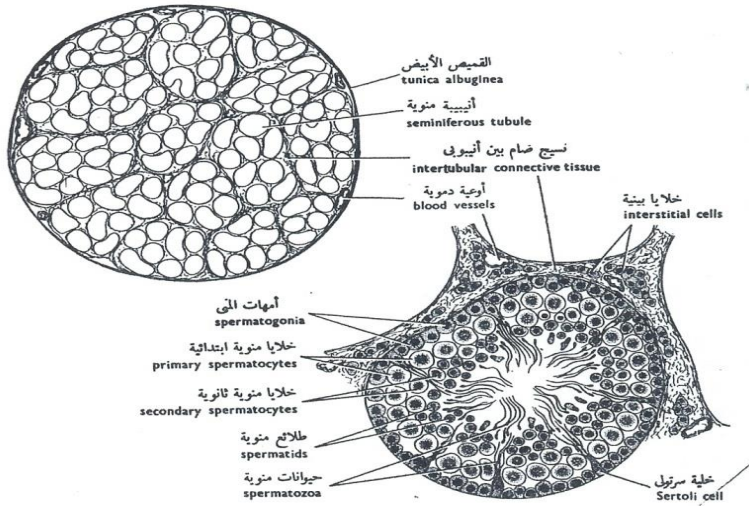
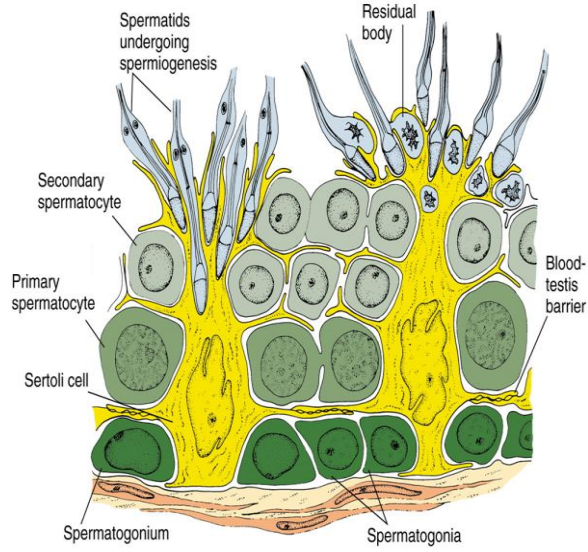


Figure 9: T.S. of Testis

The testes contain millions of *spermatogonia*. Spermatogonia are the most primitive cells.

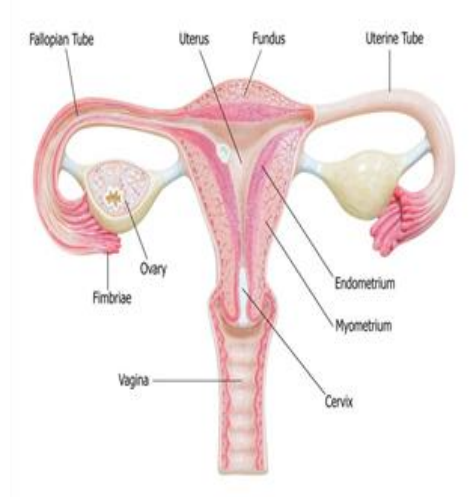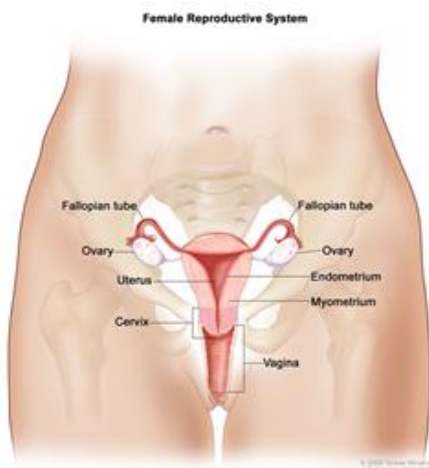
Each of these cells can develop into a primary spermatocyte.

-A primary spermatocyte will undergo Meiosis Division I to produce two secondary spermatocytes.

-Finally, each secondary spermatocyte undergoes Meiosis Division II resulting in four sperm cells.

- Each sperm cell receives the same amount of cytoplasm. Spermatogenesis results in equal distribution of the cytoplasm, in contrast to oogenesis which has unequal cytoplasmic division.

Female Reproductive System

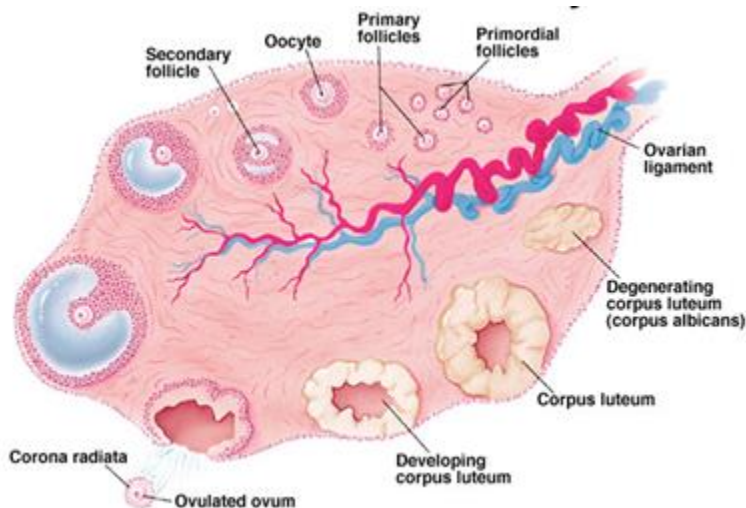


The ovary has three main histological features

Surface – formed by simple cuboidal epithelium (known as germinal epithelium). Underlying this layer is a dense connective tissue capsule.

Cortex – comprised of a connective tissue stroma and numerous ovarian follicles. Each follicle contains an oocyte, surrounded by a single layer of follicular cells.

Medulla -formed by loose connective tissue and a rich neurovascular network, which enters via the hilum of the ovary.



1- Gametogenesis

Is the formation of the germ cells or gametes.

- Each gamete contains haploid number of chromosomes.
- Both kinds of gametes are produced by different individuals of an animal species

The cells which are destined to develop into gametes are called primordial germ cells.

The primordial germ cells originate in the endoderm of adjoining region of the yolk sac in human before migrating into the gonads (tests or ovary).

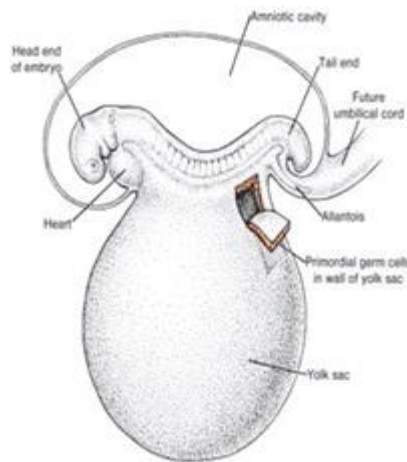


Figure 10 : Human embryo (4 weeks old)

The timing of meiosis differs in females and males

In males, the spermatogonia enter meiosis and produce sperm from puberty until death. The process of sperm production takes only a few weeks.

In females, this process is more complex. The first meiotic division starts before birth but fails to proceed. It is eventually completed about one month before ovulation in

humans. In humans, the second meiotic division occurs just before the actual process of fertilization occurs.

Thus, in females, the completion of meiosis can be delayed for over 50 years. This is not always good.

Only 1 egg produced

In addition, all meiosis is ended in females at menopause.

Spermatogenesis

Spermatogenesis occurs in the seminiferous tubules

Vitellogenesis

Vitellogenesis is the process of producing the major yolk proteins. Animal eggs contain large amounts of protein, lipid, and glycogen to nourish the embryo. These materials are collectively called yolk. Yolk proteins are synthesized in the liver in vertebrates, or in the fat body of insects.

Yolk is minimal in animal eggs that sustain only the first portion of embryogenesis (humans and many mammals that have a placenta need only support cleavage for several days before implantation into the uterus). Yolk is stored in

large amounts in the eggs of birds and reptiles because their eggs have to support the entire process of development.

When little yolk is present, young develop into larval stages that can feed (Indirect development). When lots of nourishing yolk is present, embryos develop into a miniature adult (Direct development). Mammals have little yolk, but nourish the embryo via the placenta.

Polarity and types of eggs



Figure11 :Animal – vegetal polarity

On the basis of presence or absence and amount of yolk particles, the eggs classified as follows:

A- According to the amount of yolk

the egg arranged into the following

1-Alecithal type

When the yolk particles are entirely lacking as in placentals (Mammals).

2- Oligolecithal type

Here the yolk particles are present but in little amount as in Echinodermata Amphioxus, hydra.

3-Mesolecithal type: The yolk particles are present in Moderate amount as in toad.

4-Macrolecithal type

In birds and reptiles and egg laying mammals, the yolk particles are in good amount. The yolk is concentrated in the vegetal pole Here, in such cases the size of nucleus and cytoplasm reduce and lie in the form of a small germinal disc at the animal pole.

B- According to distribution of yolk

Isolecithal type when yolk particles are distributed evenly throughout the cytoplasm as in fishes.

Centrolecithal type

In insects and other Arthropods the yolk particles are restricted to the center of the egg.

Telolecithal type

When the yolk increases in quantity and becomes accumulated at one end or pole of the egg as in frog, toad and some fishes.

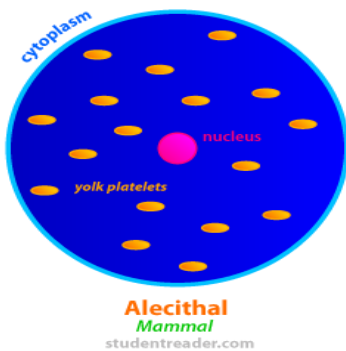


Figure13 :Alecithal and Isolecithal egg

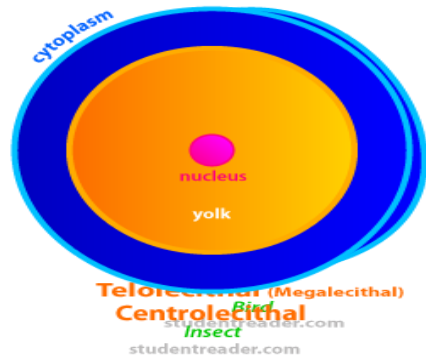


Figure15 :Centrlecithal egg

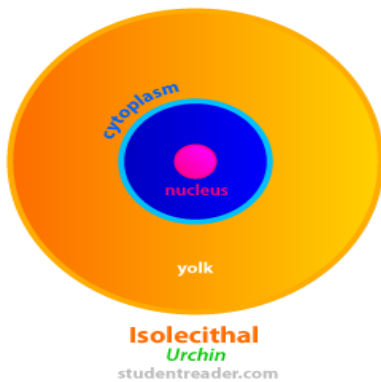


Figure14 :Isolecithal egg

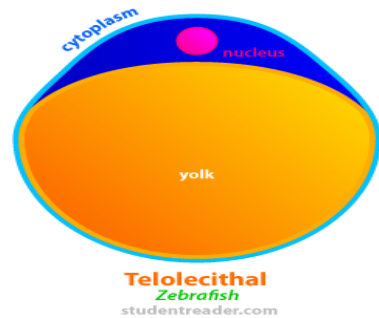


Figure 13 : Telolecithal and macrolecithal

2- Fertilization

Definition: The process by which the male and female gametes (sperm and ovum) unite to give rise to zygote.

Types of Fertilization

External fertilization:

When the fertilization occurs in the aquatic medium outside the bodies of male and female parents.

Internal fertilization:

In terrestrial forms, particularly where eggs are completely enclosed in impermeable envelopes before being laid (birds), or where they are retained within the maternal body throughout development (mammals), thus the fertilization occurs inside the body of the female.

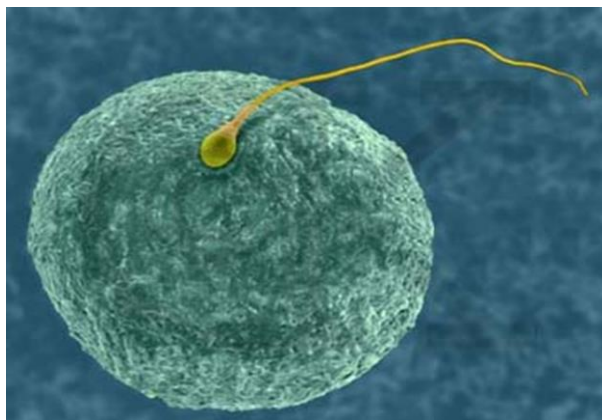


Figure16 :Fertilization

The main results of fertilization are as follows:

- 1- Restoration of the diploid number of chromosomes, half from the father and half from the mother. Hence, the zygote contains a new combination of chromosomes different from both parents.
- 2- Determination of the sex of the new individual. An X-carrying sperm produces a female (XX) embryo, and a Y-carrying sperm produces a male (XY) embryo. Hence, the chromosomal sex of the embryo is determined at fertilization.
- 3- Initiation of cleavage. Without fertilization, the oocyte usually degenerates 24 hours after ovulation.

Zygote is a fertilized egg. A fertilized egg becomes an embryo as soon as the first cleavage occurs. The zygote ultimately, produced a diploid multicellular organism by the several repeated and organised mitotic divisions and cellular differentiation.

3- Cleavage

The development of a normal, adult animal from a zygote involves a series of distinct steps in which specific takes are

accomplished, *cleavage*, the mitotic division of the egg or , is the first step after fertilization and is a universally occurring phenomenon among metazoan animals, very little growth occurs. The cells that arise from cleavage are known as blastomeres.

-The pole of the egg with the highest concentration of yolk is referred to as the vegetal pole while the opposite is referred to as the animal pole.

Influence of yolk on cleavage, in two ways:

- 1- It affects the rate of cleavage
- 2- It determines the pattern of cleavage

When the yolk is abundant, it tends to retard and even inhibit the process of cleavage. As a result, the blastomeres which are rich in yolk tend to divided at a slower rate, and consequently they remain larger than those which have less yolk. The yolk is more concentrated at the vegetal pole. Therefore at the vegetal pole the cleavage in most retarded, and also where the blastomeres are larger in size.

Determinate Cleavage

Determinate cleavage (also called mosaic cleavage) is in most protostomes. It results in the developmental fate of the cells being set early in the embryo development. Each blastomere produced by early

embryonic cleavage does not have the capacity to develop into a complete embryo.

Indeterminate cleavage

A cell can only be indeterminate (also called regulative) if it has a complete set of undisturbed animal/vegetal

cytoarchitectural features. It is characteristic of deuterostomes – when the original cell in a deuterostome embryo divides, the two resulting cells can be separated, and each one can individually develop into a whole organism.

Planes of cleavage

Cleavage is initiated by the appearance of a groove or constriction called cleavage furrow. The furrow appears first at one point of the egg. For example, the furrow appears at the animal pole. The furrow then deepens and extends downward on both sides. The two ends meet at the vegetal pole. The furrow then extends inwards radially, finally constricting the egg into two blastomeres.

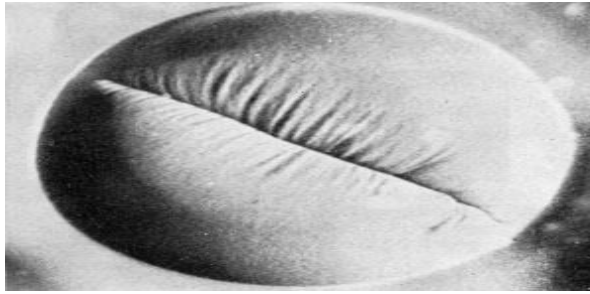


Figure 17:cleavage

The cleavage furrow divide the egg at different angles or plans. There are four main planes of cleavage. They are as follows:

1- Meridional plane

The cleavage furrow passes through the center of animals-vegetal axis and bisects the both poles of the egg.

2- Vertical plane

The cleavage tend to pass in a direction from the animal pole toward the vegetal pole. It does not pass through the median axis of the egg.

3- Equatoril plane

The cleavage furrow bisects the egg at right angles to the main axis and half way between the animal and vegetal poles.

4- Latitudinal plane

The cleavage furrow is similar to the equatorial but it courses through the cytoplasm on either side of the equatorial plane. It also called transverse or horizontal plane.

Patterns of cleavage

In the absence of a large concentration of yolk, four major cleavage types can be

In holoblastic eggs, the first cleavage always occurs along the vegetal-animal axis of the egg, the second cleavage is perpendicular to the first. From here, the spatial arrangement of blastomeres can follow various patterns, due to different planes of cleavage, in various organisms.

A- Complete or holoblastic cleavage

In holoblastic, total or complete cleavage, the entire egg divides by each cleavage furrow, observed in isolecithal cells (cells with a small even distribution of yolk) or in mesolecithal cells (cells with a moderate amount of yolk), It may be :

- 1- Bilateral holoblastic cleavage
- 2- Radial holoblastic cleavage
- 3- Rotational holoblastic cleavage
- 4- Spiral holoblastic cleavage.

1-Bilateral holoblastic cleavage

The first cleavage results in bisection of the zygote into left and right halves. The following cleavage planes are centered on this axis and result in the two halves being mirror images of one another. In bilateral holoblastic cleavage, the divisions of the blastomeres are complete and separate; compared with bilateral meroblastic cleavage, in which the blastomeres stay partially connected.

2- Rotational cleavage

Rotational cleavage involves a normal first division along the meridional axis, giving rise to two daughter cells. The way in which this cleavage differs is that one of the daughter cells divides meridionally, whilst the other divides equatorially. Mammals display rotational cleavage.

3-Radial cleavage

In radial cleavage the cleavage furrows appear in such that each of blastomeres of the upper tier lies over the corresponding blastomeres of the lower tiers

This pattern of cleavage is one in which the organism viewed from above (dorsal, animal pole) is essentially radial in symmetry- where a dorso-ventral slice in any plane will yield a set of mirror images. As in deuterostomes.

4-Spiral cleavag

Spiral cleavage is an early cleavage pattern in which cleavage planes are not parallel or perpendicular to the animal-vegetal pole axis of the egg. Cleavage takes place at oblique angles, forming a “spiral” pattern of daughter blastomeres. As in Protostomes

B- Meroblastic (partial)cleavage

In meroblastic cleavage, only a portion of the egg divides (partial or incomplete cleavage. It is characteristic of telolecithal eggs. It may be :

1- Discoidal meroblastic cleavage

It occurs in fishes, reptiles, and birds. Here the cytoplasm is placed at the animal pole as a disc called blastodisc, and this disc alone divides, the huge mass of yolk does not participate in cleavage.

2- Superficial meroblastic cleavage

In centrolecithal ovum, the cleavage remains restricted to the peripheral cytoplasmic investment. As in insects, where

there is a moderate to large amount of yolk, and it is concentrated in the center of the egg. This means that although there is resistance to cleavage plane development in the center of the egg, it is easier to develop cleavage plane at the periphery of the egg – and thus early zygote.

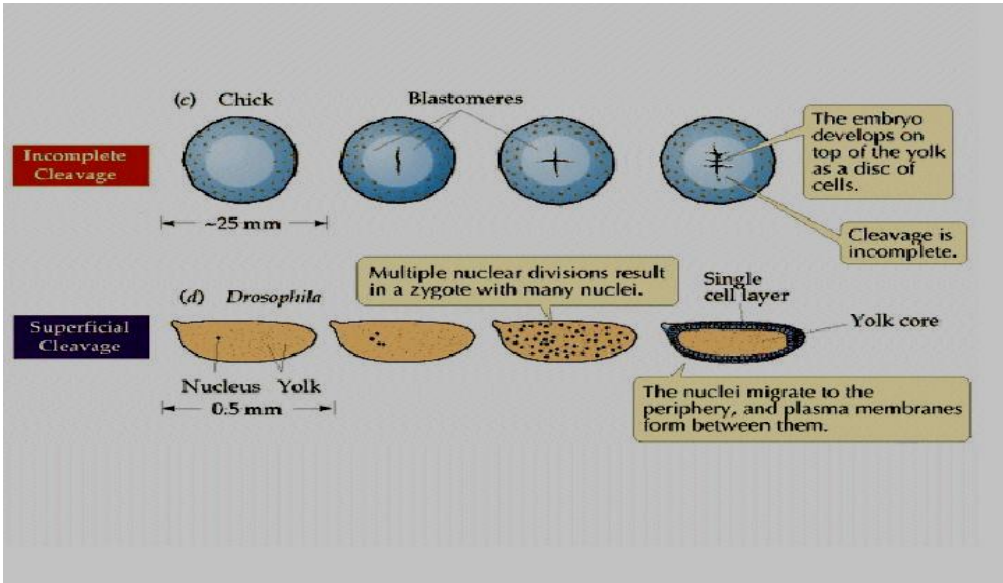
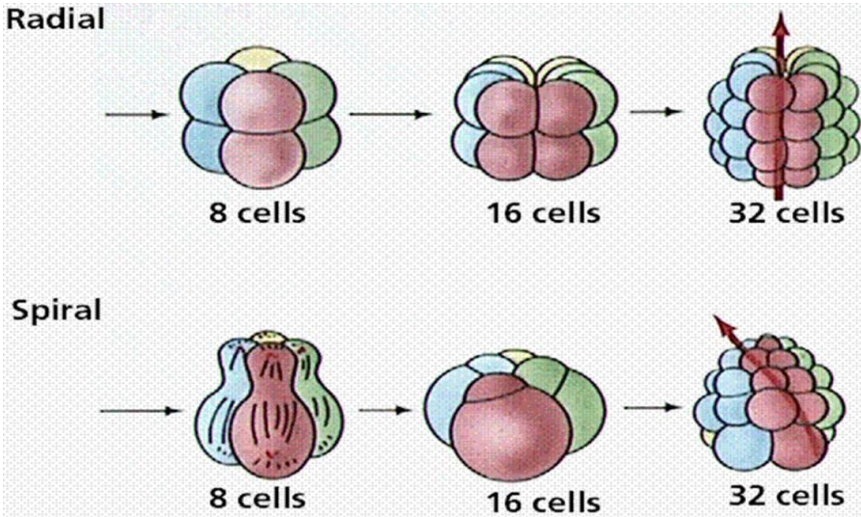


Figure18 : Meroblastic cleavage



Embryonic development of Amphioxus

Phylum: Chordata – Class: Cephalochordata

Fertilization : External.

Type of Egg: According to amount of yolk oligolecithal.

According to distribution of yolk isolecithal.

Type of cleavage: Equal holoblastic cleavage.

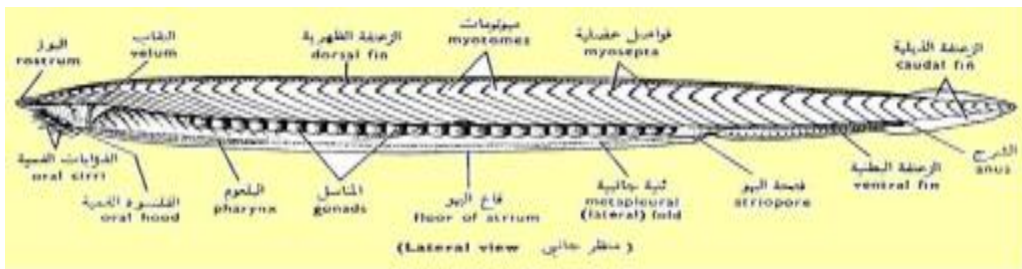


Figure20 : Lateral view of Amphioxus

Cleavage and blastula formation of Amphioxus

The first cleavage is longitudinal and gives two equal blastomeres.

The second cleavage is vertical on the first and gives 4 equal blastomeres.

The third is horizontal above the equatorial line and gives 8 blastomeres, 4 small upper micromeres and 4 large lower (yolkier) macromeres.

The Fourth : two vertical cleavage gives 16 blastomeres.

The Fifth : two Meridional (horizontal) gives 32 blastomeres.

The cleavage proceeds with irregular manners with increased in the number of cells. Up to this stage, the blastomeres remain loosely packed and form the embryonic stage, called **morula**.

Meanwhile, a semifluid materials accumulates in the centre of this mass of cells. This fluid serves to push all the blastomeres outwards, so that they become arranged in single layer called **blastoderm**, enclosing a central fluid filled cavity, the **blastocoel**.

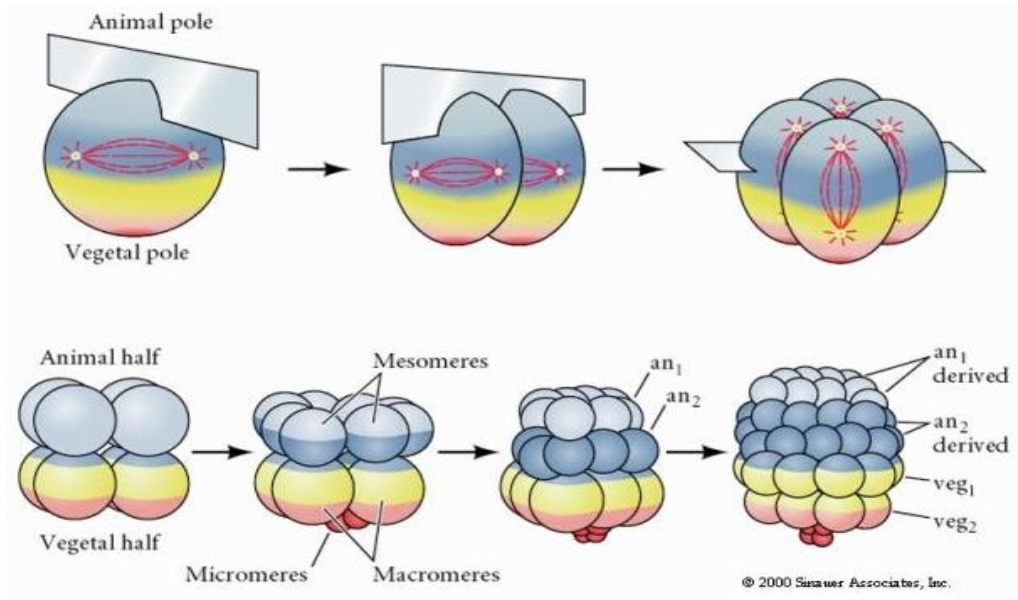


Figure 21 :Cleavage of Amphioxus

-The Blastula

is a hollow ball of a single layer of cells. The cavity of the blastula (the blastocoele), is centric. The cells of the vegetal hemisphere (the prospective endoderm) are somewhat richer in the yolky material than the other cells and slightly larger than those of the animal hemisphere (the prospective ectoderm).

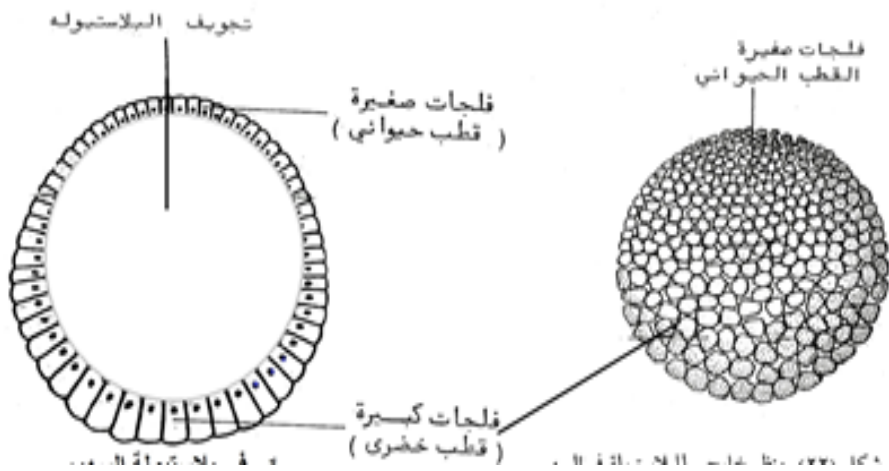


Figure 22: T.S. of blastula

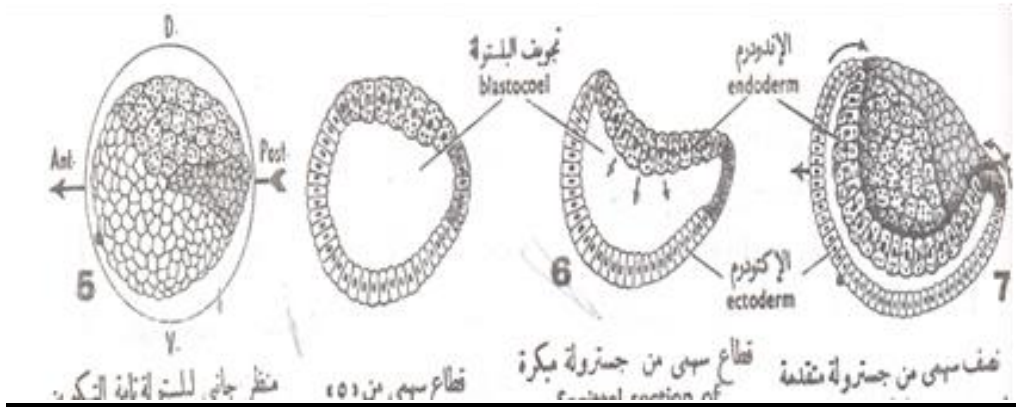


Figure 23: Formation of gastrula (gastrulation)

Gastrulation

This occurred as a result of different cell movements simply by invagination of the macromeres inwards the micromeres, thus the blastocoel decreased in size and a new cavity appears called gastrocoel or archenteron. Gastrulation rearranges the blastula to form a three-layered embryo with a primitive gut

The three germ layers are outer ectoderm, inner endoderm and mesoderm in between.

Diploblastic gastrula = **2** germ layers.

Triploblastic = **3** germ layers

Fates of the Primary Germ Layers

Ectoderm

- hair, nails, epidermis, brain, nerves

Mesoderm

- Notochord, dermis, blood vessels, heart, bones, cartilage, muscle

Endoderm

- internal lining of the gut and respiratory pathways, liver, pancreas

Embryonic development of Toad

Phylum: Chordata – Class: Amphibia

Fertilization : External.

Type of Egg: According to amount of yolk mesolecithal.

According to distribution of yolk telolecithal.

Type of cleavage: Unequal holoblastic cleavage.

Adult toads live on land most of the time and rely on water for hydration, breeding, and temperature regulation.

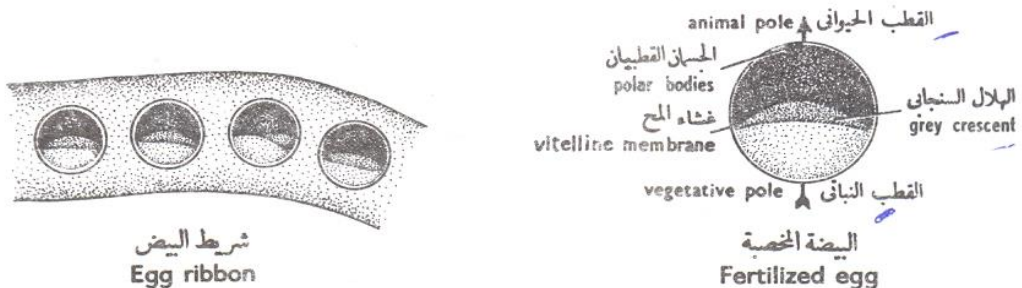


Figure 24: Toad egg

The toad eggs

The upper hemisphere of the frog egg is black due to the presence of many pigment granules which is called animal hemisphere or animal pole. The dark colour of the egg is an adaptation for absorbing and retaining heat as eggs are laid in water when ponds and streams are very cold. The other half is lighter in colour provided with yolk; this is called vegetal pole or yolk pole. The nucleus is situated in the upper pigment part.

During fertilization: The whole spermatozoon enters the ovum. The tail then disintegrates, the head and middle piece travel carrying a trail of black pigment behind it which results an area opposite the sperm entrance point, to have a slightly decreased pigment content. This lighter pigmented area is called the gray crescent.



Cleavage:-

The first cleavage plane is meridional. This cleavage furrow first appear near the animal pole and progressively extend towards the vegetal pole of the egg. It cuts the egg through its median animal-vegetal polar axis and results in 2 equal sized blastomeres.

The second division is holoblastic and equal, and the planes are meridional, but at the right angle to the first plane and results in 4 equal sized blastomeres.

The third division is latitudinally parallel to the axis, and displaced as they are toward the animal pole, due to the unequally distributed yolk. The resulted 8 blastomeres consists of four small-sized (the micromeres) and four large-sized yolk- rich, vegetal cells (the macromeres).

The fourth cleavage is usually double. It tends to be vertical,. The furrows begin near the center of the animal pole and progress vegetally, dividing each of the original four blastomeres of the animal hemisphere resulted in 16 blastomeres. The uppermost cells (micromeres) divides most rapidly, while the vegetative cells divides more slowly.

The fifth cleavage (also double), which should provide a 32-cell. The smallest cells, which contain the most pigment, are now found at the animal pole, and the largest blastomeres with no pigment and the most yolk are at the vegetal pole.

The cleavage proceeds with irregular manners with increased in the number of cells.

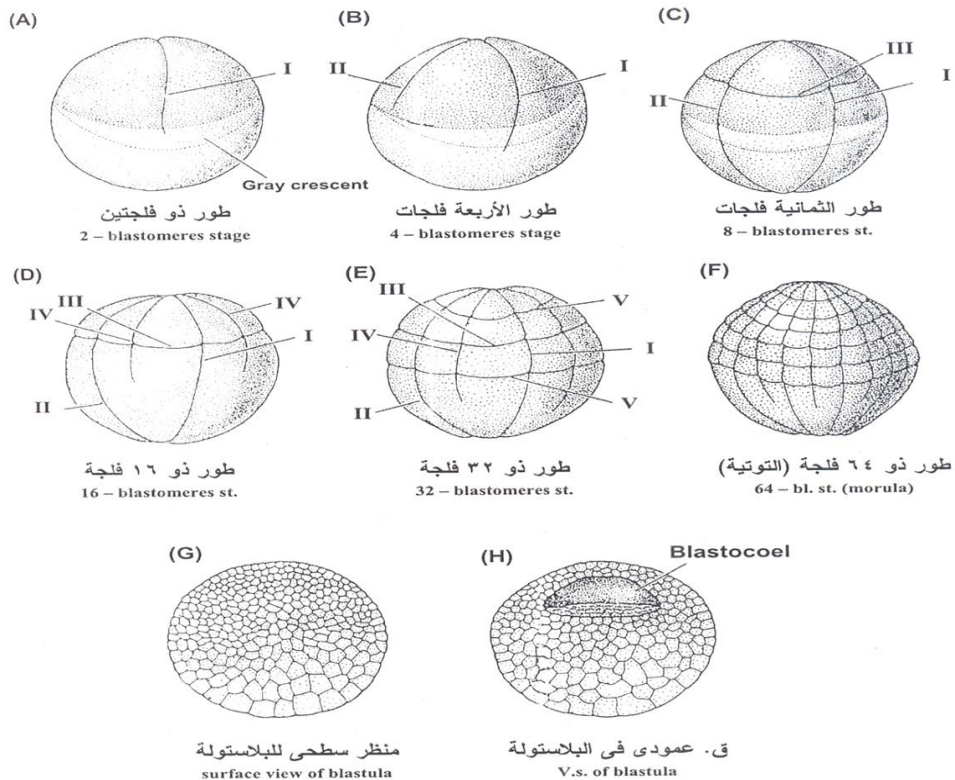
The Toad blastula

Blastula is a hollow spherical embryonic stage. The blastoderm remains two-cell thick towards the animal pole

of the egg, the sides and floor of the blastocoel are multilayered blastoderm of large yolky blastomeres.

-The blastoderm encloses ecentric (peripheral) blastocoel.

-The blastocoel becomes infiltrated by water and albuminous fluid secreted by the surrounding blastomeres.



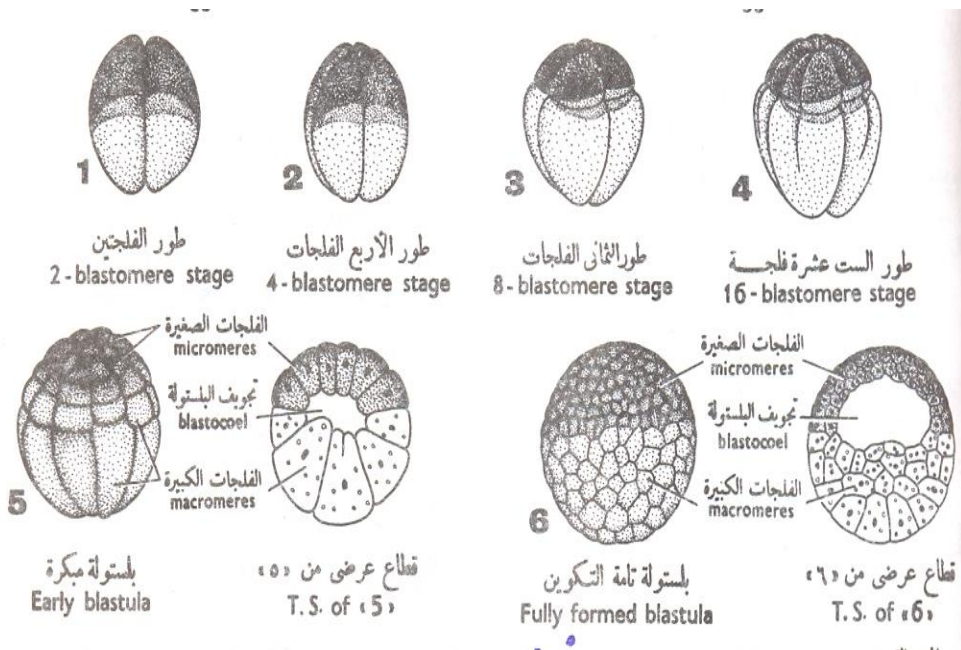
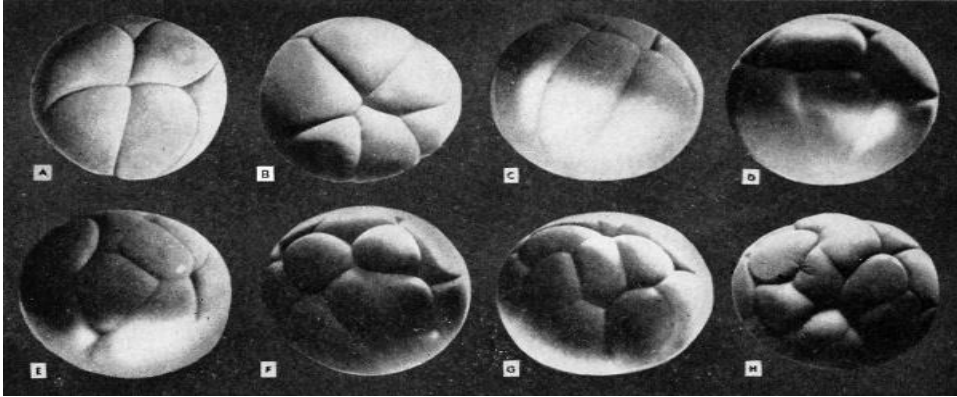


Figure 25: Cleavage and blastula formation of toad

Early Embryonic Development of Birds

Phylum: Chordata – Class: Aves (birds)

Fertilization : Internal.

Type of egg : According amount of yolk : Macrolecithal.

According to distribution of yolk: telolecithal.

Type of cleavage : Discoidal meroblastic cleavage.(
Cleavage is restricted to the blastodisc).

BLASTODISC is the portion where the embryo will form.

Reptiles and birds laid eggs with protective shell and a series of cellular membranes surrounding the embryonic .body

These membranes assist the embryo in vital functions, such as nutrition, gas exchange, and removal or storage of waste materials.

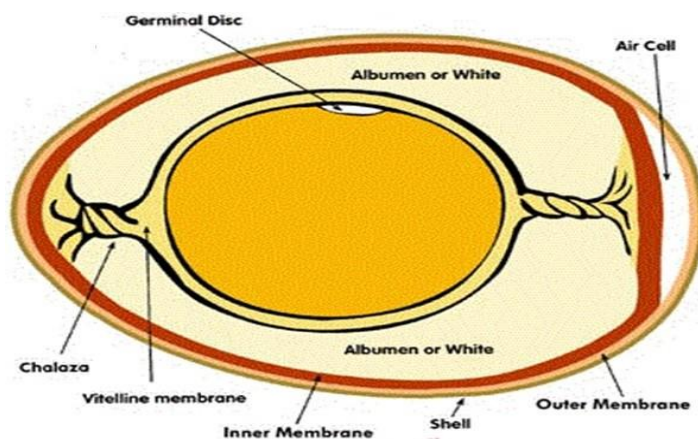


Figure 26: birds egg

Cleavage and blastulation

The first cleavage is vertical and give two blastomeres, the cleavage don't even pass entirely through the blastodisc.

The second cleavage at right angle to the first and give 4 blastomeres.

The third cleavage is two parallel furrows lies at right angles to the second cleavage result in 8 blastomeres. The furrows do not even reach the edge of the blastodisc.

The fourth cleavage also two furrows result in 16 blastomeres.

-The cleavage proceeds with irregular manners with increased in the number of cells and spread over the surface of the yolk. After awhile we can distinguish two groups of blastomeres.

- Central blastomeres that are completely bounded.

- Marginal blastomeres that are continuous with the rest of the undivided blastodisc

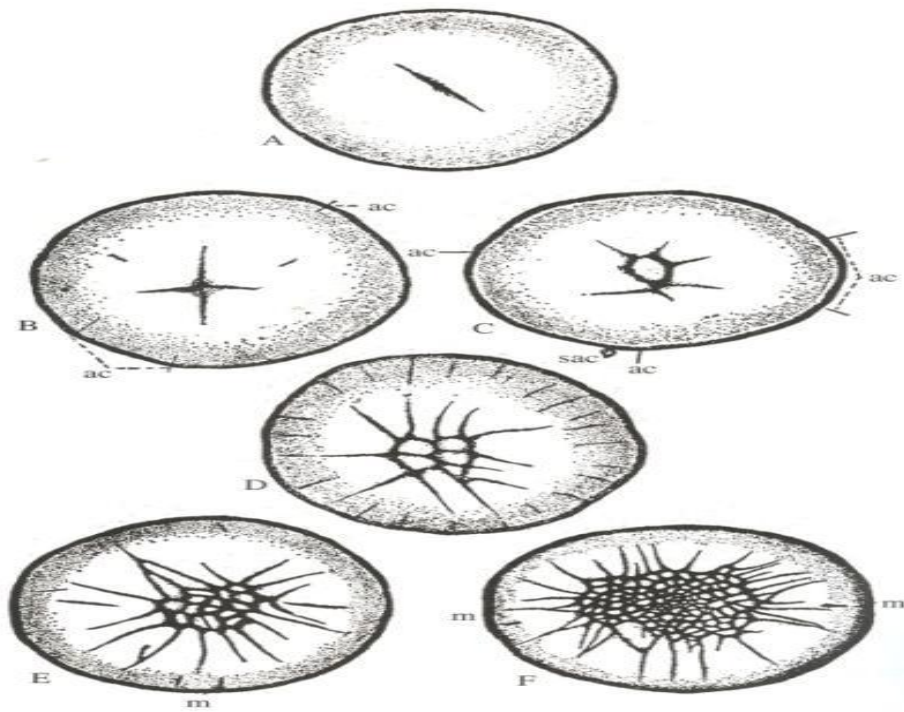


Figure 27: Cleavage and blastula formation of birds

BLASTODERM is a multilayered plate formed with a cavity beneath it. The cavity below it is called the subgerminal space.

The Blastula stage:

Some of the cells of the blastoderm above the subgerminal space are somewhat more heavily laden with yolk than others. they migrate down closer to the subgerminal space.

It results in a two-layered embryo. The upper layer is called the epiblast and the lower layer is called the hypoblast. Then, a space develops between the epiblast and the hypoblast, called blastocoel

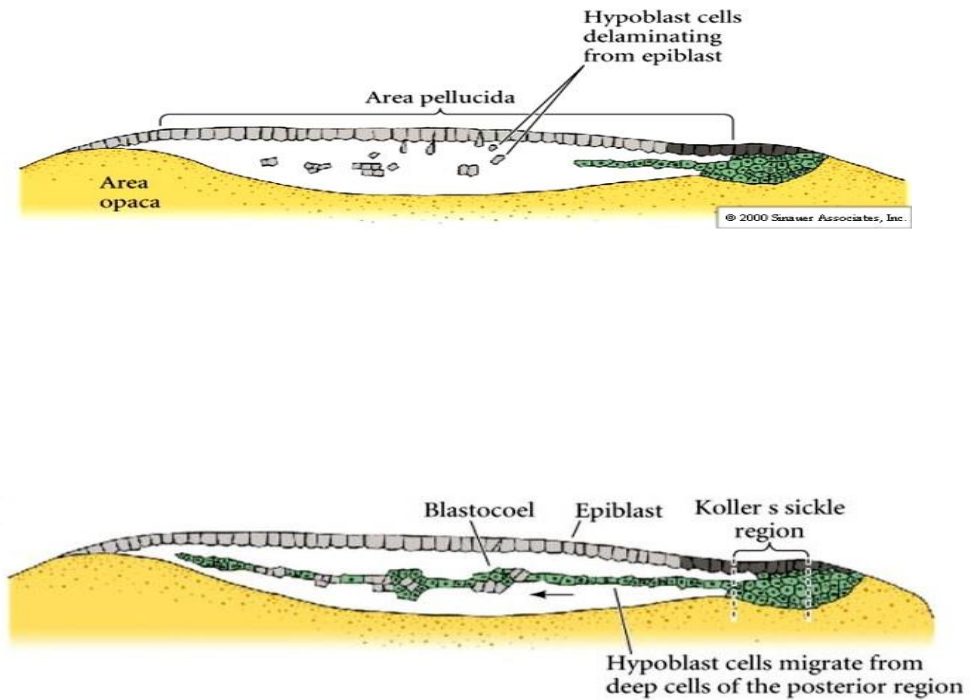


Figure 28: The Discoblastula

Embryonic Development of Mammals

Mammals classification according the embryonic development

into

- 1- Prototheria (primitive mammals) that lay eggs
- 2- Metatheria (pouched mammals)
- 3- Eutheria (placental mammals) Represent 94% of the class Mammalia.

Types of Mammals Uterus

- 1- Simple uterus
- 2- Duplex uterus
- 3- Bipartite
- 4- Bicornate uterus

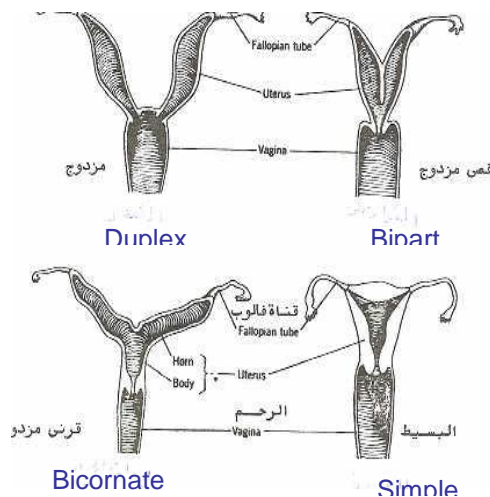


Figure29 : Types of Mammals Uterus

Early Embryonic Development of Mammals

Fertilization : Internal. Type of eggs : Alecithal type.

Type of cleavage: Holoblastic.

First Cleavage: Occurs at right angles to the axis and results in the formation of two blastomeres, takes place while embryo is still in the uterine tubes of the mother.

Second Cleavage: Mammals have what's known as **ROTATIONAL CLEAVAGE** wherein one of the blastomeres divides meridionally, and the other equatorially.

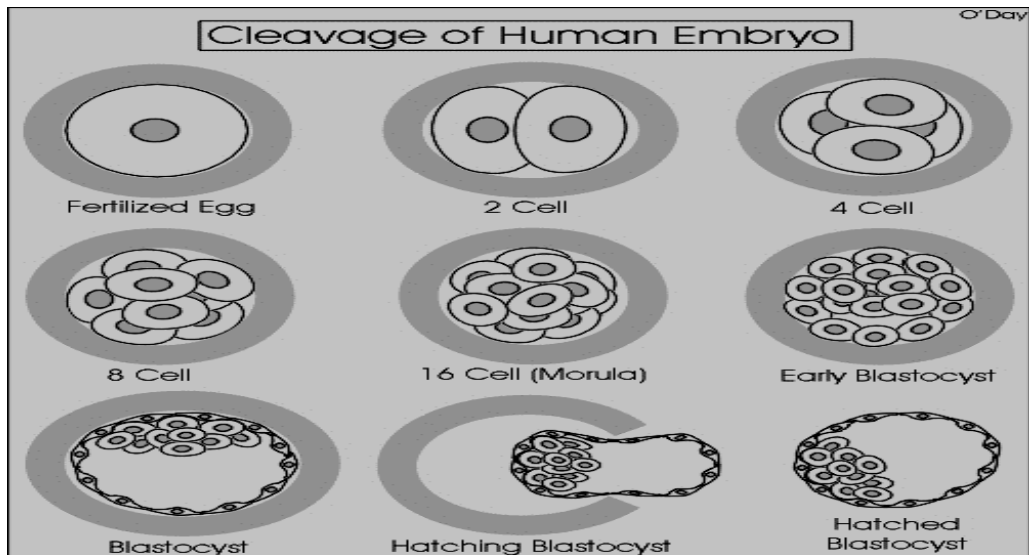


Figure 30:cleavage and blastula formation of mammals

Subsequent Cleavages are relatively less organized. At 3 days : The morula stage is formed. At 4-5 days :blastula stage is formed with The outer periphery trophoblast cells

and the inner cell mass. The embryo still surrounds by zona pellucida to make close contact of the blastomeres.

At the 6th day , the zona pellucida become lysed after the blastula reached to the proper side of the endometrium (Hatching of blastula). By the end of 8-10 days implantation is completed.

Twins

1-Binovular or dizygotic twins :

Occurred either naturally or as a result of ovarian stimulation lead to ovulate two eggs or more and then each fertilized by a sperm. The twins have totally different genetic characters.They may or may not be of different sex.

2- Identical or monozygotic twins:

Develops from a single fertilized ovum. They result from splitting of the zygote at various stages of development. Both have strong resemblance in blood groups, fingerprints, sex, and external appearance.

Modes of monozygotic twins

1-A cleaving embryo may split at an early stage of development, occur at the two-cell stage allowing the two portions to develop as completely separate embryos. And each embryo has its own placenta and chorionic sac.

2-At a later stage of development the inner cell mass may split into two separate masses within the same blastocyst cavity. The two embryos have a common placenta and a common chorionic cavity, but separate amniotic cavities.

3- If the inner cell mass does not become completely subdivided, conjoined twins may result. Conjugation may occur in different parts of the body.

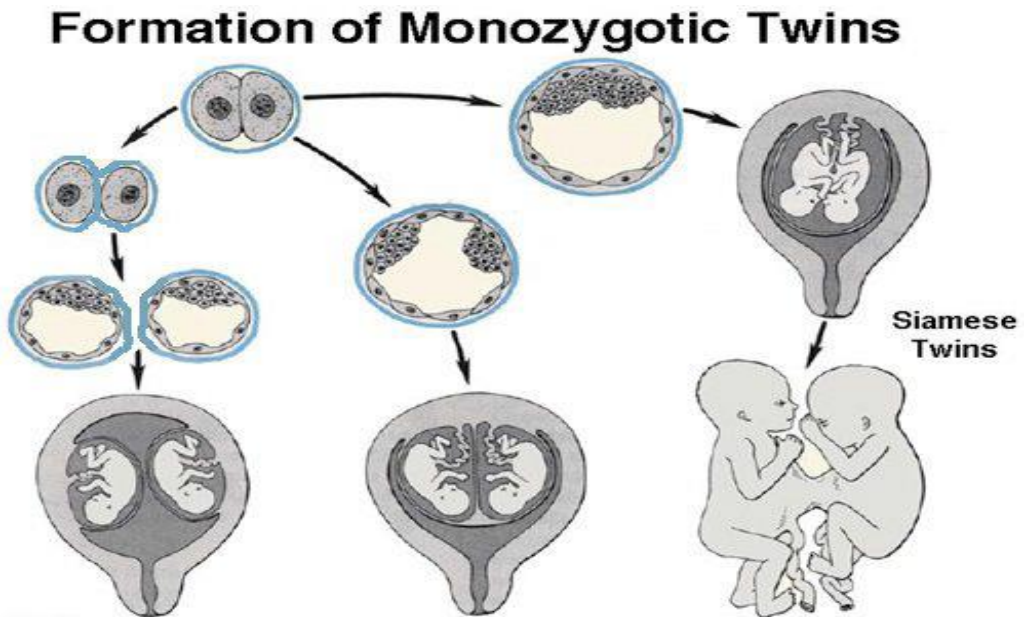


Figure 31: Formation of monozygotic twins